

# Toluidine blue as an adjunctive tool for early diagnosis of premalignant and malignant oral lesions

Surwaich Ali Channa<sup>1</sup>, Arhama Surwaich<sup>2</sup>, Muhammad Muslim Khahro<sup>3</sup>, Waqas Iqbal<sup>4</sup>, Uzma Tariq<sup>5</sup>, Abdul Majid<sup>6</sup>

<sup>1</sup>Senior Lecturer, Oral pathology department, Isra Dental College Hyderabad

<sup>2</sup>Senior Lecturer, Oral pathology department, Bhitai Dental and Medical College, Mirpurkhas

<sup>3</sup>Assistant professor, Science of Dental Material Department, LUMHS Jamshoro Hyderabad

<sup>4,5</sup>Assistant Professor, Oral pathology department, Isra Dental College Hyderabad

<sup>6</sup>Assistant Professor, Histopathology department, Isra University Hyderabad

## Author's Contribution

<sup>1,4</sup>Drafting the work or revising it critically for important intellectual content

<sup>2,3,6</sup>Substantial contributions to the conception or design of the work; or the acquisition, analysis, or interpretation of data for the work.

<sup>5</sup>Final approval of the version to be published

Funding Source: Nil

Conflict of Interest: Nil

Received for Publication:

February 23, 2019

Accepted for Publication:

July 15, 2019

## Address of Correspondent

Dr. Surwaich Ali Channa

Senior Lecturer, Oral pathology department, Isra Dental College Hyderabad

surwaish.channa@gmail.com

**Cite this article as:** Channa SA, Surwaich A, Khagro MM, Iqbal W, Tariq U, Majid A. Toluidine blue as an adjunctive tool for early diagnosis of premalignant and malignant oral lesions. *Ann Pak Inst Med Sci.* 2019; 15(1): 22-26.

## ABSTRACT

**Objective:** To determine the Toluidine blue as an adjunctive tool for diagnosis of premalignant and malignant oral lesions by taking histopathology as gold standard.

**Methodology:** This cross-sectional study was held at the Outpatient Department of Isra Dental College Hospital, Isra University, Hyderabad, over six months from January 2017 to June 2017. All patients of oral premalignant lesions were selected. Toluidine blue staining was used at lesion's area. The dye was applied directly with a cotton bud for 10-20 seconds and was decolorized and a photograph was taken. The dye retention pattern was evaluated by stain retention's intensity on the lesion. Incisional biopsy was performed simultaneously from that site as gold standard. The data was filled in proforma and analysis was done via SPSS version 20.

**Results:** Out of 60 cases, males were 49 (81.6%) and females were 11 (18.3%). The mean age of males and females was 41.9±10.7 years and 39.8±7.74 years respectively. 65.0% of patients had more than one addicting habit of *mainpuri*, *gutka* and *supari*. The commonest region of oral lesions was the buccal mucosa among 61.6% patients followed by alveolus in 16.6%, lips 8.3%, tongue 6.6%, retro molar area 3.33%, while palate and floor of mouth were involved in 1.66% patients. According to the diagnostic accuracy of methylene blue the sensitivity was 89.4% and specificity was 66.6%.

**Conclusion:** Toluidine blue staining is the best, reliable and noninvasive screening tools to detect the early diagnosis of malignancy.

**Keywords:** Premalignant and malignant lesions, Toluidine blue.

## Introduction

Cancer of the oral cavity is the higher relevant global problem of public health, it mostly arise on lips or oral cavity and more prevalent among males.<sup>1</sup> Most Oral cancers take place as squamous cell carcinomas; inspite of incredible developments in therapeutic modalities, the

survival rate of 5-year hasn't significantly enhanced over the previous many decades as well as yet drifts at nearly 50% to 60%.<sup>2,3</sup> The Oral cancer's commonest form is squamous cell carcinoma, which represents 96% of overall Oral cavity carcinomas.<sup>3</sup> Oral squamous cell

carcinoma (OSCC) is placed in 8<sup>th</sup> level in cancer prevalence globally, with an yearly prevalence of 64,460. Though total cases per unit time will remain 2.5-3 folds greater than this quantity.<sup>3</sup> Several OSCCs emerge from premalignant lesions & oral cavity disorders.<sup>4</sup> The tobacco usage has been found as a substantial risk for the occurrence of oral squamous cell carcinoma (OSCC) and premalignant lesions. Around 80% of cases with oral squamous cell carcinoma have utilized tobacco products; in addition, the risk of carcinoma development is 3 times higher among smokers contrasted to non-smokers.<sup>5</sup> Consumption of the alcohol has too been considered as hazard factor for creating the pre-malignant lesions and SCC. Even though not consistently believed to contribute in the oral malignancy development, studies have exhibited that heavy to moderate drinkers have 3 to 9-fold higher risk of acquiring malignancy. Actually, the heavy consumption of tobacco and alcohol in combination can possibly carry risk 100-folds higher than the general populace.<sup>5</sup> A variety of conditions are involved in occurrence of oral malignancy, including erythroplakia, oral sub-mucous fibrosis, leukoplakia, palatal lesion of reverse cigar smoking, discoid lupus erythematous, and hereditary conditions for instance epidermolysis bullosa and dyskeratosis congenital.<sup>7</sup> In spite of the wide accessibility of buccal cavity in the course of physical examination, several melanomas remain undiagnosed until late stage.<sup>8</sup> So that to avoid malignant metamorphosis of these predecessor lesions, multiple detection and screening methods have been established to deal with this challenge. The timely detection of malignance is of vital significance because rates of survival evidently improve if oral lesions are detected at early stage. Oral cavity's periodic clinical examination is most important in early detections.<sup>9</sup>

Presently, biopsy of oral cavity with histological appraisal is a benchmark for oral premalignant disorders. Yet, being invasive, a few patients can possibly not afford this investigation, particularly if lesion seems "normal". Furthermore, observer variability and subjectivity are much frequent in histologic diagnosis of oral premalignant disorders and oral cancer. The outcomes can possibly be influenced by depth and size of biopsy, specimen quality, freezing & fixation methods, and experience of pathologist.<sup>10</sup> So, techniques of detection which are non-invasive are required for oral premalignant disorders. In previous few decades, wide-ranging non-invasive methods have emerged for oral premalignant disorders detection. Though, it's challenging for clinicians to decide the most useful and

appropriate diagnostic tool for the screening of oral premalignant disorders.<sup>10</sup> The structures of mucosal surface of oropharynx and mouth are much like the proximal esophagus and neoplastic transformational risk factors at these areas are alike. Toluidine blue (TB) is a thiazine group's metachromatic dye which has been applied successfully as a nuclear stain due to its DNA binding characteristics. It has been reported that timely identification of asymptomatic oral cancer is often curable, inexpensive to manage and affords the best quality of life.<sup>11,12</sup> This study has been conducted to assess the Toluidine blue as an adjunctive tool for diagnosis of premalignant and malignant oral lesions by taking histopathology as gold standard. On best diagnostic accuracy this technique it should be considered as best diagnostic tool and should be applied for early diagnosis of oral malignant lesions.

## Methodology

This cross-sectional study was held at Outpatient Department of Oral Surgery, Isra Dental College and histopathological laboratory of Isra University, Hyderabad. Study duration was 6 months from Jan. 2017 to June 2017. All the patients aged from 20 to 70 years presented with oral premalignant lesion and either of gender were included. All the patients were interviewed regarding smoking, chewing betel quid, areca nuts etc and patients with the habit of tobacco consumption. Patients with an earlier history of radiotherapy, chemotherapy and with recurrence of oral SCC were excluded from study. All patients suffering from oral premalignant lesions underwent Toluidine blue staining and biopsy.

After documenting the clinical photographs and features of clinically suspicious lesion, the lesions sites were applied earlier with 1% lactic acid by cotton bud for 20 seconds and additionally rinsed with water to eliminate excess saliva and food debris and for providing a reliable oral setting. The mucosa of targeted site was gently cleaned with gauze and power air spray with triple syringe to make sure that the lesions are not being infested with saliva. Patients were underwent dye (1%) lugols iodine, which was directly applied with a cotton bud for 10 to 20 seconds and was decolorized with 2% acetic acid by cotton bud for 20 to 30 seconds and a photograph was taken in each patient. The dye retention had evaluated through stain retention intensity on the lesion. Dark blue retention was marked as positive (+) reaction for lesion suspicious of malignancy. While light blue retention was marked as positive (+) reaction for

pre-malignant lesion and the lesions without any retention was marked as normal. Toluidine blue dye staining findings were assessed by photographs. After that incisional biopsies were performed at the lesions and specimens were sent to diagnostic Hospital laboratory for histopathology to compare the diagnostic accuracy of Toluidine blue.

The data was analyzed via SPSS 22.0. The continuous variables were computed as mean and standard deviation. Categorical variable were computed as frequency and percentage. ROC-curve analysis was applied for sensitivity and specificity.

## Results

Total 60 patients were studied. Majority of patients were in 4th-5th decade of life and mean age of males was 41.9±10.7 years and female's 39.8±7.74 years. Out of all patients 49 (81.6%) were male and 11 (18.3%) were female. Patient's age groups, habits and site involvement are shown in Table I.

Table I: Basic information of patients (n=60)		
Variables	Frequency	%
<b>Age Groups</b>		
20-290	03	05.0%
30-390	19	31.6%
40-490	20	33.4%
50-590	15	25.0%
>600	03	05.0%
<b>Habits</b>		
Mainpuri	05	08.3 %
Ghutkha	02	03.3 %
Betel nut	08	13.4 %
Pan	03	05.0 %
Smoking	03	05.0%
More than one Habit	39	65.0%
<b>Site Involvement</b>		
Buccal mucosa	37	61.6%
Alveolus	10	16.6%
Lip	05	08.4%
Tongue	04	06.6%
Retromolar area	02	03.4%
Palate	01	01.6%
Floor of mouth	01	01.6%

Among pre-cancerous lesions homogenous leukoplakia was most common among 65.0% cases, speckled leukoplakia in 16.7% patients, epithelial hyperplasia was in 13.3% cases and erosive lichen planus was found only among 5.0% patients. Toluidine blue showed 89.4% sensitivity and 66.6% specificity. Figure 1

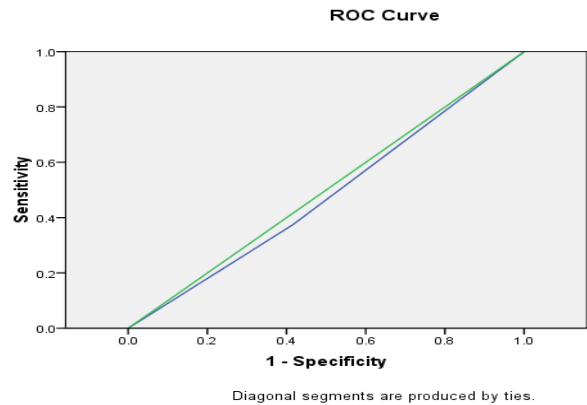


Figure 1. Sensitivity and specificity of (TB) in diagnosis of pre-malignant lesions by ROC curve analysis

## Discussion

Total 60 patients were studied their overall mean age was 41.58±6.23 years. Ya-Wei Chen et al<sup>1</sup> reported that the patients' ages (patient group) varied between 31 and 82 years (41±15 years), with the ratio of male to female being 51:7. In this study when habit profile of study population were seen more than 39 (65%) patients had multiple habits as smoking, mainpuri, naswar and paan while particularly 5 (8.3%) patients were used only mainpuri while 2 (3.3%) had habit of only *gutka*, 8 (13.3%) were taking betel nuts and 3(5%) were using *pan* only. Similarly, Ya-Wei Chen et al<sup>1</sup> reported that 2/3<sup>rd</sup> of cases were found with history of betel quid chewing, and 52 subjects had a history of cigarette smoking. In this study males were most common as compare to females. These findings were similar to Ya-Wei Chen et al<sup>1</sup> and Pallagatti S et al.<sup>14</sup>

In our study buccal mucosa was the most common site of lesion which is similar to Pallagatti S et al<sup>14</sup> who also found most common site lesions was buccal mucosa among 57.5% cases, labial vestibule in 27.5% cases and among 7.5% cases were commissural area and buccal vestibule. Similarly, in different other studies it is reported that most common sites of the Leukoplakia's were lateral tong, mouth flour and the lower lip exhibit more dysplasia for malignant alteration.<sup>2,3</sup>

Sensitivity of TB was found to be 89.4% while its specificity was 66.6%. These findings were similar to the study of Pallagatti S et al<sup>14</sup> as sensitivity and specificity for toluidine blue staining was 95% and 71.45% respectively. PPV and NPV were 84.6% and 90.9%, and 86.48% was diagnostic. Similarly, Allegra et al.<sup>15</sup> also observed that sensitivity and specificity of toluidine blue

96.2% and 77.7% respectively. Awan et al<sup>16</sup> also reported that staining of the toluidine blue has been utilized for a long time as the a guide for screening and post-careful administration for oral pre-malignant and malignant disease and it has been asserted that staining of the toluidine blue has a higher recognition rate of oral pre-malignant and could additionally lessen the frequency of oral malignant growth when contrasted with ordinary visual investigation reported by Su et al.<sup>17</sup> Parakh MK et al<sup>12</sup> reported that sensitivity and specificity of toluidine blue was 88.89% and 74.19% respectively. Desai Vela D et al<sup>18</sup> stated that staining of the toluidine blue to be profoundly solid in the recognition of extreme and moderate dysplasia however its utilization is flawed in the identification of the mild dysplasia, attributable to high false negative outcomes. It is a basic, reasonable and delicate seat side test; a profitable assistant to indicative procedure however not a substitute for either clinical judgment or biopsy. It has high possibility, particularly in low financial areas. PK Sinha et al<sup>19</sup> stated that TB when used as a vital stain is highly sensitive in identifying oral lesions with dysplastic epithelium as; out of 44 lesions which were diagnosed positive for presence of dysplasia on histological examination, 41 cases were stained positively with TB, thus giving a sensitivity of 97.6% and positive predictive value of 89.1%.

## Conclusion

Toluidine blue staining is reliable and noninvasive diagnostic tool for the early identification of the malignant and pre-malignant lesions of oral cavity with high sensitivity and specificity. Early identification of these lesions is important for prevention and management of malignancy. Betel quid and smoking habits should be avoided.

## References

1. Rivera C. Essentials of oral cancer. *Int J Clin Exp Pathol.* 2015;8(9):11884- 11894.
2. Waldron CA, Shafer WG. Leukoplakia revisited. A clinicopathologic study 3256 oral leukoplakias. *Cancer.* 1975;36(4):1386-1392.
3. Pogrel MA. Sublingual keratosis and malignant transformation. *J Oral Pathol.* 1979;8(3):176-178.
4. Kramer IR, El-Labban N, Lee KW. The clinical features and risk of malignant transformation in sublingual keratosis. *Br Dent J* 1978;144(6):171-180.
5. Chen YW, Lin JS, Wu CH, Lui MT, Kao SY, Fong Y. Application of in vivo stain of methylene blue as a

- diagnostic aid in the early detection and screening of oral squamous cell carcinoma and precancer lesions. *Journal of the Chinese Medical Association.* 2007 ;70(11):497-503.
6. Riaz A, Shreedhar B, Kamboj M, Natarajan S. Methylene blue as an early diagnostic marker for oral precancer and cancer. *Springer Plus.* 2013 ; 2(1): 95. doi.org/10.1186/2193-1801-2-95
7. Liu D, Zhao X, Zeng X, Dan H, Chen Q. Non-Invasive Techniques for Detection and Diagnosis of Oral Potentially Malignant Disorders. *The Tohoku journal of experimental medicine.* 2016; 238(2):165-177.
8. Epstein JB, Sciubba J, Silverman Jr S, Sroussi HY. Utility of toluidine blue in oral premalignant lesions and squamous cell carcinoma: continuing research and implications for clinical practice. *Head & Neck: Journal for the Sciences and Specialties of the Head and Neck.* 2007;(10):948-958.
9. Patton LL, Epstein JB, Kerr AR. Adjunctive techniques for oral cancer examination and lesion diagnosis: a systematic review of the literature. *The Journal of the American Dental Association.* 2008;139(7):896-905.
10. Masthan KM, Sankari SL, Babu NA, Rajguru JP. How to help the oral pathologist in making an accurate diagnosis. *Journal of clinical and diagnostic research: JCDR.* 2013 ;7(1):181-184.
11. Driemel O, Kunkel M, Hullmann M, Eggeling FV, Müller-Richter U, Kosmehl H, Reichert TE. Diagnosis of oral squamous cell carcinoma and its precursor lesions. *JDDG: Journal der Deutschen Dermatologischen Gesellschaft.* 2007;5(12):1095-1100.
12. Parakh MK, Reddy RJ, Subramani P. Toluidine blue staining in identification of a biopsy site in potentially malignant lesions: A case–control study. *Asia-Pacific journal of oncology nursing.* 2017 ;4(4):356-360.
13. Epstein JB, Scully C, Spinelli J. Toluidine blue and Lugol's iodine application in the assessment of oral malignant disease and lesions at risk of malignancy. *Journal of oral pathology & medicine.* 1992 ;21(4):160-163.
14. Pallagatti S, Sheikh S, Aggarwal A, Gupta D, Singh R, Handa R, Kaur S, Mago J. Toluidine blue staining as an adjunctive tool for early diagnosis of dysplastic changes in the oral mucosa. *Journal of clinical and experimental dentistry.* 2013;5(4):e187-e191.
15. Allegra E, Lombardo N, Puzzo L, Garozzo A. The usefulness of toluidine staining as a diagnostic tool for precancerous and cancerous oropharyngeal and oral cavity lesions. *Acta Otorhinolaryngol Ital.* 2009;29:187–190.

16. Awan, K.H., Yang, Y.H., Morgan, P.R. & Warnakulasuriya, S. Utility of toluidine blue as a diagnostic adjunct in the detection of potentially malignant disorders of the oral cavity-a clinical and histological assessment. *Oral Dis.*2012; 18: 728-733.
17. Su, W.W., Yen, A.M., Chiu, S.Y. & Chen, T.H. A community-based RCT for oral cancer screening with toluidine blue. *J. Dent. Res.*2010; 89: 933-937.
18. Desai Vela D, Narang Priyanka. Utility of Toluidine Blue Staining in the Detection of Oral Epithelial Dysplasia: a Diagnostic Adjunct. *Indian Journal of Public Health Research & Development.*2015: 6(1):80-85.
19. Parul Khare Sinha, Madhvika Patidar, Vineet Raj, Shaleen Chandra, Nitin Agarwal. Clinical and histological evaluation of toluidine blue positive and negative stained oral mucosal lesions.2016;2(3)120-124.