

# Clinical Pattern and Post-Operative Complications of Post Tuberculous Meningitis Hydrocephalus in Patients Underwent Ventriculoperitoneal Shunt

<sup>1</sup>Abdul Razaque Mari, <sup>2</sup>Muhammad Aslam Shaikh, <sup>3</sup>Fehmida Arab Mallah, <sup>4</sup>Sheraz Ahmed

## Author's Affiliation

<sup>1</sup>Assistant professor  
Department of Neurosurgery PUMHS  
Nawabshah

<sup>2</sup>Assistant professor  
Department of Neurosurgery  
SMBMU Larkana

<sup>3</sup>Senior registrar  
Department of Neurosurgery PUMHS  
Nawabshah

<sup>4</sup>Assistant professor  
Department of Neurosurgery DUHS  
Karachi

## Author's Contribution

<sup>1,2</sup>Conception, synthesis, planning of research and writing of manuscript

<sup>3</sup>Active participation in methodology, interpretation and discussion, review of manuscript, <sup>3</sup>Review of literature

<sup>4</sup>Statistical data analysis

<sup>4</sup>Data collection, data entries

## Article Info

Received: Aug 2, 2017

Accepted: Dec 19, 2017

Funding Source: Nil

Conflict of Interest: Nil

## Address of Correspondence

Dr. Abdul Razaque Mari

Email: razaqmari@yahoo.com

## ABSTRACT

**Objective:** To determine the clinical presentation of post tuberculous meningitis hydrocephalus and post-operative complications in patients underwent placement of a ventriculoperitoneal shunt.

**Study Design:** This Quasi-experimental study was conducted at Department of Neurosurgery of Dow University of Health Sciences/ Civil Hospital, Karachi. Study duration was six months from October 2013 to March 2014.

**Methodology:** Total 40 patients were studied who were diagnosed as cases of tuberculous meningitis and hydrocephalus on the basis of history, clinical examination, CSF findings, CT and MRI. Each patient underwent placement of a ventriculoperitoneal shunt. All the data regarding clinical presentation and postoperative complications was recorded in the proforma

**RESULTS:** Total 40 patients having tuberculous meningitis hydrocephalus were selected; their mean age was 16.4±07.8 years. Male were found in the majority 62.50%, as compared to female 37.50%. According to the clinical presentation, most patients 70.0% were presented with a headache and 62.50% with fever, followed by nausea and vomiting was in 37.5% patients, Neck rigidity was in 27.50% cases, extra neural tuberculosis in 25.0% patients, papilledema in 22.50% cases, limb weakness in 10.0% patients, while fits were found only in 5.0% of the patients. Past history of tuberculosis was in 7.50% patients. According to postoperative complications infection was found in 10.0% of the cases, peritoneal pseudo-cyst without infection was in 7.5% cases, while 10.0% patients died. No significant difference was found in the postoperative complications according to gender p-value 0.94.

**Conclusion:** It is concluded that a headache, fever and nausea/vomiting were the commonest clinical features and the Ventriculoperitoneal shunt is relatively simple and suitable for the patients of all age groups with hydrocephalus, its complications are relatively easy to manage.

**Key Words:** Hydrocephalus, clinical presentation, ventriculoperitoneal shunt, complications.

## Introduction

Tuberculosis is a major health hazard and neuro-tuberculosis especially tuberculous meningitis (TBM) is the main cause of death as complications of primary infection<sup>1</sup>. It is commonest form of serious extra-pulmonary tuberculosis most common in children as

compared to adults, particularly during first 5 years of the age.<sup>1</sup> Moreover, children having age 5 years or less mostly affected with tuberculous meningitis as compare to those having age more than 5 years. Tuberculous meningitis is the recurrent and

commonest cause of the prolonged morbidities and mortality in cases infected by it.<sup>2,3</sup> Tuberculous meningitis is the commonest infectious illness of "Central nervous system" in the developing nations. Initial diagnosis and the management including chemotherapy and proper management of developed complications importantly performed the role in the prevention of the irreversible neurologic sequel and the mortality.<sup>4</sup> Several sign and symptoms and morbidities of tuberculous meningitis resulting of immunological direct inflammatory reactions to the infections.<sup>5</sup> Development of tuberculous meningitis is the two steps process. Mycobacterium tuberculosis bacilli enter in the hosts through droplet inhalations, the early point of infection being alveolar macrophage. Localized infection increases within lungs, with the dissemination to regional lymph nodes to develop primary complex.<sup>5</sup> On presenting phase, the shortest but the significant bacteremia is present which may seed tubercle bacilli to the other organs of body. In cases those developed the Tuberculous meningitis, bacilli seed parenchyma of the brain or meninges in resulting formation developed of small subpial or subependymal foci of the metastatic caseous lesion. Tuberculous meningitis typically follows a subacute course with low-grade fever, headache, and intermittent nausea and vomiting, followed by more severe headache and fever, neck stiffness, drowsiness and cranial (usually oculomotor, but also II, VII and VIII) nerve palsies.<sup>6</sup> Progressive disease is associated with more pronounced meningeal signs, seizures and focal neurological deficits including hemiparesis and involuntary movements, increasing lethargy and signs of increased intracranial pressure (ICP). Some other clinical features of tuberculous meningitis including acute meningitis, disturbances of behavioral or intellectual without meningeal sign, seizures, encephalopathy, isolated cranial neuropathy, increased ICP, stroke and recurrent serous meningitis. Signs of meningitis present in approximately 70% of cases, cranial nerve palsy in 25% and focal neurological findings in 16-18%.<sup>7</sup> Hydrocephalus (dilatation of the ventricular system) may be due to obstruction of the CSF circulation or failure of absorption of CSF by the arachnoid villi, which lie in the parasagittal region and

in the rare circumstance, from increased production by a choroid plexus papilloma. CSF is ultra-filtrate of plasma in the central nervous system.<sup>8</sup> The clinical presentation of hydrocephalus is variable and depends on the age of onset,<sup>9</sup> cause, duration and rate of raised of intracranial pressure. Ventriculoperitoneal shunt most commonly used shunt in modern era.<sup>10</sup> It is relatively simple and it is suitable for patients of all ages with hydrocephalus from any cause, and the complications are relatively easy to manage.<sup>11,12</sup> Shunt complications and failures remain a significant problem in treating hydrocephalus. Many studies showed different rate of complications and outcome, therefore this study has been conducted to assess the clinical presentation of post tuberculous meningitis hydrocephalus and post-operative complications in patients underwent placement of a ventriculoperitoneal shunt.

## Methodology

This Quasi-experimental study was conducted at Department of Neurosurgery, Civil Hospital Karachi. Study duration was 6 months from October 2013 to March 2014. All the patients of all age groups and diagnosis of tuberculous meningitis hydrocephalus based on history, clinical features, CSF analysis, CT and MRI appearances of either sex were included in the study. All the cases with subarachnoid hemorrhage, pyogenic meningitis, leukemic infiltrate encephalitis and posterior fossa tumors were excluded. Patient's complete history was taken including duration of tuberculosis meningitis from initial diagnostic time to expose the hydrocephalus. The complete clinical examination was done before insertion of VP shunt to assess the preoperative GCS. Brain CT was carried out to assess the hydrocephalus presentation and its severity including infarction of the brain. All the patients underwent placement of ventriculoperitoneal shunting. Informed consent was taken from all the patients or their caretakers after complete explanation of risk and benefit of the procedure. Pudenz-Schulte medical ventriculoperitoneal shunt was placed under general anesthesia and under sterile condition ventricular catheters were placed at right occipital horn through the burr hole. Catheters were connected with peritoneal end by medium pressure chamber. After surgery cases were discharged in stable

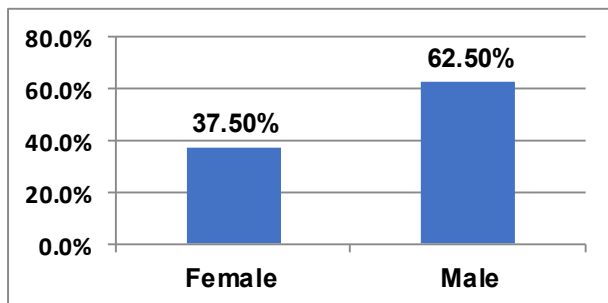
condition with standard 18 months therapy of anti-tuberculous medicine. Patients were followed up at 1<sup>st</sup> week, 2<sup>nd</sup> week, 1<sup>st</sup> month, 3<sup>rd</sup> month and 6<sup>th</sup> month interval in the outpatient department. All the data regarding clinical presentation and postoperative complications was recorded in the proforma. All the data was entered in the SPSS version 16 for analysis.

## Results

In this study total 40 patients with tuberculous meningitis hydrocephalus were selected, their mean age was 16.4+07.8 years with range of minimum 6 months and maximum 60 years. **Table I**

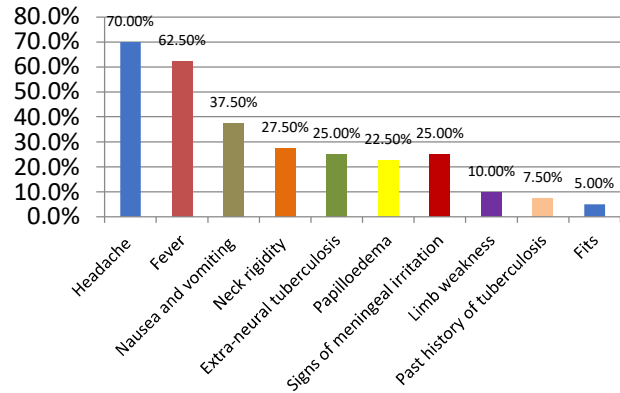
Table I: Patients distribution according to age (N=40)	
Mean Age of Patients	
Mean	16.4 years
Standard deviation	07.8 years
Minimum	06 months
Maximum	60 years

In this study, male were found in the majority 62.50%, as compared to female 37.50%. **Figure 1**



**Figure 1. Patients distribution according to gender (N=40)**

According to the clinical presentation, mostly patients were found with 70.0% headache and 62.50% fever, followed by nausea and vomiting was in 37.5% patients, Neck rigidity was in 27.50% cases, extra neural tuberculosis in 25.0% patients, papilledema in 22.50% cases, limb weakness in 10.0% patients, past history of tuberculosis was in 7.50% patients, while fits were found only in 5.0% of the patients. **Figure 2**



**Figure 2. Patients distribution according to clinical pattern (n= 40)**

According to the postoperative complications infection resulting to shunt malfunction was found in 10.0% of the cases, peritoneal pseudo-cyst without infection was found in 7.5% cases, while 10.0% patients were died. **Table II**

Table II: Post-Operative Complications (n= 40)		
Complication	No. of cases	Percentage
Infection	04	10.0%
Peritoneal pseudo-cyst without infection	03	07.5%
Mortality	04	10.0%

No significant difference was found in the postoperative complications according to gender p-value 0.94. Out of total 4 infected patients, 3 were male and 1 female. Total 3 patients died and out of the 3 were male and 1 female.

**Table III**

Table III: Post-operative complications According to gender (n= 40)				
Complications	Gender		Total	p-value
	Male	Female		
No complication	17	12	29	
Infection	03	01	04	
Peritoneal pseudo-cyst without infection	02	01	03	0.94
Mortality	03	01	04	
<b>Total</b>	<b>25</b>	<b>15</b>	<b>40</b>	

## Discussion

Hydrocephalus is the commonest complication of the tuberculous meningitis. It is still very important event in

adults especially in children. Ventriculo-atrial shunts are the initial choice for the shunt procedures. The distress of disseminating tuberculous disease by such shunt procedure was dispelled by Bhagwati and others,<sup>13-15</sup> and who pronounced the fruitful usage of ventriculo-atrial shunts in patients having tuberculous meningitis. According to this study, it was also found as a treatment option with less complications and mortality. In this study patient's mean age was  $16.4 \pm 07.8$  years with range of minimum 6 months and maximum 60 years. Inconsistently Kankane VK et al<sup>16</sup> reported that mean age was 3.25 years, which was lower, this may because age range of our study is very high as compare to it. In this study, male were found in the majority 62.50%, as compared to female 37.50%. Male to female ratio was consistent with a study conducted by Gambhir.<sup>17</sup> Similarly in the study Sarkar DN et al<sup>18</sup> reported that the incidence in males was 56.7% and in females 43.3%. Consistently Kankane VK et al<sup>16</sup> also found 56% male and 44% females.

In this study mostly, patients 70.0% were found with a headache and 62.50% had fever, followed by nausea and vomiting was in 37.5% patients, Neck rigidity was in 27.50% cases, extraneural tuberculosis in 25.0% patients, papilledema in 22.50% cases, limb weakness in 10.0% patients, past history of tuberculosis was in 7.50% patients, while fits were found only in 5.0% of the patients. Sarkar DN et al<sup>18</sup> reported that commonest prevalent symptom was fever in 91.7% patients. Headache was in 70%, altered consciousness was in 45%, vomiting was in 43.3% and neck stiffness was in 28.9% patients. Comparable findings were also seen in other studies.<sup>15,19</sup> In this study according to the postoperative complications infection was found in 10.0% of the cases, peritoneal pseudo-cyst without infection was found in 7.5% cases. Consistently in some other studies, infection rate was found from 13–14% patients underwent shunt surgery.<sup>20-22</sup> While Kankane VK et al<sup>16</sup> found less infection rate only 4% as compare to our study. In this study 10.0% patients were died during 6 months follow-up. On other hand Irfan A et al<sup>23</sup> reported that mortality was 22% during a follow-up period of 2 years. Palur et al<sup>24</sup> stated that mortality rate was 100% during 13 year follow-up and Bhagwati et al<sup>25</sup> reported that 43% mortality during 15 months follow-up. Though in this study

mortality rate was very low this may because the follow-up period of this study was very low as compare to above-mentioned studies, a prolonged follow-up very necessary to assess the better outcome. In this series, no significant difference was found in the postoperative complications according to gender p-value 0.94. One of the risks of such a strategy is that certain cases undergoing medical treatment may deteriorate quickly and have an unfavorable outcome if the surgery is delayed of shunt. Medical therapy also indicates incessant monitoring of cases in a prolonged hospital stay.

## Conclusion

It is concluded that a headache, fever and nausea/vomiting were the commonest clinical features and the Ventriculoperitoneal shunt is relatively simple, it is suitable for the patients of all age groups with hydrocephalus, and the complications are relatively easy to manage. As soon as hydrocephalous should be diagnosed and shunt procedure/ventricular drainage should be done which is the only lifesaving procedure. Hydrocephalous if treated early by shunting the cerebrospinal fluid to atrium or peritoneum has a good prognosis.

## References

1. Kumar P, Clark M. Neurological diseases. Clinical Medicine. 6th ed. Edinburgh: Elsevier Saunders, 2005: 1173-1272.
2. Hosoglu S, Geyik MF, Balik I, Aygen B, Erol S, Aygencel SG, et al. Tuberculous meningitis in adults in Turkey: epidemiology, diagnosis, clinic and laboratory. *Eur J Epidemiol* 2003; 18:337-43.
3. Fazel PA, Makki KU, Haroon H, Soomro IB, Afzal U. Clinical spectrum and outcome of patients with tuberculous meningitis. *Med Channel* 2006 Dec;12(4): 21-3.
4. Sarkar DN, Hossain MI, Shoab AK, Quraishi FA. Presentation of Tuberculous Meningitis Patients: Study of 30 Cases. *Medicine Today*. 2013 Aug 4;25(1):32-5.
5. Tarakad S Ramachandran, Tuberculous Meningitis; Chief Editor: Karen L Roos; Medscape; <http://emedicine.medscape.com/article/2011;1166190>
6. Strake JR, Munoz FM. Tuberculosis (Mycobacterium Tuberculosis). In: Kliegman RM, Behrman RE, Jenson HB, Stanton BF eds. *Nelson Text Book of Pediatrics*. 18th ed. New Delhi (India): Elsevier Saunders; 2007: 1240-54.
7. Skarar DN, Hossain MI, Shoab AK, Amin MR. Adenosine Deaminase (ADA) in Tuberculous Meningitis. *Bangladesh Journal of Medicine*. 2015 Sep 21;25(2):61-71.
8. Ganong WF. *Circulation through special regions*. Review of Medical Physiology. 22nd ed. Boston: Mc Graw Hill, 2005: 611-29
9. Rizvi R, Anjum Q. Hydrocephalus in children. *J Pak Med Assoc* 2005 Nov; 55(11): 502-6.

10. Irfan A. Role of V.P shunt in post TBM hydrocephalus. *J Pakistan Med Assoc* 1995; 45(2): 37-8.
11. Lamprecht D, Schoeman J, Donald P, Hartzberg H. Ventriculoperitoneal shunting in childhood tuberculous meningitis. *Br J Neurosurg* 2001 Apr; 15(2):119-25.
12. Agrawal D, Gupta A, Mehta VS. Role of shunt surgery in pediatric tuberculous meningitis with hydrocephalus. *Indian Pediatrics* 2005; 42: 245-250.
13. Bhagwati SN. Ventriculoatrial shunt in tubercular meningitis with hydrocephalus. *J Neurosurg* 1971;35:309-13
14. Roy TK, Sircar PK, Chandar V. Ventriculoatrial shunt in the management of tuberculous meningitis. *Indian Pediatr* 1979;16:1023-7.
15. Rajshekhar V. Management of hydrocephalus in patients with tuberculous meningitis. *Neurology India*. 2009 Jul 1;57(4):368.
16. Kankane VK, Gupta TK, Jaiswal G. Outcome of ventriculoperitoneal shunt surgery, without prior placement of external ventricular drain in Grades III and IV patients of tubercular meningitis with hydrocephalus: A single institution's experience in the pediatric population and review of literature. *Journal of pediatric neurosciences*. 2016 Jan;11(1):35.
17. Gambhir IS, Mehta M, Singh DS and Khanna HD. 'Evaluation of CSF-adenosine deaminase activity in tubercular meningitis', *J Assoc physician India*. 1999;47:192-194
18. Sarkar DN, Hossain MI, Shoab AK, Quraishi FA. Presentation of Tuberculous Meningitis Patients: Study of 30 Cases. *Medicine Today*. 2013 Aug 4;25(1):32-5.
19. Tyagi DK, Balasubramaniam S, Jayaswal SA, Savant HV, Gandhi AS. Outcome analysis of ventriculoperitoneal shunt procedures in hydrocephalus due to tubercular meningitis and non-infective cases. *International Journal of Contemporary Pediatrics*. 2016 Dec 22;3(4):1210-5.
20. Srikantha U, Morab JV, Sastry S, Abraham R, Balasubramaniam A, Somanna S, et al. Outcome of ventriculoperitoneal shunt placement in Grade IV tubercular meningitis with hydrocephalus: A retrospective analysis in 95 patients. *Clinical article. J Neurosurg Pediatr*. 2009;4:176–83.
21. Peng J, Deng X, He F, Omran A, Zhang C, Yin F, et al. Role of ventriculoperitoneal shunt surgery in grade IV tubercular meningitis with hydrocephalus. *Childs Nerv Syst*. 2012;28:209–15.
22. Lamprecht D, Schoeman J, Donald P, Hartzberg H. Ventriculoperitoneal shunting in childhood tuberculous meningitis. *Br J Neurosurg*. 2001;15:119–25
23. Irfan A, Qureshi A. Role of Ventriculoperitoneal Shunt in Post-tuberculous Meningitic Hydrocephalus. *JOURNAL-PAKISTAN MEDICAL ASSOCIATION*. 1995 Feb;45:37-.
24. Palur, R., Rajshekhar, V. Chandy, M.J. et al. Shunt surgery for hydrocephalus in tuberculous meningitis: A longterm followup study, *J. Neurosurg.*, 1991 ;74:64-69.
25. Bhagwati, SN. Ventriculo-atrial shunt in tuberculous meningitis with hydrocephalus. *J.Neurosurg.*, 1971 ;35:309-13