

Contents lists available at [ScienceDirect](http://ScienceDirect.com)

# Journal of Cranio-Maxillo-Facial Surgery

journal homepage: [www.jcmfs.com](http://www.jcmfs.com)

## Midcheek mass: 10 year of clinical experience



Giovanni Dell' Aversana Orabona<sup>a</sup>, Vincenzo Abbate<sup>a,\*</sup>, Pasquale Piombino<sup>b</sup>,  
Giorgio Iaconetta<sup>c</sup>, Luigi Califano<sup>a</sup>

<sup>a</sup> Department of Maxillofacial Surgery, University of Naples "Federico II", Naples, Italy

<sup>b</sup> Department of Otorhinolaryngology, University of Naples "SUN", Naples, Italy

<sup>c</sup> Department of Neurosurgery, University of Salerno, Salerno, Italy

### ARTICLE INFO

#### Article history:

Paper received 28 August 2013

Accepted 20 March 2014

#### Keywords:

Midcheek mass  
Minimally invasive approach  
Accessory parotid gland  
Vascular malformations  
Endoscopic approach

### ABSTRACT

This is a literature review and retrospective chart review of ten years experience on the treatment of midcheek masses in our department. The purpose of this study is to provide the reader with an overview of the pathology of this complex anatomic area focusing the attention on the differential diagnosis and the recent surgical strategies.

From May 2002 to December 2012 we enrolled 22 consecutive patients studied for masses located in the midcheek area. Only four studies were found in the literature describing the experience of individual centres reporting few cases of midcheek masses. Combined with the previously reported 37 cases, we describe 22 lesions for a total of 59 cases. Patients were evaluated with a head and neck clinical and instrumental examination. Apart from 4 cases treated with intramuscular infiltration of botulinum toxin for masseter hypertrophy, surgical approach to the lesions was varied: 10 patients received an external approach (standard parotidectomy approach or face-lift-type approach); 6 patients had the lesion removed through an intraoral approach; in 2 cases a direct skin incision was performed. In our series we found a significant rate (55.5%) of temporary complications in all the procedures performed (external, intraoral, direct skin approach). This study aims to emphasize the role of endoscope assisted surgery as a possible alternative to the traditional approaches for the management of well selected benign midcheek masses.

It would be advisable to increase the study of the endoscopic anatomy of the midcheek area in order to standardize the procedure and better define the surgical indications.

© 2014 European Association for Cranio-Maxillo-Facial Surgery. Published by Elsevier Ltd. All rights reserved.

### 1. Introduction

The term "midcheek" refers to a part of the midface on the anterior aspect of the face, between the lower eye-lid above, and the upper lip below.

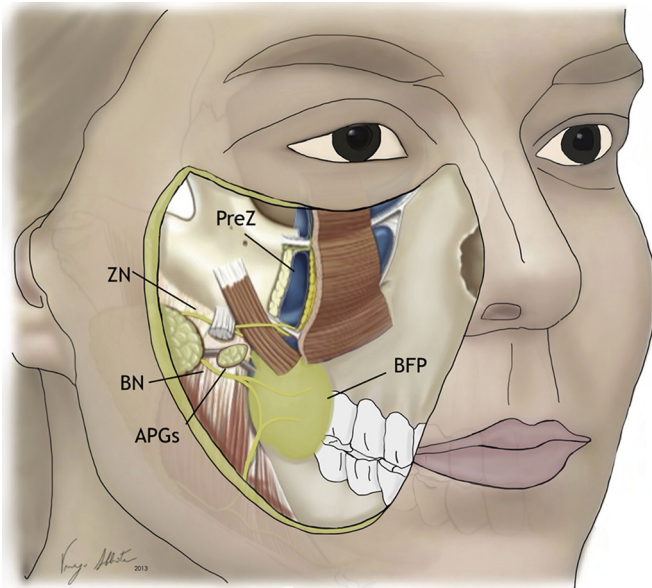
The midcheek is trapezoidal in shape, narrowing below, because of the roundness of the cheek. Laterally the midcheek region is bounded by an anterior concavity line, extending from the lateral canthus to the labial commissure. This line passes over the body of the zygomatic bone, the upper and anterior boundary of the masseter muscle and the anterior portion of the buccinator muscle (Mendelson and Jacobson, 2008) (Fig. 1).

The peculiar anatomical location and the presence of so many different structures in confined spaces, makes this region a formidable challenge for surgeons.

Pathology of this district is rare and the clinical evaluation of masses in the midcheek region can be difficult. Benign or malignant lesions in this area may arise from any number of the soft tissues of the face, including skin, lymphatic, adnexal, neurogenic, and salivary structures (Klotz and Coniglio, 2000). The differential diagnosis for midcheek soft tissue masses includes Solitary Vascular Malformations VMs (Cavernous hemangioma of APG, Intramasseteric hemangioma, vascular leiomyoma), benign or malignant lymphadenopathy, Masseter Muscle Hypertrophy, lipomas, neurofibromas, schwannomas, neurilemmomas, fibromas, malignant tumors arising from the muscles, buccal fat pad, or other structures, sialoceles, sialolithiasis and all benign and malignant tumors arising from APGs. Benign or malignant tumors originating from the accessory parotid glands (APGs) or parotid gland proper are among the most frequent diagnoses.

\* Corresponding author. Istitutional Address: Via Pansini 5, Naples 80131, Italy. Tel.: +39 (0) 817462176.

E-mail addresses: [giovanni.dellaversanaorabona@unina.it](mailto:giovanni.dellaversanaorabona@unina.it) (G.D. Aversana Orabona), [abbate.maxfacc@gmail.com](mailto:abbate.maxfacc@gmail.com) (V. Abbate).



**Fig. 1.** Midcheek has a trapezoidal shape, narrow below following of the roundness of the cheek. Laterally, the midcheek region is limited by a line extending from the lateral canthus to the labial commissure. This line passes over the body of the zygomatic bone, the upper and anterior border of the masseter muscle and the anterior portion of the buccinator muscle. PreZ, Prezygomatic space; ZN, Zygomatic nerve; BN, Buccal nerve; APGs, Accessory Parotid Glands; BFP, Buccal fat pad.

We found only four studies in the literature, describing the experience of some centres reporting a small number of cases of midcheek masses (Table 1).

A total of 37 cases were described, the largest number arising from the APGs (59.5%) (Klotz and Coniglio, 2000; De Riu et al., 2011; Jung et al., 2010; Zhong et al., 2012).

The authors focus their attention on a specific disease, however, there are still no reviews that describe all the midcheek masses.

This is a literature review and retrospective chart review of ten years experience of midcheek mass treatment in our Department. The purpose of this study is to provide the reader with an overview about the pathology of this complex anatomic area focusing the attention on the differential diagnosis and the recent surgical strategies.

## 2. Material and Methods

The Authors conducted a retrospective study on our patient database, analyzing all the cases treated in our department for masses located in the midcheek area.

From May 2002 to December 2012 we treated 22 consecutive patients (12 Females, 10 Males), with an average age of 38.8 years (range 6 y to 76 y) (Table 2).

All patients were evaluated with a head and neck clinical and instrumental examination. Apart from the presence of a progressively enlarging mass, the patients were all asymptomatic. None

complained of tenderness, difficulty chewing, or other head and neck symptoms (Fig. 2).

A careful neck examination disclosed no enlarged node in any patient. Sensation and facial nerve function were intact, and clear saliva flowed from the parotid duct in all cases. There was no evidence of intraoral disease.

Patients underwent ultrasound investigations (US), computerized tomography (CT) or magnetic resonance imaging (MRI) as well as fine-needle aspiration (FNAC) of the masses (Fig. 3a,b).

In three cases with masseter hypertrophy the diagnosis was so clear that it was not necessary to perform the FNAC.

Masseter hypertrophy was treated with intramuscular infiltration of botulinum toxin (Botox).

Surgical approach to the lesions was varied: 10 patients received an external approach (standard parotidectomy approach or face-lift-type approach); 6 patients had the lesion removed through an intraoral approach; in 2 cases a direct skin incision was performed (Fig. 4a–d).

Two cases of VMs received a selective embolization using alcohol copolymer agents 24 h before surgery.

The course of disease of the sample ranged from 6 to 34 months with a mean time period of 12.3 months.

## 3. Results

None of the patients receiving botulinum toxin for masseter hypertrophy showed complications at a 6-months follow-up.

After surgical procedures, the most common complications observed were hematoma, edema and temporary paralysis of the buccal and zygomatic branches of the facial nerve.

Facial nerve palsy fully recovered in all cases within 6-months after the intervention. In one case the paralysis of the buccal branch of the facial nerve was permanent due to the entrapment of the nerve in the neurofibromatous lesion.

None of the patients with Pleomorphic adenoma of APGs experienced recurrence at a 22 months follow-up.

Although they were all reversible, in our series there was a high complication rate (55.5%) in the approaches performed (Table 3).

## 4. Discussion

Only four studies in the literature describing the experience of individual centres reporting few cases of midcheek mass were found (Table 1). Adding our 22 cases with the previously reported 37 cases, results in a total of 59 cases observed to date.

An analysis of the cases described, showed that the most frequent pathology of midcheek region arises from the APGs. Lukšić et al., 2012 reported 162 cases of tumors originating from the APGs. These tumors are quite rare if considered alone; they account for 1–8% of all parotid tumors but they should always be taken into account in midcheek mass differential diagnosis (Frommer, 1977; Lewkowicz et al., 2000; Toh et al., 1993).

Differential diagnosis of a mass in the midcheek region can be a very difficult task. In our sample all patients were referred with a history of progressive enlarging and painless mass in the midcheek area. Head and neck clinical examination allowed us to guide the diagnostic choices in all patients. Klotz and Coniglio (2000) demonstrated that an accentuation of the mass on clenching the teeth was evident in all the case of Masseter muscle hypertrophy. Zhong et al. (2012) have reported that a change in size of the mass with the posture is suspect for a Solitary Vascular Malformations (VMs). The prevalence of VMs in midcheek area is second in frequency only to APG masses. According to Zhong et al. (2012) a Doppler ultrasound (US) is useful in order to obtain information about vascularity of the mass; however, what is important in the

**Table 1**  
Midcheek mass literature review.

Year	Author	Patients n.	APGs mass %	Other mass %
2012	De Riu G et al.	9	77.8%	22.2%
2012	Zhong LP et al.	12	33.3%	66.7%
2010	Jung YH et al.	7	85.7%	14.3%
2000	Klotz DA et al.	9	55.5%	44.5%
<b>Total</b>		<b>37</b>	<b>59.5%</b>	<b>40.5%</b>

**Table 2**

Summary of the 22 patients with midcheek masses.

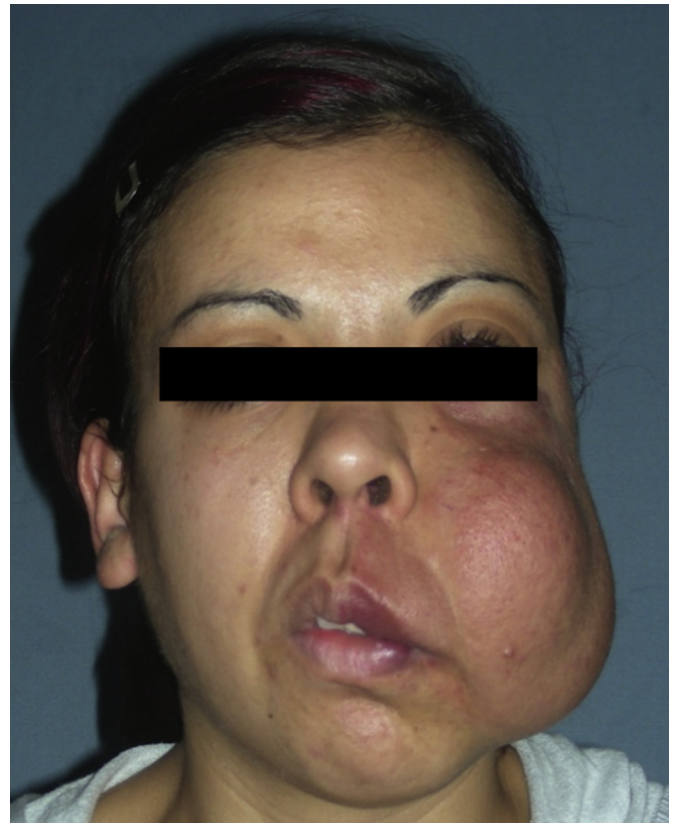
Patient no.	Age/ Sex	Size cm	FNAC	Final Diagnosis	Management	Follow-up month	Complication
1	F/17	1 × 1.2	Muscular tissue	Masseter hypertrophy	Botox infiltration	6	None
2	M/32	1.3 × 1.2	//	Masseter hypertrophy	Botox infiltration	6	None
3	F/76	2 × 1.5	Fibroliop tissue, lymphoepithelial cells	Chronic sclerosing sialadenitis of APGs	External	6	Temporary Facial nerve palsy
4	M/39	2.3 × 1	Salivary tissue	VMs/ Hemangioma of APGs	External previous Embolization	10	None
5	F/41	2.6 × 2	Fibroliop tissue	Lipoma	External	6	Edema, Hematoma
6	F/30	3 × 1.5	Blood and fibroliop tissue	VMs/Hemangioma	Intraoral	14	None
7	M/51	2.9 × 1.3	Linf B cells	APGs Scialoadenitis	External	24	Temporary Facial nerve palsy, Hematoma
8	M/11	4.1 × 1.7	Blood- tinged fluid without cellular component	VMs/Hemangioma	Intraoral	12	Edema, Hematoma
9	M/51	3 × 2.4	Lymph tissue	Lipoma	External	6	None
10	M/55	5.7 × 9.1	Fibroliop tissue	Fibroma	External	6	None
11	M/6	0.5 × 1	Neurogenic tumor	Neurofibroma	Direct skin incision	34	Buccal branches palsy
12	F/63	1.5 × 0.4	Salivary tissue	Fibroma of APGs	Intraoral	6	None
13	F/39	5 × 3	Fibroliop tissue	Lipoma	External	6	None
14	M/53	2.4 × 2	Pleomorphic adenoma	Pleomorphic adenoma of APGs	Intraoral	22	Hematoma
15	M/69	2.5 × 2.4	Fibroliop tissue	APGs Scialoadenitis	External	11	Temporary facial nerve palsy
16	F/20	4.2 × 5.3	Blood and inflammatory cells	VMs	Direct skin incision previous Embolization	13	Unpleasant scar Temporary facial nerve palsy
17	F/7	2 × 1	Blood- tinged fluid without cellular component	VMs/Linfangioma	Intraoral	36	Hematoma
18	F/19	1.4 × 2.1	//	Masseter hypertrophy	Botox infiltration	6	None
19	F/25	1.3 × 1	//	Masseter hypertrophy	Botox infiltration	6	None
20	F/54	2.2 × 1.4	Muscular tissue	Intramuscular lipoma	Intraoral	6	None
21	M/51	3 × 2.8	Fibroliop tissue	Fibroma of APGs	External	6	None
22	F/45	1.4 × 2.4	Pleomorphic adenoma	Pleomorphic adenoma of APGs	External	23	Temporary facial nerve palsy, Hematoma

management of VMs is to recognize accurately the origin of the mass. Actually these lesions may be intramuscular, may arise from APGs or may originate from midcheek vessels in general.

Magnetic Resonance imaging was extremely useful in diagnosing the mass as a VMs before surgery, clarifying relationships between the mass and adjacent structures and determining the surgical approach to the mass. Hemangiomas in the APGs had high T2-weighted signal intensity and showed strong patchy enhancement with gadolinium (Kaneko and Kanai, 2011) (Fig. 5a,b). Zhong et al. (2012) observed small flow voids on MR on both T1- and T2-weighted images where an intramuscular vascular malformation was present. Contrast enhanced CT scans were useful in all remaining cases as an investigation to obtain information about the anatomical relationships, with regard to the origin and extent of the underlying mass. Fine-needle aspiration cytology (FNAC), which is reliable, safe, and quick to perform, is still suggested as the first line diagnostic tool for a midcheek mass. In our experience we achieved good results on diagnostic accuracy, using Doppler ultrasound, CT scans and FNAC.

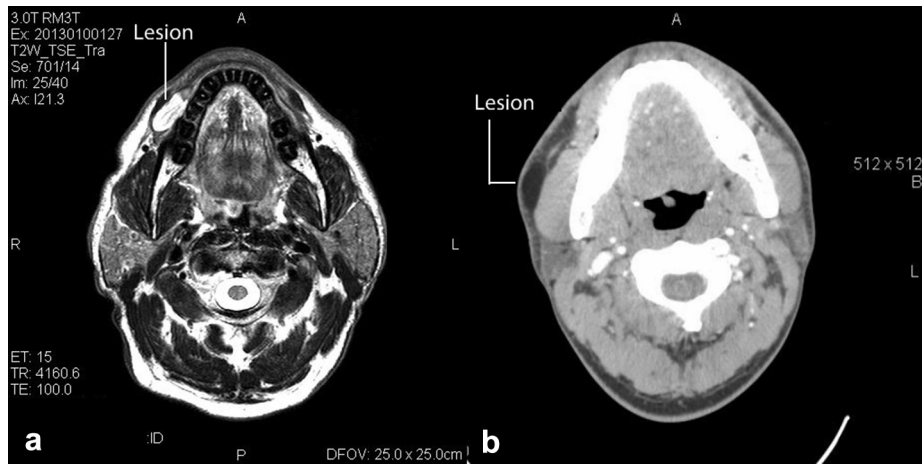
After differential diagnosis, the second important question concerns the surgical approach to the midcheek region. Most Authors focus their attention on the surgical treatment of specific midcheek masses (APGs, VMs etc), however, they do not describe the surgical management of the midcheek pathology in general. The Intraoral approach first described in 1979 was soon rejected because it provides inadequate exposure for the control of bleeding and preservation of facial nerve. Schmutzhard et al., 1979 proposed a reevaluation of this method as supported by active nerve monitoring and bipolar cautery but difficulties to obtain bleeding control and to avoid Stensen's duct damage still remain.

Direct skin incision over the mass was an ill-advised procedure. Johnson and Spiro (1979) reported a 40% incidence of facial nerve injury for tumors approached via a direct skin incision over the mass (May and Schaitkin, 2003; Stajčić and Roncević, 1990).

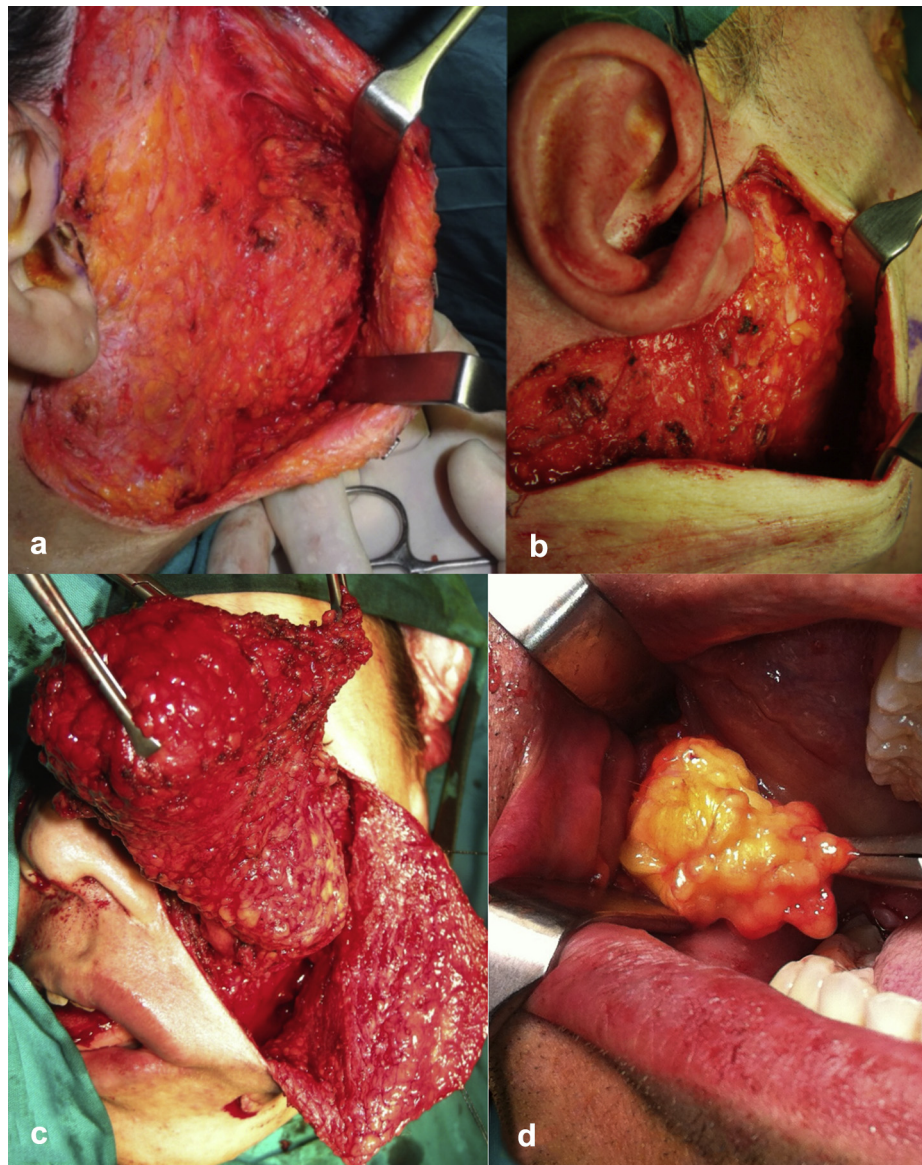

**Fig. 2.** Typical appearance of a patient with a large venous malformation (VMs) in the left midcheek.





**Fig. 3.** (a) T2 weighed MRI in axial view showing Hyperintense lesion in right midcheek, (b) axial view contrast enhanced CT scan showing Hypointense lesion in right midcheek.



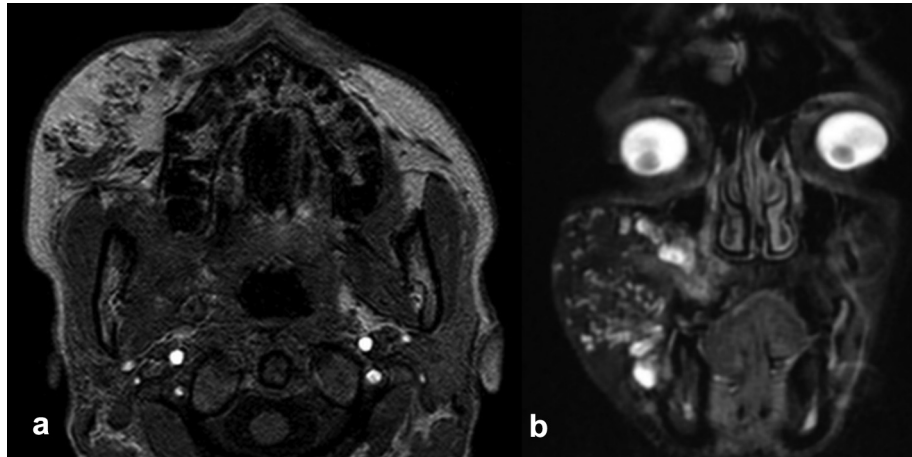
**Fig. 4.** External parotid approaches to reach midcheek area: (a) modified Blair s' incision; (b) Face-lift-type incision; (c) Direct skin incision over a large solitary vascular malformation (VMs) in left midcheek area; (d) Intraoperative pictures during removal of lipoma in the left midcheek area through an intraoral approach.

**Table 3**  
Post-operative complications.

Number of procedures	Approach	Complications	Complications rate
10	External	5	50%
6	Intraoral	3	50%
2	Direct skin incision	2	100%
18	Total	10	55.5%

## 5. Conclusions

In our series we found a significant rate of temporary complications in all procedures performed (external, intraoral, direct skin approach) which cause prolonged healing time and costs of care (Table 3). Good results obtained by endoscope assisted surgery suggest that this new approach could be a possible alternative to



**Fig. 5.** Right midcheek hemangioma on MR examination had high T2-weighted signal intensity (a); and showed strong patchy enhancement with gadolinium (b).

Most authors believe that the surgical approach of choice for APGs pathology is the standard parotidectomy incision (Blair's incision or face-lift incision) (Bozzetti et al., 1999; Brusati et al., 1987; De Maria et al., 2010; Kronenberg et al., 1988; Perzik and White, 1992; Rodino and Shaha, 1993).

Klotz and Coniglio (Klotz and Coniglio, 2000) suggest extending the incision superiorly into the hair bearing portion of the scalp and inferiorly into an upper cervical crease to obtain adequate exposure of the operative site and to obtain good bleeding and nerve control. Low-grade APGs malignancy may be adequately dealt with by wide excision without parotidectomy, while advanced stage disease requires total parotidectomy and neck dissection.

Perzik and White (Perzik and White, 1992) commented that managing every tumor with a formal superficial parotidectomy and full facial nerve dissection would increase morbidity with little added benefit.

According to Zheng (2012) Authors believe that VMs should be treated with a selective embolization of blood vessels supply before surgery; this procedure reduces the risk of bleeding and reduces post-operative complications as in our series. Jung et al. (2010) have suggested a new surgical procedure to treat the midcheek mass named "parotidotomy approach". After facial nerve trunk identification they bisected the parotid gland along the zygomatic and buccal branches preserving the parotid gland tissue as much as possible. In this way the mass is safely removed while protecting the facial nerve and the Stenson's duct, and avoiding unnecessary parotid gland resection (McCormack et al., 1945).

An incision up to 10–15 cm long, a large wound, and a visible scar on obvious facial areas are the common disadvantages of these parotidectomy approaches.

The balance between the operation's safety and the cosmetic and minimally invasive aspects must be considered. Xie et al., 2012 first described the results of minimally invasive endoscopic approach for resection of a benign tumor in the accessory parotid gland. Later, Li et al. (2013) evaluated the feasibility of a modified endoscopic approach with minimal, and concealed, incisions for the resection of benign tumors in the accessory parotid gland.

the traditional approaches for the management of well selected benign midcheek mass. Further studies are needed to increase the knowledge of the endoscopic anatomy of the midcheek area in order to standardize the procedure and better define the surgical indications.

## Acknowledgment

The authors are greatly indebted to and thankful for Marzia Petrocelli MD Resident to the Department of Maxillofacial Surgery, University of Naples "Federico II" for unstinting efforts and utter devotion in the development of this article.

## References

- Bozzetti A, Biglioli F, Salvato G, Brusati R: Technical refinements in surgical treatment of benign parotid tumours. *J Craniomaxillofac Surg* 27(5): 289–293, 1999 PubMed PMID: 10717830
- Brusati R, Bozzetti A, Chiapasco M: Facial nerve and parotid surgery. *J Craniomaxillofac Surg* 15(5): 278–280, 1987 PubMed PMID: 3479449
- De Maria G, Graziano P, Dell' Aversana Orabona G, Esposito F, Abbate V, Pavone E, et al: Surgical exposure of the parotid gland: Blair versus modified face lift incision. *Int J Maxillofac Surg* 21: 63–69, 2010
- De Riu G, Meloni SM, Massarelli O, Tullio A: Management of midcheek masses and tumors of the accessory parotid gland. *Oral Surg Oral Med Oral Pathol Oral Radiol Endod* 111(5): 5–11. <http://dx.doi.org/10.1016/j.tripleo.2011.01.005>, 2011 PubMed PMID: 21497733
- Frommer J: The human accessory parotid gland: its incidence, nature, and significance. *Oral Surg Oral Med Oral Pathol Oral Radiol Endod* 43: 671–676, 1977
- Johnson FE, Spiro RH: Tumors arising in accessory parotid tissue. *Am J Surg* 138: 576–578, 1979
- Jung YH, Hah JH, Sung MW, Kim KH: Parotidotomy approach for a midcheek mass: a new surgical strategy. *Laryngoscope* 120(3): 495–499. <http://dx.doi.org/10.1002/lary.20778>, 2010 PubMed PMID: 20058313
- Kaneko K, Kanai R: Cavernous hemangioma of the accessory parotid gland. *J Craniomaxillofac Surg* 22(6): 28–29. <http://dx.doi.org/10.1097/JCS.0b013e31822ec9a2>, 2011 PubMed PMID: 22134314
- Klotz DA, Coniglio JU: Prudent management of the mid-cheek mass: revisiting the accessory parotid gland tumor. *Laryngoscope* 110: 1627–1632, 2000
- Kronenberg J, Horowitz A, Creter D: Pleomorphic adenoma arising in accessory salivary tissue with constriction of Stensen's duct. *J Laryngol Otol* 102: 382–383, 1988
- Lewkowicz A, Levy Y, Zeltser R, Zagury A, Nahlieli O: Accessory parotid gland masses. *Oral Surg Oral Med Oral Pathol Oral Radiol Endod* 89: 610–612, 2000

- Li B, Zhang L, Zhao Z, Shen G, Wang X: Minimally invasive endoscopic resection of benign tumours of the accessory parotid gland: an updated approach. *Br J Oral Maxillofac Surg* 51(4): 342–346. <http://dx.doi.org/10.1016/j.bjoms.2012.07.014>, 2013 Jun [Epub 2012 Aug 11]. PubMed PMID: 22884850
- Lukšić I, Suton P, Rogić M, Dokuzović S: Accessory parotid gland tumours: 24 years of clinical experience. *Int J Oral Maxillofac Surg* 41(12): 1453–1457. <http://dx.doi.org/10.1016/j.ijom.2012.09.016>, 2012 Epub 2012 Oct 9. PubMed PMID: 23062716
- May M, Schaitkin BM: *Facial paralysis, rehabilitation techniques*. New York: Thieme, 2003
- McCormack LJ, Cauldwell EW, Anson BJ: *The surgical anatomy of the facial nerve: with special reference to the parotid gland*. *Surg Gynecol Obstet* 80: 620, 1945
- Mendelson BC, Jacobson SR: Surgical anatomy of the midcheek: facial layers, spaces, and the midcheek segments. *Clin Plast Surg* 35(3): 395–404. <http://dx.doi.org/10.1016/j.cps.2008.02.003>, 2008 discussion 393, Review. PubMed PMID: 18558234
- Perzik SL, White IL: *Surgical management of preauricular tumors of the accessory parotid apparatus*. *Am J Surg* 112: 498–503, 1992
- Rodino W, Shaha AR: *Surgical management of accessory parotid tumors*. *J Surg Oncol* 54: 153–156, 1993
- Schmutzhard J, Schwentner IM, Andrie J, Gunkel AR, Sprinzl GM: Resection of accessory parotid gland tumors through a peroral approach with facial nerve monitoring. *The J Craniofac Surg* 18: 1419–1421, 1979
- Stajčić Z, Rončević R: Facial nerve palsy following combined maxillary and mandibular osteotomy. A case report. *J Craniomaxillofac Surg* 18(5): 192–194, 1990 PubMed PMID: 2387906
- Toh H, Kodama J, Fukuda J, Rittman B, Mackenzie I: Incidence and histology of human accessory parotid glands. *Anat Rec* 236: 586–590, 1993
- Xie L, Zhang D, Lu X, Li G: Minimally invasive endoscopic-assisted resection of benign tumors in the accessory parotid gland. 5 case studies. *Head & Neck* 34: 1194–1197, 2012
- Zheng JW: Comment on surgical management of solitary venous malformation in the midcheek region. *Oral Surg Oral Med Oral Pathol Oral Radiol* 113(3): 421–422. <http://dx.doi.org/10.1016/j.oooo.2011.09.001>, 2012 author reply 422–3, PubMed PMID: 22669148
- Zhong LP, Ow A, Yang WJ, Hu YJ, Wang LZ, Zhang CP: Surgical management of solitary venous malformation in the midcheek region. *Oral Surg Oral Med Oral Pathol Oral Radiol* 114(2): 160–166. <http://dx.doi.org/10.1016/j.oooo.2011.05.043>, 2012 Epub 2011 Aug 19. PubMed PMID: 22776728