



TITLE:

# A case of pulmonary arterial hypertension complicated by anti-neutrophil cytoplasmic antibody-associated vasculitis and systemic sclerosis

AUTHOR(S):

Yoshifuji, Hajime; Kagebayashi, Sumika; Kinoshita, Hideyuki; Fujii, Takao; Okano, Yoshiaki; Katsushima, Masao; Mimori, Tsuneyo

---

CITATION:

Yoshifuji, Hajime ...[et al]. A case of pulmonary arterial hypertension complicated by anti-neutrophil cytoplasmic antibody-associated vasculitis and systemic sclerosis. *Immunological Medicine* 2021, 44(4): 263-269

ISSUE DATE:


2021

URL:

<http://hdl.handle.net/2433/277830>

RIGHT:

© 2021 The Author(s). Published by Informa UK Limited, trading as Taylor & Francis Group on behalf of the Japanese Society of Clinical Immunology.; This is an Open Access article distributed under the terms of the Creative Commons Attribution License, which permits unrestricted use, distribution, and reproduction in any medium, provided the original work is properly cited.



## Immunological Medicine

ISSN: (Print) (Online) Journal homepage: <https://www.tandfonline.com/loi/timm20>

# A case of pulmonary arterial hypertension complicated by anti-neutrophil cytoplasmic antibody-associated vasculitis and systemic sclerosis

Hajime Yoshifuji, Sumika Kagebayashi, Hideyuki Kinoshita, Takao Fujii, Yoshiaki Okano, Masao Katsushima & Tsuneyo Mimori

To cite this article: Hajime Yoshifuji, Sumika Kagebayashi, Hideyuki Kinoshita, Takao Fujii, Yoshiaki Okano, Masao Katsushima & Tsuneyo Mimori (2021) A case of pulmonary arterial hypertension complicated by anti-neutrophil cytoplasmic antibody-associated vasculitis and systemic sclerosis, *Immunological Medicine*, 44:4, 263-269, DOI: [10.1080/25785826.2021.1874137](https://doi.org/10.1080/25785826.2021.1874137)

To link to this article: <https://doi.org/10.1080/25785826.2021.1874137>



© 2021 The Author(s). Published by Informa UK Limited, trading as Taylor & Francis Group on behalf of the Japanese Society of Clinical Immunology.



Published online: 15 Jan 2021.



Submit your article to this journal [↗](#)



Article views: 1799




View related articles [↗](#)



View Crossmark data [↗](#)

## A case of pulmonary arterial hypertension complicated by anti-neutrophil cytoplasmic antibody-associated vasculitis and systemic sclerosis

Hajime Yoshifuji<sup>a</sup> , Sumika Kagebayashi<sup>a</sup>, Hideyuki Kinoshita<sup>b,c</sup>, Takao Fujii<sup>a,d</sup> , Yoshiaki Okano<sup>c,e</sup>, Masao Katsushima<sup>a</sup> and Tsuneyo Mimori<sup>a</sup>

<sup>a</sup>Department of Rheumatology and Clinical Immunology, Graduate School of Medicine, Kyoto University, Kyoto, Japan;

<sup>b</sup>Department of Community Medicine Supporting System, Graduate School of Medicine, Kyoto University, Kyoto, Japan;

<sup>c</sup>Department of Cardiovascular Medicine, Graduate School of Medicine, Kyoto University, Kyoto, Japan; <sup>d</sup>Department of Rheumatology and Clinical Immunology, Wakayama Medical University, Wakayama, Japan; <sup>e</sup>Hanwa Dai-ni Senboku Hospital, Osaka, Japan

### ABSTRACT

Pulmonary arterial hypertension (PAH) is a rare complication of ANCA-associated vasculitis (AAV). We report a 37-year-old man with PAH complicated by both AAV and SSc who presented with dyspnea, cardiac enlargement, positive myeloperoxidase (MPO)-ANCA, anti-centromere antibodies, proteinuria, and urinary casts. Elevated pulmonary arterial pressure (58/22/34 mmHg) and low PAWP (2 mmHg) were confirmed by right heart catheterization. Treatment with glucocorticoids (GC) decreased urinary protein and serum MPO-ANCA; however, PAH did not respond to GC. Therefore, a combination of beraprost, bosentan, and tadalafil was needed. The differences in responses to GC suggest that the pathophysiology of nephropathy is different from that of PAH. We considered that nephropathy was associated with AAV but that PAH was associated with SSc in the present case. We discuss the pathophysiology and treatment response of PAH complicated by AAV, referring to nine past cases.

### ARTICLE HISTORY

Received 13 November 2020

Accepted 6 January 2021

### KEYWORDS

Pulmonary arterial hypertension; anti-neutrophil cytoplasmic antibody-associated vasculitis; microscopic polyangiitis; systemic sclerosis

## 1. Introduction

Anti-neutrophil cytoplasmic antibody (ANCA)-associated vasculitis (AAV) is a group of autoimmune diseases characterized by inflammatory cell infiltration causing fibrinoid necrosis of small blood vessels [1]. The clinical spectrum of AAV is broad and its presentation ranges from a skin rash to fulminant multisystem disorders, including rapidly progressive glomerulonephritis and diffuse alveolar hemorrhage. Among them, pulmonary arterial hypertension (PAH) is a rare condition associated with AAV [2–7], although PAH is a common complication of systemic sclerosis (SSc) [8,9] and systemic lupus erythematosus (SLE) [9,10]. We report a rare case of a 37-year-old man with PAH complicated by AAV and SSc and discuss the mechanisms of PAH in association with AAV and SSc.


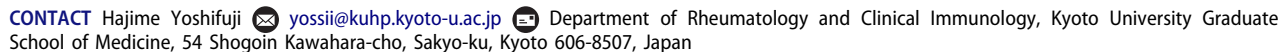
## 2. Case report

A 37-year-old man with no significant medical history presented with dyspnea on exertion and Raynaud's phenomenon that had continued for two

years. Because cardiac enlargement was detected during a chest X-ray examination, he consulted a primary doctor and received nifedipine and furosemide. Because positive anti-nuclear antibody and myeloperoxidase (MPO)-ANCA were detected, he was referred to the Department of Rheumatology and Clinical Immunology at Kyoto University Hospital. He had never used alcohol or cigarettes, and there was no family history of connective tissue diseases.

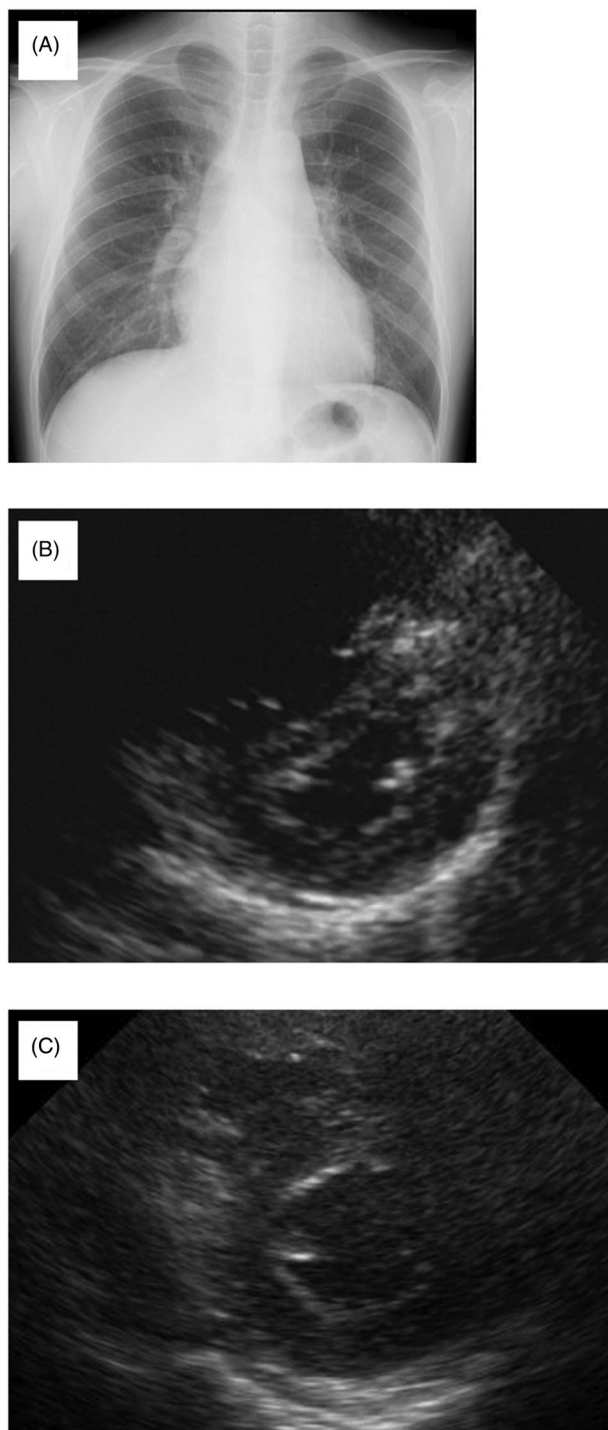
His height was 170 cm, body weight was 63.9 kg (body mass index, 22.1), blood pressure was 113/82 mmHg, pulse rate was 112/min, SpO<sub>2</sub> was 88–93% with room air, and basal temperature was 37.2 °C. Physical examination revealed sclerodactyly and telangiectasia on his chest. Cardiac auscultation found an accentuated second heart sound. There were no signs of ankyloglossia or skin ulcers.

Laboratory analysis revealed the following: white blood cells,  $11.1 \times 10^3/\mu\text{L}$ ; red blood cells (RBC),  $4.93 \times 10^6/\mu\text{L}$ ; hemoglobin, 15.6 g/dL; platelets,  $253 \times 10^3/\mu\text{L}$ ; erythrocyte sedimentation rate, 52 mm/h; aspartate transaminase, 34 IU/L; alanine transaminase, 25 IU/L; lactic dehydrogenase, 233 IU/L

**CONTACT** Hajime Yoshifuji  [yossii@kuhp.kyoto-u.ac.jp](mailto:yossii@kuhp.kyoto-u.ac.jp) 

© 2021 The Author(s). Published by Informa UK Limited, trading as Taylor & Francis Group on behalf of the Japanese Society of Clinical Immunology.

This is an Open Access article distributed under the terms of the Creative Commons Attribution License (<http://creativecommons.org/licenses/by/4.0/>), which permits unrestricted use, distribution, and reproduction in any medium, provided the original work is properly cited.



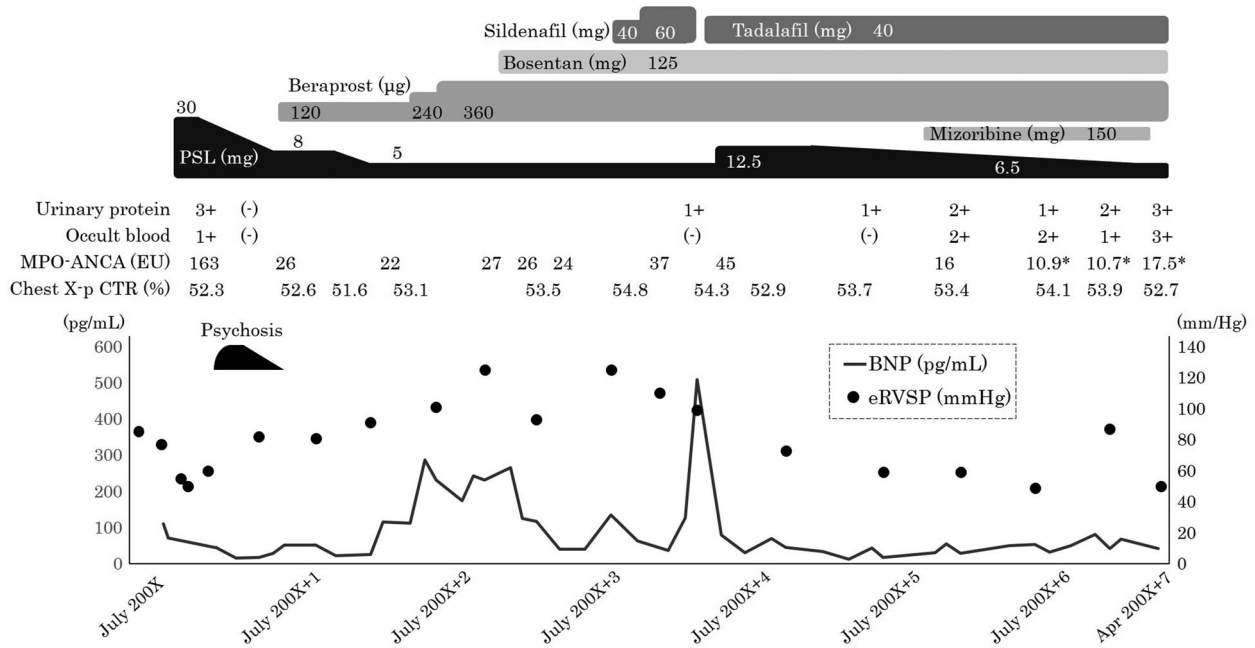
**Figure 1.** Chest X-ray (A) examination showed enlargement of the bilateral pulmonary artery. Transthoracic echocardiography (B) showed the compressed left ventricle in a D shape, which improved 7 years later (C).

L; alkaline phosphatase, 512 IU/L; total protein, 8.5 g/dL; albumin, 4.0 g/dL; creatinine, 0.8 mg/dL; sodium, 142 mEq/L; potassium, 4.2 mEq/L; C-reactive protein (CRP), 1.9 mg/dL; brain natriuretic peptide (BNP), 193 pg/mL; Krebs von den Lungen-6 (KL-6), 541 U/mL; immunoglobulin (Ig)-G, 2665 mg/dL; IgA, 573 mg/dL; IgM, 293 mg/dL; C3, 122 mg/dL (normal range: 70–125); C4, 12.6 mg/dL (normal range, 10.6–33.0); and CH50, 36 U/mL (normal range, 28–51). Anti-nuclear antibody (Ab)

(1:320; discrete speckled), rheumatoid factor (36.4 IU/mL), anti-centromere Ab (155 EU), anti-SS-A/Ro Ab (132 EU), anti-SS-B/La Ab (77 EU), anti-mitochondrial Ab (1:20), and MPO-ANCA (163 EU) were all positive, whereas anti-Scl-70, anti-U1-RNP, and anti-cardiolipin antibodies were all negative. A urinalysis revealed proteinuria with a score of 3+ and microhematuria with a score of 1+. Urinary protein was 0.7 g/day. Granular and RBC casts were observed in urinary sediments.

The Saxon test was positive (0.45 g/2 min), and the Schirmer test was negative (right, 18 mm/5 min; left, 19 mm/5 min). Hand X-ray showed calcification of soft tissue around his fingertips. Chest X-ray (Figure 1(A)) revealed enlargement of the bilateral pulmonary arteries. Interstitial pneumonia or lung fibrosis was not found by chest computed tomography (CT). Pulmonary perfusion scintigraphy did not reveal any perfusion defects. Electrocardiogram showed tall, peaked P waves in leads II, III, and aVF; dominant R wave was also noted in lead V1. The respiratory function test indicated the following: vital capacity (VC), 3.93 L; %VC, 98.5%; forced expiratory volume in 1 s (FEV<sub>1.0</sub>%), 81.7%; and %diffusing capacity of carbon monoxide (DLCO), 28.5%. Echocardiography showed severe dilation of the right atrium and ventricle, and the left ventricle was compressed in a D shape (Figure 1(B)). Left ventricular ejection fraction was 76%, mitral regurgitation was negative, aortic regurgitation was negative, and there was moderate tricuspid regurgitation. The estimated tricuspid regurgitation pressure gradient (TR-PG) was 67 mmHg. Right heart catheterization (RHC) revealed the following: pulmonary arterial pressure (PAP) of 58/22/34 mmHg (systolic/diastolic/mean [s/d/m]), right atrial pressure (RAP) of 0 mmHg, pulmonary arterial wedge pressure (PAWP) of 2 mmHg, cardiac output of 5.68 L/min, cardiac index (CI) of 3.30 L/min/m<sup>2</sup>, and pulmonary vascular resistance (PVR) of 451 dyn·sec·cm<sup>-5</sup>. Systolic PAP did not respond to high oxygen concentrations, but it decreased to 50 mmHg with 5 ppm of nitric oxide (NO) and to 45 mmHg with 30 ppm of NO. Coronary angiography, left ventriculography, and pulmonary angiography showed normal results.

The patient was classified with SSc according to 2013 American College of Rheumatology/European League Against Rheumatism classification criteria for SSc [11] and Sjögren syndrome (SS) according to the diagnostic criteria of Japanese Ministry of Health, Labour and Welfare [12]. Because of positive MPO-ANCA, elevated CRP, proteinuria, and microhematuria, he was suspected of having ANCA-associated glomerulonephritis. Although we performed a renal biopsy, we could not evaluate his



**Figure 2.** The clinical course from the diagnosis of PAH and AAV to the diagnosis of pancreatic carcinoma. \*The units of MPO-ANCA changed from EU to U/mL because a new enzyme-linked immunoassay system was adopted in 200X + 6. BNP: brain natriuretic peptide; CTR: cardiothoracic ratio; eRVSP: estimated right ventricular systolic pressure; MPO-ANCA: myeloperoxidase anti-neutrophil cytoplasmic antibody; PSL: prednisolone; TR-PG: tricuspid regurgitation pressure gradient.

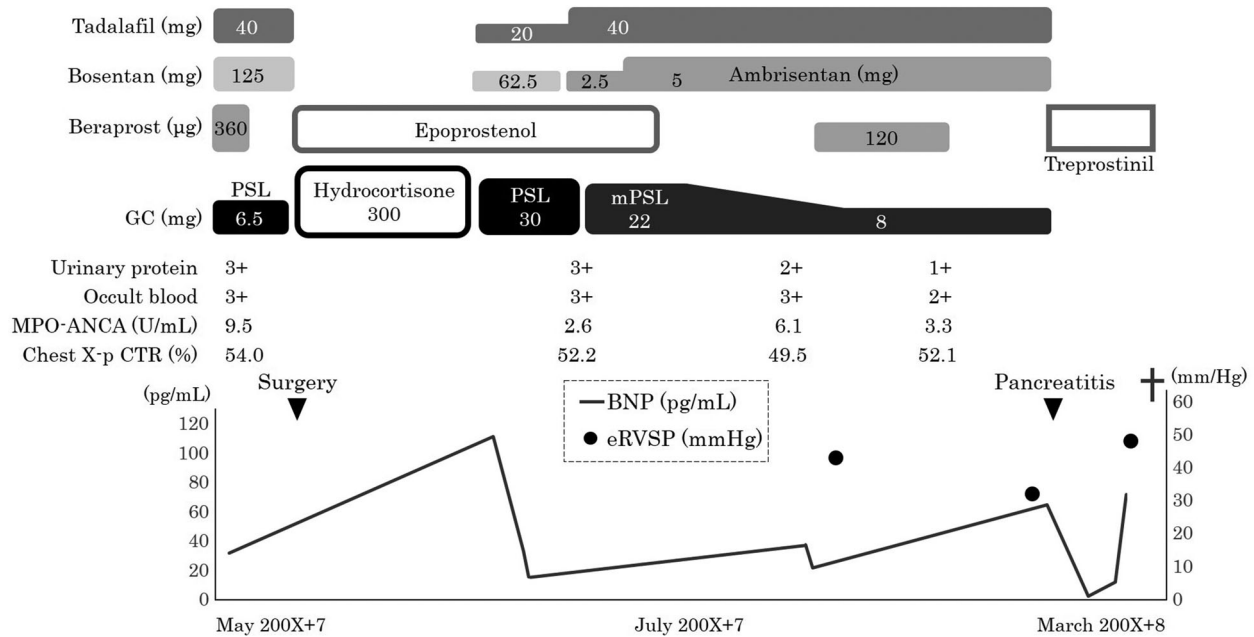
renal lesion because the sample contained only two glomeruli. After the biopsy, subcapsular hematoma emerged; therefore, re-examination was not performed. According to Watt's algorithm [13], he was classified as having microscopic polyangiitis (MPA). We excluded SLE because (1) malar rash, photosensitivity, serositis, and polyarthritis were not observed, and (2) although ANA was positive, it showed a discrete speckled pattern specific to SSc. We excluded thrombotic thrombocytopenic purpura, because no hemolysis or thrombocytopenia was observed. We excluded anti-glomerular basement membrane (GBM) disease, since anti-GBM antibody was negative. Next, according to 2015 ESC/ERS guidelines for the diagnosis and treatment of pulmonary hypertension [14], he was diagnosed as having group I pulmonary hypertension (PH) (i.e., PAH), after groups II, III, and IV PH were excluded because of low PAWP, normal lung CT findings, and normal pulmonary perfusion scintigraphy results.

Figure 2 shows the clinical course. Based on the diagnosis of PAH, nasal oxygen (1 L/min) was started. After 30 mg/day of prednisolone (PSL) was started to treat MPA and PAH, serum MPO-ANCA titers and urinary protein were decreased, and urinary occult blood and casts became negative. However, PAH was not improved; estimated right ventricular systolic pressure (eRVSP) had not decreased according to echocardiography. When we considered high-dose PSL to treat PAH, he reported fear and delusions of the devil; therefore, he was transferred to the Department of Psychiatry. He was

diagnosed with steroid psychosis and treated with risperidone and tapering of PSL dose. The psychiatric symptoms subsided, and he was discharged. Oral beraprost (maximum 360 μg/day) and bosentan (125 mg/day) were started to treat PAH in 200X + 1 and 200X + 2. However, eRVSP was not decreased; therefore, sildenafil (maximum 60 mg/day) was added in 200X + 3; sildenafil was switched to tadalafil (40 mg/day) due to worsening of dyspnea and elevation of BNP in 200X + 4. The eRVSP was improved by the combination of three pulmonary vasodilators. His cardiopulmonary symptom was also improved from World Health Organization functional class III to II. Cardiothoracic ratio on chest X-ray was slightly improved after starting the combination of tadalafil + bosentan + beraprost in 200X + 4. During the second RHC in 200X + 7, it was found that PAP had decreased to 49/20/29 mmHg (s/d/m), RAP was 2 mmHg, PAWP was 6 mmHg, CI was 2.80 L/min/m<sup>2</sup>, and PVR was 353 dyn·sec·cm<sup>-5</sup>. According to echocardiography, compression of the left ventricle had also improved (Figure 1(C)).

When the dose of PSL was tapered to 5 mg, serum CRP, MPO-ANCA titer, and urinary protein increased again (Figure 2). The dose of PSL was increased to 12.5 mg in 200X + 4, and serum CRP and MPO-ANCA titer decreased. Because proteinuria was unchanged, mizoribine (MZB) was added. However, proteinuria and microhematuria were aggravated. Mizoribine was considered ineffective and later discontinued, and we planned to start intravenous cyclophosphamide (IVCY). However,





**Figure 3.** The clinical course from surgery to death. BNP: brain natriuretic peptide; eRVSP: estimated right ventricular systolic pressure; GC: glucocorticoid; MPO-ANCA: myeloperoxidase anti-neutrophil cytoplasmic antibody; mPSL: methylprednisolone; PE: pulmonary embolism; PSL: prednisolone.

IVCY was not administered because the screening CT detected pancreatic carcinoma. The patient underwent surgery, but the tumor was not completely resected because of tumor adherence to adjacent organs.

An infusion of epoprostenol was used to control PAH after surgery (Figure 3). Five days after surgery, pulmonary embolism and heart failure occurred. Pulmonary embolism was treated with heparin, and heart failure was treated with milrinone and carperitide. The chest CT revealed diffuse ground-glass opacity of the lungs. We suspected acute lung injury due to the severe systemic conditions and treated it with hydrocortisone 300 mg/day followed by 30 mg/day of PSL. His hypoxia and general status were improved, and he was discharged. Seven months later, he was hospitalized because of pancreatitis and cholangitis, and died of sepsis at age 45 years.

### 3. Discussion

Connective tissue disease-associated PAH (CTD-PAH) can be grouped into two types [15]: PAH complicated by SSc (SSc-PAH) [8,9] and PAH complicated by other diseases except SSc (non-SSc-PAH), such as SLE [9,10], SS, and mixed connective tissue disease. Although non-SSc-PAH usually responds to GC, SSc-PAH is refractory to GC [9,16]. In the present case, whether PAH was associated with AAV, SS, or SSc was considered important because their responses to GC could be different.

PAH is a rare complication of AAV. We performed a systematic PubMed literature search using

the terms ‘ANCA-associated vasculitis’ and ‘pulmonary arterial hypertension’ from 1998 to 2019. There have been 10 cases diagnosed as both AAV and PAH in six literatures and the present report (Table 1) [2–7]. The diagnosis was granulomatosis with polyangiitis (GPA) for five, MPA for four, and eosinophilic granulomatosis with polyangiitis (EGPA) for one case. Although all ten cases were diagnosed as having PAH (or pre-capillary PH) by the attending physicians, their pathophysiology should be carefully reexamined. For example, the pathophysiology in cases 1 and 6 seemed close to group IV PH, because they had stenosis of the large pulmonary arteries by granulomatous lesion of GPA and required surgery [2,4]. In other seven cases, the diagnostic process seemed reliable; cases 2–5 were well-described by Launay et al. [3], and cases 7–9 were diagnosed by RHC [5–7]. However, notably, all seven cases had lung lesions; pulmonary granulomatosis occurred in three, diffuse alveolar hemorrhage occurred in two, and eosinophilic and interstitial pneumonia occurred in the other two cases. It means that group III PH and/or group IV PH were not completely ruled out and that PAH (group I PH) is only rarely associated with ANCA-associated vasculitis. On the contrary, the present case did not show lung lesions except during the postoperative episode and considered as having PAH. Taken together, the pathogenesis of pre-capillary PH complicated by AAV may be divided into three types: associated with lung lesions (group III-like; seven cases), large vessel involvement (group IV-like; two cases), and another mechanism described below (the present case).

**Table 1.** Past and present cases complicated by pre-capillary PH and AAV.

Case, [reference], author, year	Age, sex	Courses and organ lesions	Symptoms	PAP (mmHg)	ANCA	Treatment	Response to treatment
1. Doyle, 2003	34 F	GPA → 7 yr → PH Lung: Granulomatosis Stenosis of right main PA PH → 2 yr → GPA Lung: Micronodules Kidney: CRGN Mononeuritis multiplex	GPA: Saddle nose, deafness PH: Dyspnea, bradycardia	86/72 (s/d)	cANCA PR3	GPA: Not described PH: Pulmonary endarterectomy GPA: GC, IVCY	GPA: Not described PH: Surgery, Yes
2. Launay, 2006	49 M	GPA → 18 mo → PH Lung: Granulomatosis Pachymeningitis	PH: Dyspnea GPA: Nasal bleeding, weight loss	70 (m)	cANCA PR3	PH: Anticoagulant, nifedipine, IV-EPO GPA: GC, IVCY	PH: IV-EPO, Yes GPA: GC + IVCY, NA**
3. Launay, 2006	49 M	GPA → 18 mo → PH Lung: Granulomatosis	GPA: Headache, deafness PH: Dyspnea	44 (m)	cANCA	GPA: GC, IVCY, AZA PH: Anticoagulant	GPA: GC + IVCY, Yes PH: Anticoagulant, Yes
4. Launay, 2006	33 M	GPA → 6.5 yr → PH Lung: Granulomatosis Kidney: CRGN	GPA: Nasal bleeding, weight loss PH: Dyspnea, chest pain	55 (s)*	cANCA PR3	GPA: GC, IVCY, MMF, MTX, IFX, RTX PH: GC, IVCY, AZA	GPA/PH: GC + IVCY, Yes
5. Launay, 2006	38 F	MPA → 4 yr → PH Lung: DAH Kidney: RPGN	MPA: Hemoptysis PH: Dyspnea	57 (m)	pANCA MPO	MPA: GC, OCY, AZA PH: IV-EPO	MPA: GC + OCY, Yes PH: IV-EPO, Yes
6. Colin, 2014	62 F	GPA → 6 yr → PH Cardiac granulomatosis Stenosis of PA main trunk	GPA: AV block PH: Dyspnea	65 (s)*	(-)	GPA: Pacemaker PH: Prosthetic replacement of PA	GPA: Pacemaker, Yes PH: Surgery, Yes
7. de Menezes, 2015	28 M	EGPA → 3 yr → PH Lung: Eosinophilic pneumonia Orbital tumor, sinusitis	EGPA: Asthma, proptosis PH: Asymptomatic	39 (m)	(-)	EGPA: GC, IVCY, MTX, radiation PH: GC, IVCY	EGPA/PH: GC + IVCY, Yes
8. Li, 2015	21 F	MPA/PH: Simultaneous Lung: Interstitial pneumonia	MPA/PH: Dyspnea, cough, sputum	47 (m)	pANCA MPO	PH: BOS, GC, IVCY MPA: GC, IVCY mPSL pulse, GC	PH: BOS, No MPA/PH: GC + IVCY, Yes MPA/PH: mPSL + GC, No
9. Pilania, 2017	2 F	MPA/PH: Simultaneous Lung: DAH	MPA/PH: Dyspnea, edema	50 (TRPG)*	MPO	MPA: GC, mizoribine PH: Beraprost, BOS, SIL, TAD, IV-EPO, AMB, treprostinil	MPA: GC, Yes PH: GC, No Vasodilators: Yes
Present case	37 M	MPA/SSc/PH: Simultaneous Kidney: RPGN	MPA/SSc/PH: Dyspnea, Raynaud's phenomenon	58/22/34 (s/d/m)	pANCA MPO		

AAV: ANCA-associated vasculitis; AMB: ambrisentan; ANCA: anti-neutrophil cytoplasmic antibody; AZA: azathioprine; BOS: bosentan; CRGN: crescentic glomerulonephritis; d: diastolic; DAH: diffuse alveolar hemorrhage; EGPA: eosinophilic granulomatosis with polyangiitis; F: female; GC: glucocorticoids; GPA: granulomatosis with polyangiitis; IFX: infliximab; IVCY: intravenous cyclophosphamide; IV-EPO: intravenous epoetinol; M: male; m: mean; MMF: mycophenolate mofetil; MPA: microscopic polyangiitis; MPO: myeloperoxidase; mPSL: methylprednisolone; MTX: methotrexate; NA: not applicable; OCY: oral cyclophosphamide; PA: pulmonary artery; PH: pulmonary hypertension; PAP: pulmonary arterial pressure; PR3: proteinase 3; RPGN: rapidly progressive glomerulonephritis; RTX: rituximab; s: systolic; SIL: sildenafil; SSc: systemic sclerosis; TAD: tadalafil; TRPG: tricuspid regurgitation pressure gradient. Nine cases in the literature [2–7] and the present case are shown. \*Estimated by echocardiography. \*\*The patient died of sepsis in the short term.

Five out of the 10 cases (cases 4, 7, 8, 9, our case) showed PH onset accompanied by active AAV. PH in three (cases 4, 7, 8) of the five cases responded to GC plus IVCY, suggesting that PH can be controlled by immunosuppressive therapies in some patients with PH associated with AAV. In the present case, we expected PH to respond to GC at first, because PH onset was relatively acute and coincident with the onset of active nephropathy associated with AAV. However, although nephropathy showed a good response to GC with decreased urinary protein and serum MPO-ANCA titer, PH did not respond to GC; therefore, a combination of three pulmonary vasodilators was needed. Because of the differences in responses to GC, we reconsidered that nephropathy was associated with AAV, whereas PH was associated with SSc.

The phenotype of limited cutaneous SSc, positive anti-centromere antibody, and poor response to GC in the present case were compatible with SSc-PAH. Especially, Sanchez et al. reported that PAH complicated by SSc did not respond to GC plus IVCY and those cases required pulmonary vasodilators [9]. Recent reports have suggested that the increased FVC/DLCO ratio is a specific finding of SSc-PAH and useful for predicting the diagnosis of SSc-PAH [17,18]. Since the VC/DLCO ratio was as high as 3.45 ( $\geq 1.6$ ), it supported that PAH might be derived from SSc in the present case. Considering the low %DLCO (28.5%), it is possible that pulmonary veno-occlusive disease was also complicated in the present case. The present case also had SS. However, it seemed that the PAH was not associated with SS in the present case, because PAH associated with SS often responds to GC [16].

This case report had two limitations. First, the kidney lesion was not histologically confirmed due to a technical problem, although the diagnosis of MPA seemed to be certain because of positive MPO-ANCA, proteinuria, microhematuria, urinary casts, and their response to GC. Second, the maximal dose of PSL (30 mg/day) was relatively low and the immunosuppressive agent (MZB) that was used was mild. There was a possibility that high-dose GC and IVCY might have improved PAH associated with AAV. However, we hesitated to increase the dose of PSL to 1 mg/kg/day because steroid psychosis emerged after treatment and cancer was discovered when we were planning to start IVCY.

#### 4. Conclusions

PAH is a rare condition associated with AAV. Most reported cases with AAV and pre-capillary PH have lung lesions such as granuloma and interstitial pneumonia. Immunosuppressive therapies can be

effective on controlling PH in the patients who show PH onset accompanied by active AAV. We experienced a rare case with PAH and active AAV without lung lesion. The PAH did not respond to immunosuppressive therapies, and was considered to be associated with concomitant SSc.

#### Disclosure statement

The authors report no conflicts of interest directly relevant to the content of this article.

#### ORCID

Hajime Yoshifuji  <http://orcid.org/0000-0001-7082-4900>  
Takao Fujii  <http://orcid.org/0000-0002-1789-1984>

#### References

- [1] Jennette JC, Falk RJ, Bacon PA, et al. 2012 revised International Chapel Hill Consensus Conference Nomenclature of Vasculitides. *Arthritis Rheum.* 2013;65(1):1–11.
- [2] Doyle DJ, Fanning NF, Silke CS, et al. Wegener's granulomatosis of the main pulmonary arteries: imaging findings. *Clin Radiol.* 2003;58(4):329–331.
- [3] Launay D, Souza R, Guillevin L, et al. Pulmonary arterial hypertension in ANCA-associated vasculitis. *Sarcoidosis Vasc Diffuse Lung Dis.* 2006;23(3):223–228.
- [4] Colin GC, Pouleur AC, Lefebvre C, et al. Unexpected 'pulmonary hypertension' in a patient with granulomatosis with polyangiitis. *Eur Heart J.* 2014;35(44):3141.
- [5] de Menezes MB, Albuquerque de Andrade I, Cintra MB, et al. Pulmonary arterial hypertension and orbital involvement in a patient with eosinophilic granulomatosis with polyangiitis. *Clin Exp Rheumatol.* 2015;33(2 Suppl 89):S–182.
- [6] Li Y, Yi Q. Pulmonary arterial hypertension associated with rare cause of ANCA-associated vasculitis misdiagnosed as idiopathic one. *Int J Clin Exp Med.* 2015;8(9):16850–16853.
- [7] Paliana RK, Dhawan SR, Mathew JL, et al. ANCA-associated vasculitis presenting as severe pulmonary hypertension and right heart failure. *Indian J Pediatr.* 2017;84(10):799–801.
- [8] Salerni R, Rodnan GP, Leon DF, et al. Pulmonary hypertension in the CREST syndrome variant of progressive systemic sclerosis (scleroderma). *Ann Intern Med.* 1977;86(4):394–399.
- [9] Sanchez O, Sitbon O, Jaïs X, et al. Immunosuppressive therapy in connective tissue diseases-associated pulmonary arterial hypertension. *Chest.* 2006;130(1):182–189.
- [10] Perez HD, Kramer N. Pulmonary hypertension in systemic lupus erythematosus: report of four cases and review of the literature. *Semin Arthritis Rheum.* 1981;11(1):177–181.
- [11] van den Hoogen F, Khanna D, Fransen J, et al. 2013 classification criteria for systemic sclerosis: an American College of Rheumatology/European League against Rheumatism collaborative initiative. *Arthritis Rheum.* 2013;65(11):2737–2747.



- [12] Fujibayashi T, Sugai S, Miyasaka N, et al. Revised Japanese criteria for Sjögren's syndrome (1999): availability and validity. *Mod Rheumatol.* 2004; 14(6):425–434.
- [13] Watts R, Lane S, Hanslik T, et al. Development and validation of a consensus methodology for the classification of the ANCA-associated vasculitides and polyarteritis nodosa for epidemiological studies. *Ann Rheum Dis.* 2007;66(2):222–227.
- [14] Galiè N, Humbert M, Vachiery JL, et al. 2015 ESC/ERS Guidelines for the diagnosis and treatment of pulmonary hypertension: The Joint Task Force for the Diagnosis and Treatment of Pulmonary Hypertension of the European Society of Cardiology (ESC) and the European Respiratory Society (ERS): Endorsed by: Association for European Paediatric and Congenital Cardiology (AEPC), International Society for Heart and Lung Transplantation (ISHLT). *Eur Heart J.* 2016;37(1): 67–119.
- [15] Chung L, Liu J, Parsons L, et al. Characterization of connective tissue disease-associated pulmonary arterial hypertension from REVEAL: identifying systemic sclerosis as a unique phenotype. *Chest.* 2010;138(6):1383–1394.
- [16] Sato T, Hatano M, Iwasaki Y, et al. Prevalence of primary Sjögren's syndrome in patients undergoing evaluation for pulmonary arterial hypertension. *PLoS One.* 2018;13(5):e0197297.
- [17] Kato M, Sugimoto A, Atsumi T. Diagnostic and prognostic markers and treatment of connective tissue disease-associated pulmonary arterial hypertension: current recommendations and recent advances. *Expert Rev Clin Immunol.* 16(10):993–1004.
- [18] Gladue H, Steen V, Allanore Y, et al. Combination of echocardiographic and pulmonary function test measures improves sensitivity for diagnosis of systemic sclerosis-associated pulmonary arterial hypertension: analysis of 2 cohorts. *J Rheumatol.* 2013;40(10):1706–1711.