

Extracranial primary and secondary meningiomas

Giorgio Iaconetta¹,
Antonio Santella², Marco Friscia²,
Vincenzo Abbate², Luigi Califano²

¹Department of Neurosurgery, School of Medicine, University of Naples 'Federico II', Naples, Italy; ²Department of Oral and Maxillo-Facial Surgery, School of Medicine, University of Naples 'Federico II', Naples, Italy

Giorgio Iaconetta, Antonio Santella, Marco Friscia, Vincenzo Abbate, Luigi Califano: Extracranial primary and secondary meningiomas. Int. J. Oral Maxillofac. Surg. 2012; 41: 211–217. © 2011 International Association of Oral and Maxillofacial Surgeons. Published by Elsevier Ltd. All rights reserved.

Abstract. Meningioma is a well-recognized tumour of the central nervous system. However, extracranial non-dural or ectopic meningiomas are rare and in most of the reported cases, meningiomas are diagnosed only after histopathologic examination. Over the last 5 years, the authors have seen three cases. In these case reports, they discuss the salient features of these lesions, which can aid the preoperative diagnosis and management of these patients. One of the cases is a rarity, owing to the extreme extracranial position which allowed the pressure of the tumour abrade the adjacent structures. In one case, reconstruction of the skull bone using polymeric materials (Acrylic matter) was necessary. In the other two cases, titanium plates and screws were used to reconstruct the jaw.

Keywords: extracranial meningioma; skull base meningioma; ectopic meningioma.

Accepted for publication 31 August 2011
Available online 9 November 2011

Meningioma is a common intracranial tumour with a variety of histomorphologic growth patterns, which are usually easily recognized⁷. Their extracranial location is rare but two categories can be distinguished: primary and secondary extracranial meningiomas. The primary type arises from either displaced embryonic arachnoid cells or from multipotential mesenchymal cells, and the secondary type arises as a direct extension of an intracranial mass. Primary extracranial (ectopic, extracalvarial) meningiomas of the nasal cavity, temporal bone, paranasal sinuses, and nasopharynx (hereinafter referred to collectively as the sinonasal tract) are very rare.

The literature is generally limited to isolated case reports^{2,4,10,13,14} with a few reviews³. Histologically, meningiomas of the sinonasal district are identical to their intracranial counterparts, although diagnostic difficulties are frequently encountered in

the differential diagnosis with carcinoma, melanoma, and olfactory neuroblastoma resulting from the rarity of meningiomas in this location.

Meningiomas represent about 20–30% of all primitive encephalic tumours. They probably arise from the meningeal coverings, and arachnoid cap cells of the brain and spinal cord and 1–2% have an extracranial location¹. Possible mechanisms for extracranial meningioma have been proposed^{8,20}.

The most frequent sites of an external mass are the orbit, the outer table and scalp, the paranasal sinuses, the nasal cavity, the parotid and parapharyngeal region. It has been estimated that about 20% of intracranial meningiomas could develop an extracranial extension, and the most common site is the orbit. Following invasion of the temporal bone, the most common extension route is through the jugular and lacerate foramina into the

nasopharyngeal, retromaxillary, retromandibular and cervical spaces, whilst invasion of the external auditory canal is very uncommon^{5,18}. Extension through the foramina rotundum, spinosum and ovale, such as the pterygomaxillary fissure, the sphenopalatine foramen and the pterygopalatine canal is rare. When meningiomas occur in the head and neck, the diagnosis and management often represent a great challenge.

The differential diagnosis of extracranial meningiomas includes a variety of benign and malignant neoplasms, including epithelial tumours (carcinoma), neurogenic tumours (melanoma and olfactory neuroblastoma), vascular tumours (angiofibroma, paraganglioma), and mesenchymal tissue tumours (aggressive psammomatoid-ossifying fibroma)²².

According to the WHO classification there are 15 histologic subtypes of meningiomas (Table 1). Amongst these subtypes,

Table 1. World Health Organization (WHO) classification of meningiomas.

	WHO grade
Meningiomas with low risk of recurrence or aggressive growth	
Meningothelial	I
Fibrous (fibroblastic)	I
Transitional (mixed)	I
Psammomatous	I
Angiomatous	I
Microcystic	I
Secretory	I
Lymphoplasmacyte-rich	I
Metaplastic	I
Meningiomas with greater likelihood of recurrence and/or aggressive behaviour	
Atypical	II
Clear cell (intracranial)	II
Chordoid	II
Meningiomas of any subtype or grade with high proliferative index and/or brain invasion	
Rhabdoid	III
Papillary	III
Anaplastic (malignant)	III

meningothelial, fibrous and transitional (mixed) are the most common. The prognostic significance of these subtypes is very low, although some subtypes, such as clear cell meningiomas and papillary meningiomas, are clinically aggressive; 2–10% of these tumours are malignant.

Meningiomas are soft, smooth-surfaced masses with a broad dural attachment; the microscopic findings show lobules of neoplastic cells creating a syncytial appearance, and fibrous tissue is typically scant. The cells show round to oval nuclei, delicate chromatin, small solitary nucleoli, and often nuclear-cytoplasmic invaginations called pseudoinclusions (syncytial variant). The transitional variant demonstrates prominent lobules, whorls, collagenized blood vessels, and psammoma bodies. The fibrous variant is generally less cellular and consists of elongated cells immersed in a collagen-rich matrix. The classic ultrastructural findings show interdigitating processes, well-formed desmosomes and hemidesmosomes. Atypical and malignant meningiomas demonstrate hypercellularity, necrosis, sheet-like growth and the cytologic findings include high nuclear-cytoplasmic ratios, coarse chromatin, prominent nucleoli, and high mitotic activity.

The clinical and radiographic features of these tumours are non-specific, and consequently an accurate diagnosis requires histologic evaluation. Histologically and immunophenotypically, extracranial meningiomas are the same as their intracranial counterparts. An awareness of these pathologic and immunohistochemical features should allow them to be distinguished from other sinonasal tract tumours. The clinical manifestations, radiographic findings, and histologic features cannot predict the clinical outcome

accurately, even though, with complete surgical extirpation, sinonasal tract meningiomas have a good overall prognosis²³.

During the last 5 years, the authors have observed three cases of extracranial meningiomas. They discuss the salient features of these lesions, which can aid the preoperative diagnosis and management of these patients.

Case reports

Case 1

A 75-year-old female patient presented with progressive swelling over the right side of the outer head and temporal region. It was associated with local pain and progressive proptosis. She denied vertigo, imbalance or tinnitus. Her medical history was unremarkable. On examination, she had a 6 cm, firm, nontender, noncompressible swelling on the right temporal

region, fixed to the underlying bone. The skin over the swelling was normal and the underlying mass could be pinched off (Fig. 1). There were no other neurological symptoms or deficits. Neurologic examination, including evaluation of the cranial nerves, and head and neck examination were normal. Computed tomography (CT), before and after contrast administration, showed a large enhancing extracranial lesion located into the infra-temporal fossa; the underlying bone was irregular and soft in places and it was infiltrated by the tumour (Fig. 2).

An emicoronal skin incision was made on the right side (Fig. 3a) and dissection revealed the tumour (Fig. 3b). The temporalis muscle was extensively infiltrated by the neof ormation, so it was completely removed. The lesion was removed (Fig. 3c). It was also necessary to remove part of the temporal bone, which was partially destroyed by the tumour. This extremely rare presentation revealed a totally extracranial meningioma the pressure of which eroded the bone. Skull bone reconstruction was performed using polymeric materials (Acrylic) and fixed using titanium plates and screws. 3 weeks later, the Acrylic matter was removed due to an infection.

A good postoperative outcome was achieved. No new symptoms developed 1 year after surgery. The patient is still undergoing 6-month follow-up. Histopathology of the tumour tissue showed meningothelial meningioma (Fig. 3d) with whorled aspects and psammoma bodies, occasional mitotic figures, no nuclear pleomorphism or necrosis. Histopathological examination of the tumour revealed a meningioma with several intracellular pseudolumina with round eosinophilic periodic acid Schiff (PAS), epithelial membrane antigen (EMA) and carcinoembryonic antigen (CEA) positive

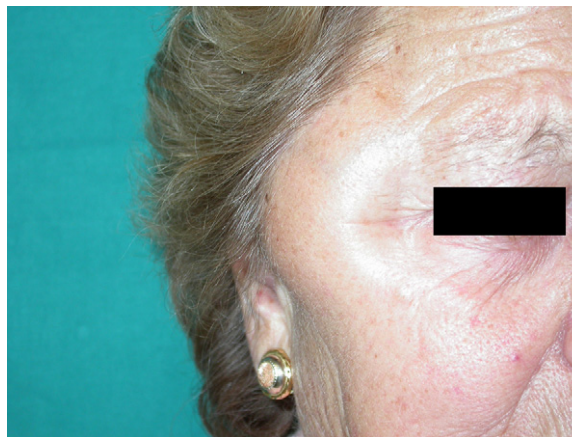

Fig. 1. Case 1. A 75-year-old female patient presented with swelling over the right side of the outer head and temporal region.

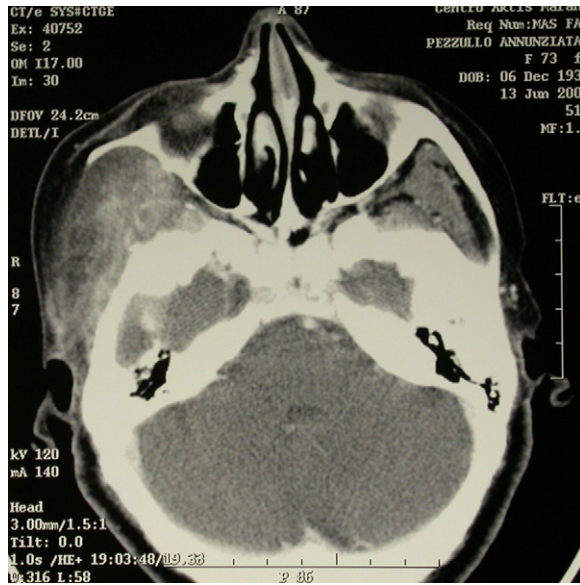

Fig. 2. Case 1. Axial CT with contrast showing a large enhancing extracranial lesion located into the temporal and infratemporal fossa; the underlying bone is irregular and soft in places and infiltrated by the tumour.

bodies, so-called pseudopsammomabodies. The tumour was a primary extracranial meningioma without any intracranial connexion.

Case 2

A 65-year-old female patient presented with new-onset headaches, facial sensory disturbance (second division of the trigeminal nerve), and airflow reduction

through the left nostril. She complained of left hypoacusia and visual reduction of the left eye. The visual field showed a deficit in the left lower quadrant and ultrasound of the orbit showed retrobulbar optic neuritis. Magnetic resonance imaging showed abnormal enhancement and widening of the left pterygopalatine fossa and sphenoidal sinus and omolateral cavernous sinus. A lesion extended into the middle cranial fossa (Fig. 4a). The

patient was subjected to surgical partial removal of the lesion through a left fronto-temporal approach.

The tumour was forcibly removed in part, because of the extent of the lesion within the cavernous sinus and sphenoidal sinus and the involvement of the internal carotid artery (Fig. 4b). A second operation was performed 3 weeks later because of the tumour extension within the pterygopalatine fossa (Fig. 4c).

A zig-zag shaped skin incision from the inferior lip to the chin to the ipsilateral mastoid was used (Fig. 5a). The oral floor was also dissected and the facial artery and vein were exposed. The authors made a para-median osteotomy of the jaw on the left side, the soft tissues were dissected until, in the lateral pharyngeal space and in the pterygopalatine fossa, a large, red-brown, hard, elastic neoplasia was found (Fig. 5b and c). It was not possible to remove the lesion en block, because it was strongly fixed to the cranial base, penetrating the cavernous sinus and it involved the internal carotid artery, so a piecemeal removal was performed. Osteosynthesis of the jaw was carried out using titanium plates and screws. Histopathology of the tumour tissue showed cellular pleomorphism, nuclear atypia, macronucleoli, small cell formation, sheeting, atypical mitoses, and necrosis. Histopathological examination of the tumour revealed an atypical meningioma (WHO grade II) (Fig. 5d). Radiotherapy was performed and at the 3-year follow-up the patient had no neurological symptoms (Fig. 6). In this case the extracranial location was a secondary extension of the intracranial meningioma.

Case 3

In 1999, a 62-year-old male patient presented with motor and nomenclature aphasia, left hypoacusia and tinnitus, pierced-type headache, reduction of vision in both eyes and hypostenia of the legs, which led to difficulties in ambulation particularly with the right leg. He underwent CT and MRI of the brain. MRI revealed a tumour mass of 3.5 cm, enhanced after contrast medium in correspondence with the left temporal pole. The lesion was excised using a left fronto-temporal approach (Fig. 7a and b). The lesion appeared largely calcified and presented features of meningioma. The histopathological findings suggested a fibroblastic meningioma. In the postoperative period, the motor aphasia and the deficit of the right leg decreased, but the nomenclature aphasia persisted. 6 years later, in 2005, a neurological examination revealed a persistence of aphasia nomenclature and left

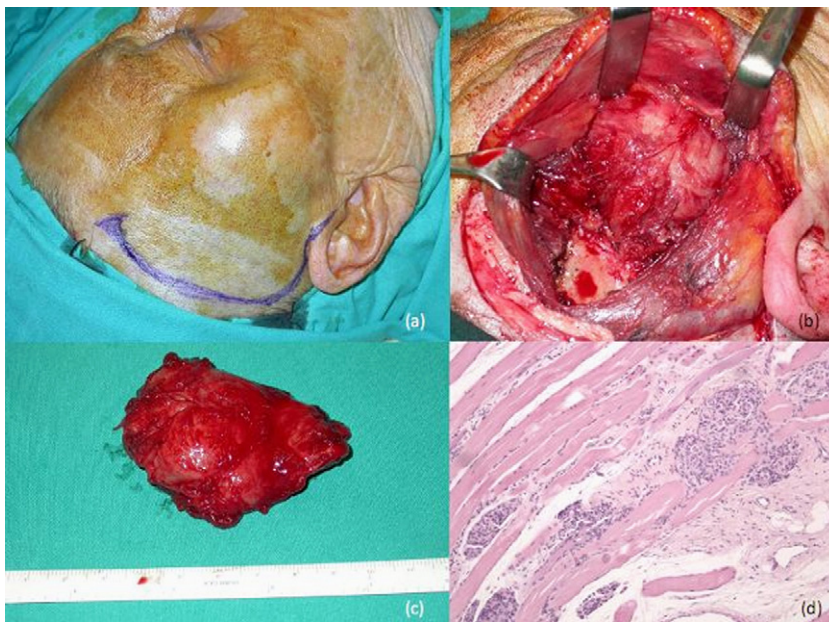


Fig. 3. Case 1. (a) The skin marked to show the line of the skin incision on the right side; (b) intraoperative view of the lesion exposed; (c) the lesion removed; (d) histological section (Hematoxylin and Eosin 10x) of the transitional meningioma infiltrating soft and muscular tissues.

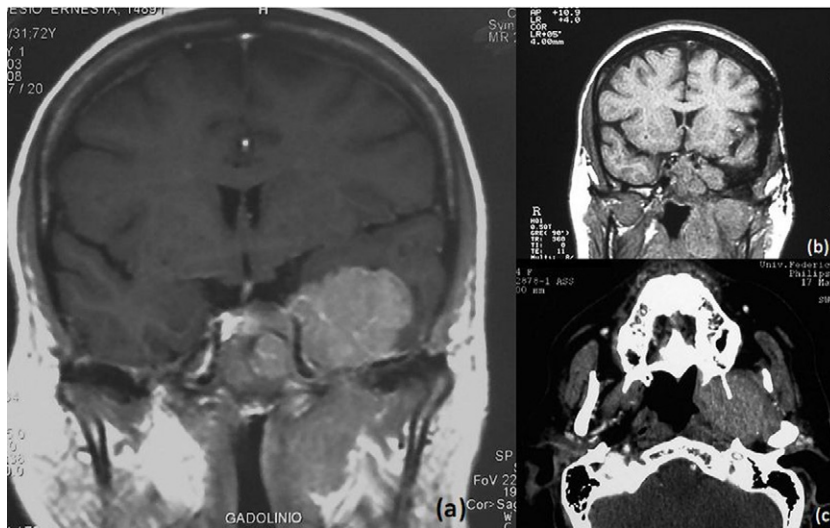


Fig. 4. Case 2. (a) MRI, T1-weighted, in coronal view after contrast administration showing the tumour mass in the left middle fossa, cavernous sinus and pterygopalatine fossa; the carotid artery is surrounded by the tumour; (b) MRI, T1-weighted, showing the removal of the intracranial lesion by a fronto-temporal approach; (c) axial CT showing the lesion located within the pterygopalatine fossa.

hypoacusia, and an MRI of the brain showed a recurrence of the lesion confirming the presence, on the left side, of a temporo-polar neoformation, about 2.5 cm in size. The patient underwent craniotomy and the tumour mass was removed. A fronto-temporal approach was used on the left side. As in the previous surgery, the lesion was moderately vascularized and infiltrated the dura mater of the great

sphenoid wing and the temporal fossa. The neoformation appeared roundish, grey-yellow and soft in consistency. It was removed step by step, using bipolar pliers. Where the floor of the middle fossa was eroded, the dura mater seemed infiltrated: so it was removed and replaced by a pericardial patch. Histopathological examination of the tumour revealed a typical transitional meningioma. Postoperatively the aphasia

nominum regressed, but the hypoacusia persisted. After a period of good health, in 2006 a follow-up contrast enhanced CT scan of the brain showed a neoformation in the upper portion of the nasal fossa, the pterygo maxillary fossa and the sphenoidal sinus (Fig. 7c). The bone was eroded. A different approach was necessary and a mandibular osteotomy was performed to expose the lesion in the pterygo maxillary fossa (Fig. 8). Using an endoscopic approach in the nasal cavity, a turbinectomy and removal of the neoformation, located between the middle turbinate and the nasal septum, was performed. The jaw was fixed using titanium plates and screws. Histopathological examination of the tumour revealed a rhabdoid meningioma and some areas of necrosis (WHO grade II) (Fig. 9). Radiotherapy was performed (Fig. 10). This case was a secondary extracranial extension of an intracranial meningioma.

Discussion

Meningiomas are benign tumours derived from the arachnoid villous structures of the meninges and are common in the central nervous system²³. Extracranial meningiomas are very rare in comparison to axial lesions, and the incidence of extracranial-extra-axial meningiomas ranges from 1% to 2% of all meningiomas. They have been reported sporadically. HOYE et al.¹⁶ sub-classified extracranial meningiomas on the basis of the major aetiologies proposed concerning their development, and the most common variety of extracranial meningioma, is that which arises from intracranial dura and extends extracranially⁸. About 40% of these, develop from the sphenoidal region into the orbit with associated hyperostosis of bone and with proptosis and progressive visual impairment. The literature indicates that extracranial meningiomas show a slight female predominance, 1:1.2, approximately 55%, and males have a worse prognosis. The average age at presentation for the authors' patients (67.3 years) was not in line with those reported in the literature (43.4 years). There is a statistically significant difference in the age at presentation for the female patients in the present series, who were on average (70.0 years), older than their male counterparts (62.0 years), comparing the average age of the females (48.7 years) and males (36.9 years) reported in the literature. Extracranial meningiomas have been observed to be benign and slow growing.

This diagnosis is rarely considered before surgical removal and histopathological examination, because of its rarity, and

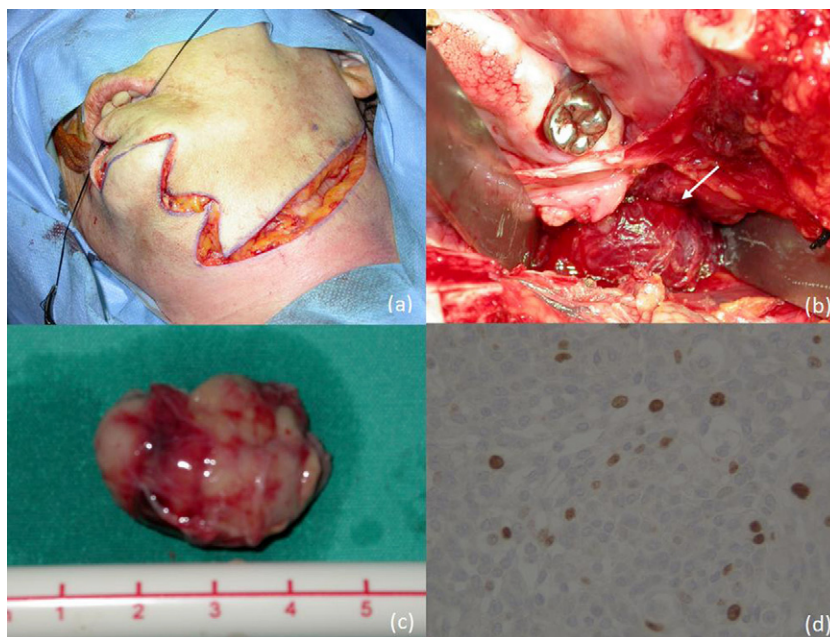

Fig. 5. Case 2. (a) The zig-zag shaped skin incision to perform the transmandibular approach; (b) exposure of the tumour mass within the pterygopalatine fossa (arrow); (c) the lesion removed; (d) histological section, immunostaining Ki-67 antigen/Monoclonal mouse antibody (MIB-1) (40 \times), showing high cellular proliferative index.

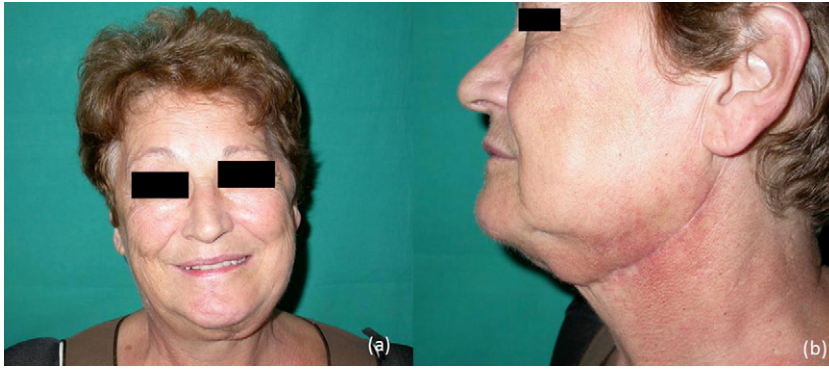

Fig. 6. Case 2. The patient in frontal (a) and lateral (b) view 2 months after surgery. The scar is cosmetically acceptable and there is no facial nerve deficiency.

the absence of clear radiological findings in favour of a meningioma, specially regarding the primary truly extracranial lesions, lacking any detectable intracranial mass or dural attachment and their often non-specific clinical findings compared to the other more common tumours of the soft tissues. The patient has to be carefully observed and the shape of the lesion, the swelling, the pain with or without compression, and the underlying tissue fixation have to be examined. The skin over the swelling is evaluated and the underlying mass is pinched off. Neurological symptoms have to be estimated, including evaluation of the cranial nerves and head and neck examination. When there is involvement of the orbit, it is necessary to estimate visual acuity, whilst involvement of

the ear is analysed by audiometry. In general, the most common symptoms are headache, vertigo, and seizures. The differential diagnosis of otological symptoms caused by middle ear tumours includes cholesteatoma, adenoma, paraganglioma, adenocarcinoma, lymphoma or metastatic carcinoma.

The role of CT with contrast medium is very significant and reveals the relationship between the tumour and the bony surfaces, the temporal bone, sphenoid ridge, and lateral wall of the orbit, and the possibility of a malignant tumour involving the temporalis muscle and/or bone. MRI allows a study of the vascularization, infiltration, extension, limits and relationships with the brain parenchyma and surrounding structures.

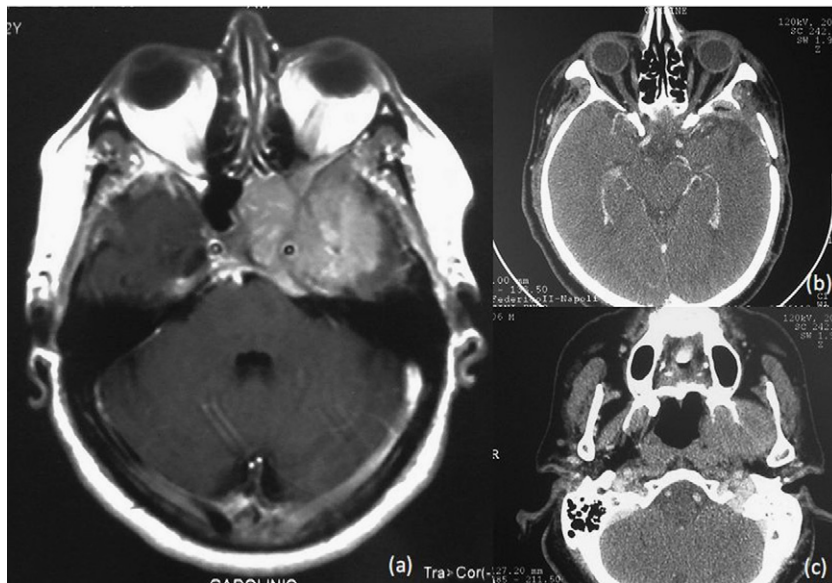


Fig. 7. Case 3. (a) MRI, T1-weighted, axial view showing the tumour mass within the left middle fossa displacing the temporal lobe, the carotid artery is encased by the tumour (arrow); (b) MRI, T1-weighted, in axial view, showing the removal of the tumour through a left fronto-temporal approach; (c) axial CT showing the tumour mass extending within the left pterygo-palatine fossa.

Surgical excision is the gold standard of treatment and must be planned by radiologic studies to determine the extent of the tumour and the presence or absence of a companion central nervous system meningioma. This includes removal of thickened bone and resection of the dura involved along with the tumor⁶. Adequate exposure of the tumour and involved bone can be achieved using a generous scalp incision. Usually, the thickened calvarium is hard but slightly softer than the normal bone and can be removed easily. If possible, this has to be accompanied by removal of an adequate margin of normal bone. A dural defect can be closed using pericranium harvested from the adjoining region or, alternatively, a vascularized pedicle pericranial flap can be used¹⁹. At surgery, the skin can be separated from the temporalis fascia easily. A firm, fleshy, highly vascular tumour infiltrating the temporalis muscle and densely adherent to the underlying bone is identified and detached all around, along with muscle from the underlying bone, and to gain access to the infratemporal part of the tumour, lateral orbitozygomatic osteotomy is performed. Bony defects can be closed by artificial graft material (polydioxanon sheet) or with vascularized pedicle pericranial flaps based on temporalis muscle and its fascial layer. If the frontal sinuses are involved, they should be excluded from the cranial cavity by cranialization. Although there are occasional reports of complete remission after radiation therapy, surgical resection is the treatment of choice. The different benign and malignant lesions arising in this region include rhabdomyosarcoma, hemangiopericytoma, chondroblastoma, hyperparathyroidism, and fibrous dysplasia. The pathologic features of extracranial meningiomas are identical to those of more frequent intracranial lesions. Preoperative suspicion of a meningioma in these patients would have resulted in a more aggressive surgical approach. Recurrence of intracranial meningiomas occurs usually in the primary site and less commonly at the surgical scar, therefore the extent of surgical excision is probably the most important factor in determining outlook, in order to decrease recurrence. The surgical strategy for primary and secondary extracranial meningiomas is different. The first has to be treated as a common tumour of the soft tissues and the target is to attempt total removal. Secondary extracranial meningiomas are extensions of intracranial lesions, migrating through the foramina or eroding the bone of the skull, often involving vital neurovascular structures. After craniotomy and the removal of the intracranial portion,

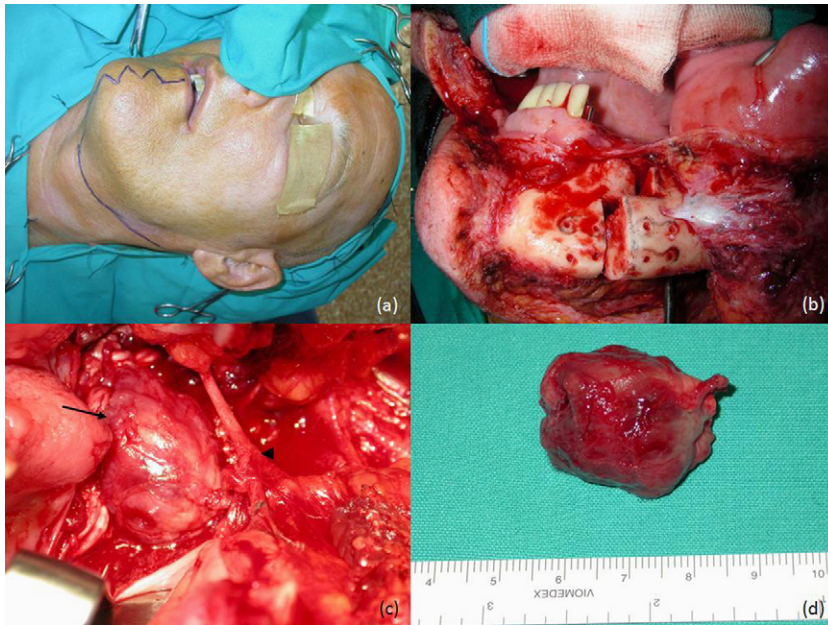


Fig. 8. Case 3. (a) The skin marked, showing the zig-zag shaped skin incision; (b) the mandible resected after the pre-plating has been performed; (c) exposure of the lesion within the left pterygopalatine fossa (arrow). Lingual nerve (arrowhead).

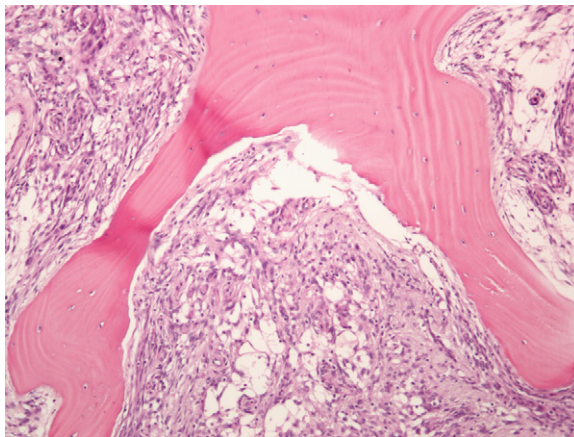


Fig. 9. Case 3. Histological section (*Hematoxylin and Eosin 10x*) showing meningiomatous tissue infiltrating bony lamellae.

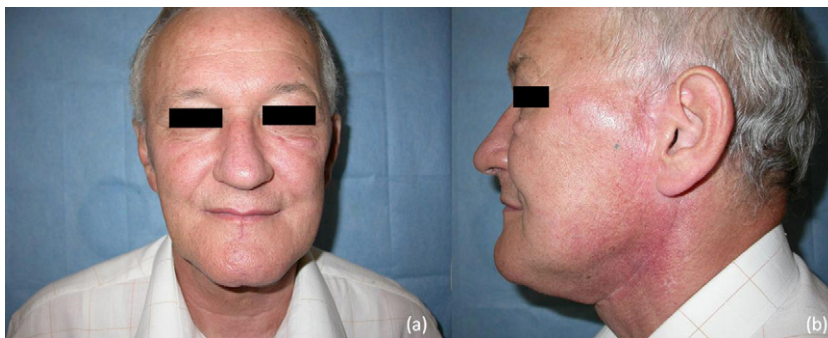

Fig. 10. Case 3. The patient in frontal (a) and lateral (b) views 2 months after surgery. The scar is not particularly evident and the left facial nerve function is preserved.

generally a transfacial approach has to be performed to extirpate the extracranial portion. The extent of surgery depends on the bone erosion due to the tumour, its size, and degree of infiltration into the surrounding structures.

Meningiomas with negative histopathological features, such as a high mitotic index and nuclear pleomorphism (anaplastic meningioma), have a higher probability of recurrence. It has been observed that, after using radiotherapy, the recurrence of intracranial meningiomas is uncommon. Radiotherapy treatment involves post-operative, three dimensional, conformal radiotherapy to partial brain using a 6 MV linear accelerator with four non-complanar fields with a dose of 60 Gy in 30 fractions in 6 weeks. In patients who have never been subjected to radiation, post-operative radiotherapy after recurrence in a meningioma can improve control rates²¹. Patients who have not received radiotherapy earlier can subsequently receive post-operative radiotherapy.

The optimal management and the overall prognosis of such recurrences, because of their rarity, are unknown. For intracranial meningiomas, radiotherapy is frequently recommended as a safe and reliable adjunctive treatment for partially resected meningiomas. When total resection of benign meningioma is not feasible, subtotal resection combined with precise treatment planning techniques and adjuvant radiation therapy can achieve results comparable to those of total resection. Increased progression-free survival in the benign tumour group was also significantly associated with increasing the minimum radiation dose ($p = 0.04$)¹². Studies in the literature provide convincing evidence that radiation therapy is beneficial in the treatment of partially resected meningiomas. The role of radiotherapy for primary extracranial meningiomas has not been established.

In the literature, the recurrence rate for meningiomas after total excision varies from 7% to 84%, depending on the histology and extent of surgery. The authors' surgery has been very aggressive because the tumour infiltrated nearby structures. In one of the present cases the authors used a polymeric material for reconstruction, and in this case the patient was reoperated on because an infection occurred.

Slowly progressive lesions in the temporal region, presenting dural involvement and contrast enhancement on CT, with extensive hyperostosis, suggest a relatively benign lesion (meningioma). These features could lead to more aggressive resection and a reconstruction of bone defects.

The origin of primary extracranial meningiomas remains controversial, although several theories have been proposed. These include extradural trapping of arachnoid cells during embryogenesis, ectopic migration of the arachnoid cell nests with the developing peripheral nerves, and metaplasia of the mature peripheral nerve sheath cells or progenitor cells. HOYE et al.¹⁶ subclassified extracranial meningiomas on the basis of the major aetiologies proposed in the development of extracranial meningiomas, and the most common variety of extracranial meningiomas is that which arises from intracranial dura and extends extracranially⁹. There are a number of different mechanisms to suggest how extracranial meningiomas arise and develop^{8,9,15}, including: arachnoidal cells are evident in the sheaths of the nerves and vessels where they emerge through the skull foramina; displaced pacchionian bodies become detached, pinched off, or entrapped during embryologic development in an extracranial location; an origin from undifferentiated or multipotential mesenchymal cells, such as fibroblasts, Schwann cells, or a combination of these, perhaps explaining the diverse pathologic spectrum found in meningiomas; traumatic events or cerebral hypertension that displace arachnoid islets.

By one or more of these mechanisms, arachnoid cells are identified outside the neuraxis and give rise to extracranial meningiomas. Clinicopathologically, they are usually categorized in four groups, based on the suggested aetiologies proposed for the development of extracranial meningiomas: direct extension of a primary intracranial meningioma through pressure necrosis/absorption of the bone, or through an iatrogenic or natural opening (including the cribriform plate); extracranial metastasis from an intracranial meningioma; extracranial meningioma originating from arachnoid cell clusters in the sheaths of the cranial nerves (or vessels) as they exit through the foramina or suture lines of the skull, including the cribriform plate; extracranial meningioma without any apparent demonstrable connexion with foramina, cranial nerves, or cranial primaries.

Up to 20% of intracranial meningiomas may have extracranial/extraspinal extension⁸, including the orbit, middle ear, soft tissues, and skin of the head and neck, and upper airway involvement (nasal cavity, para-nasal sinuses, nasopharynx). Most of the reported cases involving the upper airway represent secondary extension from an intracranial lesion^{8,10,11,13,17}. Extracranial meningiomas arising from the sinonasal

tract or temporal muscle with no evidence of an association with an intracranial tumour (also called heterotopic, ectopic, or extracalvarial) are rare^{2,3,9,10,13,15,22}, and most of the reported cases were described before modern radiographic imaging techniques were available to exclude intracranial tumours. There is a growing consensus that primary extracranial meningiomas are truly extracranial, lacking any detectable intracranial mass or 'dural enhancement' by radiologic techniques.

In summary, the clinical and radiographic features of these uncommon lesions are nonspecific, hence, a precise diagnosis requires histologic evaluation. The prognosis, after complete surgical extirpation, is generally good with disease-free survival rates of 82% and 78% at 5 and 10 years, respectively²³.

Competing interests

None declared.

Funding

None.

Ethical approval

Not required.

References

1. Agrawal A, Rao KS, Makannavar JH, Shetty L, Patel N. Extracranial meningioma in the vicinity of the temporal bone: a difficult preoperative diagnosis. *Surg Neurol* 2007; **67**:102–5.
2. Atherino CCT, Garcia R, Lopes LJ. Ectopic meningioma of the nose and paranasal sinuses (report of a case). *J Laryngol Otol* 1985; **99**:1161–6.
3. Bagchi AK, Sen GK. Primary nasal meningioma. *J Indian Med Assoc* 1969; **53**:286–8.
4. De SK, Chatterjee AK, Misra AK. An unusual presentation of meningioma of the frontal sinus. *J Laryngol Otol* 1986; **100**:711–4.
5. Ereño C, Izquierdo AP, Basurko JM, Bilbao FJ, López JJ. Temporal bone secretory meningioma presenting as a middle ear mass. *Pathol Res Pract* 2006; **202**:408–14.
6. Eshete M, Schneider J. Extracranial meningioma of the scalp: case report. *Ethiop Med J* 2005; **43**:119–22.
7. Fagerlund M, Stenling R, Soderberg O. A subfrontal meningioma with primary origin from the nasal cavity. *Acta Otolaryngol Stockh* 1983; **95**:365–70.
8. Farr HW, Gray GF, Vrana M, Panio M. Extracranial meningioma. *J Surg Oncol* 1973; **5**:411–20.
9. Friedman CD, Costantino PD, Teitelbaum B, Berkold RE, Sisson Sr GA. Primary extracranial meningiomas of the head and neck. *Laryngoscope* 1990; **100**:41–8.
10. Fujitsu K, Saijoh M, Aoki F, Sakata K, Fujii S, Mochimatsu Y, Kuwabara T. Telecanthal approach for meningiomas in the ethmoid and sphenoid sinuses. *Neurosurgery* 1991; **28**:714–9.
11. Geoffroy A, Lee YY, Jing BS, Wallace S. Extracranial meningiomas of the head and neck. *AJNR* 1984; **5**:599–604.
12. Goldsmith BJ, Wara WM, Wilson CB, Larson DA. Postoperative irradiation for subtotally resected meningiomas. *J Neurosurg* 1994; **80**:195–201.
13. Granich MS, Pilch BZ, Goodman ML. Meningiomas presenting in the paranasal sinuses and temporal bone. *Head Neck Surg* 1983; **5**:319–28.
14. Hill CL. Meningioma of the maxillary sinus. *Arch Otolaryngol* 1962; **76**:547–9.
15. Ho KL. Primary meningioma of the nasal cavity and paranasal sinuses. *Cancer* 1980; **46**:1442–7.
16. Hoye SJ, Hoar CS, Murray JE. Extracranial meningioma presenting as a tumor of the neck. *Am J Surg* 1960; **100**:486–9.
17. McCullough JB, Evans AT, Vaughan-Jones R, Hussein KA. Fine needle aspiration (FNA) of a nasal meningioma: a case report. *Cytopathology* 1996; **7**:56–60.
18. Munshi A, Dutta D, Muzumdar D, Jalali R. An atypical presentation of recurrent temporal lobe meningioma with external auditory canal mass. *Indian J Cancer* 2007; **44**:119–21.
19. Nadkarni T, Desai K, Goel A. Giant meningioma of the cranial vertex. *Neurol Med Chir* 2002; **42**:128–31.
20. Nager GT, Heroy J, Hoeplinger M. Meningioma invading the temporal bone with extension of the neck. *Am J Otolaryngol* 1983; **4**:297–324.
21. Platt M. A case of extradural meningioma treated successfully with high energy electron. *J Radiol Electrol* 1974; **155**:519–21.
22. Taxy JB. Meningioma of the paranasal sinuses. A report of two cases. *Am J Surg Pathol* 1990; **14**:82–6.
23. Thompson LD, Gyure KA. Extracranial sinonasal tract meningiomas: a clinicopathologic study of 30 cases with a review of the literature. *Am J Surg Pathol* 2000; **24**:640–50.

Address:

Marco Friscia
Department of Oral and Maxillo Facial
Surgery
University of Naples 'Federico II'
Via Pansini 5
Napoli 80100
Italy
Tel: +39 0817462075
E-mail: marcofriscia@yahoo.it