



## Case report

# CD34<sup>+</sup>-enriched donor lymphocyte infusions in a case of pure red cell aplasia and late graft failure after major ABO-incompatible bone marrow transplantation

C Selleri, A Raiola, G De Rosa, L Luciano, L Pezzullo, M Picardi and B Rotoli

Division of Hematology, Federico II University Medical School, Naples, Italy

### Summary:

**A variety of immunohematological complications may occur after ABO-incompatible BMT. We report a CML patient (blood group O) who received a BMT from an HLA-identical sibling (blood group AB). The transplant was followed by normal myeloid and megakaryocytic engraftment, but erythroblastopenia persisted for more than 200 days after BMT. By bone marrow culture studies, a complement-dependent serum inhibitor of hemopoiesis was detected, suggesting immunological inhibition of erythropoiesis. The patient was resistant to a number of treatments such as intravenous gamma-globulins, prednisolone and high-dose erythropoietin. Full engraftment with normal blood counts and marrow cellularity was achieved after two dose-escalating CD34<sup>+</sup>-enriched donor lymphocyte infusions (DLI). This experience suggests that CD34<sup>+</sup>-enriched DLI may be an effective treatment for patients with delayed engraftment or late graft failure due to major ABO-incompatibility.**

**Keywords:** PRCA; graft failure; DLI; CD34<sup>+</sup> cells

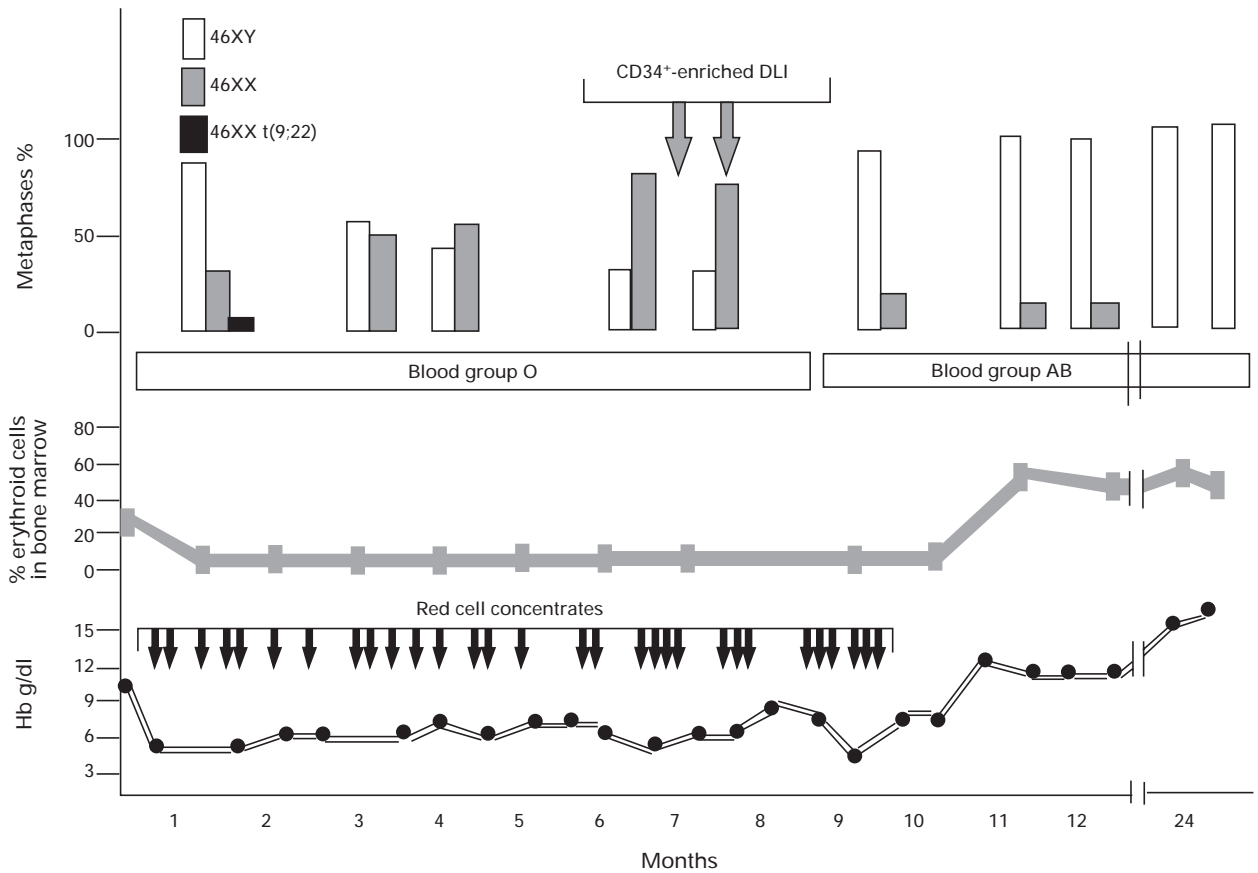
ABO-incompatible BMT is a difficult task; various immunosuppressive regimens, erythropoietin and plasmapheresis have been used with variable results.<sup>2</sup> Immune-mediated mechanisms may also play a key role in the development of late graft failure.<sup>5</sup> Graft rescue by infusing peripheral blood stem cells (PBSC) may be an effective therapy for patients with early or late graft failure,<sup>6</sup> whereas donor lymphocyte infusions (DLI) have been primarily used for treating or preventing cytogenetic or early hematological CML relapse.<sup>7</sup>

We report a case of PRCA followed by a progressive graft failure complicating an ABO-incompatible allogeneic BMT for CML in chronic phase, that was successfully treated with CD34<sup>+</sup>-enriched DLI.

### Case report

A 20-year-old woman underwent BMT from her HLA-identical brother 6 months after the diagnosis of CML in chronic phase. We used the conditioning regimen BU/CY2; GVHD prophylaxis was carried out with CYA (2 mg/kg) and short-course methotrexate. As the donor's blood group was AB (Rh: CcDee; Kell positive) and the recipient's was O (Rh: CCDee; Kell negative), erythrocyte-depleted marrow containing  $3.8 \times 10^6/\text{kg}$  CD34<sup>+</sup> cells and  $2.54 \times 10^4/\text{kg}$  CFU-GM was transplanted. Engraftment of neutrophils and platelets was observed on days +23 and +25, respectively. On day +30 laboratory findings were as follows: Hb 9.6 g/dl; leukocytes  $2.4 \times 10^9/\text{l}$  with 66% neutrophils, 30% lymphocytes, 4% monocytes; platelets  $39 \times 10^9/\text{l}$ ; reticulocytes 0.1%; blood group O+. A bone marrow aspirate revealed normal myeloid and megakaryocyte differentiation with severe erythrocyte hypoplasia (2%), consistent with PRCA; a BM karyotype showed 81% 46 XY, 15% 46XX and 4% 46XX t(9;22) metaphases (Figure 1). Peripheral lymphocyte phenotyping showed normal CD4/CD8 ratio. *In vitro* colony assay performed in methylcellulose showed a marked decrease of erythroid burst-forming units (BFU-E) with normal growth of myeloid progenitors (Table 1). In a set of coculture experiments carried out after a 2 h incubation of normal marrow cells with the patient's lymphocytes or serum, the growth of normal BFU-E was clearly inhibited by the patient's fresh serum and not by heat inactivated serum (Table 1). There were no

Allogeneic bone marrow transplant with major ABO incompatibility may be associated with delayed erythroid engraftment that may either regress spontaneously or become chronic. Acquired pure red cell aplasia (PRCA) has been reported after major ABO-incompatible transplant from peripheral blood<sup>1</sup> or marrow,<sup>2</sup> unmanipulated or T cell-depleted progenitor cells. It is characterized by severe anemia, reticulocytopenia and absence of erythroblasts in otherwise normally engrafted bone marrow. Although human parvovirus B19 may be a causative agent of PRCA following BMT,<sup>3</sup> more frequently autoimmune or alloimmune mechanisms have a role in its pathogenesis.<sup>4</sup> A well-recognized mechanism of PRCA complicating major ABO-incompatible BMT involves antibodies towards red cell precursors;<sup>2</sup> a T cell-mediated suppression of erythropoiesis has also been described.<sup>2</sup> Management of PRCA after



**Figure 1** Hemoglobin, marrow erythropoiesis, blood group and karyotype modifications in the post-transplant period.

**Table 1** Effects of patient's lymphocytes and serum on colony formation from normal bone marrow cells before and after CD34<sup>+</sup>-enriched DLI

	<i>Before DLI</i>		<i>After DLI</i>	
	<i>BFU-E</i>	<i>CFU-GM</i>	<i>BFU-E</i>	<i>CFU-GM</i>
<i>Patient</i>	6 ± 5*	25 ± 5**	34 ± 4***	28 ± 1
Control + patient's lymphocytes	34 ± 6	44 ± 6	35 ± 6	39 ± 6
Control + patient's fresh serum	6 ± 4	20 ± 11	40 ± 7****	35 ± 4
Control + patient's heat inactivated serum	24 ± 3	36 ± 6	32 ± 8	37 ± 6
<i>Control</i>	30 ± 4	40 ± 5	36 ± 4	47 ± 5
Control + normal lymphocytes	32 ± 6	45 ± 1	41 ± 6	49 ± 4
Control + normal fresh AB serum	42 ± 10	45 ± 2	38 ± 8	45 ± 6
Control + normal heat inactivated AB serum	39 ± 4	49 ± 4	37 ± 5	40 ± 6

The values represent mean ± s.d. of colony number/2 × 10<sup>5</sup> monocyte-depleted bone marrow cells plated in methylcellulose in the presence of rEPO 3 U/ml, rGM-CSF 50 ng/ml, rIL3 50 ng/ml, rSCF 50 ng/ml. Coculture experiments were carried out after 2 h incubation of marrow cells from a group AB normal donor with patient's lymphocytes (10<sup>5</sup>/plate) or serum (100 μl/plate). Each experiment was performed in duplicate. Serum was heat inactivated at 56°C for 1 h. The mean colony number from bone marrow of 25 normal controls was 35.4 ± 16 erythroid and 30.7 ± 10 myeloid colonies. Statistical analysis (*t*-test): \**P* < 0.05 for comparison with control BFU-E; \*\*\**P* < 0.05 for comparison with patient's BFU-E before treatment; \*\**P* < 0.05 for comparison with control CFU-GM; \*\*\*\**P* < 0.05 for comparison with control BFU-E with patient's fresh serum before treatment.

signs of hemorrhage, hemolysis or acute GVHD. During the following 5 months, the patient was supported with about five group O red cell concentrates per month, and showed progressive reduction of allogeneic hemopoiesis (Figure 1). In this period no circulating group AB red cells were detectable, the Coomb's test was persistently negative, marrow examinations confirmed PRCA and no GVHD fea-

tures were observed. Likewise, serial analyses of the patient's serum and marrow cells for B19 parvovirus DNA by nested-polymerase chain reaction showed no sign of infection; even cytomegalovirus infection was excluded by weekly checking CMV antigenemia. The patient was unresponsive to several therapeutic attempts: a 5-day course of intravenous immunoglobulins (0.4 g/kg/day); danazol (600

mg/day for 2 months); bolus methylprednisolone (5 mg/kg/day for 5 days) followed by 1 month administration of oral prednisone (1.5 mg/kg/day); 8 week administration of subcutaneous erythropoietin (150 U/kg/day 3 days a week) and a 5-day course of high-dose subcutaneous erythropoietin (30 MU/day). Six months after BMT, the karyotype showed a further decrease of allogeneic hemopoiesis (Figure 1) and CYA was discontinued. Anti-A and anti-B isohemagglutinin titers, that were 1:1024 and 1:256, respectively before transplant, still were 1:256 and 1:8 on day +180. On day +195, G-CSF-mobilized (243  $\mu$ g/day for 5 days) donor mononuclear cells containing  $0.4 \times 10^8$ /kg CD3<sup>+</sup> cells,  $0.9 \times 10^6$ /kg CD34<sup>+</sup> cells and  $1.8 \times 10^4$ /kg CFU-GM were infused without GVHD prophylaxis. Tolerance was excellent. Four weeks later, the patient received an additional CD34<sup>+</sup> enriched DLI containing  $1 \times 10^8$ /kg CD3<sup>+</sup> cells,  $1.53 \times 10^6$ /kg CD34<sup>+</sup> cells and  $3.8 \times 10^4$ /kg CFU-GM. Within 2 months of this treatment, Hb level, reticulocyte count and marrow erythropoiesis markedly improved (12.2 g/dl,  $2.1 \times 10^{12}/l$  and 50%, respectively), with normalization of BFU-E growth at marrow culture; at this time, there was no evidence of growth inhibition of normal erythroid precursors by the patient's serum (Table 1). A conversion of blood group from O to AB and a progressive increase of allogeneic hemopoiesis up to 100% of mitoses were documented within 4 months (Figure 1), together with signs of skin and mucosal chronic GVHD. Twelve months after DLI the patient is in complete hematological remission with negative RT-PCR for *bcr-abl*; a limited cutaneous chronic GVHD is successfully controlled by low-dose azathioprine. Anti-A and anti-B titers are now 1:4 and 1:2, respectively.

## Discussion

Pure red cell aplasia following ABO-incompatible BMT is attributed to an immune-mediated pathogenesis, by which antibodies and/or cytotoxic lymphocytes may inhibit erythroid progenitor cell proliferation.<sup>2</sup> In our patient, *in vitro* studies revealed that the patient's fresh serum inhibited normal marrow erythroid colony formation, suggesting a complement-dependent inhibition of erythroid progenitor cells. In addition, cytogenetic data documented a progressive graft failure. G-CSF-mobilized allogeneic PBSC have been found to be an effective and safe treatment for patients with primary or late graft failure after BMT for hematological diseases.<sup>6</sup> Donor lymphocyte infusions provide effective treatment for patients with CML (and for a minority of patients with acute myeloid leukemia and myelodysplastic syndrome) in early relapse after BMT; however, DLI may be associated with severe or even lethal myelosuppression or GVHD.<sup>7</sup> It has been suggested that DLI may eliminate or inactivate host-specific lymphocytes, thus enhancing the engraftment through residual host T cell killing or through a 'veto' activity;<sup>8,9</sup> the same mechanisms may mediate induction and maintenance of donor-specific graft by CD34<sup>+</sup> cells.<sup>10</sup> Experimental studies in animal models have also shown that G-CSF may modulate donor T cell function by polarizing them towards type-2 cytokine production, thus reducing the severity of acute GVHD.<sup>11</sup>

Based on the above considerations, we reasoned that in our patient an appropriate treatment could be a combination of DLI (immunomodulation and veto activity) with boosts of donor CD34<sup>+</sup> cells (to potentiate allogeneic hemopoiesis). Such a combined treatment can be obtained by using CD34<sup>+</sup>-enriched DLI. This is a feasible therapy for patients with incomplete hematological reconstitution, who are unresponsive to other treatments and thus at risk of graft rejection. Further studies are needed to verify whether G-CSF mobilization may reduce DLI-related complications even in other settings.

## Acknowledgements

We wish to thank Dr A Azzi (Microbiology Department, University of Pisa, Italy) who performed PCR for parvovirus detection and Dr F Giglio (Immunohematology Service, Federico II University Medical School, Naples) for immunohematological studies. This work was supported in part by 'Associazione Italiana per la Ricerca sul Cancro' (AIRC), and 'Associazione Italiana Leucemie (AIL) - Trenta Ore per la Vita'.

## References

- 1 Martelli M, Ponchio L, Beguin Y *et al*. Pure red cell aplasia following peripheral stem cell transplantation: complete response to a short course of high-dose recombinant human erythropoietin. *Haematologica* 1994; **79**: 456–459.
- 2 Santamaria A, Sureda A, Martino R *et al*. Successful treatment of pure red cell aplasia after major ABO-incompatible T cell-depleted bone marrow transplantation with erythropoietin. *Bone Marrow Transplant* 1997; **20**: 1105–1107.
- 3 Niitsu H, Takatsu H, Miura I *et al*. Pure red cell aplasia induced by B19 parvovirus during allogeneic bone marrow transplantation. *Rinsho Ketsueki* 1990; **31**: 1566–1571.
- 4 Klumpp TR. Immunohematologic complications of bone marrow transplantation. *Bone Marrow Transplant* 1991; **8**: 159–170.
- 5 Hows JM. Mechanisms of graft failure after human marrow transplantation: a review. *Immunol Lett* 1991; **29**: 77–80.
- 6 Arseniev L, Tischler HJ, Battmer K *et al*. Treatment of poor marrow graft function with allogeneic CD34<sup>+</sup> cells immunoselected from G-CSF-mobilized peripheral blood progenitor cells of the marrow donor. *Bone Marrow Transplant* 1994; **14**: 791–797.
- 7 Van Rhee F, Kolb HJ. Donor leukocyte transfusions for leukemic relapse. *Curr Opin Hematol* 1995; **2**: 423–435.
- 8 Lagoo-Deenadayalan S, Lagoo AS, Lemons JA *et al*. Donor specific bone marrow cells suppress lymphocyte reactivity to donor antigens and differentially modulate TH1 and TH2 cytokine gene expression in the responder cell population. *Transpl Immunol* 1995; **3**: 124–134.
- 9 Martin PJ. Prevention of allogeneic marrow graft rejection by donor T cells that do not recognize recipient alloantigens: potential role of a veto mechanism. *Blood* 1996; **88**: 962–969.
- 10 Aversa F, Martelli MM, Reisner Y. Use of stem cells from mismatched related donors. *Curr Opin Hematol* 1997; **4**: 419–422.
- 11 Pan L, Delmonte J Jr, Jalonen CK, Ferrara JL. Pretreatment of donor mice with granulocyte colony-stimulating factor polarizes donor T lymphocytes toward type-2 cytokine production and reduces severity of experimental graft-versus-host disease. *Blood* 1995; **86**: 4422–4429.