

Caso  
clinico

Case  
report

# Tuberculosis of the tongue in a patient with rheumatoid arthritis treated with methotrexate and adalimumab

***Tubercolosi della lingua in un paziente affetto da  
artrite reumatoide trattato con metotrexate  
e adalimumab***

Luca Rosario Assante<sup>1</sup>, Enrica Barra<sup>2</sup>, Marialuisa Bocchino<sup>1</sup>,  
Giacomo Zuccarini<sup>1</sup>, Gerardo Ferrara<sup>3</sup>, Alessandro Sanduzzi<sup>1</sup>

<sup>1</sup>Section of Respiratory Diseases, Department of Surgery and Clinical Medicine,  
University "Federico II", Naples, Italy;

<sup>2</sup>Unit of Pathology, AORN Ospedali dei Colli, Naples, Italy;

<sup>3</sup>Unit of Pathology, AO G. Rummo, Benevento, Italy

## INTRODUCTION

According to the World Health Organization (WHO) tuberculosis (TB) remains a major health problem with one third of the world population infected and 8,6 million new cases in 2012 [1]. Oral tuberculosis is a rare entity that accounts for 0,1-5% of all TB infections. *Mycobacterium tuberculosis* can infect all parts of the mouth such as the gingiva, soft and hard palate, lips, maxilla, mandible and the tongue. The tongue is the most common site of oral TB.

Lesions commonly appear as a single, swollen non-healing ulcer that often resembles malignant neoplasms. Tuberculosis is rarely considered in differential diagnosis of oral ulcers and often diagnosis is made by pathological examination [2]. In recent years rheumatoid arthritis (RA) treatment takes advantage of biological drugs that inhibit Tumor Necrosis Factor alpha (TNF $\alpha$ ). TNF $\alpha$  inhibitors include monoclonal antibodies like infliximab (IFN) or adalimumab (ADA), and the soluble TNF receptor-Fc fusion

protein etanercept (ETA). This therapy is associated with an increased risk of active TB, especially due to latent tuberculosis (LTB) reactivation [3].

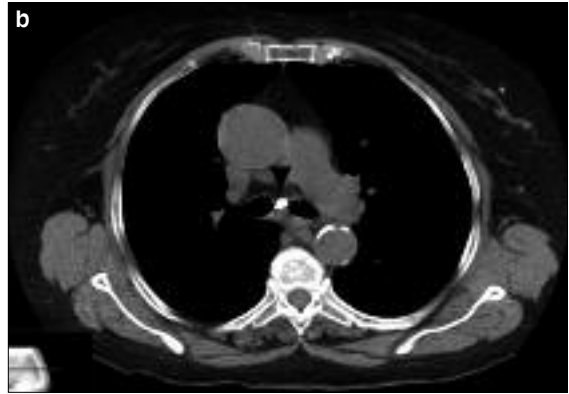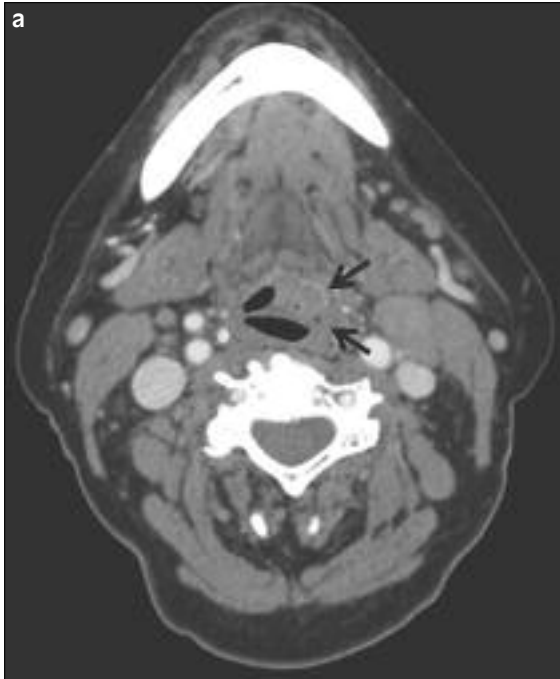
Risk of tuberculosis is higher for monoclonal antibodies than ETA [4]. Therefore, RA guidelines introduced TB screening by TST and, more recently, by in vitro Interferon- $\gamma$  release assays (IGRAs) before treatment with anti-TNF $\alpha$  agents to prevent LTB reactivation [5, 6]. We describe a case of a RA patient treated for long time with MTX and ADA suffering from a non-healing ulcer of the tongue.

## CASE PRESENTATION

A 71-year-old woman was admitted to our division in March 2011 with two months history of ulcerated, non-healing lesion of the tongue. The patient suffered from RA for 20 years and she was on ADA and MTX treatment for the last 6 years. Previously she was treated with prednisone, INF and ETA.

Pretreatment TST was reported to be negative and no IGRAs were performed. The patient had no history of BCG vaccination. She reported asthenia, pharyngodinia, dysphagia, low grade fever and night sweats in the last 3 months. On

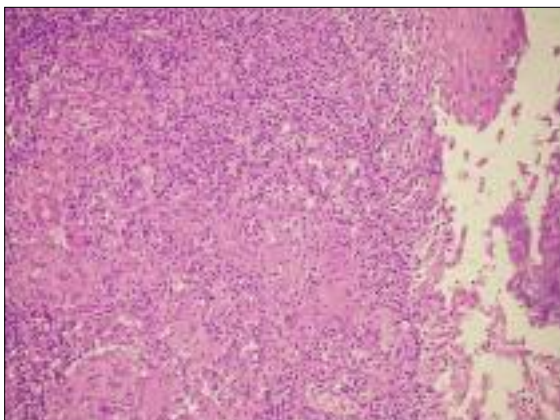
Corresponding author  
Alessandro Sanduzzi  
E-mail: sanduzzi@unina.it



**Figure 1 - a)** Neck CT show the infiltration of the hypopharynx wall with left pyriform sinus obliteration (black arrows); **b)** chest CT show subcarinal calcified lymph node (black arrowhead).

physical examination, the patient had an ulcerated swelling on the left border of the base of the tongue, cervical lymphadenopathy and ulnar deviation of metacarpophalangeal joints bilaterally.

Thoracic examination was normal. Cervical CT scan revealed a reduced lumen of the pharynx with an infiltrated left wall, left cervical lymphadenopathy and left pyriform sinus obliteration. Chest CT showed mediastinal calcified lymphadenopathies (Figure 1). An initial



**Figure 2 -** Biopsy specimen show granulomatous inflammation with epithelioid cells and giant cells that causes ulceration of the mucosa.

diagnosis of squamous cell carcinoma of the tongue was pointed out. Biopsy of the lesion showed chronic inflammatory changes, numerous epithelioid and Langhan's giant cells granulomata without malignant cells (Figure 2).

Routine blood tests revealed mild anemia (Hb 11,4 g/dl), normal white blood cells count, erythrocyte sedimentation rate 73 mm/hr, C-reactive protein 56 mg/L (reference <5 mg/L). Serologic tests for HIV, Epstein Barr Virus, Cytomegalovirus, Herpes simplex virus, Brucella and *Toxoplasma gondii* were all negative. TST was strongly positive (35x35 mm) and T-SPOT-TB test was also reactive. Biopsy specimens were negative for acid-fast bacilli but mycobacterial culture was positive. Afterwards MTX and ADA were discontinued and the patient was treated for 2 months with isoniazid 300 mg per day, rifampicin 600 mg per day, ethambutol 1200 mg per day and pyrazinamide 1500 mg per day and then received isoniazid and rifampicin at the same dose for other 7 months.

Three months after discontinuation of RA therapy the patient presented polyarticular synovitis with severe functional impairment. The patient reintroduced MTX and received rituximab with functional improvement. Six months later, the ulcer was completely healed and cervical lymphadenopathies were reduced in number and size.

## DISCUSSION

We presented a case of tuberculosis of the tongue in a RA patient treated with MTX and ADA for 6 years.

Previously the patient received high dose of prednisone, INF and subsequently ETA. TNF $\alpha$  is the most important cytokine in the host response to TB infection. Particularly TNF $\alpha$  is essential for macrophage activation, inflammatory cell recruitment, granuloma formation and maintenance of granuloma integrity [7].

Although the probability of TB infection is very low for MTX, this risk is more consistent for TNF $\alpha$  inhibitors with an increased risk to develop extrapulmonary and disseminate TB disease [8].

In the literature there are only two reports on oral TB in RA patients treated with ADA and MTX. In one report the patient developed TB after 3 months of treatment and no pretreatment TST result was reported.

As in our case, in the second report TB arose after a long time of treatment, TST was reported to be negative pre-therapy and conversed positive when the patient developed oral TB [9, 10]. Oral TB is a rare entity and may be either primary or, more often, secondary to pulmonary TB. Primary oral TB is more common in young people while secondary form is more common in adults [11].

The tongue is affected most commonly. The integrity of oral mucosa, the cleaning action of saliva, the presence of oral saprophytes and submucosal antibodies presents a natural resistance to Mycobacterium invasion.

Oral trauma, inflammatory conditions, poor oral hygiene or tooth extraction may represent a route of entry for Mycobacterium [2]. However, in our case, the patient didn't report any of these risk factors.

Primary oral TB presents mainly as painful chronic non healing ulcers and are more often associated with cervical lymphadenopathy [11]. Since 2008 American College of Rheumatology (ACR) guidelines for the use of TNF $\alpha$  inhibitors in RA patients put strong attention to the

screening of LTB with an initial TST in all patients, being considered for therapy with TNF $\alpha$  inhibitors, regardless of the presence of risk factors for LTB or BCG vaccination status. Although 2012 ACR revised guidelines indicate IGRAs as an alternative to TST, it is not still clarified if these tests are more useful than TST in RA patients because they are also influenced by host immunological status. Severely immunocompromised or paediatric patients have high rate of IGRA indeterminate results [12, 13]. However, in recent studies IGRAs seem to be more specific and more sensitive than TST in rheumatologic patients [14, 15].

In the present case, an initial TST was negative and later both TST and IGRA were positive. The risk to develop TB seems to be different among different TNF $\alpha$  inhibitors. Patients treated with ADA or INF have a 3 to 4 fold increased risk to develop TB compared with those treated with ETA.

These differences seem to be explained by different pharmacokinetics and pharmacodynamics properties. INF and ADA bind TNF $\alpha$  in a stable manner, their biologic effect is prolonged and they have proven to induce apoptosis of T cells whereas ETA biologic effect is reversible and has no cytotoxic effects.

The mean time to TB diagnosis from the start of TNF $\alpha$  inhibitors is relatively short, which suggests reactivation of LTB [3]. However, as in our patient, TB may occur after years of treatment with ADA.

Annual testing for TB is recommended only in patients who have a high rate of TB exposure and it was not performed in our patient because she was considered a low risk patient. Rituximab is a chimeric monoclonal antibody that targets CD20 positive B cells.

It was recommended in RA patients with TNF inhibitors inadequate response or adverse events. Rituximab seems to be safe in RA patients who have an elevated risk of TB and it may be a valid choice in such patients [6, 16].

*Keywords:* oral tuberculosis, rheumatoid arthritis, adalimumab, metotrexate, IGRA.

## SUMMARY

In recent years Tumor Necrosis Factor alpha (TNF $\alpha$ ) inhibitors have been highly effective in treating rheumatoid arthritis (RA). However, patients receiving these inhibitors have an increased risk of developing tuberculosis (TB). We describe a rare case of tuberculosis of the tongue in an RA patient treated with methotrexate (MTX) and the TNF $\alpha$  inhibitor adalimumab (ADA) for the previous six years.

Pre-treatment tuberculin skin test (TST) was negative. The patient was admitted to our division complaining of a sore throat for months. Clinical examination revealed a swollen non-healing ulcer at the base of the tongue, which was suspected to be a squamous cell carcinoma. Histopathological

assessment unexpectedly revealed a chronic granulomatous inflammation compatible with tuberculosis. TST was strongly positive and the T-Spot-TB test was also reactive.

MTX and ADA were discontinued and the patient received antituberculous treatment with complete healing of the lesion.

After three months our patient had a worsening RA that was treated with MTX and rituximab with no TB-related adverse events. This case highlights the importance of considering tuberculosis in the differential diagnosis of ulcerative lesions of the oral cavity, especially in immunocompromised patients treated with TNF $\alpha$  inhibitors. Rituximab can be a valid alternative therapy in such patients.

## RIASSUNTO

*Negli ultimi anni gli inibitori del Tumor Necrosis Factor alpha (TNF $\alpha$ ) si sono dimostrati molto efficaci nel trattamento dell'artrite reumatoide (AR). Tuttavia i pazienti trattati con questi inibitori hanno un aumentato rischio di sviluppare la tubercolosi (TB). Qui presentiamo un raro caso di tubercolosi della lingua in una paziente affetta da AR trattata negli ultimi 6 anni con metotrexate (MTX) e l'inibitore del TNF $\alpha$  adalimumab (ADA). Il test cutaneo alla tubercolina (TST) prima del trattamento era negativo. La paziente è giunta alla nostra osservazione poiché lamentava mal di gola da alcuni mesi. L'esame obiettivo ha rivelato una tumefazione ulcerata alla base della lingua che si sospettava essere un carcinoma squamoso. Inaspettatamente, l'esame*

*istologico ha mostrato una flogosi granulomatosa cronica compatibile con infezione tubercolare. Adesso il TST risultava fortemente positivo ed il T-Spot-TB era reattivo. MTX ed ADA sono stati sospesi e la paziente ha cominciato il trattamento antitubercolare, con completa guarigione della lesione. Dopo tre mesi la paziente ha presentato un peggioramento dell'AR trattato con MTX e rituximab in assenza di eventi avversi correlabili alla TB. Questo caso clinico sottolinea l'importanza di considerare la tubercolosi nella diagnosi differenziale delle lesioni ulcerate del cavo orale, in modo particolare nei pazienti immunodepressi trattati con inibitori del TNF $\alpha$ . Il rituximab potrebbe essere una valida alternativa per il trattamento di tali pazienti.*

## REFERENCES

- [1] Global tuberculosis report 2013. WHO 2013. Retrieved from [http://www.who.int/tb/publications/global\\_report/en/](http://www.who.int/tb/publications/global_report/en/) 2013. Last accessed March 24, 2014.
- [2] Kakisi O.K., Kechagia A.S., Kakisis I.K., Rafailidis P.I., Falagas M.E. Tuberculosis of the oral cavity: a systematic review. *Eur. J. Oral. Sci.* 118, 103-109, 2010.
- [3] Dixon W.G., Hyrich K.L., Watson K.D., et al. Drug-specific risk of tuberculosis in patients with rheumatoid arthritis treated with anti-TNF therapy: results from the British Society for Rheumatology Biologics Register (BSRBR). *Ann. Rheum. Dis.* 69, 3, 522-528, 2010.
- [4] Wallis R.S. Tumor necrosis factor antagonists: structure, function, and tuberculosis risks. *Lancet Infect. Dis.* 8, 601-611, 2008.
- [5] Saag K.G., Teng G.G., Patkar N.M., et al. Ameri-

- can College of Rheumatology 2008 Recommendations for the use of nonbiologic and biologic disease-modifying antirheumatic drugs in rheumatoid arthritis. *Arthritis Rheum.* 59, 6, 762-784, 2008.
- [6] Singh J.A., Furst D.E., Bharat A., et al. Update of the 2008 American College of Rheumatology recommendations for the use of disease-modifying antirheumatic drugs and biologic agents in the treatment of rheumatoid arthritis. *Arthritis Care Res. (Hoboken)*. 64, 5, 625-639, 2012.
- [7] Roach D.R., Bean A.G., Demangel C., France M.P., Briscoe H., Britton W.J. TNF regulates chemokine induction essential for cell recruitment, granuloma formation, and clearance of mycobacterial infection. *J. Immunol.* 168, 9, 4620-4627, 2002.
- [8] Keane J., Gershon S., Wise R.P., et al. Tuberculosis associated with infliximab, a tumor necrosis factor alpha-neutralizing agent. *N. Engl. J. Med.* 345, 15, 1098-1104, 2001.

- [9] Kolokotronis A., Avramidou E., Zaraboukas T., Mandraveli K., Alexiou S., Antoniadis D. Oral tuberculosis associated with a treatment with anti-rheumatic drugs. *J. Oral. Pathol. Med.* 35, 2, 123-125, 2006.
- [10] Barouta G., Karapetsa M., Kostopoulou E., Alexiou I., Koukoulis G., Sakkas L.I. Oral tuberculosis in a patient with rheumatoid arthritis after long treatment with methotrexate and adalimumab. *J. Clin. Rheumatol.* 16, 7, 330-331, 2010.
- [11] Mignogna M.D., Muzio L.L.O., Favia G., et al. Oral tuberculosis: a clinical evaluation of 42 cases. *Oral Dis.* 6, 1, 25-30, 2000.
- [12] Bocchino M., Bellofiore B., Matarese A., Galati D., Sanduzzi A. IFN-gamma release assays in tuberculosis management in selected high-risk populations. *Expert Rev. Mol. Diagn.* 9, 2, 165-177, 2009.
- [13] Bruzzese E., Bocchino M., Assante L.R., et al. Gamma interferon release assays for diagnosis of tuberculosis infection in immune-compromised children in a country in which the prevalence of tuberculosis is low. *J. Clin. Microbiol.* 47, 7, 2355-2357, 2009.
- [14] Mínguez S., Latorre I., Mateo L., et al. Interferon-gamma release assays in the detection of latent tuberculosis infection in patients with inflammatory arthritis scheduled for anti-tumour necrosis factor treatment. *Clin. Rheumatol.* 31, 5, 785-794, 2012.
- [15] Vassilopoulos D., Tsikrika S., Hatzara C., et al. Comparison of two gamma interferon release assays and tuberculin skin testing for tuberculosis screening in a cohort of patients with rheumatic diseases starting anti-tumor necrosis factor therapy. *Clin. Vaccine Immunol.* 18, 12, 2102-2108, 2011.
- [16] Xanthouli P., Sailer S., Fiehn C. Rituximab (RTX) as an alternative to TNF-alpha antagonists in patients with rheumatoid arthritis and high risk of severe infections: a systematic analysis of the experience in one center. *Open Rheumatol. J.* 6, 286-289, 2012.