



This is a repository copy of *Radiation-induced osteosarcoma involving the mandible – report of a rare diagnosis*.

White Rose Research Online URL for this paper:

<https://eprints.whiterose.ac.uk/194451/>

Version: Published Version

Article:

Mahmood, H. orcid.org/0000-0001-7159-0368, Hankinson, P., Andrew, D. et al. (2 more authors) (2022) Radiation-induced osteosarcoma involving the mandible – report of a rare diagnosis. *Oral Surgery*. ISSN 1752-2471

<https://doi.org/10.1111/ors.12794>

Reuse

This article is distributed under the terms of the Creative Commons Attribution (CC BY) licence. This licence allows you to distribute, remix, tweak, and build upon the work, even commercially, as long as you credit the authors for the original work. More information and the full terms of the licence here:

<https://creativecommons.org/licenses/>

Takedown

If you consider content in White Rose Research Online to be in breach of UK law, please notify us by emailing eprints@whiterose.ac.uk including the URL of the record and the reason for the withdrawal request.



eprints@whiterose.ac.uk
<https://eprints.whiterose.ac.uk/>

CASE REPORT

Radiation-induced osteosarcoma involving the mandible—Report of a rare diagnosis

Hanya Mahmood¹  | Paul Hankinson²  | David Andrew³ | Muzzammil Nusrath⁴ | Syed Ali Khurram²

¹Academic Unit of Oral & Maxillofacial Surgery, School of Clinical Dentistry, University of Sheffield, Sheffield, UK

²Unit of Oral & Maxillofacial Pathology, School of Clinical Dentistry, University of Sheffield, Sheffield, UK

³Department of Oral & Maxillofacial Radiology, School of Clinical Dentistry, University of Sheffield, Sheffield, UK

⁴Department of Oral & Maxillofacial Surgery, Royal Hallamshire Hospital, Sheffield, UK

Correspondence

Hanya Mahmood, Academic Unit of Oral & Maxillofacial Surgery, School of Clinical Dentistry, University of Sheffield, 19 Claremont Crescent, S10 2TA, UK.
Email: h.mahmood@sheffield.ac.uk

Abstract

Background: Radiation-induced osteosarcomas of the jaws are a rare but often fatal consequence of radiation therapy in the head and neck region. Here we present a case of radiation-induced osteosarcoma of the mandible.

Case Presentation: A male presented with severe trismus and marked left lingual alveolus expansion 1 year following extractions in the lower left quadrant. Four years previously, he had radical radiotherapy (70Gy) and chemotherapy for a p16-positive T1N2cM0 squamous cell carcinoma of the left tonsil with a positive left level II node. Initial bone biopsies of the left mandible showed a bony sequestrum suggestive of osteoradionecrosis with the presence of abnormal osteoid suspicious of osteosarcoma. Imaging demonstrated an abnormal exophytic bone-forming lesion in the left mandibular body and parasymphysis and ruled out a metastatic lesion. The patient underwent bilateral neck dissection, left mandibulectomy with fibula flap reconstruction and full-thickness skin graft.

Conclusions: Osteosarcoma should be considered if changes are seen in previously stable irradiated bone with bony destruction and a soft tissue mass. This case highlights the importance of synthesis of clinical, radiological and pathological findings in the diagnosis of such lesions, especially where the histology initially suggested a benign process.

KEYWORDS

case report, head and neck cancer, oral and maxillofacial surgery, radiation therapy, radiation-induced osteosarcoma

BACKGROUND

Radiation therapy is a standard treatment modality for head and neck malignancies. However, it can have adverse effects on bone. Late complications include osteoradionecrosis, radiation-induced osteitis and osteosarcoma.¹ Osteosarcomas are malignant tumours of undifferentiated bone connective tissue which most commonly occur in the long bones of limbs, particularly the distal femur and proximal tibia. Its incidence in the jaws is exceedingly rare (0.7 per million) with only 10% being radiation-induced.^{2,3}

For irradiation to induce malignant change, the injury to individual cells must be adequate enough to cause a genetic

mutation but not to cause cell death, a sequela that can be seen at the margins of the radiation field.⁴ Radiation-induced osteosarcomas (RIOS) usually present as slow-growing, painless swellings which may be accompanied by numbness, trismus or tooth mobility. They can be extensively destructive warranting the need for radical life-changing surgery and chemotherapy.⁵ They have a poor prognosis, with 5-year survival ranging between 17% and 60%^{6,7} and are more aggressive with worse outcomes than osteosarcomas arising in the absence of radiotherapy.^{8,9}

This report illustrates a rare case of RIOS of the mandible. We highlight the surgical complexity of treating these cases and the importance of radiology in the diagnosis of these

This is an open access article under the terms of the [Creative Commons Attribution](https://creativecommons.org/licenses/by/4.0/) License, which permits use, distribution and reproduction in any medium, provided the original work is properly cited.

© 2022 The Authors. *Oral Surgery* published by British Association of Oral Surgeons and John Wiley & Sons Ltd.

lesions, particularly where the histology initially suggests a benign process. The CARE guidelines (for CAse REports) were used for data collection and reporting of this case.

CASE REPORT

A 60-year-old Caucasian male presented to the Oral and Maxillofacial department with an expansile mass in the left mandible. Four years earlier, he was treated for a p16-positive T1N2cM0 squamous cell carcinoma of the left tonsil with radical radiotherapy (70 Gy in 35 fractions) and concurrent cetuximab chemotherapy. Two months prior to the presentation this mass was diagnosed as osteoradionecrosis following a biopsy at a different unit. The patient was otherwise fit and well, a non-smoker and consumed approximately 16 units of alcohol per week.

Clinical examination revealed marked expansion of the left mandibular body with exposed lingual bone. There was no cervical lymphadenopathy and an examination of the temporomandibular joint was normal. Neurosensory testing did not identify any facial weakness or altered sensation. A Cone beam Computerised Tomography (CT) scan revealed a spiculated periosteal reaction with an abnormal exophytic bone-forming lesion in the left mandibular body and parasymphysis suggestive of either osteosarcoma or a 'blastic' metastasis (Figure 1). Whole-body imaging ruled out metastasis and a staging Magnetic Resonance Imaging (MRI) neck confirmed the CT findings.

A biopsy of the lesion was initially diagnosed as a bony sequestrum with radiation-induced changes. This contrasted with the features seen on the imaging and prompted multidisciplinary team (MDT) discussion. The histology was reviewed, including an external specialist bone pathology review and a diagnosis of high-grade chondroblastic osteosarcoma was made, which given the history was presumed to be radiation-induced (Figure 2).

Discussions at the local head and neck and sarcoma MDT meetings led to a consensus of radical surgery with curative intent. The patient declined referral to the national sarcoma MDT to avoid delays in treatment.

The patient underwent a tracheostomy, bilateral neck dissection (levels I-III), left mandibulectomy and fibula-free flap reconstruction. The resection extended from the left subcondyle to the mandibular right canine. Histological analysis revealed a grade 3 chondroblastic osteosarcoma (Figure 3) with a diameter of 100 mm. The pathological staging was pT2pN0. The tumour was present at the deep soft tissue, posterior bone and buccal soft tissue margins. Following further MDT discussion, a second surgery was planned.

The patient had further excisions of the areas where margins were presumed to be involved, including the left mandibular condyle, guided by intra-operative frozen sections. No convincing evidence of a tumour was found in the soft tissue; however, the tumour was seen in the most inferior aspect of the remaining condyle though the margins were clear. Nine months after the initial RIOS diagnosis, the patient developed a left temporal swelling which

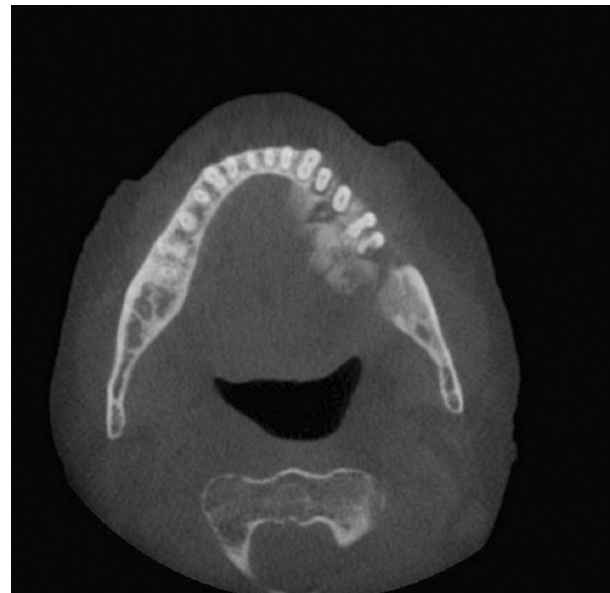


FIGURE 1 An axial view of the cone beam CT mandible revealing the expansile mass in the left mandible.

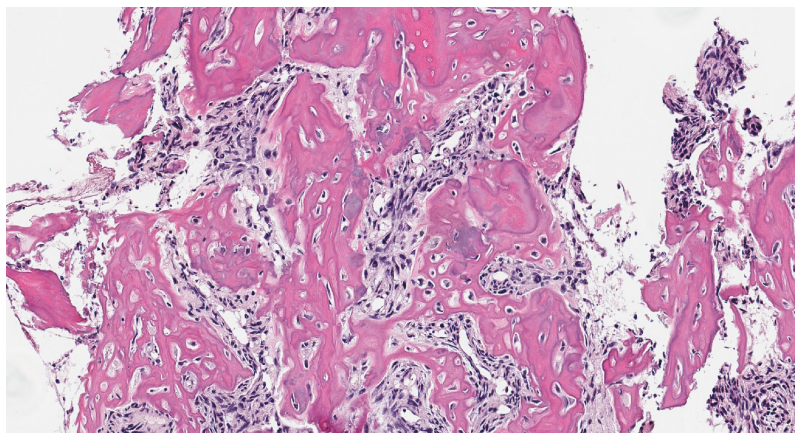


FIGURE 2 A high-power photomicrograph displaying neoplastic bone formation by the atypical tumour cells.

FIGURE 3 A high-power photomicrograph showing areas of cartilaginous differentiation within the tumour. The lesional cells display significant atypia.

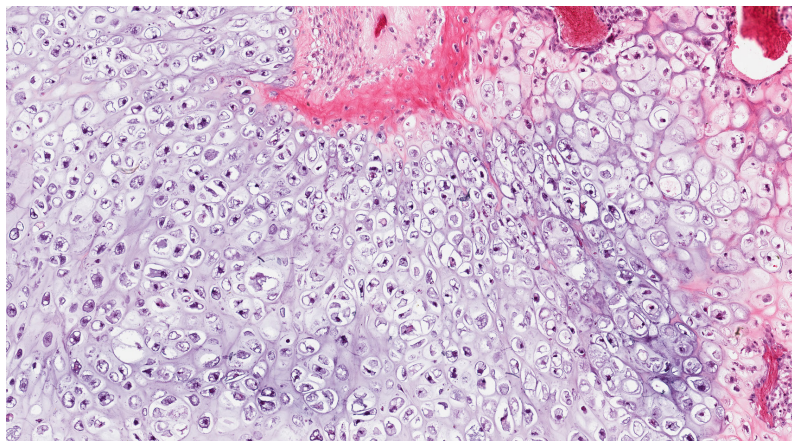


TABLE 1 CARE checklist timeline of clinical events and investigations in patient's journey of care

Event	Timeline
First symptoms	November 2016
First presentation to clinic	April 2017
Radiological Investigations (CBCT & MRI)	October 2019
Initial biopsy	October 2019
Surgical resection	January 2020
MDT review of histology	March 2020
Further excisions	March 2020
Recurrence and palliative chemotherapy	April 2021
Sepsis, pneumonia, death	May 2021

was confirmed as a recurrence of the tumour. The patient received palliative chemotherapy but succumbed to neutropenic sepsis and pneumonia 19 months after the initial diagnosis. A summary of the timeline of clinical events and investigations in the patient's journey of care is summarised in [Table 1](#).

CONCLUSIONS

Whilst sarcomatous conversion is one of the most feared complications of irradiation, given the increasing incidence of head and neck malignancies,¹⁰ it is predictable that the number of RIOS in the head and neck will likely rise.^{4,10} Due to the rarity of RIOS and its slow-growing and painless nature, diagnosis is often delayed.

This case highlights the importance of radiology in the diagnosis of RIOS, particularly if changes are seen in previously stable irradiated bone with bony destruction and a soft tissue mass. Here, two biopsies did not show convincing sarcomatous change and suggested a benign process, however, the CT imaging prompted discussion at the MDT, an external review of the histology and ultimately led to the diagnosis. Definitive surgery with chemotherapy remains the mainstay of treatment for sarcomas of the jaws.⁹

AUTHOR CONTRIBUTIONS

HM analysed the patient information to produce the first draft of the manuscript. PH assisted with data analysis and obtained relevant images for inclusion in the manuscript. DA provided radiological expertise and MN provided information regarding surgical treatment. SAK conceptualised the report and provided histological analysis and overall supervision and guidance. All authors read and approved the final manuscript.

CONFLICT OF INTEREST

The authors declare that they have no competing interests.

DATA AVAILABILITY STATEMENT

Data sharing is not applicable to this article as no datasets were generated or analysed during the current study.

CONSENT FOR PUBLICATION

We have publishing permission for all images.

ORCID

Hanya Mahmood  <https://orcid.org/0000-0001-7159-0368>
Paul Hankinson  <https://orcid.org/0000-0002-7213-5380>

REFERENCES

- Shao ZY, He Y, Wang L, Hu H, Shi H. Computed tomography findings in radiation-induced osteosarcoma of the jaws. *Oral Surg Oral Med Oral Pathol Oral Radiol Endod.* 2010;109(3):E88–94.
- Garrington GE, Scofield HH, Coryn J, Cornyn J, Hooker SP. Osteosarcoma of the jaws. Analysis of 56 cases. *Cancer.* 1967;20(3):377–91.
- Thompson L. World Health Organization classification of tumours: pathology and genetics of head and neck tumours. *Ear Nose Throat J.* 2006;85(2):74.
- Huvos AG, Woodard HQ, Cahan WG, Higinbotham NL, Stewart FW, Butler A, et al. Postradiation osteogenic sarcoma of bone and soft tissues. A clinicopathologic study of 66 patients. *Cancer.* 1985;55(6):1244–55.
- Luetke A, Meyers PA, Lewis I, Juergens H. Osteosarcoma treatment – where do we stand? A state of the art review. *Cancer Treat Rev.* 2014;40(4):523–32.
- Tabone MD, Terrier P, Pacquement H, Brunat-Mentigny M, Schmitt C, Babin-Boilletot A, et al. Outcome of radiation-related osteosarcoma after treatment of childhood and adolescent cancer: a study of 23 cases. *J Clin Oncol.* 1999;17(9):2789–95.
- LeCornu MG, Chuang S, Kaban LB, August M. Osteosarcoma of the jaws: factors influencing prognosis. *J Oral Maxillofac Surg.* 2011;69(9):2368–75.

8. Bennett JH, Thomas G, Evans AW, Speight PM. Osteosarcoma of the jaws: a 30-year retrospective review. *Oral Surg Oral Med Oral Pathol Oral Radiol Endod.* 2000;90(3):323–33.
9. McCarthy CE, Field JK, Rajlawat BP, Field AE, Marcus MW. Trends and regional variation in the incidence of head and neck cancers in England: 2002 to 2011. *Int J Oncol.* 2015;47(1):20.
10. Coca-Pelaz A, Mäkitie AA, Strojan P, Corry J, Eisbruch A, Beitler JJ, et al. Radiation-induced sarcomas of the head and neck: a systematic review. *Adv Ther.* 2021;38(1):90–108.4-210.

How to cite this article: Mahmood H, Hankinson P, Andrew D, Nusrath M, Khurram SA. Radiation-induced osteosarcoma involving the mandible—Report of a rare diagnosis. *Oral Surg.* 2022;00:1–4. <https://doi.org/10.1111/ors.12794>