

# Giant Thoracic Wall Lipoma Mimicking Plexiform Neurofibroma: A Case Report

POOJA PANDEY<sup>1</sup>, ABHISHEK GHOSH<sup>2</sup>, TAPAS KUMAR ROY<sup>3</sup>, SURENDRA MEHROTRA<sup>4</sup>

## ABSTRACT

Lipoma, a benign tumour of adipose tissue and mesenchymal origin, can occur anywhere in the body where normal fat deposits are present. Aside from the usual locations of the upper extremity, thigh, back, and shoulder, it is also seen very rarely in the posterior cervical region, face, and chest wall. Depending on the size, it is called a giant lipoma, i.e. >5 cm. To differentiate giant lipoma with other differentials like neurofibroma and liposarcoma, Fine Needle Aspiration Cytology (FNAC) is required to reach the definitive diagnosis and plan for the required surgical treatment. Here, a rare case of a 53-year-old male is reported, with chief complaints of swelling in front of his chest for the past 25 years. On evaluation, Magnetic Resonance Imaging (MRI) thorax reported a large, elongated, lobulated soft tissue mass in the subcutaneous plane of the anterior thorax. Under general anaesthesia, an elliptical incision was given and a complete portion of the mass was excised. Histopathological examination revealed, encapsulated adipose cells, capillaries, and connective tissue stroma, pathognomonic of Lipoma. Postoperatively, there was haematoma formation, which was managed conservatively. In the evidence based system, chronology of approach for skin and soft tissue swelling need to be followed, which starts from FNAC followed by Computed Tomography (CT) and MRI.

**Keywords:** Adipocyte, Benign tumour, Mesenchymal

## CASE REPORT

A 53-year-old male, normotensive and nondiabetic, working as a shopkeeper, presented to the Surgery Outpatient Department (OPD) with chief complaints of swelling in front of his chest for the past 25 years [Table/Fig-1]. The painless solitary swelling was insidious in onset, small in size (approx. 3×1 cm), which gradually started increasing in size after 20 days of application of some Ayurveda (jadi buti) paste over it, in order to suppress the swelling. Presently, swelling had obtained a size of approximately 35×18 cm. The patient underwent FNAC at a local hospital 18 years back, following which the patient developed ulceration over the swelling and size also kept on increasing gradually. The ulcer was treated conservatively and no past documents or treatment history were available. The patient's daily activities were restricted. The patient develops shortness of breath, after walking for a distance of 500 meters to 1 km. There was no significant family history and no history of addiction.

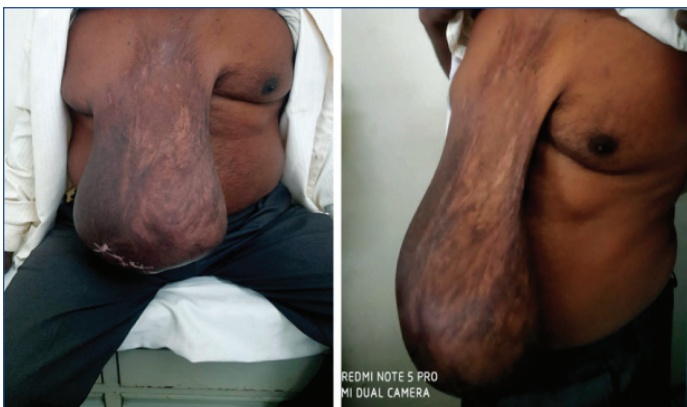On general examination, Body Mass Index (BMI) was 25.4 kg/m<sup>2</sup>, and Karnofsky's performance status was 70 [1]. No significant finding was revealed on systemic examination. On local examination, on swelling was present in front of the chest

attached to the manubrium sterni and freely hanging, reaching up to 1 cm above the level of the pubic symphysis, having a dimension of 40×20×16 cm. At the distal portion of the swelling, there was an old, healed ulcerative area of about 12×4 cm. The rest of the overlying skin was normal. The surface appeared to be irregular at some distal places. Venous prominence were present at the root of the swelling.

Superiorly, it was attached to the manubrium sterni, towards the right side, extending to the right nipple areolar complex, the left side 2 cm inferolaterally to the manubrium sterni, and inferiorly it was attached to the upper third of the body of the sternum [Table/Fig-1]. On palpation, the swelling was nontender, soft to firm in consistency, with lobulated surface. There was no local rise in temperature. The trachea was in the midline, carotid pulsation was noticeable, power in all four limbs was 5/5, and sensory and motor functions were normal. Differential diagnoses were made of neurofibroma, lipoma, and soft tissue sarcoma.

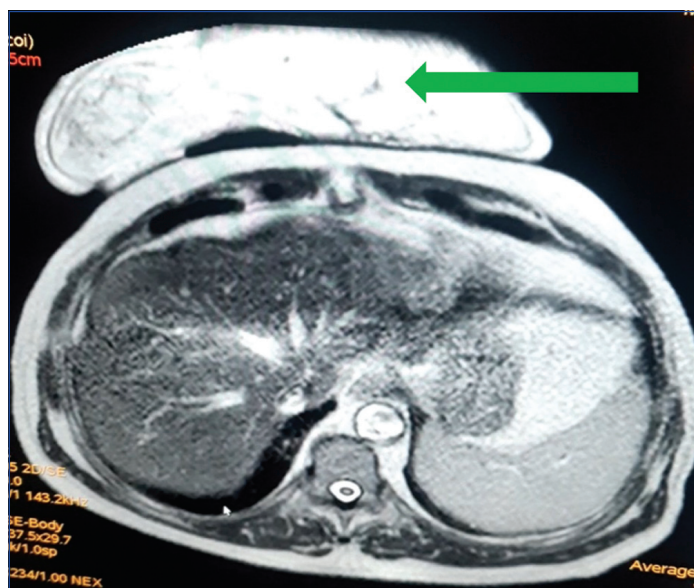
The FNAC showed plenty of mature adipocytes with an inconspicuous nucleus, the presence of fibrous septa, some areas of fat necrosis, minimal stroma and vascularity, suggestive of lipoma. An MRI thorax was done, to look for delineation of tissue planes and to look for any malignant transformation. MRI thorax reported, a large elongated, lobulated soft tissue mass in the subcutaneous plane of the anterior thorax [Table/Fig-2]. There was no evidence of bony erosion or deeper invasion. Swelling was supplied by a branch of the right internal mammary artery, suggestive of lipoma.

Under general anaesthesia, an elliptical incision was given and a complete portion of the mass was excised. After surgical excision, a negative suction drain was left in-situ and the excised swelling was weighed 4 kg [Table/Fig-3a-c]. Histopathological examination revealed encapsulated adipose cells, capillaries, and connective tissue stroma suggestive of lipoma [Table/Fig-4]. Postoperatively, after three days, there was haematoma formation, which was managed conservatively. From postoperative day 1, the patient started to mobilise happily, with a sense of relief of

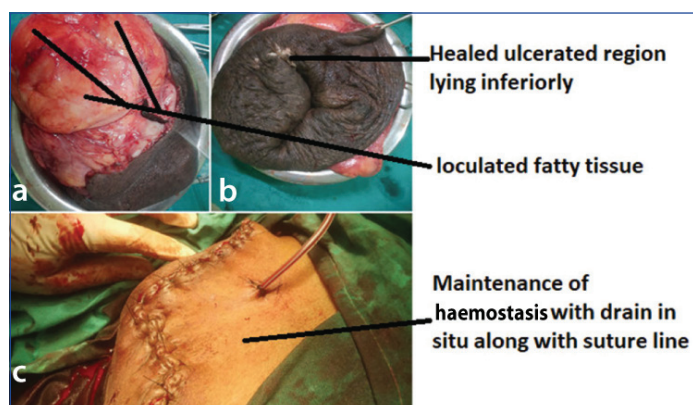


**[Table/Fig-1]:** Preoperative view of Giant Lipoma

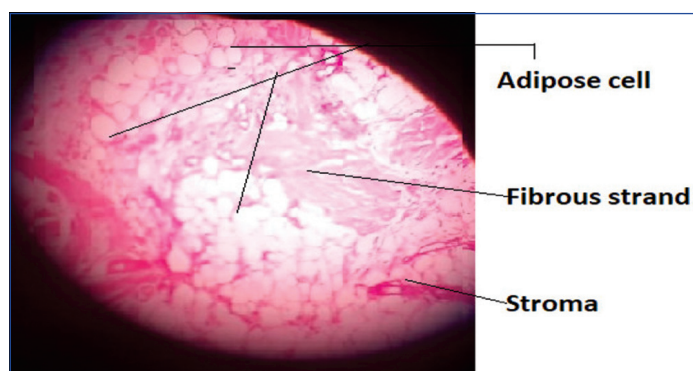
weight from his chest. The patient was discharged on day 7 after the removal of the drain. On follow-up visit, the sutures were removed. After three months of surgery, the wound was healthy, with no discharge, and Karnofsky's performance status was 100.



**[Table/Fig-2]:** Magnetic Resonance Imaging (MRI) Thorax T2W shows lipoma indicated by green arrow and it has no communication with the thoracic cavity.



**[Table/Fig-3]:** A and B excised tissue and C- postoperative suture line along with drain to prevent haematoma formation.



**[Table/Fig-4]:** Histopathological view at 10x showing adipose cells in cluster interspersed by collagen fibrils and minimal vascularity noted (H&E, 10x).

## DISCUSSION

Lipoma, a benign entity, has an incidence of 10% with a prevalence of 2.1 per 1000 [2]. It most commonly occurs in the 4<sup>th</sup> and 6<sup>th</sup> decades of life. Rarely, lipoma reaches a size of 2 cm [3]. Giant lipomas are those, that are larger than 5 cm in diameter and weigh more than 1000 g [1]. It can arise from different planes, either from subcutaneous, fascial or intramuscular planes. The location of giant lipomas reported in the literature are the posterior cervical region, scapula, chest wall, and gastrointestinal tract [3-8].

The aetiology behind the occurrence of lipoma is unknown. It has been postulated that hypercholesterolaemia, trauma, obesity, and genetic factors can be the predisposing factors [4,6]. Giant lipoma over the thorax can be confused with other types of the soft tissue swellings. Although, plexiform neurofibroma and soft tissue sarcoma also presents with painless, soft to firm, mobile or fixed swelling. Therefore, FNAC is the only way to differentiate between these swellings. FNAC shows, well-encapsulated mature adipose cells interspersed with collagen fibres in lipoma; whereas on the other hand, neurofibroma will present, well-encapsulated nodules composed of hypocellular myxoid tissue and nerve bundles. Round to oval nuclei, pleomorphism, and hyperchromatism, with moderate amount of cytoplasm goes in favour of soft tissue sarcoma [9-11]. Hence, FNAC serves as an important diagnostic tool for further management. CT and MRI are useful in planning the surgical procedure or further management of the patient [6,9,12].

Jang HJ et al., had reported a chest wall lipoma, growing into the pleural cavity, where direct and thorascopic approach has been followed for surgical excision without any postoperative complications [12]. Recurrence rate after surgical excision have been reported to be <5% by the Chen M et al., [13]. The index case report presented a unique clinical presentation at the unusual location i.e. chest wall.

## CONCLUSION(S)

The clinical presentation may mislead the diagnosis. To avoid under or over diagnosis, a systematic approach from history to investigation is required. Excision is the preferred treatment for the giant lipoma, if there is no organ involvement, as it improves the cosmetic outcome and escalates the quality of life.

## Acknowledgement

The authors are thankful to the Department of Pathology in contributing towards reaching the diagnosis.

## REFERENCES

- [1] Picot J, Cooper K, Bryant J, Clegg AJ. The clinical effectiveness and cost-effectiveness of Bortezomib and Thalidomide in combination regimens with an alkylating agent and a corticosteroid for the first-line treatment of multiple myeloma: A systematic review and economic evaluation. *Health Technol Assess.* 2011;15(41):01-204.
- [2] Mello DF, Manica MZ, Helene Junior A. Giant lipomas: A 14 case series. *Rev Bras Cir Plast.* 2015;30(1):33-37.
- [3] Charifa A, Azmat CE, Badri T. Lipoma Pathology. [Updated 2021 Dec 12]. In: StatPearls [Internet]. Treasure Island (FL): StatPearls Publishing; 2022 Jan-. Available from: <https://www.ncbi.nlm.nih.gov/books/NBK482343/>.
- [4] Kolb L, Yarrarapu SNS, Ameer MA, Rosario-Collazo JA. Lipoma. [Updated 2021 Dec 29]. In: StatPearls [Internet]. Treasure Island (FL): StatPearls Publishing; 2022 Jan-. Available from: <https://www.ncbi.nlm.nih.gov/books/NBK507906/>.
- [5] Singh SB, Vardhan H, Chauhan N, Singh AK. An unusual case of giant multilobulated lipoma over left truncal region. *International Surgery Journal.* 2020;7(8):2741-43. Doi:10.18203/2349-2902.isj20203267.
- [6] Tchernev G, Chokoeva AA, Patterson JW, Bakardzhiev I, Wollina U, Tana C. Plexiform neurofibroma: A case report. *Medicine (Baltimore).* 2016;95(6):e2663.
- [7] Schicchi N, Tiberi M, Fogante M, Andolfi M, Giovagnoni A, Refai M. Chest wall lipoma mimicking intrathoracic mass: Imaging with surgical correlation. *Radiology Case Reports.* 2019;14(8):956-61.
- [8] Siddiqi MS, Al Kindi AH, Al Marhoon M, Salem A. Giant Intrathoracic Lipoma. *Sultan Qaboos Univ Med J.* 2021;21(4):670-672.
- [9] Messersmith L, Krauland K. Neurofibroma. [Updated 2022 May 15]. In: StatPearls [Internet]. Treasure Island (FL): StatPearls Publishing; 2022 Jan-. Available from: <https://www.ncbi.nlm.nih.gov/books/NBK539707/>.
- [10] Rekhi B, Gorad BD, Kakade AC, Chinoy R. Scope of FNAC in the diagnosis of soft tissue tumors--A study from a tertiary cancer referral center in India. *Cytojournal.* 2007;4:20.
- [11] Lee JH, Do HD, Lee JC. Well-circumscribed type of intramuscular lipoma in the chest wall. *J Cardiothorac Surg.* 2013;8:181. <https://doi.org/10.1186/1749-8090-8-181>.
- [12] Jang HJ, Choi BH, Park SO. A rare case of chest wall lipoma growing into the

pleural cavity: A case report. J Cardiothorac Surg. 2021;16:197. <https://doi.org/10.1186/s13019-021-01576-x>.

and review of the literature. J Cardiothorac Surg. 2013;8:196. doi: 10.1186/1749-8090-8-196. PMID: 24120207; PMCID: PMC3973812.

[13] Chen M, Yang J, Zhu L, Zhao H. Intrathoracic giant pleural lipoma: Case report

#### PARTICULARS OF CONTRIBUTORS:

1. Postgraduate Resident, Department of General Surgery, MIMS, Barabanki, Uttar Pradesh, India.
2. Postgraduate Resident, Department of General Surgery, MIMS, Barabanki, Uttar Pradesh, India.
3. Postgraduate Resident, Department of General Surgery, MIMS, Barabanki, Uttar Pradesh, India.
4. Head, Department of General Surgery, MIMS, Barabanki, Uttar Pradesh, India.

#### NAME, ADDRESS, E-MAIL ID OF THE CORRESPONDING AUTHOR:

Dr. Surendra Mehrotra,  
Mayo Institute of Medical Sciences Gadia, Barabanki, Uttar Pradesh, India.  
E-mail: rememberepooja@gmail.com

#### PLAGIARISM CHECKING METHODS: [\[Jain H et al.\]](#)

- Plagiarism X-checker: Jun 23, 2022
- Manual Googling: Aug 06, 2022
- iThenticate Software: Sep 15, 2022 (8%)

#### ETYMOLOGY: Author Origin

#### AUTHOR DECLARATION:

- Financial or Other Competing Interests: None
- Was informed consent obtained from the subjects involved in the study? Yes
- For any images presented appropriate consent has been obtained from the subjects. Yes

Date of Submission: **Jun 16, 2022**

Date of Peer Review: **Jul 21, 2022**

Date of Acceptance: **Aug 08, 2022**

Date of Publishing: **Oct 01, 2022**