

A Rare Case of Accessory Breast Mimicking Lipoma in a Male

VM VINOTH VAITHIYA¹, S SARAVANA KUMAR²

CC BY-NC-ND

ABSTRACT

Accessory breast tissue is a rare condition in which there is a presence of breast tissue in an ectopic site in addition to normal site. It occurs in about 0.4-6% of women and 1.68% occurrence is seen in men. The obstacle to management comes in the diagnosis of the accessory breast tissue. The commonest site is the axilla, and the other sites of occurrence are groin, buttock and thigh. The disease may present as a unilateral swelling with changes occurring during the time of pregnancy, lactation and menses due to the influence of hormones. This breast tissue also undergoes the changes that occur in a normal breast tissue such as fibrocystic changes or carcinomatous changes. A case of accessory breast tissue was reported in a 28-year-old-male which was initially suspected to be a pedunculated lipoma in the right axillary region and later on histopathological evaluation diagnosed to be an accessory breast tissue.

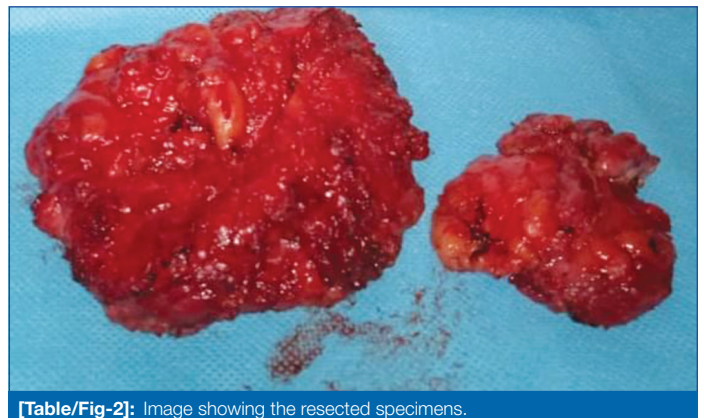Keywords: Axillary breast, Benign lesion, Ectopic, Excision, Fibrofatty tissue, Soft tissue mass

CASE REPORT

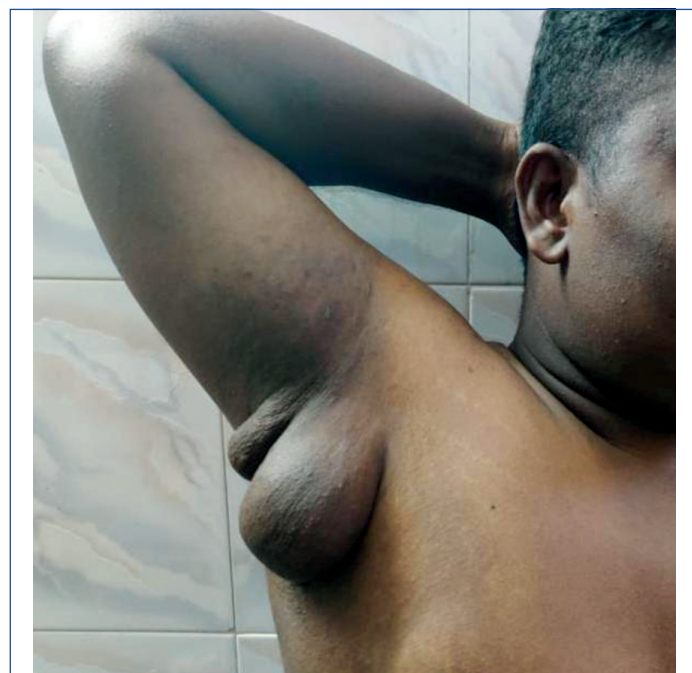
A 28-year-old-male presented to the Surgery Outpatient Department (OPD) with history of swelling in the right axilla for a period of two years. He noticed a swelling in right axilla, which was insidious in onset and gradually progressed to attain the current size. No history of pain/discharge or any other complaints. There was no history of trauma.

On examination, presence of two pedunculated swellings adjacent to each other were noted with the largest one measuring about 8×6 cm and the other one about 3×2 cm, it was soft in consistency. The skin over swelling was normal. Bilateral breast tissue was normal [Table/Fig-1].

Only with clinical assessment, differential diagnoses of pedunculated lipoma and accessory breast tissue were made and was admitted with plan for excision biopsy for confirmation of the diagnosis. Patient underwent surgery in the same admission where complete excision of both the swellings was done under general anaesthesia and the specimen [Table/Fig-2] was sent for histopathological analysis.

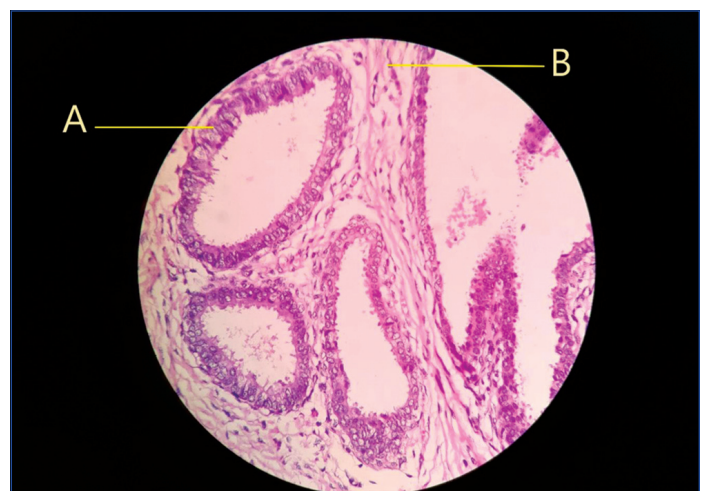


[Table/Fig-2]: Image showing the resected specimens.



[Table/Fig-1]: Showing two pedunculated swellings in right axilla.

Patient recovered well postoperatively with no complications. Biopsy report showed fibrofatty tissue with breast parenchymal tissue composed of proliferated ducts and acini with stromal proliferation. There was no evidence of malignancy in the histological examination of the specimen. A diagnosis of accessory breast tissue with fibrocystic changes was made based on the histopathology report which showed fatty breast parenchymal tissue with proliferated ducts and acini [Table/Fig-3].



[Table/Fig-3]: Histological picture with haematoxylin and eosin staining at 40X magnification showing proliferated ducts and acini (A) and fatty breast parenchymal tissue (B).

Postoperatively patient came for review after three months with no complications and a completely healed scar. And after six months of follow-up, patient had no local recurrence.

DISCUSSION

Embryologically the breast tissue develops in the “mammary line or milk line” [1]. As the development progress, they usually regress in all regions except in fourth intercostal space which forms the normal breast tissue [2]. Any failure in this process results in accessory breast tissue formation. They respond to hormonal stimulus, and become symptomatic during menarche, pregnancy and lactation [3]. It may also develop all pathologic conditions of normal breast tissue. [4] There are two types of ectopic breast tissue diseases namely supernumerary breast tissue and accessory breast tissue [5]. Supernumerary breast have nipple, areolae or sometimes both. Histologically they have an organised ductal system that communicates with the overlying skin. On the other hand, Aberrant or accessory breast tissue, unlike supernumerary breast, doesn't have any organised secretory system histologically [5].

In this case, the patient had no symptoms apart from the swelling due to the absence of hormones like oestrogen and progesterone as the patient was a male, and the swelling also had no nipple areola complex, only HPE analysis revealed the presence of breast parenchyma. Based on, it was diagnosed as accessory breast tissue. There are few syndromes which can have accessory breast tissue along with its other clinical features. Kallmann syndrome is one among such congenital disorder. It is characterized by gonadotropic hypogonadism, anosmia, undescended testes and accessory breast in rare cases [6]. These patients have no secondary sexual character development [7]. But the patient in the present case had normal primary and secondary sexual characters of male pattern, therefore, Kallmann syndrome was ruled out.

So, the most probable cause for the occurrence of this in this patient was probably due to congenital cause i.e failure in regression of the breast tissue during embryogenesis. Based on Kajava classification, this patient comes under class IV consisting of only glandular tissue [8].

The management for accessory breast is mainly surgical removal of the swelling [9] for either cosmetic reasons or to avoid further complications in future. Lesavoy MA et al., conducted a study on 28 patients who were managed with surgical removal of their axillary breast tissue [9]. The accessory breast tissue can also undergo carcinomatous change [10]. It can have poor prognosis due to the delayed diagnosis of the disease [11]. Due to these reasons, surgery was performed and complete removal of the lesion was done.

Marshall MB et al., reported 94% of ectopic breast cancers arose from aberrant tissue as opposed to 6% in supernumerary breasts [12].

The alternative treatment modality available for ectopic breast tissue was liposuction. It provides better cosmetic outcome than traditional excision [13]. Fan J et al., conducted a study on 51 patients who were treated with tumescent liposuction approach for the removal of accessory breasts [13]. But the long-term recurrence and complications

are still a controversial area. It is generally advised to remove the lesion surgically [8] as it can also lead to all pathological conditions of a normal breast tissue from benign [14] to malignant [15,16].

In cases of malignancy arising from the accessory breast tissue, further evaluation and extended resection is required for complete removal of the disease [16,17].

In the present case, at six months follow-up the patient had no local recurrence.

CONCLUSION(S)

The occurrence of an accessory breast is very rare in a male and poses a diagnostic difficulty. In the present case, the patient was asymptomatic due to absence of influencing hormones. While diagnosing, it is always advised to rule out other causes or syndromes associated with the disease to find the existence of other diseases. The present case was treated by excision of the swellings. Based on the histopathology report, a diagnosis of accessory breast tissue with fibrocystic changes was made. The patient showed no recurrence at six months of follow up.

REFERENCES

- [1] Brightmore TG. Cystic lesion of a dorsal supernumerary breast in a male. *Proc R Soc Med.* 1971;64:662-63.
- [2] DeFillippis EM, Arleo EK. The ABCs of accessory breast tissue: basic information every radiologist should know. *Am J Roentgenol.* 2014;202(5):1157-62.
- [3] Loukas M, Clarke P, Tubbs RS. Accessory breasts: A historical and current perspective. *Am Surg* 2007;73(5):525-28.
- [4] Bello U, Omotara SM. Clinico-pathologic spectrum of accessory axillary breast: Case series and literature review. *Sahel Med J.* 2017;20(3):129-33.
- [5] Teke Z, Kabay B, Akbulut M, Erdem E. Primary infiltrating ductal carcinoma arising in aberrant breast tissue of the axilla: A rare entity. *Report of a case. Tumori.* 2008;94(4):577-83.
- [6] Xia W, Cheng J, Zhang H, Lu Y. A male patient with Kallmann syndrome and accessory breasts. *Radiol Infect Dis.* 2015;2(3):141-45.
- [7] Sonne J, Lopez-Ojeda W. Kallmann Syndrome. *StatPearls [Internet]. Treasure Island (FL): StatPearls Publishing; 2022 Jan. PMID: 30855798. https://pubmed.ncbi.nlm.nih.gov/30855798/.*
- [8] Kajava Y. The proportions of supernumerary nipples in the Finnish population. *Duodecim.* 1915;31:143-70.
- [9] Lesavoy MA, Gomez-Garcia A, Nejd R, Yosur G, Szyau T J, Chang P. Axillary breast tissue: Clinical presentation and surgical treatment. *Ann Plast Surg.* 1995;35(4):356-60.
- [10] Badejo OA. Fungating accessory breast carcinoma in Nigerian women. *Trop Geogr Med.* 1984;36(1):45-49.
- [11] Kayahan M, Koksali N, Gunes P, Uzun MA, Aliustaoglu M, Gunerhan Y, et al. Ectopic breast carcinoma. *J Coll Physicians Surg--Pak JCPSP.* 2009;19(11):734-36.
- [12] Marshall MB, Moynihan JJ, Frost A, Evans SR. Ectopic breast cancer: Case report and literature review. *Surg Oncol.* 1994;3(5):295-304.
- [13] Fan J. Removal of accessory breasts: A novel tumescent liposuction approach. *Aesthetic Plast Surg.* 2009;33(6):809-13.
- [14] Riizvi G, Pandey H, Gupta MK. Fibroadenoma of ectopic breast tissue in axilla. *J Case Rep.* 2012;2(2):13-15.
- [15] Pang L, Cui M, Dai W, Wu S, Kong J. Diagnosis and treatment of male accessory breast cancer: A comprehensive systematic review. *Front Oncol.* 2021;11:640000.
- [16] Shinseki K, Takahashi M, Kushima A, Nakamoto T, Wakata M, Nakajima T, et al. One case of accessory breast cancer complicated by contralateral breast cancer. *Gan To Kagaku Ryoho.* 2020;47(12):1703-05.
- [17] Sikdar O, Roy M, Al-Ishaq Z, Shinde V, Sircar T. A rare case of primary carcinoma of axillary accessory breast tissue. *J Surg Case Rep.* 2021;2021(10):rjab473. Doi: 10.1093/jscr/rjab473. PMID: 34691386; PMCID: PMC8531245.

PARTICULARS OF CONTRIBUTORS:

1. Postgraduate Student, Department of General Surgery, Mahatma Gandhi Medical College and Research Institute, Puducherry, India.
2. Professor, Department of General Surgery, Mahatma Gandhi Medical College and Research Institute, Puducherry, India.

NAME, ADDRESS, E-MAIL ID OF THE CORRESPONDING AUTHOR:

VM Vinoth Vaithiya,
245/1, Vasanth Surgical Clinic, Sivagangai Road, M.Malampatti, Melur, Madurai,
Tamil Nadu, India.
E-mail: vaithiya44@gmail.com

AUTHOR DECLARATION:

- Financial or Other Competing Interests: None
- Was informed consent obtained from the subjects involved in the study? Yes
- For any images presented appropriate consent has been obtained from the subjects. Yes

PLAGIARISM CHECKING METHODS: [Jain H et al.]

- Plagiarism X-checker: Mar 04, 2022
- Manual Googling: Jul 25, 2022
- iThenticate Software: Sep 16, 2022 (10%)

ETYMOLOGY: Author Origin

Date of Submission: **Feb 25, 2022**
Date of Peer Review: **Apr 13, 2022**
Date of Acceptance: **Jul 27, 2022**
Date of Publishing: **Oct 01, 2022**