

Cone beam computed tomography indications for interdisciplinary therapy planning of impacted canines

Randi Lynds Ihlis,^{a,b} Christina Giovanos,^c Haihong Liao,^d Ingrid Ring,^e Olle Malmgren,^d Georgios Tsilingaridis,^e Daniel Benchimol,^f and Xie Qi Shi^{a,g}

Objective. To investigate how cone beam computed tomography (CBCT) affects the therapeutic planning of impacted maxillary canines.

Study Design. A total of 132 impacted canines from 89 pediatric patients were collected from 3 specialist clinics in Stockholm, Sweden. An interdisciplinary therapy planning team consisting of 5 dental specialists evaluated each case and chose their preferred treatment alternative, initially without and later with CBCT images, to decide whether CBCT was justified for therapy planning. Predefined variables measurable using only 2-dimensional (2D) assessments were analyzed using stepwise logistic regression analyses.

Results. The CBCT was considered indicated in 47% of the cases. Additional information from CBCT led to a treatment decision change in 9.8%. Significant 2D predictors for CBCT justification were horizontal canine angulation compared with vertical angulation (odds ratio [OR] = 10.9), extraction strategy involvement (OR = 6.7), and buccally positioned canines compared with palatal (OR = 5.3), central (OR = 25.0), and distal or uncertain positions (OR = 7.7).

Conclusions. The benefit-risk assessment of CBCT for impacted canines may be reinforced by performing and applying justification decisions for CBCT acquisition at the therapeutic thinking level. If preliminary treatment planning motivates further in-depth investigation of either root status or tooth location, a CBCT is indicated. (Oral Surg Oral Med Oral Pathol Oral Radiol 2022;000:e1–e9)

Cone beam computed tomography (CBCT) is widely used in dentistry, providing detailed information of hard tissues in 3 dimensions (3D).^{1–3} The most common indication for CBCT examinations in adolescent patients is impacted maxillary canines (IMCs).^{4,5} The radiation dose of CBCT, however, is much higher than that of conventional 2D radiographs.^{6,7} There are currently concerns, especially regarding children, that CBCT examinations are being performed routinely on orthodontic patients, even when unjustified.⁸ From a perspective of radiation protection, considering the risks that radiation entails is especially important regarding pediatric patients, who are ≥ 3 times as

radiosensitive as adults.⁹ Therefore, justification and optimization of CBCT use are essential and regulated by international guidelines.

Maxillary canines that are embedded in the alveolus, unable to erupt at an appropriate time in the dental arch, are considered impacted.¹⁰ The prevalence of IMC is approximately 2% but varies among different ethnicities.^{11,12} Studies on orthodontic patients have shown that this condition appears more frequently in females.¹³ Palatal impactions are more common in Caucasian populations, whereas buccal impactions are more common in Asian populations.^{14,15} Early diagnosis and swift interventional treatment result in a better prognosis for these canines reaching their correct position.^{14,16} A missed diagnosis or delayed treatment results in 48% of patients developing root resorption of permanent adjacent incisors, which, in turn, creates a need for future treatments, including orthodontic alignment, surgical exposure, and extrusion of the canine, extractions, or even implants.^{17,18}

^aDepartment of Clinical Dentistry, University of Bergen, Bergen, Norway.

^bRegion Dalarna and the Center for Clinical Research, Association with Uppsala University, Falun, Uppsala, Sweden.

^cPrivate practice, Stockholm, Sweden.

^dHuddinge Specialistklinik, Huddinge, Sweden.

^eDivision of Orthodontics and Paediatric Dentistry, Department of Dental Medicine, Karolinska Institutet, Huddinge, Sweden.

^fDivision of Oral Diagnostics and Rehabilitation, Department of Dental Medicine, Karolinska Institutet, Huddinge, Sweden.

^gFaculty of Odontology, Malmö University, Malmö, Sweden.

Corresponding author: Randi Lynds Ihlis. E-mail address: Randi.LyndsIhlis@regiondalarna.se

Received for publication Apr 8, 2022; returned for revision Jun 13, 2022; accepted for publication Jun 24, 2022.

© 2022 The Author(s). Published by Elsevier Inc. This is an open access article under the CC BY license (<http://creativecommons.org/licenses/by/4.0/>)

2212-4403/\$-see front matter

<https://doi.org/10.1016/j.oooo.2022.06.013>

Statement of Clinical Relevance

Cone beam computed tomography examinations entail a higher dose level than intraoral or panoramic radiographs and may not always be necessary for therapeutic planning. With more clearly defined indications, the dose burden of cone beam computed tomography examinations intended for impacted maxillary canines can be limited.

The canines' positions are first assessed based on clinical examinations. If an unerupted maxillary canine cannot be located by palpation by 10 to 11 years of age, or if root resorptions on adjacent teeth are suspected, conventional 2D radiographs consisting of periapical intraoral radiographs in 2 different projections and panoramic images should be taken to visualize the relationship between the canine and adjacent teeth.² A limitation of these 2D radiographs is that maxillary canines are often superimposed or overlap the incisor's root, making possible resorption difficult to assess in the bucco-palatal plane. The literature has suggested that approximately half of existing root resorptions are overlooked when clinicians rely solely on 2D images for their discovery.¹⁹⁻²¹ Thus, when 2D radiographs cannot provide enough necessary diagnostic information, the current European guidelines recommend supplementing with a CBCT examination.^{9,22,23} Though CBCT has obvious diagnostic advantages, such as information about canine-induced root resorptions (CIRRs), there is no strong evidence to support using CBCT as the first choice of imaging modality when assessing impacted canines.^{9,24,25}

Little is known about the efficiency of CBCT on therapy planning and, ultimately, the outcome of treatment for patients with impacted canines. Most of the studies that investigate CBCT and IMC are limited at the level of technical and diagnostic efficiency of CBCT.^{1,26-32} Although understanding CBCT indications on different levels of efficacy is important and has been described, few studies have been performed on the therapeutic thinking level.³³ Furthermore, these studies have conflicting conclusions and are based solely on orthodontic decision making.^{24,27,29,34}

This study aimed to (1) investigate how CBCT affects the treatment plan of patients with impacted canines and (2) identify possible clinical and 2D imaging markers for the justified CBCT examination at the therapeutic thinking level.

MATERIALS AND METHODS

Ethical considerations

The regional ethics review boards in Stockholm, Sweden (Dnr: 2013/1701-31/3, Dnr: 2015/24232, and Dnr 2020-00676), and in Bergen, Norway (Dnr: 77310), approved the study protocol.

Case selection and data collection

This study is a retrospective cohort study, conforming to STROBE (STrengthening the Reporting of OBServational studies in Epidemiology) guidelines. All CBCT examinations regarding potential IMC were consecutively collected from 3 specialist clinics in Stockholm, Sweden. These clinics were Karolinska Institutet (2009-2012), Folk tandvården Eastman Institutet

(2009-2014), and Huddinge Specialistklinik (2012-2019).

Inclusion and exclusion criteria

To be included, the cases were required to have CBCT examinations due to maxillary canine impaction, clinical photos, and a panoramic radiograph taken within a 9-month cutoff period before the CBCT date. All of the additional periapical intraoral radiographs and cephalograms taken within the same cutoff period were also included. After the initial screening, 170 patients met the inclusion criteria. The exclusion criteria were patients with craniofacial syndromes, cleft lip/palate, odontomas, cysts, previous traumatic dental injuries, or ongoing orthodontic treatment as well as patients with improper journal documentation. In total, 81 patients were excluded because of these factors or suboptimal radiographic 2D/3D material.

A total of 132 impacted canines from 89 cases fulfilled the inclusion and exclusion criteria. A description of the patients included in this study can be seen in Table 1. The following information was collected for each patient: sex, date of birth, anamnesis, uni- or bilateral impaction, acquisition date of all radiographs, and clinical photos.

CBCT units

Material for the 2D radiographic analysis was imported to Planmeca Romexis research database software version 3.8.3.R (Planmeca, Helsinki, Finland) at Karolinska Institutet. The CBCT volumes were exported and viewed with each respective unit's software viewer. The CBCT units used to obtain all 3D volumetric data were the Promax3D (Planmeca, Helsinki, Finland), the Veraviewepocs 3D R100/F40 (J. Morita Mfg. Corp., Tokyo, Japan), and NewTom 3G (Quantitative Radiology s.r.l., Verona, Italy). The clinical default settings

Table 1. Patient characteristics.

Variable	Total	Male	Female
No. of patients, <i>n</i> (%)	89 (100)	34 (38)	55 (62)
Age at CBCT exposure (y):			
Mean (SD)	13.3 (1.8)	13.6 (1.7)	13.1 (1.8)
Range	10.0-18.9	10.8-17.4	10.0-18.9
Impactions, <i>n</i> (%)			
Total impactions	132 (100)	47 (36)	85 (64)
Unilateral	46 (52)	21 (62)	25 (45)
Bilateral	43 (48)	13 (38)	30 (55)
Time lag from PAN to CBCT, <i>n</i> (%)			
≤1 mo	44 (49)	18 (41)	26 (59)
>1-3 mo	27 (30)	7 (26)	20 (74)
>3-6 mo	13 (15)	7 (54)	6 (46)
>6-9 mo	5 (6)	2 (40)	3 (60)

CBCT, cone beam computed tomography; PAN, panoramic radiograph.

for each CBCT device were used at each respective clinic at that time of exposure, adjusted for individual patient size and age.

Radiographic assessment

Before the therapeutic planning, 2 dentomaxillofacial radiologists jointly performed the radiographic assessment for all 2D images. After a time lag of 6 months, the same assessment was done for all of the 3D images. The radiologists were blinded at the patient level and did not have access to CBCT images during the 2D evaluation. The images were viewed under identical viewing conditions consisting of a dimly-lit room, a 19-in screen with 1280 × 1024 resolution (Eizo Flexscan, model MX190, EIZO Nanao Corporation, Hakui, Ishikawa, Japan), and a Digital Imaging and Communications in Medicine (DICOM) screen display, calibrated as described by Barten.³⁵ The radiologists were free to adjust the image quality to their individual preferences and completed the assessment with no time limit.

Assessment protocols 2D and 3D

The protocol used for the radiographic assessment consisted of the following radiographic variables, as summarized in a supplemental document: Canine eruption angulation, canine cusp position, root development stage, presence of root resorption on the lateral incisor, the distance of the medial position of the impacted canine's crown from the midline, the angle between the canine midline and the maxillary midline, the angle between the canine midline and the adjacent lateral incisor, the distance between the canine cusp tip and the occlusal line, and the presence of anomalies.^{36,37}

Interdisciplinary therapeutic planning

For each case ($n = 89$), a pair of PowerPoint v16 (Microsoft Corp., Redmond, WA) presentations were made. The first presentation consisted of the patient's age, sex, anamnesis, clinical photos, and registered diagnostic information based on the 2D radiographs. The second presentation included the referral information in addition to the patient information listed above and registered diagnostic information found on CBCT images. All of the cases were evaluated by an interdisciplinary expert group, consisting of the 2 radiologists who performed the initial assessment as well as 2 orthodontists and a pedodontist, each with 10+ years of experience in their specialty.

To ensure familiarity with the cases, the 2D evaluation PowerPoints were distributed to the individual members of the expert group a week before the group discussion. During the group discussion, the interdisciplinary experts were gathered together and all 2D PowerPoints were presented by R.L.I. The expert group

held a discussion and then completed a questionnaire consisting of treatment plan choices. A treatment plan was formed based on consensus, according to the following predefined treatment alternatives:

- No surgical exposure therapies: Nonextraction, extraction of the adjacent premolar, or extraction of the maxillary lateral incisor
- Surgical exposure with extrusion therapies: Nonextraction, extraction of the adjacent premolar, or extraction of the maxillary lateral incisor
- Therapies involving extraction only: The impacted maxillary canine or the deciduous canine
- Other alternatives: Observation or none of the other therapy alternatives.

The group then selected from the following orthodontic approaches following the therapy choice: expansion and leveling, space closure and leveling, or not relevant.

Immediately after the 2D assessment, the second PowerPoint was presented to the expert group by R.L.I. and volumetric images were demonstrated for the group by the dentomaxillofacial radiologists. The expert group held another discussion and completed the same questionnaire as above, and in an additional questionnaire ranked the level of CBCT indication on the following scale: 1 = definitely not indicated, 2 = probably not indicated, 3 = uncertain, 4 = probably indicated, or 5 = definitely indicated.

Statistical analysis

The mean values with SDs and ranges were presented for the continuous variables, and the frequencies and percentages were presented for the categorical variables, based on the number of CBCT examinations that were deemed justified after viewing the CBCT, as well as to observe when the therapy plan differed between 2D images and 3D images. Crude logistic regression models were performed to identify when CBCT was considered justified by evaluating statistically significant clinical, radiographic, or therapy-based variables based on the 2D therapy discussion. To identify whether multiple variables were statistically significant associated with cases that had a CBCT indication, a stepwise logistic regression model was performed. The stepwise regression was applied to avoid overfitting the adjusted model including nonsignificant variables. The cutoffs for age was set to 13 years, the angulation of the canine to the midline at 33.5°, the angulation to the lateral incisor to 42.5°, and the distance of the canine cusp to the occlusal line of the maxilla to 13.2 mm. Regarding CBCT justification, definitely not indicated and probably not indicated answers were seen as CBCT not being justified, and unsure, probably

indicated, and definitely indicated were seen as CBCT being justified. In this model, the significance level for entering a variable was set to .15, and the significance for removing the variable from the model was set to .3. Because 43 patients had bilateral impaction, robust variance estimates adjusting for the bilaterality were used in the logistic regression analyses. In the logistic regressions, only the patients with complete data for the included variables were used for the estimation. Hence, the number of included patients varied slightly.

The statistical analyses were performed using the statistical package Stata v17 (Stata Corp., College Station, TX USA). *P* values <.05 were considered statistically significant.

RESULTS

The mean age of the 89 included patients was 13.3 ± 1.8 years (range, 10.0-18.9 years). Of these patients, 55 were female (61.8%) and 34 were male (38.2%).

Effect of CBCT on therapeutic thinking

The panel found an indication for CBCT in 62 of the 132 impacted canines based on the 3D material (47%). The therapy choice changed for 13 of 132 impacted teeth after additional diagnostic information from 3D imaging (9.8%). Of these, the therapy changed from nonextractions to extraction therapy in 6 cases. Additionally, 6 cases changed from extracting premolars to extracting lateral incisors or the impacted canine. In 1 case, the therapy changed from extracting the impacted canine to extracting the central incisor. All 13 cases of changed therapy resulted in a final therapy choice involving the extraction of a permanent tooth, and the root status of adjacent incisors was essential for the choice of extraction.

Prediction of CBCT at the therapeutic thinking level

The descriptive data based on ordinal data as well as the continuous data for CBCT indication are provided in Tables 2 and 3, respectively.

The eruption angle of the canine, canine crown position, root development stage, severity of CIRR, extraction therapy, and the medial position of the canine crown were significant predictors for CBCT indication in the crude regression analyses ($P < .05$, Table 4). The crude analyses showed that impacted canines with a horizontal angulation had a 26 times higher odds for CBCT compared with impacted canines with the normal/vertical position ($P = .006$), whereas the odds were 10.9 times higher in the adjusted model. When the cusp of the canine was located buccal, there was a 5.3 times higher likelihood that a CBCT was needed compared to palatally placed canines, but the spread of the OR was large. If the extraction strategy was

Table 2. Descriptive information of categorical variables.

Predicted variables	CBCT not indicated, n (%)	CBCT indicated, n (%)
Patient-related predictors		
Sex		
Male	49 (58.3)	35 (41.7)
Female	28 (58.3)	20 (41.7)
Uni- or bilateral IMC		
Unilateral	21 (27.3)	56 (72.7)
Bilateral	25 (45.5)	30 (54.5)
2D radiographic predictors		
Eruption angulation of canine		
Normal/vertical	12 (66.7)	6 (33.3)
Mesioangular	64 (64.0)	36 (36.0)
Horizontal	1 (7.1)	13 (92.9)
Canine crown position		
Central	6 (66.7)	3 (33.3)
Buccal	9 (29.0)	22 (71.0)
Palatal	36 (72.0)	14 (28.0)
Uncertain/distal	26 (61.9)	16 (38.1)
Root development stage		
Ongoing/open apex	28 (65.1)	15 (34.9)
Apex closure/completely developed	43 (61.4)	27 (38.6)
Uncertain	6 (31.6)	13 (68.4)
Severity of CIRR		
None	13 (36.1)	23 (63.9)
Mild	10 (58.8)	7 (41.2)
Moderate, deep, or uncertain	54 (68.4)	25 (31.6)
Medial position of the canine crown		
Distal to the lateral incisor	6 (37.5)	10 (62.5)
Distal ½ of the lateral incisor	16 (51.6)	15 (48.4)
Mesial ½ of the lateral incisor	29 (70.7)	12 (29.3)
Mesial to the lateral incisor	26 (59.1)	18 (40.9)
Therapy-related predictors		
Extraction therapy of permanent teeth		
Yes	12 (23.5)	39 (76.5)
No	65 (80.2)	16 (19.8)
Space management		
Leveling/irrelevant	40 (58.0)	29 (42.0)
Expansion	29 (74.4)	10 (25.6)
Closure	8 (33.3)	16 (66.7)

CBCT, cone beam computed tomography; IMC, impacted maxillary canine; 2D, 2-dimensional; CIRR, canine-induced root resorption.

involved in the therapy planning, the OR was 6.7 in the adjusted model. When the severity of the CIRR was moderate, deep, or uncertain, a significantly lower odds was found in both the crude and adjusted models compared to “none” (OR = 0.26 and 0.12, respectively).

DISCUSSION

This study aimed to derive evidence that may contribute to guidelines clarifying clinical situations where CBCT is considered beneficial for both clinicians and pediatric patients with IMC. Based on the interdisciplinary evaluation, more than half of the cases did not have a justified indication for CBCT, implying that

Table 3. Descriptive information of continuous variables.

Predicted variables	CBCT not indicated	CBCT indicated
Patient-related predictors		
Age (y)		
Mean (SD)	13.2 (1.9)	13.0 (1.6)
Median (range)	13.1 (10.0-18.9)	12.7 (10.3-16.4)
2D radiographic predictors		
Angulation of canine eruption to midline*		
Mean (SD)	33.4° (14.1°)	40.3° (22.4°)
Median (range)	33.1° (1.8°-74.0°)	35.0° (2.8°-94.0°)
Angulation of canine eruption to lateral incisor*		
Mean (SD)	39.2° (14.5°)	48.8° (21.7°)
Median (range)	40.0° (0.1°-75.0°)	47.5° (4.0°-103.0°)
Distance in millimeters of cusp to occlusal line of maxilla†		
Mean (SD)	12.8 mm (4.0 mm)	14.7 mm (4.9 mm)
Median (range)	12.5 (3.1-26.2 mm)	13.8 (5.6-32.1 mm)

*The variable contains missing data of 1 tooth.

†The variable contains missing data of 7 teeth.

CBCT, cone beam computed tomography; IMC, impacted maxillary canine; 2D, 2-dimensional.

more than half of the CBCT exams may not have been necessary for treatment decision making. A large percentage of cases included in this material were not seen to have required a CBCT for therapy planning. This may partially be due to the material being collected before 2012 from 2 clinics, because clearly established European clinical guidelines for the use of CBCT in the case of IMC were published in 2012.⁹

There is currently no consensus over whether diagnostic information obtained from 2D images and 3D images leads to a different treatment plan. Haney et al. studied therapy plans decided by 4 orthodontists considering 25 impacted canines and found a change in therapy plan in 27% of the teeth, suggesting that CBCT examinations influence orthodontic therapy planning.²⁷ Christell et al. surveyed 112 orthodontists regarding 12 cases of IMC and found that CBCT examinations changed therapy planning 25% of the time.²⁴ Botticelli et al. showed similar results of more active orthodontic treatment following 3D image sets of 39 impacted

Table 4. Crude and stepwise regression analysis of 2D session variables for CBCT indication.

Predicted variables	Crude		Stepwise	
	OR (95% CI)	P value	OR (95% CI)	P value
Patient-related predictors				
Sex				
Male	1	ref		
Female	1.00 (0.41-2.43)	.999		
Uni- or bilateral IMC				
Unilateral	1	ref		
Bilateral	0.45 (0.19-1.05)	.065		
Age (y)	0.81 (0.34-1.94)	.640		
2D radiographic predictors				
Eruption angulation of canine				
Vertical	1	ref	1	ref
Mesioangular	1.12 (0.34-3.76)	.848	1.56 (0.42-5.79)	.504
Horizontal	26.00 (2.54-266.55)	.006	10.92 (1.65-72.42)	.013
Canine crown position				
Central	0.20 (0.05-0.85)	.03	0.04 (0.01-0.26)	.001
Buccal	1	ref	1	ref
Palatal	0.16 (0.05-0.47)	.001	0.19 (0.04-0.98)	.047
Uncertain/distal	0.25 (0.08-0.77)	.016	0.13 (0.03-0.53)	.005
Root development stage				
Ongoing/open apex	1	ref	1	ref
Apex closure/completely developed	1.39 (0.54-3.61)	.494	2.79 (0.62-12.50)	.181
Uncertain	4.33 (1.06-17.72)	.041	5.69 (0.68-47.74)	.109
Severity of CIRR				
None	1	ref	1	ref
Mild	0.40 (0.10-1.60)	.192	0.22 (0.01-3.82)	.295
Moderate, deep, or uncertain	0.26 (0.10-0.69)	.007	0.12 (0.03-0.52)	.005
Medial position of the canine crown				
Distal to the lateral incisor	1	ref		
Distal ½ of the lateral incisor	0.56 (0.14-2.23)	.413		
Mesial ½ of the lateral incisor	0.25 (0.06-0.97)	.045		
Mesial to the lateral incisor	0.42 (0.11-1.61)	.204		
Angulation of canine eruption to lateral incisor	2.05 (0.99-4.22)	.052		
Distance in millimeters of cusp to occlusal line of maxilla	1.94 (0.89-4.22)	.093		

(continued)

Table 4. Continued

Predicted variables	Crude		Stepwise	
	OR (95% CI)	P value	OR (95% CI)	P value
Therapy-related predictors				
Extraction therapy of permanent teeth				
Yes	1	ref	1	ref
No	0.08 (0.03-0.22)	< .001	0.15 (0.04-0.58)	.006
Space management				
Leveling/irrelevant	1	ref	1	ref
Expansion	0.48 (0.17-1.33)	.158	0.58 (0.14-2.45)	.458
Closure	2.76 (0.79-9.63)	.112	2.11 (0.38-11.62)	.392

Eruption angle of the canine, canine crown position, root development stage, severity of canine-induced root resorption, extraction therapy, and space management, all with a *P* value <.05 in the ordinary adjusted model, were considered as variables in the stepwise multivariable prediction model for cone beam computed tomography indication.

2D, 2-dimensioal; CBCT, cone beam computed tomography; OR, odds ratio; IMC, impacted maxillary canine; CIRR, canine-induced root resorption.

canines based on 8 dentists who had not completed their postgraduate orthodontic education.²⁹ In an earlier CT study of 113 impacted canines with 1 orthodontist, the 3D information influenced the extraction strategy, often resulting in a different tooth being chosen for extraction than in the original plan based on 2D images alone.²⁰ In contrast, Algerban et al. demonstrated, in a study based on 4 orthodontists' analyses of 40 patient cases, that CBCT did not significantly influence the therapy plan for impacted canines, which the results of this study also supported.³⁴ None of these studies had an interdisciplinary approach, however, and differing experiences or opinions among observers may affect result interpretation.

A significant 2D radiographic predictor for CBCT justification was a panoramic image providing a rough estimation that the impacted canine has a horizontal angulation. Such canines or canines located in an unfavorable position, high up in the hard palate, are difficult to assess with only 2D radiographs. In the case of canine extraction, surgeons often require an exact localization of the tooth in order to know the most appropriate site for surgical access before surgical removal or surgical exposure, and deciphering this using intraoral images is of little use because of the unfavorable position of the tooth. A CBCT provides information about the exact position of the canine in relation to surrounding vital anatomic structures, such as the nasal cavity, root apices, and the foramen incisivum. A CBCT not only helps the clinician determine the most appropriate surgical access site, but it also provides vital information about the proximity to other anatomic structures of interest, possible ankylosis, or complicated root morphology (e.g., dilacerated roots).³⁸

Buccally placed canines had higher odds than canines placed in other positions that a CBCT was needed for therapy decision making, with a 5.3 times higher

risk compared with palatally placed canines. Our results were in agreement with previous studies in which root resorption on adjacent incisors was reported to be 33% to 50% due to buccally displaced teeth.^{15,39}

Preliminary therapy planning involving extraction of permanent teeth increased the need for CBCT. Simultaneously, root resorptions of the lateral incisors were only an issue when knowledge of the suspected resorption's location and degree was essential for extraction strategy planning and suspected resorption was not seen in the 2D images (Figures 1 and 2). Requesting information about root resorptions is not always indicated for further therapy planning. When the preliminary therapy plan involves possible permanent tooth extraction based on 2D radiographs, alertness to root resorptions is important, and this diagnostic information should be requested in referrals.

The analysis of different angles measured in the panoramic image was not significant. The angulation of canine eruption in relation to the focal trough, patient position, and head alignment may complicate angle measurement interpretation. Caution should therefore be taken when interpreting angulations because the panorama technique is sensitive to patient placement.⁴⁰

This study was based on interdisciplinary virtual case discussions, which closed possible knowledge gaps between disciplines. The management of patients with impacted canines often involves communication between the orthodontists and dentomaxillofacial radiologists, as well as pediatric dental surgeons. The involved disciplines have their own perspectives when evaluating whether CBCT is needed. Though radiologists understand the strength and limitations of different radiologic modalities well, they need to know what diagnostic information is expected and essential for the treatment when performing a benefit-risk assessment. The expected diagnostic information from either

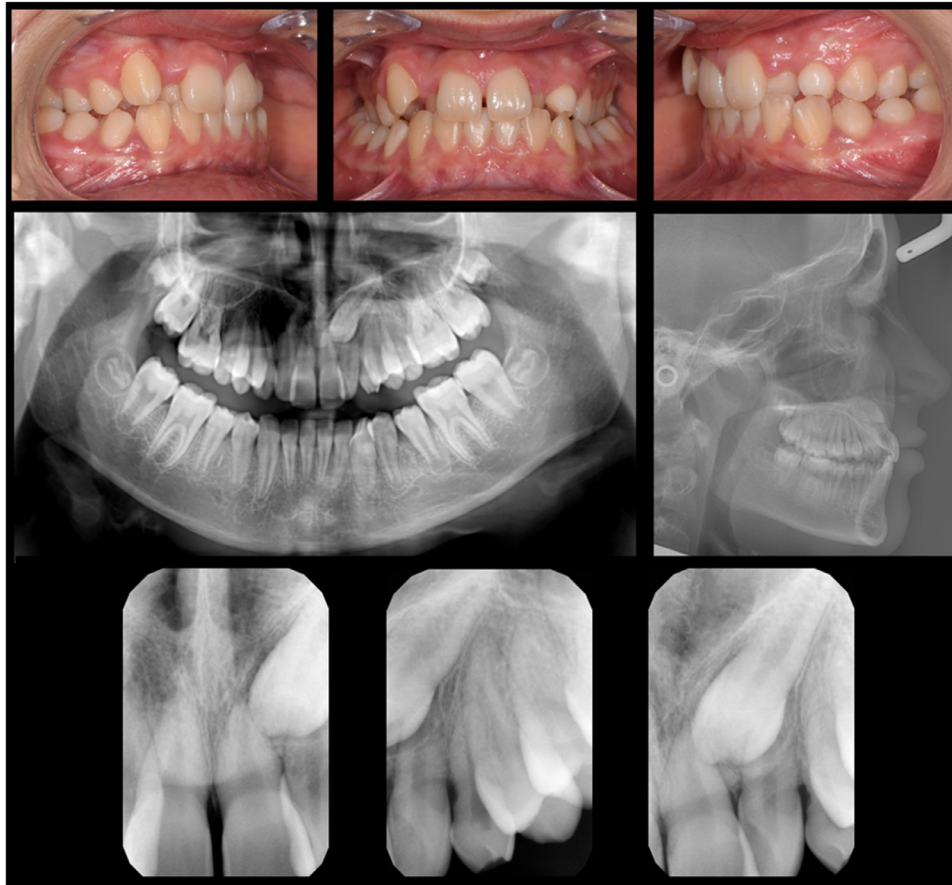


Fig. 1. A case example of 2-dimensional information available for the preliminary therapy planning and the first session. Clinical photos, a panoramic image, a cephalometric image, and 4 intraoral images were available in this case. The preliminary therapy plan was nonextraction and surgical exposure and extrusion of tooth 23. The specialists determined this case to have an indication for a cone beam computed tomography evaluation because of suspected root resorption that would be critical to a successful orthodontic treatment.

orthodontists or pediatric dental surgeons varies depending on the preliminary treatment plan based on 2D imaging. Therefore, the interdisciplinary approach in the present study ensured the best possible decision-making outcome regarding CBCT indications. Based on the results, we recommend that preliminary therapy planning involving extraction of permanent teeth be addressed in the referral along with the reasons for CBCT request, such as localization of the impacted canine/investigation of possible root resorption. Because the prescription of CBCT should preferably be based on the future treatment plan, the referrals should be ordered by the clinician who plans and will carry out the treatment.

Our results indicated that performing a justification process at the treatment decision level can reinforce the benefit-risk assessment of CBCT examinations. In doing so, the importance of referral content and effective collaboration between different specialties is emphasized.

Limitations

A limitation of this study was the retrospective nature of the study design, because the image quality of the 2D images could not be standardized; thus, the diagnostic efficiency of 2D imaging might have been underestimated. A larger prospective study in which more uniform images are obtained, containing qualified intraoral radiographs using the parallax technique, could improve the validity of the results.

CONCLUSIONS

1. The benefit-risk assessment of CBCT for impacted canines may be reinforced by performing and applying justification decisions for CBCT acquisition at the therapeutic thinking level.
2. When knowledge of root resorptions or canine location is essential for deciding an extraction strategy after preliminary 2D treatment planning, a CBCT is indicated. However, when extraction of permanent

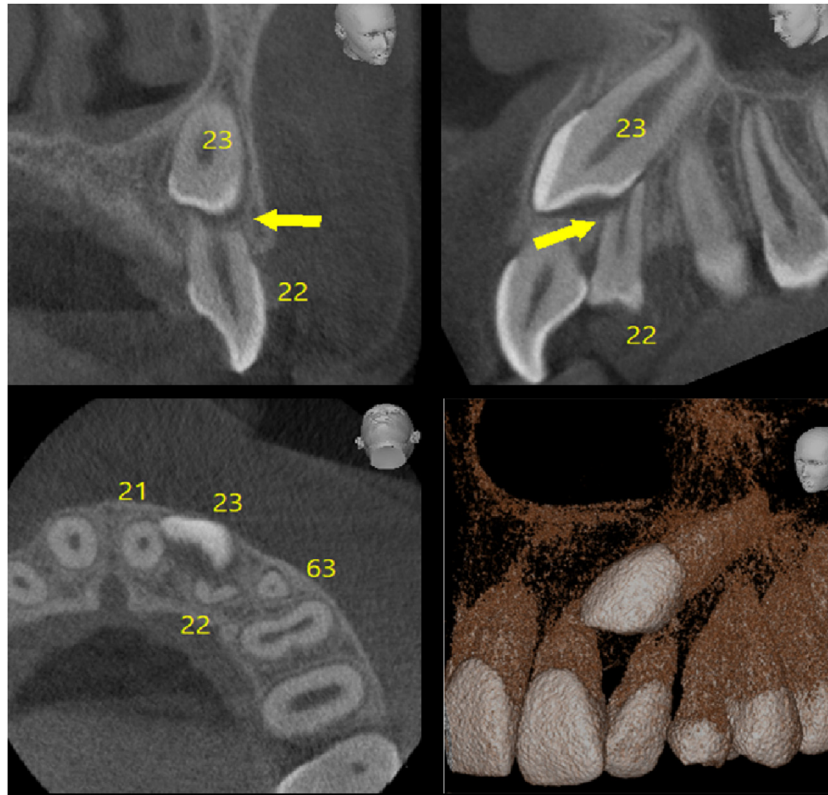


Fig. 2. The cone beam computed tomography image of the same case seen in Figure 1, depicting slices from the coronal, sagittal, and axial planes. After additional cone beam computed tomography information, the therapy for this case changed from surgical exposure and extrusion of tooth 23 without any permanent tooth extractions to extraction of tooth 22 in addition to extrusion. Tooth 23 is located buccal to tooth 22. The lateral incisor's resorption is deep.

teeth is not an alternative for the orthodontic treatment, a CBCT is not indicated to elucidate root status.

ACKNOWLEDGMENTS

The authors thank Eastman Institute Folk tandvården Stockholm, Karolinska Institutet, and Huddinge Specialist Clinic for providing patient information.

DISCLOSURES

None.

FUNDING

This work was financed by Folk tandvården Dalarna and the Center for Clinical Research of Dalarna in Sweden, the Stockholm County Council of Sweden (ALF project), the Steering Committee at Karolinska Institutet and Stockholm County Council for Odontology Research (SOF project), and Norway's Research Council (NFR).

PRESENTATION

Preliminary results of this study were presented at the International Congress of DentoMaxilloFacial

Radiology in Gwangju, South Korea, in April 2021 and the Odontologisk Riksstämman, a national dental conference in Stockholm, Sweden, in November 2021, both in the form of an oral presentation.

SUPPLEMENTARY MATERIALS

Supplementary material associated with this article can be found in the online version at [doi:10.1016/j.oooo.2022.06.013](https://doi.org/10.1016/j.oooo.2022.06.013).

REFERENCES

1. Alqerban A, Jacobs R, Fieus S, Willems G. Comparison of two cone beam computed tomographic systems versus panoramic imaging for localization of impacted maxillary canines and detection of root resorption. *Eur J Orthod*. 2011;33:93-102.
2. Ericson S, Kurol J. Radiographic examination of ectopically erupting maxillary canines. *Am J Orthod Dentofacial Orthop*. 1987;91:483-492.
3. Ericson S, Kurol J. Incisor root resorptions due to ectopic maxillary canines imaged by computerized tomography: a comparative study in extracted teeth. *Angle Orthod*. 2000;70:276-283.
4. Hidalgo Rivas JA, Horner K, Thiruvengkatchari B, Davies J, Theodorakou C. Development of a low-dose protocol for cone beam CT examinations of the anterior maxilla in children. *Br J Radiol*. 2015;88:20150559.

5. Hajem S, Brogardh-Roth S, Nilsson M, Hellen-Halme K. CBCT of Swedish children and adolescents at an oral and maxillofacial radiology department. A survey of requests and indications. *Acta Odontol Scand.* 2020;78:38-44.
6. Theodorakou C, Walker A, Horner K, et al. Estimation of paediatric organ and effective doses from dental cone beam CT using anthropomorphic phantoms. *Br J Radiol.* 2012;85:153-160.
7. Kadesjo N, Lynds R, Nilsson M, Shi XQ. Radiation dose from x-ray examinations of impacted canines: cone beam CT vs two-dimensional imaging. *Dentomaxillofac Radiol.* 2018;47:20170305.
8. Smith BR, Park JH, Cederberg RA. An evaluation of cone-beam computed tomography use in postgraduate orthodontic programs in the United States and Canada. *J Dent Educ.* 2011;75:98-106.
9. European Commission. Radiation protection no. 172: conebeam CT for dental and maxillofacial radiology. Evidence based guidelines. (The SEDENTEXTCT project). Available at: <https://ec.europa.eu/energy/sites/ener/files/documents/172.pdf>. Accessed March 26, 2022.
10. Bjerklin K. Orthodontic management of impacted maxillary canines. *APOS Trends Orthod.* 2020;10:64-71.
11. Kramer RM, Williams AC. The incidence of impacted teeth. A survey at Harlem Hospital. *Oral Surg.* 1970;29:237-241.
12. Thilander B, Myrberg N. The prevalence of malocclusion in Swedish schoolchildren. *Scand J Dent Res.* 1973;81:12-21.
13. Chaushu S, Kaczor-Urbanowicz K, Zadurska M, Becker A. Predisposing factors for severe incisor root resorption associated with impacted maxillary canines. *Am J Orthod Dentofacial Orthop.* 2015;147:52-60.
14. Peck S, Peck L, Kataja M. Site-specificity of tooth agenesis in subjects with maxillary canine malpositions. *Angle Orthod.* 1996;66:473-476.
15. Sajjani AK, King NM. Prevalence and characteristics of impacted maxillary canines in Southern Chinese children and adolescents. *J Investig Clin Dent.* 2014;5:38-44.
16. Kuroi J. Impacted and ankylosed teeth: why, when, and how to intervene. *Am J Orthod Dentofacial Orthop.* 2006;129(4 suppl):S86-S90.
17. Ericson S, Kuroi PJ. Resorption of incisors after ectopic eruption of maxillary canines: a CT study. *Angle Orthod.* 2000;70:415-423.
18. Barlow ST, Moore MB, Sherriff M, Ireland AJ, Sandy JR. Palatally impacted canines and the modified index of orthodontic treatment need. *Eur J Orthod.* 2009;31:362-366.
19. Ericson S, Kuroi J. Incisor resorption caused by maxillary cuspids. A radiographic study. *Angle Orthod.* 1987;57:332-346.
20. Bjerklin K, Ericson S. How a computerized tomography examination changed the treatment plans of 80 children with retained and ectopically positioned maxillary canines. *Angle Orthod.* 2006;76:43-51.
21. Dagsuyu IM, Kahraman F, Oksayan R. Three-dimensional evaluation of angular, linear, and resorption features of maxillary impacted canines on cone-beam computed tomography. *Oral Radiol.* 2018;34:66-72.
22. De Grauwe A, Ayaz I, Shujaat S, et al. CBCT in orthodontics: a systematic review on justification of CBCT in a paediatric population prior to orthodontic treatment. *Eur J Orthod.* 2019;41:381-389.
23. Oenning AC, Jacobs R, Pauwels R, et al. Cone-beam CT in paediatric dentistry: DIMITRA project position statement. *Pediatr Radiol.* 2018;48:308-316.
24. Christell H, Birch S, Bondemark L, Horner K, Lindh C, Consortium S. The impact of cone beam CT on financial costs and orthodontists' treatment decisions in the management of maxillary canines with eruption disturbance. *Eur J Orthod.* 2018;40:65-73.
25. Eslami E, Barkhordar H, Abramovitch K, Kim J, Masoud MI. Cone-beam computed tomography vs conventional radiography in visualization of maxillary impacted-canine localization: a systematic review of comparative studies. *Am J Orthod Dentofacial Orthop.* 2017;151:248-258.
26. Alqerban A, Jacobs R, Fieuws S, Willems G. Predictors of root resorption associated with maxillary canine impaction in panoramic images. *Eur J Orthod.* 2016;38:292-299.
27. Haney E, Gansky SA, Lee JS, et al. Comparative analysis of traditional radiographs and cone-beam computed tomography volumetric images in the diagnosis and treatment planning of maxillary impacted canines. *Am J Orthod Dentofacial Orthop.* 2010;137:590-597.
28. Guerrero ME, Shahbazian M, Elsiens Bekkering G, Nackaerts O, Jacobs R, Horner K. The diagnostic efficacy of cone beam CT for impacted teeth and associated features: a systematic review. *J Oral Rehabil.* 2011;38:208-216.
29. Botticelli S, Verna C, Cattaneo PM, Heidmann J, Melsen B. Two- versus three-dimensional imaging in subjects with unerupted maxillary canines. *Eur J Orthod.* 2011;33:344-349.
30. Wriedt S, Jaklin J, Al-Nawas B, Wehrbein H. Impacted upper canines: examination and treatment proposal based on 3D versus 2D diagnosis. *J Orofac Orthop.* 2012;73:28-40.
31. Alqerban A, Hedesiu M, Baciut M, et al. Pre-surgical treatment planning of maxillary canine impactions using panoramic vs cone beam CT imaging. *Dentomaxillofac Radiol.* 2013;42:20130157.
32. Baccetti T, Leonardi M, Armi P. A randomized clinical study of two interceptive approaches to palatally displaced canines. *Eur J Orthod.* 2008;30:381-385.
33. Fryback DG, Thornbury JR. The efficacy of diagnostic imaging. *Med Decis Making.* 1991;11:88-94.
34. Alqerban A, Willems G, Bernaerts C, Vangastel J, Politis C, Jacobs R. Orthodontic treatment planning for impacted maxillary canines using conventional records versus 3D CBCT. *Eur J Orthod.* 2014;36:698-707.
35. Barten P. *Contrast Sensitivity of the Human Eye and Its Effects on Image Quality*. Bellingham, WA: SPIE Press; 1999.
36. Jawad Z, Carmichael F, Houghton N, Bates C. A review of cone beam computed tomography for the diagnosis of root resorption associated with impacted canines, introducing an innovative root resorption scale. *Oral Surg Oral Med Oral Pathol Oral Radiol.* 2016;122:765-771.
37. Ericson S, Kuroi J. Early treatment of palatally erupting maxillary canines by extraction of the primary canines. *Eur J Orthod.* 1988;10:283-295.
38. Alqerban A, Jacobs R, van Keirsbilck PJ, et al. The effect of using CBCT in the diagnosis of canine impaction and its impact on the orthodontic treatment outcome. *J Orthod Sci.* 2014;3:34-40.
39. Knight H. Tooth resorption associated with the eruption of maxillary canines. *Br J Orthod.* 1987;14:21-31.
40. Granlund CM, Lith A, Molander B, Grondahl K, Hansen K, Ekstubby A. Frequency of errors and pathology in panoramic images of young orthodontic patients. *Eur J Orthod.* 2012;34:452-457.