Calcified Tissue International (2021) 108:528–538
https://doi.org/10.1007/s00223-021-00838-z

REVIEW

The Role of Bone Biopsy in the Management of CKD-MBD

Ana Carina Ferreira[1,2] · Martine Cohen-Solal[3,4] · Patrick C. D'Haese[5] · Aníbal Ferreira[1,2] on behalf of the European Renal Osteodystrophy (EUROD), an initiative of the CKD-MBD working group of the ERA-EDTA

Received: 17 February 2021 / Accepted: 11 March 2021 / Published online: 26 March 2021
© The Author(s), under exclusive licence to Springer Science+Business Media, LLC, part of Springer Nature 2021

Abstract
A bone biopsy is still considered the gold standard for diagnosis of renal osteodystrophy. It allows to measure both static and dynamic parameters of bone remodeling and is the only method able to evaluate mineralization and allows analysis of both cortical and trabecular bone. Although bone volume can be measured indirectly by dual-energy X-ray absorptiometry, mineralization defects, bone metal deposits, cellular number/activity, and even turnover abnormalities are difficult to determine by techniques other than qualitative bone histomorphometry. In this review, we evaluate the role of bone biopsy in the clinical practice.

Keyword Bone histomorphometry · Dialysis · Renal osteodystrophy

Introduction

Chronic kidney disease (CKD) has systemic complications, including the development of bone disorders, also known as renal osteodystrophy (ROD). ROD is a component of the mineral and bone disturbances related to CKD, the CKD-mineral and bone disorders (CKD-MBD) syndrome [1]. This syndrome is almost universal in stage 5 CKD patients and has important consequences, such as high mortality, cardiovascular disease, and fractures [2].

In 2006, a group of experts implemented a definition of the CKD-MBD, under the umbrella of Kidney Disease Improving Global Outcomes (KDIGO). For the first time, a broader concept was accepted, including (1) mineral and endocrine abnormalities of calcium, phosphorous, parathyroid hormone (PTH), or vitamin D metabolism; (2) abnormalities of bone related to turnover, mineralization, volume, linear growth, or strength; and (3) extra-skeletal calcifications [1]. These three components of CKD-MBD syndrome interact with one another, and bone disease maintained a central role in the definition as it impacts on extra-osseous calcifications and on continued laboratory abnormalities.

Treating ROD is of utmost importance in halting the progression of vascular calcifications associated with CKD-MBD syndrome and reversing its high mortality. Correct diagnosis of the ROD abnormality is essential for its correct treatment, as the latter depends on the type of bone disease. To be absolutely sure of what we are treating, in many situations, a bone biopsy should be performed, as we don't have, at the present time, reliable biomarkers or feasible imaging methods to access bone quality and/or quantity.

We recognize that, during the last few decades, because of its relative invasiveness, the study of undecalcified bone biopsies has decreased abruptly. Today, there are only a few centers in the world still performing bone biopsies and performing quantitative bone histomorphometric analysis to support the treatment of uremic patients. This is in line with the revised KDIGO guidelines launched in 2017 where experts put forward their opinion that bone biopsies should be performed if the diagnosis impacts treatment [3], which to a certain extent is in contrast to the guidelines published in 2009 stating that a bone biopsy should be performed in at least five situations (multiple fractures, unexplained hypercalcemia or hypophosphatemia, suspected aluminum toxicity or before osteoporosis treatment) [4].

✉ Ana Carina Ferreira
carina.ferreira@fcm.unl.pt

1 Nephrology Department, Centro Hospitalar e Universitário de Lisboa Central, Rua da Beneficência no. 8, 1050-099 Lisbon, Portugal

2 Nova Medical School, Nova University, Lisbon, Portugal

3 Bioscar, INSERM u1132, Paris, France

4 Hopital Lariboisiere, Université de Paris, 75010 Paris, France

5 Laboratory of Pathophysiology, Department of Biomedical Sciences, University of Antwerp, Antwerp, Belgium

Interestingly, in a recent survey conducted among European nephrologists with focus on bone biopsy-based diagnosis of ROD, histomorphometric analysis was considered relevant and useful, in several clinical situations [5]. Unfortunately, the same survey identified many significant difficulties and operational limitations that explain the decline in the number of bone biopsies performed nowadays, especially the cost of histopathological analysis (with insufficient reimbursement) and the lack of centers with sufficient expertise [5].

In the present review, we discuss if an invasive diagnosis in uremic patients, through a non-decalcified bone biopsy procedure, is still relevant for the diagnosis of mineral and bone disorders. In addition to evaluating the usefulness of a bone biopsy in uremic patients, we will also discuss the most relevant difficulties and limitations frequently ascribed to this invasive approach.

Bone Biopsy

Bone is composed of two components: inorganic mineralized bone and organic matrix, or osteoid. Both components are remodeled approximately within a three-month cycle through the recruitment and activation of osteoblasts and osteoclasts [6]. Briefly, resorption of bone is a function of osteoclasts; formation of new bone is a task of osteoblasts, and osteocytes control both processes. It is a dynamic process, controlled by hormones and physical factors. It is important to note that bone architecture is composed of a cortical or compact zone and a trabecular or spongy zone. While mechanical function of the bone is mainly dependent on cortical bone representing almost 80% of the total human bone mass [7], metabolic activity mainly takes place within the trabecular bone compartment.

In CKD, the remodeling process is frequently altered (too much or too little resorption and formation), and delayed mineralization and abnormal volume are documented. All these modifications of the bone phenotype have been associated with fractures, bone pain, vascular calcification, or even death [8].

To have complete information on a patient's bone health, we should aim to have histomorphometric evaluation of both static and dynamic parameters. In order to evaluate the rate of bone formation and rate of mineral deposition (dynamic parameters), a label technique is necessary. In our institutions, tetracycline hydrochloride 500 mg, 12/12 h is prescribed for 3 days, 1 month, and 1 week or for 2 days beginning at 14 and 4 days before the bone biopsy and the biopsy is scheduled in line with this prescription.

In our institution, we give an intravenous analgesic and diazepam immediately before the biopsy. We obtain the fragment from the anterior iliac crest by manual puncture with local anesthesia. The procedure is well tolerated, not difficult to perform for a trained physician, and rarely associated with major complications. Following collection of the fragment, it should be fixed in 70% ethanol, followed by dehydration in 96 and 99.9% ethanol. This takes approximately 15 days during which the bone fragments, while fixed or dehydrated, should be sent to the dedicated hospital/laboratory to further process and the undecalcified bone biopsy should be analyzed. In fact, any physician can perform a bone biopsy after adequate training and then send the bone fragment, at room temperature, in a small hermetic bottle filled with ethanol.

After this initial process, the bone specimens are cleared with xylene and embedded in methyl methacrylate in the lab for a variable period of time, until a total solidification of the plastic is obtained. Serial decalcified 5 μm-thick sections are obtained and stained according to the protocol and experience of each laboratory. In our case, we perform routine staining with Masson–Goldner trichrome, Toluidine Blue, von Kossa, and acid phosphatase (osteoclasts) by histoenzymology techniques, and, if available, alkaline phosphatase (osteoblasts) for evaluation of static histomorphometric parameters. Additionally Perls (iron staining) and solochrome azurine (aluminum) staining can be prepared. Unstained 10 μm sections for fluorescent dynamic analysis are needed. In summary, sample collection and analysis require at least 4 weeks.

We expect a bone biopsy to provide information on all the abovementioned parameters: volume, turnover, mineralization, architecture, and cortical bone-related aspects, such as porosity or thickness. A bone biopsy provides highly valuable and in-depth information that is required for the patient's treatment. This technique remains the gold standard for ROD diagnosis since it (a) allows analysis of both cortical and trabecular bone, (b) gives information on static and dynamic parameters of bone turnover, and (c) is the only method able to assess mineralization. Nevertheless, there are limitations, as it (a) is an invasive procedure; (b) a one-shot vision at a time-point, (c) can be impaired by sampling errors; (4) is restricted by the time needed to complete the technique and analyze the sample, being a time-consuming process; and (5) expertise is needed not only in collecting and processing the bone fragments, but also in measuring the indices that will lead to an accurate diagnosis.

For years, nephrologists have been looking for markers or imaging tests as an alternative for the histomorphometric analysis of bone biopsies. To date, no other available technique provides the most relevant information for the management of CKD-MBD. We will discuss below the clinical conditions under which a bone biopsy provides a unique contribution and added value to diagnosis and treatment of CKD patients.

TMV Classification

The TMV classification (Turnover, Mineralization, Volume) described in 2006 [1] aimed to designate the quantity (volume) and the quality (turnover and mineralization) of the bone, although we acknowledge that other features of quality are also important, such as architecture and micro-damage (Fig. 1). Bone quantity and bone quality are responsible for bone strength, and bone strength correlates inversely with fracture risk.

Bone Volume

In CKD patients, bone quantity or volume can be low, normal, or high. Many patients have abnormalities in volume, not only as the presence of ROD is a risk factor for volume reduction in some patients, but also because CKD patients share many risk factors with non-uremic patients who have osteoporosis. This was elegantly reviewed elsewhere [9] and CKD patients with low volume were proposed to have "uremic" osteoporosis [9].

Various imaging tools are available to evaluate bone volume in CKD patients. Bone density is a measure of mineralized bone mass or quantity and is measured by dual-energy X-ray absorptiometry (DXA). The relevance of DXA in the evaluation of bone mass was recognized in the updated KDIGO 2017 guidelines [10]. In fact, this review recommends bone mineral density (BMD) evaluation by DXA in patients with CKD G3A to G5D, based on the growing evidence that DXA BMD can predict incident fractures in this population [11, 12] and also in transplanted patients [13].

Although it gives information only on bone volume, sequential DXA measurement can be useful to evaluate a trend in the quantity of bone gain or loss (with different therapies or pathological processes). The limitations of DXA are known: it does not discriminate between cortical and trabecular bone; neither does it provide any direct information on bone quality, namely, microarchitecture and micro-damage, fibrosis, or collagen organization [14]. However, microarchitecture of cortical and trabecular bone could be quantified in bone biopsies using quantitative computerized tomography (QCT) [15, 16]. DXA is also unable to determine bone turnover and, at most, it can indirectly provide information on the long-term effect of a low or high bone turnover on the bone quantity [17]. DXA is also unable to evaluate bone mineralization defects, which is a major limitation. For instance, a patient with severe osteomalacia can present a DXA bone density result similar to someone without impaired mineralization [18].

In addition to DXA, new non-invasive imaging diagnosis tools have become available. These include high-resolution peripheral quantitative computerized tomography (HR-pQCT) [19] and magnetic resonance imaging (MRI) [20] which allow separate measurement of cortical and trabecular volumetric BMD and geometry. The most reported is HR-pQCT, which is able to evaluate and quantify cortical and trabecular geometry, microarchitecture, and strength. Despite its very high image resolution capacity, it does not allow evaluation of bone turnover and bone mineralization; it is expensive and used predominantly for research purposes or in very small populations. Moreover, it does not add information for fracture prediction, when compared to DXA [21].

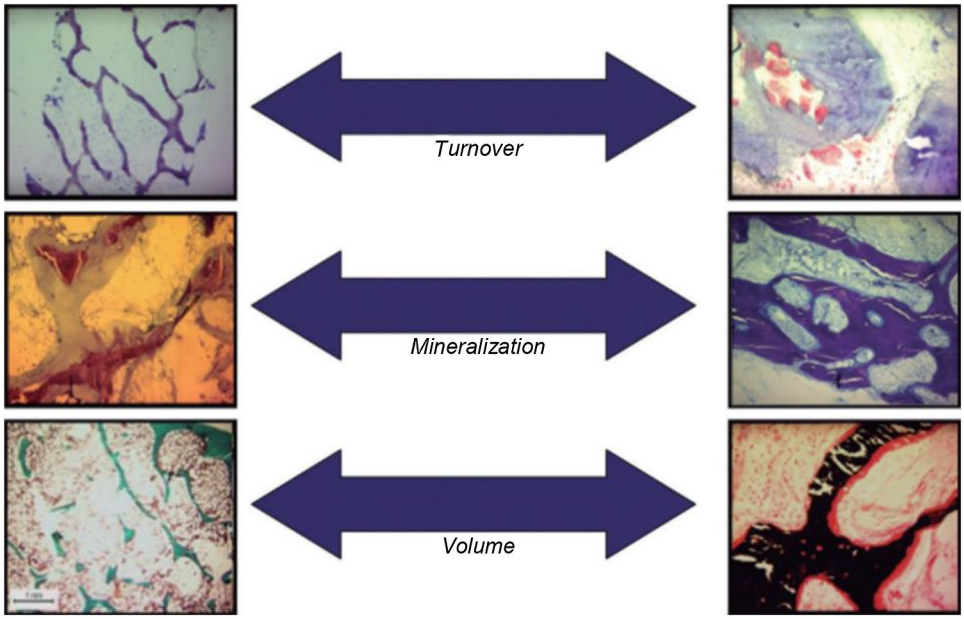

Fig. 1 TMV classification

Another innovative tool for predicting risk of fractures is the Trabecular Bone Score (TBS), a software-based tool that draws trabecular bone based on the DXA images. According to this software, the higher the TBS, the more compact the bone is [22]. Despite these new techniques, DXA remains the standard method for predicting fracture risk, although TBS seems to help predict non-vertebral fractures in dialysis patients [23].

In summary, we can assess bone volume using imaging tools. In our clinical practice, only DXA is widely available, but has many limitations. As stressed before, uremic patients experience fractures at 4 times higher incidence than the general population [24, 25], and fracture risk is even greater in kidney transplant patients [26, 27]. So, bone fragility in CKD patients is not restricted to bone volume. Consequently, none of these imaging methods give us information on turnover or mineralization, and so, neither one can be used individually to evaluate bone health in CKD.

In addition to all the other relevant information, histomorphometric bone biopsy analysis also allows to quantity the volume of bone in the fragment, and allows relating volume to turnover and mineralization in the same sample. We can provide information in a qualitative way, without calculations (primary parameters), or we can use semiautomatic techniques that will calculate the bone volume/total volume (BV/TV) (secondary parameters). These semiautomatic measure methods of analysis are able to easily quantify trabecular and cortical bone volume separately from each other. Low cortical bone volume is particularly relevant as a risk for bone fracture, in this population.

Bone Turnover

In CKD, bone turnover can either be low, normal, or high, and the extremes have been associated with extra-osseous calcifications and high mortality. These abnormal remodeling deviations are also responsible for changes in bone volume [9, 28]. Thus, in addition to fractures, it has been postulated that excess bone resorption on the one hand or low bone remodeling on the other hand are associated with vascular calcifications, which is thought to result from an increased efflux of calcium/phosphate from bone in the former case versus an impaired calcium apatite incorporation into the bone in the latter case, both of which result in increased deposition of the mineral content from skeletal system in the vessel wall [29].

How to determine bone turnover without performing a bone biopsy? The recently identified new players that participate in bone mineral metabolism in CKD patients, including sclerostin, klotho, and fibroblast growth factor 23 (FGF23) could help nephrologists in predicting skeletal activity [30]. On the one hand, there will be high levels of FGF23, low levels of vitamin D, and high levels of PTH, transforming the remodeling process in a high turnover bone disease. On the other hand, aside from the FGF23, RANK/RANKL/Osteoprotegerin system, also the sclerostin and Wingless-related integration site (Wnt)/beta-catenin system will be active and participate in a low bone turnover disease, along with the other known risk factors for low turnover, such as vigorous treatment of secondary hyperparathyroidism, diabetes, age, and the use of high-flux dialysis' membranes. Nevertheless, neither of those markers are available in clinical practice and their diagnostic accuracy still needs to be assessed. Nephrologists use non-invasive biochemical markers of bone formation/resorption to support clinical and therapeutic decisions. PTH and, in some centers, bone-specific alkaline phosphatase (BALP) are used in clinical practice to follow-up bone turnover status in uremic patients. Unfortunately, both lack sufficient sensitivity and specificity, as shown by Sprague and colleagues [31]. It has been also shown that whole PTH seems to offer minimal additional value in comparison with intact PTH, and that BALP alone was almost as good as when used in combination with intact PTH [31].

Studies evaluating the role of ^{18}F-NaF PET in accessing turnover [32] are ongoing, but more analyses are necessary in uremic patients.

Biochemical markers of bone formation and resorption transmit a dynamic but blurred video of the bone changes. Conversely, a bone biopsy, offers a sharp picture of the bone, at a particular moment. They are not mutually exclusive, and, in several situations, their information is clearly complementary [17, 18, 33]. Nevertheless, bone biopsy undoubtedly is the gold standard for assessing turnover. It remains the only technique able to quantify the activity of bone formation at the cellular and tissue level.

In the case of high bone turnover, the most typical bone findings in static histomorphometry are a significant increase in osteoblast and osteoclast number, which can be accompanied by an increased cancellous bone volume and a decrease in cortical bone volume in terms of cortical thinning and increased cortical porosity. The inter-trabecular fibrosis can be massive if secondary hyperparathyroidism is severe that can even compromise the bone marrow erythropoiesis. Usually, bone mineralization is normal, even though osteoid surface and even volume may be slightly increased, due to the accelerated bone formation process along with a delay in bone mineralization. In severe high turnover bone disease, osteoclast surface and osteoclast number are typically increased. Using a histochemical method to optimize the tartrate-resistant acid phosphatase expressed and secreted by osteoclasts, we can obtain an exuberant expression of these cells, when they are active, in the bone resorption process [34]. The complementary use of dynamic parameters makes the diagnosis of turnover abnormality more accurate.

At the opposite extreme of bone turnover, we find low turnover bone disease, with no osteoclasts and few osteoblast numbers, no osteoid formation, and, in extreme cases, features of an acellular bone. This low bone remodeling aspect, with low dynamic parameters when associated with low volume, is termed adynamic bone disease.

If we have a semiautomatic technique, the static parameters of osteoblast surface/bone surface (OBs/BS), and osteoclast surface/bone surface (Ocs/BS), osteoid surface/bone surface are provided, as are the dynamic parameters of mineral apposition rate (MAR) and the adjusted value, and bone formation rate (BFR), all important parameters to quantify bone turnover.

Bone Mineralization

Mineralization can be normal or compromised in CKD. Mineralization defects might be associated with low vitamin D, mineral deficiency (e.g., low phosphate levels), acidosis, and aluminum toxicity. Symptoms are very similar to those of hyperparathyroidism and no imaging technique or non-invasive biomarker is capable of ensuring the diagnosis of delayed mineralization. Recent findings have highlighted the importance of BALP in this diagnosis [35], as BALP is produced by osteoblasts and seems to be associated with osteoid quantity. Nevertheless, the variation of mineral indices such as calcium or phosphate levels and the high variability and non-specificity of serum biomarkers are limitations to rule out mineralization disorders that are crucial for the management and the treatment of ROD.

Bone biopsies allow the addressing of the mineralization defects that can be rapidly observed in severe cases, even with a qualitative analysis. Semiautomatic techniques can provide static parameters including osteoid thickness (OTh), osteoid volume/bone volume (OtV/BV), and dynamic parameters, as mineralization lag time (MLT).

Osteoporosis

In recent years, the relevance of CKD-associated osteoporosis has been growing as a new entity that should be included in CKD-MBD [9]. In fact, CKD-associated osteoporosis seems to have particular physio-pathological bone derangements and is associated with an increased fracture risk, morbidity, and mortality [36–38].

The main indication for a bone biopsy in CKD is spontaneous or low-energy trauma skeletal fractures, while biochemical markers of bone metabolism are within expected ranges or unexplained by severe hyperparathyroidism. In these cases, one expects to find reduced bone volume, bone turnover, or failure of mineralization. Any type of low or high bone turnover can be found in the presence of fracture. Hence no prospective study evaluated the prevalence of fractures as a function of the type of ROD and bone quality, or at the moment of the fracture occurrence. Two cross-sectional studies showed that dialysis patients with low bone turnover disease or osteomalacia had a higher annual rate of skeletal fractures compared to those with high bone turnover [39, 40]. A longitudinal study also reported a higher rate of fracture in patients with hyperparathyroidism in a small group of dialysis patients followed for 5 years [41].

In addition to fractures, bone pain and skeletal deformities observed at the pelvis or metaphyseal bones are signs of osteomalacia in conjunction with high spots in a bone scanning. Additionally, a patient's significant exposure to aluminum in the past should prompt the measurement of aluminum levels before parathyroidectomy. Low turnover bone disease with aluminum deposition may be precipitated after the parathyroidectomy if there is aluminum overload above 25% of the bone surface [42, 43]. Therefore, the presence of aluminum deposits in bone surfaces confirms the diagnosis of aluminum overload and/or mixed uremic osteodystrophy and is one of the best indications of bone biopsy.

The main issue is that fractures might be observed in low or normal bone mineral density and might be related to low bone turnover, whether osteomalacia or osteoporosis, as well as with secondary hyperparathyroidism. It is therefore crucial to determine the type of CKD-MBD and in particular to rule out a mineralization defect that will need specific management and to avoid the use of anti-osteoporotic treatment. This prompted the KDIGO to recommend a bone biopsy before the treatment is started in CKD patients with osteoporosis in 2006 [1]. Nevertheless, this recommendation was substituted in 2017 by other less restrictive, which includes a consideration of a bone biopsy [10]. However, without a bone biopsy, the physician cannot rule out a mineralization defect, in which a treatment directed for osteoporosis will not solve the problem.

The presence of severe secondary hyperparathyroidism or clinical or biochemical signs of osteomalacia will require specific treatment of the cause. Thus, anti-osteoporotic drugs will be considered in the case of osteoporosis, with low bone turnover or with PTH levels within the 2–9 times expected normal range. Available therapies include inhibitors of bone resorption such as bisphosphonates or Denosumab while Teriparatide or Romosozumab, the newly approved biotherapy, represents anabolic agents.

Osteoporosis in maintained or high bone resorption is better treated with the inhibitors of bone resorption. Noteworthy, bisphosphonates are associated to a modest increased risk of CKD progression in the general population [44], without increased mortality in CKD stages 3–4 [45]. Because bisphosphonates are cleared by the kidney, these agents accumulate and are stored in bone tissues and therefore bisphosphonates might promote or precipitate

mineralization defects and osteomalacia [46]. Hence, it is crucial to ensure the absence of mineralization disorders that could be aggravated.

These effects on mineralization should not be observed with Denosumab, although there is no histological study available. The FDA and EMA approved Denosumab for the treatment of osteoporosis, drug-induced bone loss, bone metastases, multiple myeloma and giant cell tumor of the bone. Denosumab inhibits RANKL, inhibits osteoclast differentiation and function, and thereby decreases bone resorption. Denosumab is mainly metabolized by the liver, is not excreted by the kidney, and does not appear to accumulate in renal failure. Post hoc analysis of the Freedom trial revealed that Denosumab is safe in osteoporotic women with CKD stage 2 and 3 and does not promote CKD progression, although hypocalcemia was reported in 3–6% of the patients [47]. In an open-label study carried out in 12 dialysis patients with severe secondary hyperparathyroidism who were treated during 6 months, bone mineral density increased by 23% at the femoral neck and by 17% at the lumbar spine [48].

More recently, a 12-month study with Denosumab has reported a higher increase in bone mineral density than Alendronate without changes in serum calcium and PTH [49]. Together, these studies show no evidence on the induction of mineralization compromise. However, the design of short-term treatment and the absence of follow-up do not rule out eventual long-term side effects in much more severe CKD patients.

In low bone turnover diseases, further inhibition of bone resorption with bisphosphonates or Denosumab will probably not improve the bone volume. Osteoanabolic agents are the most suitable approach for increasing bone volume and stimulating bone formation. This includes Teriparatide and the new approved Romososumab. Teriparatide and Abaloparatide are the two agents that activate the PTH pathway and are currently used for the management of osteoporosis.

Hyperparathyroidism in CKD leads to increased cortical porosity and to decreased cortical thickness, but with an increased trabecular volume in relation to cortical trabecularization. The effect of additional exogenous PTH in CKD patients is unknown. The half-life of Teriparatide is significantly prolonged in CKD stage 4 compared to CKD stage 2 or 3, but there is no accumulation in bone and Teriparatide is no longer detectable after 24 h [50]. Few trials have been performed to assess the effect of Teriparatide on CKD patients. A 6-month study in seven patients with low PTH showed an increase in spinal and femoral BMD [51]. Further clinical trial using Teriparatide should provide more insight about the efficacy and expected outcomes.

The bone biopsy in uremic patients with osteoporosis should be indicated prior to the use of Romosozumab and would also be of particular value to evaluate its safety and understand the mechanism of action at the bone level. Romosozumab is a monoclonal antibody against sclerostin, an osteocyte-secreted glycoprotein that inhibits osteoblast function, by blocking Wnt signaling pathways [52]. The anabolic effect of anti-sclerostin drug differs from the response to recombinant human PTH because, with the former, the initial increase in bone formation markers is followed by an increase in markers of bone resorption. In contrast, Romosozumab increased markers of bone formation, sustainably decreased markers of bone resorption, and significantly increased bone mineral density at the spine and hip in postmenopausal osteoporosis for a period of 12 months. Histomorphomeric analysis of bone biopsies revealed that Romosozumab promoted the reactivation of osteoblast lining cells to functional osteoblasts able to synthetize bone matrix [53]. The stimulation of Wnt signaling, which is altered in CKD, is particularly relevant in adynamic bone disease, a frequent subtype of ROD. Randomized clinical trials are needed for testing the efficacy in improving bone mass, reducing risk of fractures, and evaluating the safety and tolerability of Romosozumab in patients with CKD stage 4 or stage 5.

Caution should be taken because anti-sclerostin biotherapy could potentially induce, or aggravate, cardiovascular calcifications. Preliminary study showed no sign of acceleration of vascular or cardiac valve calcification after 3 years of treatment with Romosozumab in osteoporotic women [54]. However, a more recent study comparing the use of Romosozumab and Alendronate over a 12 months period, revealed a higher number of serious adverse events to the anti-sclerostin group (2.5% vs. 1.9%) [55] and a second study in osteoporotic men, a higher number of cardiovascular serious adverse events compared to placebo (4.9% vs. 2.5%) in a 12-month study [56], but this need to be addressed in this CKD population at high risk of calcification.

Data about sclerostin and its potential role in cardiovascular health in CKD patients is not consensual. Some studies showed a link between high levels of sclerostin and cardiovascular death [57, 58], whereas others a protective role of the protein [59, 60]. In CKD, sclerostin levels are higher than normal, and as the glycoprotein is an inhibitor of bone formation, some authors related its cardio-protective role to an inhibition of calcification in vessels. Other authors advocate that it can increase the calcification of vessels through a modification in bone turnover, defending a U-shaped association with mortality.

Bone Metal Deposits

Aluminum

Aluminum has long been used as a potent phosphate-binding agent. Minimal gastrointestinal absorption of daily therapeutic doses of this bone-seeking element may lead to skeletal

deposition of the element [61]. In addition, aluminum may enter the body parenterally during dialysis because of the use of aluminum-contaminated dialysis fluids [62]. Although replacement of aluminum-containing phosphate binders by safer alternatives and the introduction of adequate water treatment systems have significantly decreased the risk for accumulation of the element, toxic effects at the bone level cannot be ruled out in some areas of the globe. Aluminum accumulation in the bone results in particular forms of renal osteodystrophy, most notably osteomalacia and adynamic bone disease [63]. With the former bone disorder, the impaired mineralization has been associated with the deposition of aluminum at the osteoid-calcified bone boundary whereby the element acts as an inhibitor of hydroxyapatite formation/growth. Definite diagnosis of this type of bone lesion is made by histological demonstration of stainable aluminum at the mineralization front and should be considered in patients at risk of increased exposure [64]. The role of aluminum in the development of adynamic bone disease is subtler and is believed to occur via either a direct effect on osteoblastic activity or indirectly through its inhibitory effect on PTH secretion/synthesis [65, 66]. Chelation therapy with desferrioxamine results in improvements of clinical symptoms and bone histology [67].

Lanthanum

In the search for safer phosphate binders, lanthanum carbonate was developed two decades ago [68]. Strictly spoken, lanthanum is not a metal as it belongs to the rare earths. Given the fact that this element, to a certain extent, shows some physico-chemical characteristics similar to aluminum, concerns were initially raised as to whether it might exert deleterious effects on bone. Compared to aluminum, however, gastrointestinal absorption is one to two orders of magnitude less, and even after long-term use, accumulation of lanthanum in bone is minimal [69]. As demonstrated by synchrotron-based scanning X-ray micro-fluorescence, lanthanum, in contrast to aluminum, is not found at critical sites of bone mineralization and so far no serious effects on either bone mineralization and/or osteoblastic activity have been reported in lanthanum-treated dialysis patients [70–72]. As of yet, no procedure for histochemical bone biopsy staining of lanthanum is available. To which extent lanthanum in humans at the nanomolar levels at which it circulates may exert a direct isolated effect (i.e., independent of its phosphate-lowering effect) on PTH synthesis/secretion through its calcimimetic effect on the calcium-sensing receptor, as demonstrated in in vitro studies, needs to be evidenced further [73].

Iron

Iron must be considered a two-faced Janus as both overload or deficiency have been reported to cause bone disorders. Until the early nineties of the former century, before erythropoietin was available and CKD patients were receiving oral iron and blood transfusions, aluminum overload was frequently accompanied by iron overload and both elements often co-localized in bone, which made it difficult to evaluate bone histologic diagnoses, that might be solely attributable to iron [74]. Based on histological bone biopsy examination and both aluminum and iron specific staining, an association between iron overload and an increased frequency of adynamic bone disease was reported in dialysis patients [75]. A high frequency of iron bone deposits (61.4% out of 70 patients) as indicated by a positive Perl's staining at the mineralization front, was reported in a Mexican dialysis population in the absence of distinct aluminum overload which, however, could not be associated with a particular type of renal osteodystrophy [76]. Evidence has been presented from both clinical and experimental investigation that, because of the competition of both iron and aluminum for binding to transferrin, iron might affect the bone deposition/toxicity of aluminum [77]. Although in subjects with normal renal function both iron overload and iron deficiency have been associated with osteoporotic lesions, no evidence for such a relationship has been presented in CKD/ESKD patients [78]. Given the current therapeutic use of iron compounds for both the correction of anemia and for phosphate control the potential for bone effects should be considered during histological bone biopsy evaluation.

Magnesium

The role of magnesium in bone mineralization and in the pathogenesis of renal bone disease is still a matter of debate. An association between hypermagnesemia and the development of osteomalacia and/or renal osteodystrophy was first hypothesized some decades ago, based on (a) the element's calcimimetic effect on the calcium-sensing receptor and thus secretion/synthesis of PTH and (b) its ability to prevent mineralization and/or calcification [79, 80]. A cross-sectional observational study in which the concentrations of various trace metals were associated with bone biopsy failed to demonstrate a linkage with magnesium and any type of renal osteodystrophy including osteomalacia and adynamic bone disease [81]. Experimental studies evaluating the effect of therapeutic doses of magnesium as a phosphate binder and concomitant prevention of vascular calcification in CKD did not show any harmful effect on bone turnover [82]. As magnesium is a well-known essential element for multiple biological processes in the body, the potential for hypomagnesemia to exert deleterious effect on bone should

not be overlooked. In this respect it is worth mentioning that magnesium deficiency is likely to be an issue in osteoporosis as it is crucial for regulation of osteoblast and osteoclast function and activity in bone remodeling [82].

Strontium

From a physico-chemical point of view, strontium exerts strong similarities to calcium. Therefore, its potential to interact with bone metabolism is reasonably to be expected. While in patients with intact renal function, strontium as the ranelate compound is being used as an anti-osteoporotic agent, it is contra-indicated in patients with a GFR < 30 mL/min. Epidemiological studies indeed revealed that in CKD patients, in particular those treated by dialysis, strontium accumulates in the body [83]. Moreover, a bone biopsy-based study in 100 dialysis patients revealed increased bone strontium concentrations in patients with osteomalacia [84]. Rhodizonate staining histochemically identifies strontium in calcified bone, mainly in new-formed bone in close proximity to the mineralization front and surrounding the osteoid in animal models [85]. Experimental studies in 5/6th nephrectomized rats presented evidence for a causal role of the element in the development of osteomalacia and that the element may exert different effects on bone, depending on the dose used [86].

When to Perform a Bone Biopsy

The abovementioned makes it clear that turnover and mineralization are accessible through biopsy, and that serum markers, although important, do not reflect histological changes and findings in some clinical cases.

Besides other eventual indications for a bone biopsy, it is the authors' opinion that the following particular five situations are in need of a bone biopsy, in both uremic and kidney transplant patients, as the knowledge of the type of ROD in these five situations will impact treatment decisions:

1. Severe and disabling bone pain;
2. Fragility fractures (more than 2);
3. Before treatment of osteoporosis;
4. Before parathyroidectomy;
5. Fast progression of vascular calcification in a young patient

Conclusions

In our clinical practice, we perform kidney biopsies in our patients to guide treatment in the short and long term. Even without a semiautomatic method and without measurements, it is useful to have the qualitative evaluation of a bone biopsy. Normally, we don't need to count kidney cells in a kidney biopsy to come to a diagnosis. A similar approach would, eventually, be justified in many bone biopsies performed in uremic patients (with different degrees of chronic renal failure, on dialysis or after transplantation), because a qualitative analysis of the bone is often enough to begin the treatment of the patient.

Different and sometimes opposing therapeutic options are available for ROD treatment. Knowing the volume, allied with the turnover status, is important to decide if the patients need an osteoclast blocker, or instead a parathyroid supplementation. Also, the exclusion of mineralization abnormalities in case of severe bone pain and fractures is fundamental for therapeutic orientation. Treatment with new drugs that have a direct effect on bone cell activity, namely, osteoblasts and osteoclasts, underline the relevance of a clear picture of the expression of these cells, at least before beginning therapy, and this can only be obtained through performing a bone biopsy.

In a bone biopsy report, TMV quantitative classification gives the relevant information in a short period of time to the nephrologist, to support his/her therapeutic decisions. The nephrologist needs to know, as soon as possible, how to treat his patient, based on the information of the 3 TMV vectors: (1) Is the bone turnover low, normal, or high? (2) Is the mineralization normal or abnormal? and finally, (3) is the bone volume low, normal, or high? This does not necessary imply that a full histomorphometry of the biopsy should be performed and allows the clinician a faster answer [33]. Of course, a full bone histomorphometric analysis can always be performed later.

We hope to have convinced the reader that there are still some indications to perform a bone biopsy to evaluate bone volume, mineralization, turnover, architecture, and differences in cortical versus trabecular bone, to anticipate the fracture risk, optimizing therapy, and minimizing mortality risk in uremic patents.

Author Contributions AF had the idea for the article. ACF, MCS, PDH, and AF performed the literature search and data analysis. ACF, MCS, PDH, and AF drafted and/or critically revised the article.

Declarations

Disclosure Ana Carina Ferreira reports personal fees from Amgen and Viphor Pharma for giving lectures, outside the submitted work; Martine Cohen-Solal has no conflict of interest; Patrick C. D'Haese

reports research grants from Vifor Pharma, Inositec, Rockwell Medical, Sanifit, Fresenius Medical Care, Oxthera, Shire Pharmaceuticals, and Amgen, outside the submitted work; Aníbal Ferreira reports personal fees, grants, and participation in advisory boards from Abbvie, Astellas, Amgen, Baxter, Merck Sharp and Dhome, Mundipharma, Nephrocare-Fresenius Medical Care, Sanofi, and Vifor Pharma, outside the submitted work.

References

1. Moe S, Drueke T, Cunningham J et al (2006) Definition, evaluation, and classification of renal osteodystrophy: a position statement from kidney disease: improving global outcomes (KDIGO). Kidney Int 69:1945–1953
2. Vervloet MG, Massy ZA, Brandenburg VM et al (2014) Bone: a new endocrine organ at the heart of chronic kidney disease and mineral and bone disorders. Lancet Diabetes Endocrinol 2:427–436
3. Ketteler M, Block GA, Evenepoel P et al (2017) Executive summary of the 2017 KDIGO Chronic Kidney Disease-Mineral and Bone Disorder (CKD-MBD) Guideline Update: what's changed and why it matters. Kidney Int 92:26–36
4. Kidney Disease: Improving Global Outcomes CKDMBDWG (2009) KDIGO clinical practice guideline for the diagnosis, evaluation, prevention, and treatment of Chronic Kidney Disease-Mineral and Bone Disorder (CKD-MBD). Kidney Int Suppl 113:S1-130
5. Evenepoel P, D'Haese P, Bacchetta J et al (2017) Bone biopsy practice patterns across Europe: the European renal osteodystrophy initiative-a position paper. Nephrol Dial Transplant 32:1608–1613
6. Nandiraju D, Ahmed I (2019) Human skeletal physiology and factors affecting its modeling and remodeling. Fertil Steril 112:775–781
7. Carvalho C, Magalhaes J, Pereira L, Simoes-Silva L, Castro-Ferreira I, Frazao JM (2016) Evolution of bone disease after kidney transplantation: a prospective histomorphometric analysis of trabecular and cortical bone. Nephrology 21:55–61
8. Hruska KA, Sugatani T, Agapova O, Fang Y (2017) The chronic kidney disease: mineral bone disorder (CKD-MBD): advances in pathophysiology. Bone 100:80–86
9. Bover J, Bailone L, Lopez-Baez V et al (2017) Osteoporosis, bone mineral density and CKD-MBD: treatment considerations. J Nephrol 30:677–687
10. Kidney Disease: Improving Global Outcomes CKDMBDUWG (2017) KDIGO 2017 clinical practice guideline update for the diagnosis, evaluation, prevention, and treatment of chronic kidney disease-mineral and bone disorder (CKD-MBD). Kidney Int Suppl 7:1–59
11. Yenchek RH, Ix JH, Shlipak MG et al (2012) Bone mineral density and fracture risk in older individuals with CKD. Clin J Am Soc Nephrol 7:1130–1136
12. Iimori S, Mori Y, Akita W et al (2012) Diagnostic usefulness of bone mineral density and biochemical markers of bone turnover in predicting fracture in CKD stage 5D patients–a single-center cohort study. Nephrol Dial Transplant 27:345–351
13. Akaberi S, Simonsen O, Lindergard B, Nyberg G (2008) Can DXA predict fractures in renal transplant patients? Am J Transplant 8:2647–2651
14. Babayev R, Nickolas TL (2015) Bone disorders in chronic kidney disease: an update in diagnosis and management. Semin Dial 28:645–653
15. Dall'Ara E, Pahr D, Varga P, Kainberger F, Zysset P (2012) QCT-based finite element models predict human vertebral strength in vitro significantly better than simulated DEXA. Osteoporos Int 23:563–572
16. Benillouche E, Ostertag A, Marty C, Urena Torres P, Cohen-Solal M (2020) Cortical bone microarchitecture in dialysis patients. Am J Nephrol 51:833–838
17. Babayev R, Nickolas TL (2014) Can one evaluate bone disease in chronic kidney disease without a biopsy? Curr Opin Nephrol Hypertens 23:431–437
18. Torres PU, Bover J, Mazzaferro S, de Vernejoul MC, Cohen-Solal M (2014) When, how, and why a bone biopsy should be performed in patients with chronic kidney disease. Semin Nephrol 34:612–625
19. Nishiyama KK, Shane E (2013) Clinical imaging of bone microarchitecture with HR-pQCT. Curr Osteoporos Rep 11:147–155
20. Wehrli FW (2007) Structural and functional assessment of trabecular and cortical bone by micro magnetic resonance imaging. J Magn Reson Imaging 25:390–409
21. Jamal S, Cheung AM, West S, Lok C (2012) Bone mineral density by DXA and HR pQCT can discriminate fracture status in men and women with stages 3 to 5 chronic kidney disease. Osteoporos Int 23:2805–2813
22. Silva BC, Leslie WD, Resch H et al (2014) Trabecular bone score: a noninvasive analytical method based upon the DXA image. J Bone Miner Res 29:518–530
23. Aleksova J, Kurniawan S, Elder GJ (2018) The trabecular bone score is associated with bone mineral density, markers of bone turnover and prevalent fracture in patients with end stage kidney disease. Osteoporos Int 29:1447–1455
24. Daya NR, Voskertchian A, Schneider AL et al (2016) Kidney function and fracture risk: the atherosclerosis risk in communities (ARIC) study. Am J Kidney Dis 67:218–226
25. Alem AM, Sherrard DJ, Gillen DL et al (2000) Increased risk of hip fracture among patients with end-stage renal disease. Kidney Int 58:396–399
26. Evenepoel P, Claes K, Meijers B et al (2019) Bone mineral density, bone turnover markers, and incident fractures in de novo kidney transplant recipients. Kidney Int 95:1461–1470
27. Jadoul M, Albert JM, Akiba T et al (2006) Incidence and risk factors for hip or other bone fractures among hemodialysis patients in the Dialysis Outcomes and Practice Patterns Study. Kidney Int 70:1358–1366
28. Malluche HH, Monier-Faugere MC, Herberth J (2010) Bone disease after renal transplantation. Nat Rev Nephrol 6:32–40
29. Stompor T (2014) Coronary artery calcification in chronic kidney disease: an update. World J Cardiol 6:115–129
30. Schaffler MB, Cheung WY, Majeska R, Kennedy O (2014) Osteocytes: master orchestrators of bone. Calcif Tissue Int 94:5–24
31. Sprague SM, Bellorin-Font E, Jorgetti V et al (2016) Diagnostic accuracy of bone turnover markers and bone histology in patients With CKD treated by dialysis. Am J Kidney Dis 67:559–566
32. Blake GM, Puri T, Siddique M, Frost ML, Moore AEB, Fogelman I (2018) Site specific measurements of bone formation using [(18) F] sodium fluoride PET/CT. Quant Imaging Med Surg 8:47–59
33. Ferreira MA (2000) Diagnosis of renal osteodystrophy: when and how to use biochemical markers and non-invasive methods; when bone biopsy is needed. Nephrol Dial Transplant 15(Suppl 5):8–14
34. Galvao MJ, Santos A, Ribeiro MD, Ferreira A, Nolasco F (2011) Optimization of the tartrate-resistant acid phosphatase detection by histochemical method. Eur J Histochem 55:e1
35. Soeiro EMD, Castro L, Menezes R et al (2020) Association of parathormone and alkaline phosphatase with bone turnover and mineralization in children with CKD on dialysis: effect of age, gender, and race. Pediatr Nephrol 35:1297–1305

36. Pimentel A, Urena-Torres P, Zillikens MC, Bover J, Cohen-Solal M (2017) Fractures in patients with CKD-diagnosis, treatment, and prevention: a review by members of the European Calcified Tissue Society and the European Renal Association of Nephrology Dialysis and Transplantation. Kidney Int 92:1343–1355
37. Khairallah P, Nickolas TL (2018) Management of osteoporosis in CKD. Clin J Am Soc Nephrol 13:962–969
38. Pereira ABFJ (2020) Kidney-induced osteoporosis: a new entity with a novel therapeutic approach. Port J Nephrol Hypert 34:92–100
39. Araujo SM, Ambrosoni P, Lobao RR et al (2003) The renal osteodystrophy pattern in Brazil and Uruguay: an overview. Kidney Int Suppl 85:S54–S56
40. Piraino B, Chen T, Cooperstein L, Segre G, Puschett J (1988) Fractures and vertebral bone mineral density in patients with renal osteodystrophy. Clin Nephrol 30:57–62
41. Gerakis A, Hadjidakis D, Kokkinakis E, Apostolou T, Raptis S, Billis A (2000) Correlation of bone mineral density with the histological findings of renal osteodystrophy in patients on hemodialysis. J Nephrol 13:437–443
42. Andress DL, Ott SM, Maloney NA, Sherrard DJ (1985) Effect of parathyroidectomy on bone aluminum accumulation in chronic renal failure. N Engl J Med 312:468–473
43. Slatopolsky E (1987) The interaction of parathyroid hormone and aluminum in renal osteodystrophy. Kidney Int 31:842–854
44. Robinson DE, Ali MS, Pallares N et al (2020) Safety of oral bisphosphonates in moderate-to-severe chronic kidney disease: a bi-national cohort analysis. J Bone Miner Res. https://doi.org/10.1002/jbmr.4235
45. Alarkawi D, Ali MS, Bliuc D et al (2020) Oral bisphosphonate use and all-cause mortality in patients with moderate-severe (Grade 3B–5D) chronic kidney disease: a population-based cohort study. J Bone Miner Res 35:894–900
46. Rodd C (2001) Bisphosphonates in dialysis and transplantation patients: efficacy and safety issues. Perit Dial Int 21(Suppl 3):S256–S260
47. Broadwell A, Chines A, Ebeling PR et al (2021) Denosumab safety and efficacy among participants in the FREEDOM extension study with mild to moderate chronic kidney disease. J Clin Endocrinol Metab 106:397–409
48. Chen CL, Chen NC, Hsu CY et al (2014) An open-label, prospective pilot clinical study of denosumab for severe hyperparathyroidism in patients with low bone mass undergoing dialysis. J Clin Endocrinol Metab 99:2426–2432
49. Iseri K, Watanabe M, Yoshikawa H et al (2019) Effects of denosumab and alendronate on bone health and vascular function in hemodialysis patients: a randomized. Controlled Trial J Bone Miner Res 34:1014–1024
50. Hagino H, Narita R, Yokoyama Y, Watanabe M, Tomomitsu M (2019) A multicenter, randomized, rater-blinded, parallel-group, phase 3 study to compare the efficacy, safety, and immunogenicity of biosimilar RGB-10 and reference once-daily teriparatide in patients with osteoporosis. Osteoporos Int 30:2027–2037
51. Cejka D, Kodras K, Bader T, Haas M (2010) Treatment of hemodialysis-associated adynamic bone disease with teriparatide (PTH1-34): a pilot study. Kidney Blood Press Res 33:221–226
52. McClung MR, Grauer A, Boonen S et al (2014) Romosozumab in postmenopausal women with low bone mineral density. N Engl J Med 370:412–420
53. Chavassieux P, Chapurlat R, Portero-Muzy N et al (2019) Bone-forming and antiresorptive effects of romosozumab in postmenopausal women with osteoporosis: bone histomorphometry and microcomputed tomography analysis after 2 and 12 months of treatment. J Bone Miner Res 34:1597–1608
54. Padhi D, Jang G, Stouch B, Fang L, Posvar E (2011) Single-dose, placebo-controlled, randomized study of AMG 785, a sclerostin monoclonal antibody. J Bone Miner Res 26:19–26
55. Saag KG, Petersen J, Brandi ML et al (2017) Romosozumab or alendronate for fracture prevention in women with osteoporosis. N Engl J Med 377:1417–1427
56. Lewiecki EM, Blicharski T, Goemaere S et al (2018) A phase III randomized placebo-controlled trial to evaluate efficacy and safety of romosozumab in men with osteoporosis. J Clin Endocrinol Metab 103:3183–3193
57. Goncalves FL, Elias RM, dos Reis LM et al (2014) Serum sclerostin is an independent predictor of mortality in hemodialysis patients. BMC Nephrol 15:190
58. Qureshi AR, Olauson H, Witasp A et al (2015) Increased circulating sclerostin levels in end-stage renal disease predict biopsy-verified vascular medial calcification and coronary artery calcification. Kidney Int 88:1356–1364
59. Drechsler C, Evenepoel P, Vervloet MG et al (2015) High levels of circulating sclerostin are associated with better cardiovascular survival in incident dialysis patients: results from the NECOSAD study. Nephrol Dial Transplant 30:288–293
60. Viaene L, Behets GJ, Claes K et al (2013) Sclerostin: another bone-related protein related to all-cause mortality in haemodialysis? Nephrol Dial Transplant 28:3024–3030
61. Cournot-Witmer G, Zingraff J, Plachot JJ et al (1981) Aluminum localization in bone from hemodialyzed patients: relationship to matrix mineralization. Kidney Int 20:375–378
62. Nebeker HG, Coburn JW (1986) Aluminum and renal osteodystrophy. Annu Rev Med 37:79–95
63. Malluche HH (2002) Aluminium and bone disease in chronic renal failure. Nephrol Dial Transplant 17(Suppl 2):21–24
64. Faugere MC, Malluche HH (1986) Stainable aluminum and not aluminum content reflects bone histology in dialyzed patients. Kidney Int 30:717–722
65. Goodman WG (1985) Bone disease and aluminum: pathogenic considerations. Am J Kidney Dis 6:330–335
66. Smans KA, D'Haese PC, Van Landeghem GF et al (2000) Transferrin-mediated uptake of aluminium by human parathyroid cells results in reduced parathyroid hormone secretion. Nephrol Dial Transplant 15:1328–1336
67. Felsenfeld AJ, Rodriguez M, Coleman M, Ross D, Llach F (1989) Desferrioxamine therapy in hemodialysis patients with aluminum-associated bone disease. Kidney Int 35:1371–1378
68. Behets GJ, Verberckmoes SC, D'Haese PC, De Broe ME (2004) Lanthanum carbonate: a new phosphate binder. Curr Opin Nephrol Hypertens 13:403–409
69. Pennick M, Dennis K, Damment SJ (2006) Absolute bioavailability and disposition of lanthanum in healthy human subjects administered lanthanum carbonate. J Clin Pharmacol 46:738–746
70. Behets GJ, Dams G, Vercauteren SR et al (2004) Does the phosphate binder lanthanum carbonate affect bone in rats with chronic renal failure? J Am Soc Nephrol 15:2219–2228
71. Behets GJ, Verberckmoes SC, Oste L et al (2005) Localization of lanthanum in bone of chronic renal failure rats after oral dosing with lanthanum carbonate. Kidney Int 67:1830–1836
72. D'Haese PC, Spasovski GB, Sikole A et al (2003) A multicenter study on the effects of lanthanum carbonate (Fosrenol) and calcium carbonate on renal bone disease in dialysis patients. Kidney Int Suppl 85:S73–S78
73. Carrillo-Lopez N, Fernandez-Martin JL, Alvarez-Hernandez D et al (2010) Lanthanum activates calcium-sensing receptor and enhances sensitivity to calcium. Nephrol Dial Transplant 25:2930–2937

74. McCarthy JT, Hodgson SF, Fairbanks VF, Moyer TP (1991) Clinical and histologic features of iron-related bone disease in dialysis patients. Am J Kidney Dis 17:551–561
75. Van de Vyver FL, Visser WJ, D'Haese PC, De Broe ME (1990) Iron overload and bone disease in chronic dialysis patients. Nephrol Dial Transplant 5:781–787
76. Velasquez Forero F, Altamirano E, Ramos PT (1998) High frequency of iron bone deposits in a Mexican population with renal osteodystrophy. Nephrol Dial Transplant 13(Suppl 3):46–50
77. Van Landeghem GF, D'Haese PC, Lamberts LV, De Broe ME (1997) Competition of iron and aluminum for transferrin: the molecular basis for aluminum deposition in iron-overloaded dialysis patients? Exp Nephrol 5:239–245
78. Toxqui L, Vaquero MP (2015) Chronic iron deficiency as an emerging risk factor for osteoporosis: a hypothesis. Nutrients 7:2324–2344
79. Cunningham J, Rodriguez M, Messa P (2012) Magnesium in chronic kidney disease Stages 3 and 4 and in dialysis patients. Clin Kidney J 5:i39–i51
80. Navarro-Gonzalez JF, Mora-Fernandez C, Garcia-Perez J (2009) Clinical implications of disordered magnesium homeostasis in chronic renal failure and dialysis. Semin Dial 22:37–44
81. D'Haese PC, Couttenye MM, Lamberts LV et al (1999) Aluminum, iron, lead, cadmium, copper, zinc, chromium, magnesium, strontium, and calcium content in bone of end-stage renal failure patients. Clin Chem 45:1548–1556
82. Huang JH, Cheng FC, Wu HC (2015) Low magnesium exacerbates osteoporosis in chronic kidney disease patients with diabetes. Int J Endocrinol 2015:380247
83. Schrooten I, Elseviers MM, Lamberts LV, De Broe ME, D'Haese PC (1999) Increased serum strontium levels in dialysis patients: an epidemiological survey. Kidney Int 56:1886–1892
84. D'Haese PC, Schrooten I, Goodman WG et al (2000) Increased bone strontium levels in hemodialysis patients with osteomalacia. Kidney Int 57:1107–1114
85. Schrooten I, Cabrera W, Goodman WG et al (1998) Strontium causes osteomalacia in chronic renal failure rats. Kidney Int 54:448–456
86. Schrooten I, Behets GJ, Cabrera WE et al (2003) Dose-dependent effects of strontium on bone of chronic renal failure rats. Kidney Int 63:927–935

Publisher's Note Springer Nature remains neutral with regard to jurisdictional claims in published maps and institutional affiliations.