



TITLE:

# A Novel Real-time Navigation System for Lymphaticovenular Anastomosis Using Projection Mapping with Indocyanine Green Fluorescence

AUTHOR(S):

Tsuge, Itaru; Yamanaka, Hiroki; Seo, Satoru; Takada, Masahiro; Katsube, Motoki; Sakamoto, Michiharu; Toi, Masakazu; Hatano, Etsuro; Morimoto, Naoki

---

CITATION:

Tsuge, Itaru ...[et al]. A Novel Real-time Navigation System for Lymphaticovenular Anastomosis Using Projection Mapping with Indocyanine Green Fluorescence. *Plastic and Reconstructive Surgery - Global Open* 2021, 9(8): e3758.

ISSUE DATE:

2021-08

URL:

<http://hdl.handle.net/2433/277677>

RIGHT:

Copyright © 2021 The Authors. Published by Wolters Kluwer Health, Inc. on behalf of The American Society of Plastic Surgeons; This is an open-access article distributed under the terms of the Creative Commons Attribution-Non Commercial-No Derivatives License 4.0 (CCBY-NC-ND), where it is permissible to download and share the work provided it is properly cited. The work cannot be changed in any way or used commercially without permission from the journal.

# A Novel Real-time Navigation System for Lymphaticovenular Anastomosis Using Projection Mapping with Indocyanine Green Fluorescence

Itaru Tsuge, MD, PhD<sup>\*</sup>; Hiroki Yamanaka, MD, PhD<sup>\*</sup>; Satoru Seo, MD, PhD<sup>†</sup>; Masahiro Takada, MD, PhD<sup>‡</sup>;  
Motoki Katsube, MD, PhD<sup>\*</sup>; Michiharu Sakamoto, MD, PhD<sup>\*</sup>; Masakazu Toi, MD, PhD<sup>‡</sup>;  
Etsuro Hatano, MD, PhD<sup>†</sup>; Naoki Morimoto, MD, PhD<sup>\*</sup>

The medical imaging projection system (MIPS), which was developed based on a collaborative effort from Kyoto University, Panasonic Corporation (Osaka, Japan) and Mitaka Kohki Co., Ltd. (Tokyo, Japan), was first reported as a novel real-time surgical navigation imaging device that uses indocyanine green (ICG) emission signals and active projection mapping using a half mirror to match the optical axis of the camera and projector in the projection head.<sup>1</sup> The difference between the object and the projected image is within 1 mm, and the time lag is within 0.1 seconds.<sup>1</sup> Our project group reported its utility in segmental liver resection<sup>1,2</sup> and sentinel lymph node biopsy in breast cancer.<sup>3</sup> We applied the MIPS to lymphaticovenular anastomosis (LVA) surgery for upper extremity lymphedema to simplify the intraoperative cutaneous marking of lymphatic vessels.

The case was a 78-year-old woman who suffered from severe lymphedema of both upper extremities (stage II; International Society of Lymphology) caused by breast cancer surgeries and axial lymph resection. Under local anesthesia and consciousness sedation, multiple LVA surgery was performed. An intradermal injection of 0.1 ml of ICG (2.5 mg/ml Diagnogreen; Daiichi Sankyo Co., Tokyo, Japan) was administered at the second web space of the right hand. The MIPS showed a clear linear projection image on the back of the hand with blue to yellow color gradation (Fig. 1). A 1-cm skin incision and microsurgical dissection detected ICG-contrasted lymphatic vessels (See figure, Supplemental Digital Content 1, which shows the setting of the MIPS (A) and intraoperative findings from a surgical microscope (B), including a built-in ICG camera view (C); OPMI PENTERO 900; Carl Zeiss Meditec AG, Jena, Germany. <http://links.lww.com/PRSGO/B751>). The projected image smoothly followed the upper extremity movement when viewing the front and back sides of the upper extremities. Late-stage progressive lymphedema resulted in

diffuse or stardust patterns in the forearm and upper arm; however, the projection gain adjustment of the MIPS clarified the linear pattern in the cubital fossa (Fig. 2).

In LVA surgery, ICG lymphography requires macroscopic and microscopic surgical navigation. For microscopic navigation, a built-in ICG camera system shows the lymphatic vessels and their flow. Moreover, a recent ICG videlymphography system<sup>4</sup> and microscope-integrated laser tomography<sup>5</sup> have the potential to make LVA surgery more accurate and certain. However, for macroscopic ICG navigation, which is performed to detect the best position to make the skin incision and LVA for the whole area of an extremity, we still required a conventional ICG camera system (PDEneo; Hamamatsu Photonics Co., Ltd, Shizuoka, Japan) displayed on monitors, which means that surgeons must shift their vision between the surgical field and the monitor. This is the first report of the intraoperative use of ICG projection mapping for macroscopic surgical navigation to find and mark lymphatic vessels. The accuracy needs to be evaluated by multiple surgical results; however, the MIPS was capable of visualizing lymphatic vessels as linear images for real-time projection mapping navigation in the clinical setting.

Itaru Tsuge, MD, PhD

Department of Plastic and Reconstructive Surgery  
Graduate School of Medicine, Kyoto University  
54 Shogoin Kawahara-cho, Sakyou-ku  
Kyoto 606-8507  
Japan

E-mail: [itsuge@kuhp.kyoto-u.ac.jp](mailto:itsuge@kuhp.kyoto-u.ac.jp)

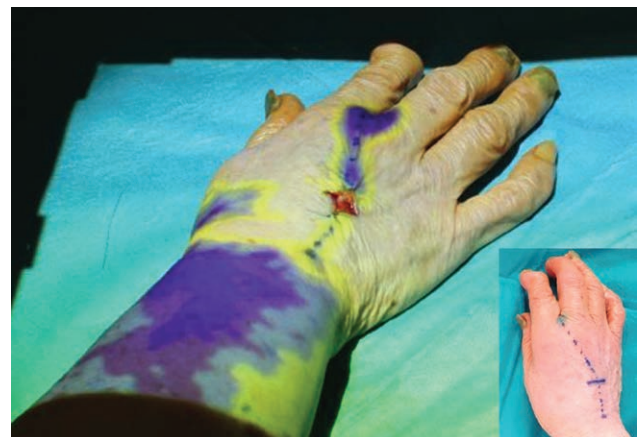

Fig. 1. Intraoperative projection mapping image of the MIPS. ICG fluorescence signals are projected onto the right hand with color gradation.

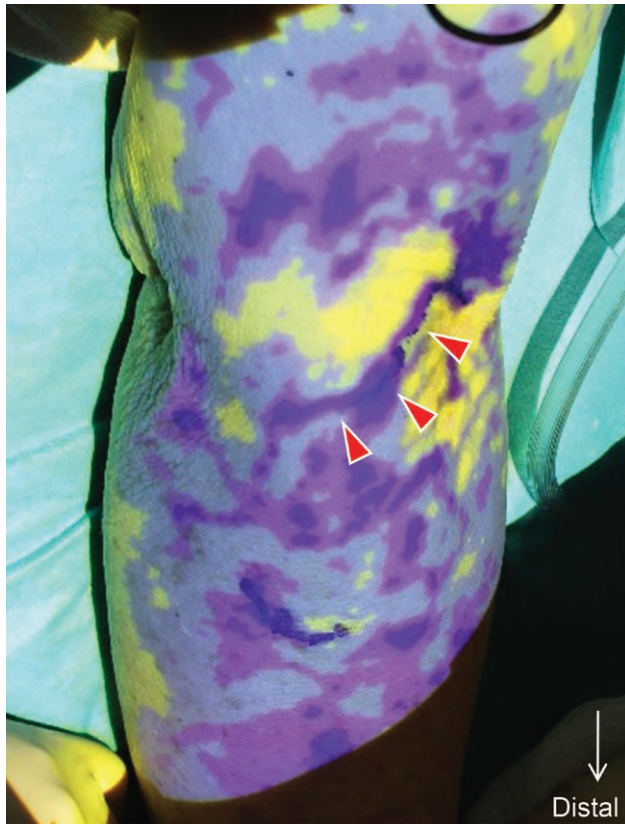
Related Digital Media are available in the full-text version of the article on [www.PRSGlobalOpen.com](http://www.PRSGlobalOpen.com).

From the <sup>\*</sup>Department of Plastic and Reconstructive Surgery, Graduate School of Medicine, Kyoto University, Kyoto, Japan; <sup>†</sup>Department of Surgery, Graduate School of Medicine, Kyoto University, Kyoto, Japan; and <sup>‡</sup>Department of Breast Surgery, Graduate School of Medicine, Kyoto University, Kyoto, Japan.

Received for publication June 15, 2021; accepted June 24, 2021.

Copyright © 2021 The Authors. Published by Wolters Kluwer Health, Inc. on behalf of The American Society of Plastic Surgeons. This is an open-access article distributed under the terms of the Creative Commons Attribution-Non Commercial-No Derivatives License 4.0 (CCBY-NC-ND), where it is permissible to download and share the work provided it is properly cited. The work cannot be changed in any way or used commercially without permission from the journal.

Plast Reconstr Surg Glob Open 2021;9:e3758; doi: [10.1097/GOX.0000000000003758](https://doi.org/10.1097/GOX.0000000000003758); Published online 16 August 2021.



**Fig. 2.** Projection mapping image of the MIPS on the right arm. Red arrowheads indicate the linear pattern in the cubital fossa, surrounded by diffuse and stardust patterns at the forearm and the upper arm.

### ACKNOWLEDGMENTS

The authors thank the Translational Research Network Program of the Japan Agency for Medical Research and Development and the Acceleration Transformative Research for Medical Innovation of the Japan Agency for Medical Research and Development.

### DISCLOSURE:

The authors have no financial interest to declare in relation to the content of this article.

### REFERENCES

1. Nishino H, Hatano E, Seo S, et al. Real-time navigation for liver surgery using projection mapping with indocyanine green fluorescence: development of the novel medical imaging projection system. *Ann Surg.* 2018;267:1134–1140.
2. Nishino H, Seo S, Hatano E, et al. What is a precise anatomic resection of the liver? Proposal of a new evaluation method in the era of fluorescence navigation surgery. *J Hepatobiliary Pancreat Sci.* 2021;28:479–488.
3. Takada M, Takeuchi M, Suzuki E, et al. Real-time navigation system for sentinel lymph node biopsy in breast cancer patients using projection mapping with indocyanine green fluorescence. *Breast Cancer.* 2018;25:650–655.
4. Seki Y, Kajikawa A, Yamamoto T, et al. Real-time indocyanine green videolymphography navigation for lymphaticovenular anastomosis. *Plast Reconstr Surg Glob Open.* 2019;7:e2253.
5. Hayashi A, Yoshimatsu H, Visconti G, et al. Intraoperative real-time visualization of the lymphatic vessels using microscope-integrated laser tomography. *J Reconstr Microsurg.* 2021;37:427–435.