

## Thrombosis Following Endovenous Glue Ablation

Raeed Deen and Andrew Bullen

*Circulation Health, Wollongong, NSW, Australia*

### Abstract

Endovenous glue ablation for lower limb varicose veins is growing in popularity due to its safety and efficacy. Of significant concern is glue-associated thrombus extension into deep veins. We present a case of thrombus extending into the common femoral vein following endovenous glue ablation for varicose veins with the VenaSeal™ closure system (VCS; Medtronic). A 63-year-old man who presented with symptomatic varicose veins had incompetence of the saphenofemoral junction. He underwent endovenous glue ablation using VCS closure. At 1 month, improvement in varicosities was mirrored by duplex ultrasound confirmation of successful long saphenous vein ablation, but ultrasound indicated thrombus extending into the common femoral vein. This was managed by surveillance duplex and serial clinical observation, with spontaneous resolution at 12 months. With increasing use of VCS for varicose veins, it is likely that thrombotic complications of the deep veins will be encountered more frequently. It is time for formulation of guideline-based management of this complication.

### Keywords

Endovenous glue ablation, VenaSeal, varicose veins, thrombus with glue extension

**Disclosure:** AB is on the *Vascular & Endovascular Review* editorial board; this did not influence peer review. RD has no conflicts of interest to declare.

**Received:** 4 October 2019 **Accepted:** 15 December 2019 **Citation:** *Vascular & Endovascular Review* 2020;3:e03. **DOI:** <https://doi.org/10.15420/ver.2019.08>

**Correspondence:** Raeed Deen, Circulation Health, Suite 101/62 Harbour Street, Wollongong, NSW 2500, Australia. E: [raeeddeen30@gmail.com](mailto:raeeddeen30@gmail.com)

**Open Access:** This work is open access under the CC-BY-NC 4.0 License which allows users to copy, redistribute and make derivative works for non-commercial purposes, provided the original work is cited correctly.

The treatment of varicose veins has become a rapidly evolving landscape with the expansion of endovenous therapies, which can be categorised into thermal tumescent (TT) and newer non-thermal non-tumescent (NTNT) methods. TT endovenous techniques, such as radiofrequency and laser ablation, have been extensively studied and shown to be effective and safe.<sup>1</sup> The newer NTNT techniques, such as glue and mechanochemical ablation, have been studied to a lesser degree. These techniques are growing in popularity due to the exclusion of tumescent anaesthesia and the absence of any risk of heat-related injuries to the skin and surrounding nerves.<sup>2</sup>

Despite this, a significant concern of endovenous glue ablation is the formation of thrombosis with glue extensions into the deep venous system. Progression of thrombus from the saphenofemoral junction (SFJ) to the common femoral vein is a rare complication following glue ablation.<sup>3</sup> To date, there are no guidelines for management. There is a similar, well-researched complication, in TT techniques – endogenous heat-induced thrombosis (eHIT), for which classification systems and management guidelines exist.<sup>4,5</sup> In the case of endovenous glue ablation, further concerns are raised in patients who are high risk, as to whether the risk of embolisation may be similar to that of eHIT.

We report a case of endovenous glue ablation with the VenaSeal closure system (VCS; Medtronic) and subsequent thrombus formation extending into the femoral vein.

### Case Report

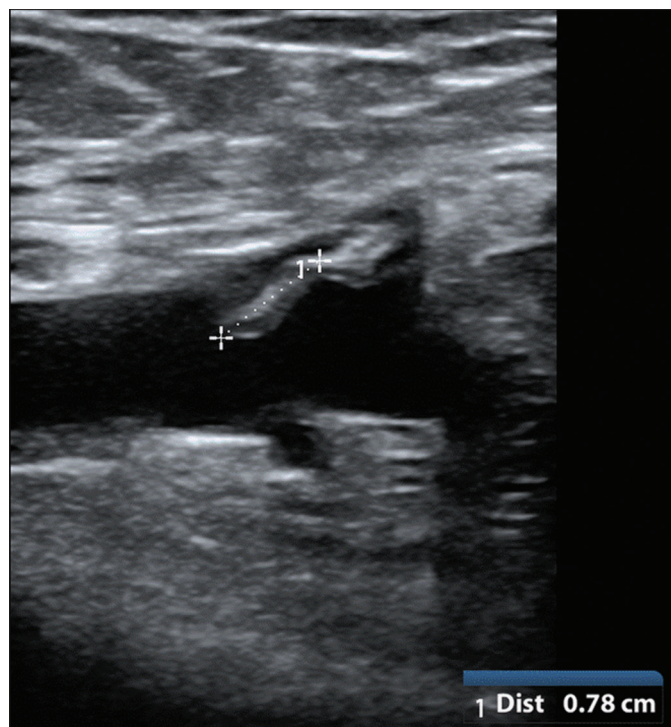
A 63-year-old man presented to the vascular clinic with extensive lower limb venous incompetency, associated varicosities and two prior

episodes of superficial thrombophlebitis (STP) treated with anticoagulation by his primary care physician. He was otherwise fit and well, with a medical history significant for controlled hypertension. There was no history of smoking, malignancy, deep vein thrombosis, thrombophilia or other prothrombotic conditions. Examination revealed multiple varicosities in the bilateral medial thighs with palpable old superficial phleboliths, and reticular veins at the ankles with associated oedema. Pulses were present throughout the lower limbs. On initial presentation, the venous clinical severity score was 13.

Duplex ultrasound of the left lower limb indicated a markedly incompetent long saphenous vein (LSV) and SFJ, primarily responsible for the lower leg varicosities. In addition, a short segment of STP was identified in an LSV medial thigh tributary, but no deep vein thrombosis. This was treated with therapeutic low molecular weight heparin and compression. Once the STP had resolved, endovenous glue ablation with the VCS was carried out. Following protocol, access was gained into the LSV at the mid-calf with ultrasound guidance. The VCS catheter tip was placed in the LSV, 5 cm distal to the SFJ, and VCS adhesive was delivered with simultaneous compression near the SFJ. The entire length of the LSV was treated with adhesive and simultaneous compression, up to the point of access at the mid-calf.

The patient returned 1 month later for review. Apart from mild tenderness on the medial thigh lasting 48 hours after the procedure, he reported significant improvement in symptoms. The site of incision for LSV access had healed, and there was marked improvement in venous oedema with no superficial thrombosis palpable. The LSV and associated varicosities had resolved on examination, and the follow-up

**Figure 1: Venous Duplex Ultrasound Image at the Groin Showing Mixed Echogenic Thrombus (within Markers) Extending into the Common Femoral Vein**



venous clinical severity score was 3, a significant improvement. Postoperative venous duplex confirmed successful ablation of the LSV from calf to groin, but the scan additionally showed a tongue of partially occlusive material extending into the common femoral vein without acute deep venous thrombosis (Figure 1). This was managed with surveillance duplex and serial clinical observation at 1, 3, 6 and 9 months, with spontaneous resolution by 12-month follow-up.

## Discussion

Overall, the VCS has proven to be an effective and safe modality in the treatment of varicose veins.<sup>3</sup> Thrombus with glue extension into the deep venous system has been reported as a rare and minor complication of the VCS. The aetiology has mainly been attributed to technique: that is, the distance of the glue-injecting catheter tip from the SFJ on initial delivery of the adhesive.<sup>3</sup> The first safety study on

humans reported thrombus extensions in 21% of patients when the catheter tip was placed 2 cm from the SFJ.<sup>6</sup> Subsequent clinical trials positioned the catheter tip 5 cm from the SFJ, and no thrombus extensions were reported.<sup>7,8</sup> However, despite this change in catheter tip positioning, as in the present case, thrombus extensions were still reported. Lam et al., in an expert review of six major studies of VCS (n=344), reported 10 patients with glue extension; an incidence of 0.03%.<sup>3</sup> Those 10 cases all resolved with anticoagulant treatment, whereas the present patient was managed non-pharmacologically.<sup>3</sup>

In order to ensure successful occlusion of the LSV, VCS glue (an n-butyl-2-cyanoacrylate-based adhesive) has been formulated to transform into a solid material upon exposure to body fluids or tissue.<sup>9</sup> As such, VCS glue has prothrombotic properties, which may explain the increased risk of formation of thrombus extension. However, it is unclear if the volume of injected glue has an impact on this complication.

A similar complication, eHIT, occurs in TT techniques.<sup>1,2</sup> Initial studies described eHIT as a complication with low incidence rates, but subsequent clinical experience reported the actual incidence to be higher.<sup>4</sup> As a result, eHIT was studied more extensively, with risk factors demonstrated in the literature, and classification systems created to guide management ranging from observation with serial ultrasound to anticoagulation.<sup>5</sup> Similar to eHIT, the theoretical risk of a thrombus with glue extension in the deep venous system is the potential for embolus to the pulmonary system – a potentially fatal event. Currently, there is no clear evidence to guide clinicians in the management of thrombus with glue extension.

Furthermore, many of the safety studies involving the VCS excluded patients with a history of STP.<sup>6-8</sup> Although active STP remains a relative contraindication to VCS, a history of STP is not a listed contraindication.<sup>9</sup> More research is required to stratify those who are at risk of thrombus formation following endovenous glue ablation and to guide appropriate management before and after intervention.

There may be a role for prophylactic anti-platelets or anti-coagulation when performing VCS on patients with a history of STP or a prothrombotic history. With the increasing prevalence of chronic venous disease and varicose veins, and the rapidly growing popularity of endovenous glue ablation, it is prudent for future studies to further investigate this minor but likely underreported and potentially fatal complication. ■

- Rasmussen LH, Lawaetz M, Bjoern L, et al. Randomized clinical trial comparing endovenous laser ablation, radiofrequency ablation, foam sclerotherapy and surgical stripping for great saphenous varicose veins. *Br J Surg* 2011;98:1079–87. <https://doi.org/10.1002/bjs.7555>; PMID: 21725957.
- Bootun R, Lane TR, Davies AH. The advent of non-thermal, non-tumescent techniques for treatment of varicose veins. *Phlebology* 2016;31:5–14. <https://doi.org/10.1177/0268355515593186>; PMID: 26130051.
- Lam YL, De Maeseneer M, Lawson J, et al. Expert review on the VenaSeal® system for endovenous cyano-acrylate adhesive ablation of incompetent saphenous trunks in patients with varicose veins. *Expert Rev Med Devices* 2017;14:755–62. <https://doi.org/10.1080/17434440.2017.1378093>; PMID: 28892412.
- Kane K, Fisher T, Bennett M, et al. The incidence and outcome of endothermal heat-induced thrombosis after endovenous laser ablation. *Ann Vasc Surg* 2014 ;28:1744–50. <https://doi.org/10.1016/j.avsg.2014.05.005>; PMID: 24911803.
- Dexter D, Kabnick L, Berland T, et al. Complications of endovenous lasers. *Phlebology* 2012;27(Suppl 1):40–5. <https://doi.org/10.1258/phleb.2012.012S18>; PMID: 22312066.
- Almeida JJ, Javier JJ, Mackay E, et al. First human use of cyanoacrylate adhesive for treatment of saphenous vein incompetence. *J Vasc Surg Venous Lymphat Disord* 2013;1:174–80. <https://doi.org/10.1016/j.jvsv.2012.09.010>; PMID: 26992340.
- Proebstle TM, Alm J, Dimitri S, et al. The European multicenter cohort study on cyanoacrylate embolization of refluxing great saphenous veins. *J Vasc Surg Venous Lymphat Disord* 2015;3:2–7. <https://doi.org/10.1016/j.jvsv.2014.09.001>; PMID: 26993674.
- Morrison N, Gibson K, McEnroe S, et al. Randomized trial comparing cyanoacrylate embolization and radiofrequency ablation for incompetent great saphenous veins (VeClose). *J Vasc Surg* 2015;61:985–94. <https://doi.org/10.1016/j.jvs.2014.11.071>; PMID: 25650040.
- VenaSeal™ closure system. [www.accessdata.fda.gov/cdrh\\_docs/pdf14/P140018c.pdf](http://www.accessdata.fda.gov/cdrh_docs/pdf14/P140018c.pdf) (accessed 20 February 2020).