

# Antegrade Chronic Total Occlusion Strategies: A Technical Focus for 2020

Calum Creaney and Simon J Walsh

Department of Cardiology, Belfast Health and Social Care Trust, Belfast, UK

## Abstract

Chronic total occlusions (CTOs) are common in patients with ischaemic heart disease. In many countries, patients with CTOs are underserved by percutaneous coronary intervention (PCI). One of the barriers to CTO PCI is the technical challenges of these procedures. Improvements in technique and dedicated devices for CTO PCI, combined with advances in procedural strategy, have resulted in a dramatic increase in procedural success and outcomes. Antegrade wiring (AW) is the preferred initial strategy in short CTOs, where the proximal cap and course of the vessel is understood. For many longer, more complex occlusions, AW has a low probability of success. Dissection and re-entry techniques allow longer CTOs and those with ambiguous anatomy to be crossed safely and efficiently, and CTO operators must also be familiar with these strategies. The CrossBoss and Stingray system is currently the primary targeted re-entry device used during antegrade dissection and re-entry (ADR), and there continues to be an evolution in its use to increase procedural efficiency. In contrast to older ADR techniques, targeted re-entry allows preservation of important side-branches, and there is no difference in outcomes compared to intraplaque stenting.

## Keywords

Chronic total occlusion, antegrade wiring, antegrade dissection and re-entry, intracoronary imaging

**Disclosure:** SJW is a consultant to Abbott, Boston, Medtronic and Teleflex, and is on the *Interventional Cardiology Review* editorial board; this did not influence peer review. CC has no conflicts of interest to declare.

**Received:** 25 February 2020 **Accepted:** 24 April 2020 **Citation:** *Interventional Cardiology Review* 2020;15:e08. **DOI:** <https://doi.org/10.15420/icr.2020.05>

**Correspondence:** Calum Creaney, Department of Cardiology, Belfast Health and Social Care Trust, Belfast, UK. E: [calum.creaney@nhs.net](mailto:calum.creaney@nhs.net)

**Open Access:** This work is open access under the CC-BY-NC 4.0 License which allows users to copy, redistribute and make derivative works for non-commercial purposes, provided the original work is cited correctly.

There has been rapid development in the techniques used for chronic total occlusion (CTO) percutaneous coronary intervention (PCI) over the past decade, with success rates in experienced centres now exceeding 90%.<sup>1</sup> This is in part due to advances in devices and techniques for CTO crossing, but also an improved understanding of strategy. The development of the 'hybrid algorithm' has improved success rates, safety and efficiency of these procedures across many countries (*Figure 1*).<sup>1-5</sup> Registries consistently show that antegrade wiring (AW) is the most common strategy for crossing CTOs, particularly those of lower complexity.<sup>1,5</sup> However, it is important to understand that to safely achieve a high success rate in CTO PCI, expertise in dissection and re-entry techniques (DART) and retrograde approaches are also required. This review will provide a contemporary update on antegrade techniques for CTO PCI.

## Angiographic Assessment and Strategy Selection

A detailed understanding of the coronary anatomy is fundamental to successful CTO procedures. Some of the necessary information can be gained from a pre-procedure diagnostic angiogram, but dual catheter angiography is essential (with the exception of ipsilateral collaterals or bridging) to provide information about collateral filling, lesion length and vessel course. When acquiring dual catheter images, a wide field of view should be used, the camera should not pan and the run should be long enough to allow accurate assessment of collateral channels.

When interpreting the angiogram, there are a number of features that require assessment, and in turn help to guide procedural strategy.

## The Proximal Cap

If the proximal cap is ambiguous (i.e. its location or the course of the vessel after the occlusion is uncertain), this is a point of jeopardy during the case. Adjunctive imaging with intravascular ultrasound (IVUS) should be considered to resolve anatomical ambiguity (*Figure 2*). Coronary CT can also provide information on location and morphology of the proximal cap, as well as lesion length, calcification and tortuosity.<sup>6</sup>

The shape of the cap is important: a tapered proximal cap may offer lower resistance to wire passage, and AW is more likely to be successful than in a CTO with a blunt proximal cap.<sup>7</sup> The presence of a side-branch at a blunt proximal cap is common in long-duration CTOs. This may cause guidewires to deflect into the side-branch, making AW more challenging.

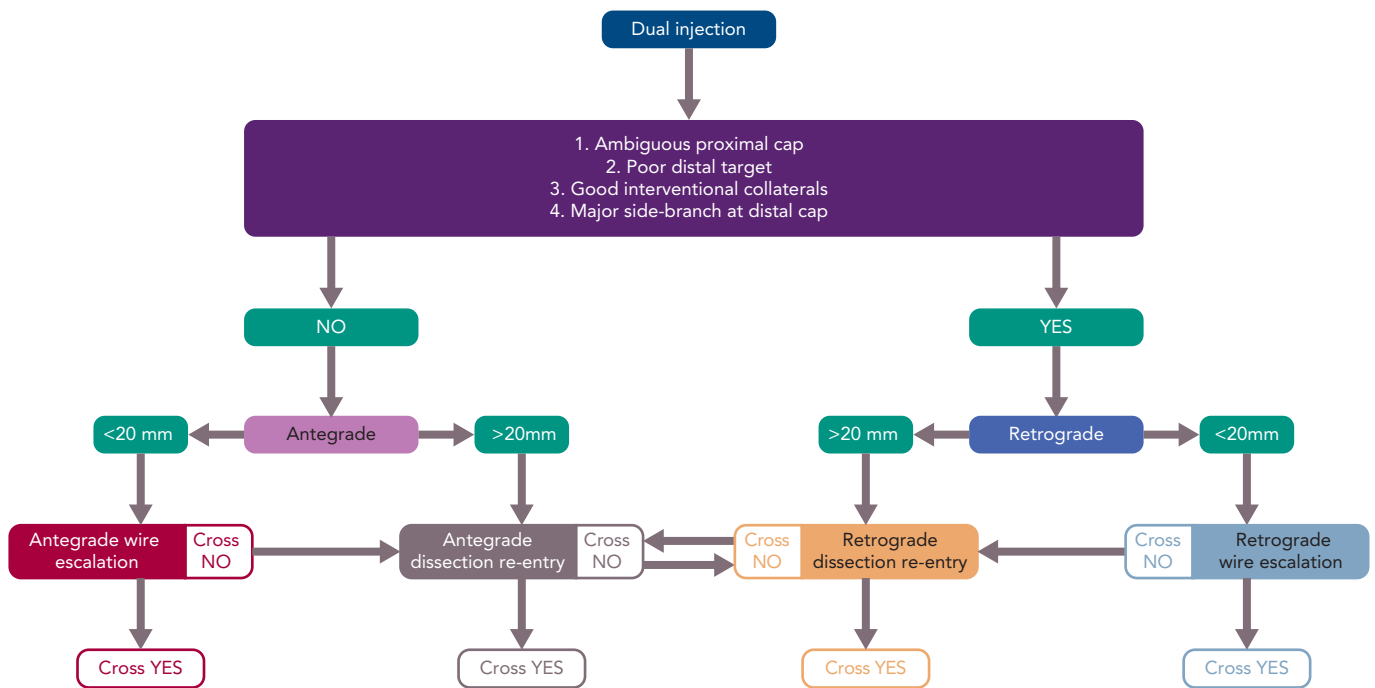
## The Chronic Total Occlusion Body

Lesion length progressively increasing >20 mm makes intimal wire passage less likely and increases procedure duration.<sup>8</sup> This will lead many operators to DART procedures primarily. A heavy burden of calcification and vessel tortuosity are additional features that confer complexity and make it more likely that DART may be required.<sup>1,5</sup>

## The Distal Cap and Landing Zone

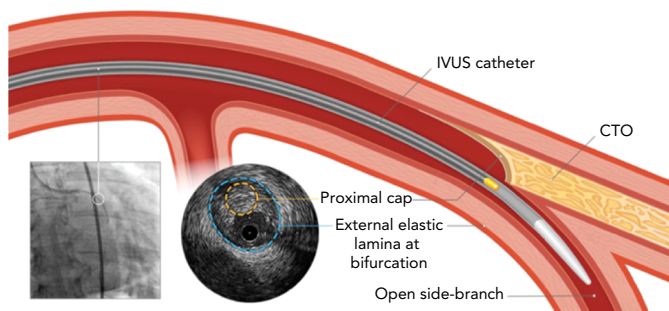
The vessel beyond the distal cap and before the origin of a major side-branch is known as the distal landing zone (LZ), referring to the area for potential re-entry during antegrade dissection and re-entry (ADR). If the distal cap is at or near a bifurcation of a significant side-branch, the

Figure 1: The Hybrid Chronic Total Occlusion Algorithm



Source: Vascular Perspectives. Reproduced with permission from Vascular Perspectives.

Figure 2: Use of Intravascular Ultrasound to Resolve Proximal Cap Ambiguity



A side-branch at the proximal cap can be used to deliver an IVUS catheter which can reveal the location of the proximal cap. CTO = chronic total occlusion; IVUS = intravascular ultrasound. Source: Vascular Perspectives. Reproduced with permission from Vascular Perspectives.

chance of dissection extending across the branch and causing occlusion is increased, making ADR a less favourable strategy. Similarly, inadvertent extraplaque wire passage at the distal cap during AW can have the same effect. If there is a heavily diseased LZ in close proximity to a major bifurcation, a primary retrograde strategy is indicated, provided this can be achieved safely.

**Collateral Supply**

Collateral vessels supplying the distal vessel facilitate visualisation of the distal target during antegrade procedures, and also open the possibility of a retrograde approach. The source of the collateral should first be identified, and then the course of the collateral considered (epicardial or septal). The diameter of the collateral, tortuosity and angle of entry and exit from vessels are other important features in determining whether the collaterals are suitable for use as a retrograde conduit.<sup>9</sup> When visualisation of a collateral channel is challenging, selective imaging using a microcatheter may be considered.

Operators should be mindful that retrograde procedures are associated with increased complications from the procedure (although selection bias may contribute to this observation) and the risk associated with perforation is highest when using epicardial collateral channels.<sup>3,10</sup>

**Procedural Setup**

With advances in equipment and technique, most CTO procedures can now be carried out through 7 French guide catheters. There has recently been a move towards bilateral radial access. The use of appropriately sized catheters, which provide a high degree of passive support, (typically Voda Left, XB or Extra Back-Up curves for the left coronary, and Amplatz Left or 3D curves for the right coronary) has little downside, while having the advantage of avoiding the morbidity and mortality of vascular complications from femoral access.<sup>11</sup> In the Registry of CrossBoss and Hybrid procedures in France, the Netherlands, Belgium and United Kingdom (RECHARGE), 24% of cases were performed using only radial access. This had no impact on procedural success compared with transfemoral access, irrespective of lesion complexity.<sup>12</sup>

After engagement of the donor guide, we recommend that a workhorse wire should routinely be placed in the donor vessel. This maintains the catheter position, allows easy engagement and disengagement and importantly also expedites treatment of any donor vessel injury (which can cause rapid deterioration in the context of a contralateral CTO).

**Antegrade Wiring**

AW is a technique where a guidewire penetrates the proximal cap of the CTO and aims to remain intraplaque before entering the distal true lumen. In reality, the wire often passes in and out of the vessel extraplaque during AW, often unrecognised angiographically.<sup>13-15</sup> AW is most likely to be successful where there is a clear, tapered proximal cap and the occlusion is short (<20 mm). Where these conditions are not met, a primary AW strategy may still be appropriate, but operators should understand that the probability of successfully completing the

procedure is lower and should remain flexible to changing to an alternative strategy if progress is not being made.

### Initial Wire Selection

AW has traditionally been described as an escalation of wire tip load until the lesion is crossed. While this is effective for crossing some CTOs, it is more efficient to select wires based on their suitability for a particular task within the procedure. It should also be noted that any wire should be used in combination with a microcatheter. Various microcatheters are available, although a comprehensive overview of their properties and application is beyond the scope of this article.

A knowledge of guidewires, their individual properties and the tasks they are used for is therefore fundamental to AW success. A detailed description of each wire is outside the scope of this review, but it is helpful to group CTO lesion crossing wires into categories based on their properties and functions. Some newer guidewires are outlined in *Table 1*.

With this understanding, the choice of initial wire for AW should be dictated by the anatomy of the CTO, in particular the proximal cap. If the cap is tapered, a low- or medium-tip load wire with a polymer jacket is a good choice, as the cap is likely to be of relatively low resistance and these wires can track loose tissue within the CTO body with a relatively low risk of exiting the vessel.

Factors that should prompt consideration of a penetration wire are:

- Blunt proximal cap – in longer-duration CTOs, the proximal cap tends to be blunt due to prolonged exposure to systemic arterial pressure, causing formation of dense fibrous tissue.
- Heavy calcification at the proximal cap.
- Presence of a side-branch or bridging collaterals at the proximal cap that often cause softer, jacketed wires to prolapse or deflect away from the cap.

A penetration wire (i.e. a Confianza Pro 12; Asahi Intecc) is well suited to crossing a short occlusion, with a blunt cap and with little tortuosity in the CTO body. It is important to understand that penetration wires can easily exit the vessel architecture, and are therefore not suitable for crossing long CTO segments, especially where the course of the vessel is ambiguous or there is established within-CTO tortuosity.

### Crossing the Chronic Total Occlusion Body

Once a penetration wire has crossed the proximal cap, it is safest to advance the microcatheter into the CTO and exchange for a less penetrative wire, unless the CTO segment is very short and straight. This principle of exchanging wires based on CTO resistance is known as 'escalation/de-escalation', and the overriding principle is of safety, provided that progress is being made.

Before advancing a microcatheter (or other equipment) over a wire, the position of the wire must be confirmed. Medium- and high-gram weight wires, especially those without polymer jackets, can exit the vessel architecture. Wire exit on its own is usually of little clinical consequence; however, advancement of secondary equipment beyond the adventitia will usually lead to significant perforation.

Wire position can be confirmed by taking a number of orthogonal views to check the wire is within the vessel architecture in all projections, and

**Table 1: Commonly Used Guidewires for Chronic Total Occlusion Percutaneous Coronary Intervention**

| Wire Properties                                     | Examples  | Function   |
|---|---|--|
| Low-gram weight, tapered tip, polymer jacket        | Fighter (Boston Scientific)<br>Fielder XT, Fielder XTA,<br>Fielder XTR (Asahi Intecc)   | Palpate proximal cap, loose tissue tracking within CTO body. Knuckle wire  |
| Medium-gram weight, polymer jacket                  | Pilot 200 (Abbott)<br>Gladius (Asahi Intecc)<br>Crosswire NT (Terumo)<br>Raider (Teleflex)  | Palpate proximal cap, tracking within more resistant CTOs. Knuckle wire. Less likely to exit in tortuosity and ambiguity |
| Medium-gram weight, no polymer jacket               | Gaia 2, Gaia 3, Gaia Next (Asahi Intecc)<br>Judo 3, Judo 6 (Boston Scientific)  | Crossing CTO body in more mature resistant lesions. Tactile feedback and torque transmission help in understood anatomy  |
| High-gram weight, tapered, no polymer jacket        | Confianza Pro12, Astato 8/20 & 8/40 (Asahi Intecc)<br>Pro Via 15 (Medtronic)<br>Progress 200T (Abbott)<br>Hornet 14 (Boston Scientific) | Penetration wires for focused crossing of highly resistant segments  |
| Dedicated knuckle wire                              | Gladius MG (Asahi Intecc)   | Crossing long segments efficiently using blunt dissection, with a low risk of perforation                                |
| Collateral crossing wires for retrograde procedures | Sion, Sion Black, Suoh03 (Asahi Intecc)<br>Samurai RC (Boston Scientific)   | Low tip load, highly torquable and flexible shafts to adapt to channel shapes  |

*Guidewires are classified by their properties, which determine the function of the wire within a CTO procedure. CTO = chronic total occlusion.*

is seen to be 'dancing' in synchrony with the vessel. A retrograde contrast injection from the donor guide can also be helpful. Antegrade injections are less likely to provide additional information and may hinder attempts at DART if there has been extraplaque wire passage.

Once the wire position has been confirmed in the distal true lumen, the microcatheter should be advanced beyond the distal cap and the wire exchanged for a workhorse wire, which can then be used for the remainder of the procedure.

There are a number of other wires that have specific functions within CTO procedures. When starting a knuckle to facilitate dissection, a soft- or medium-tip load polymer jacketed wire is usually used, although dedicated knuckle wires are now coming into routine use (*Table 1*).

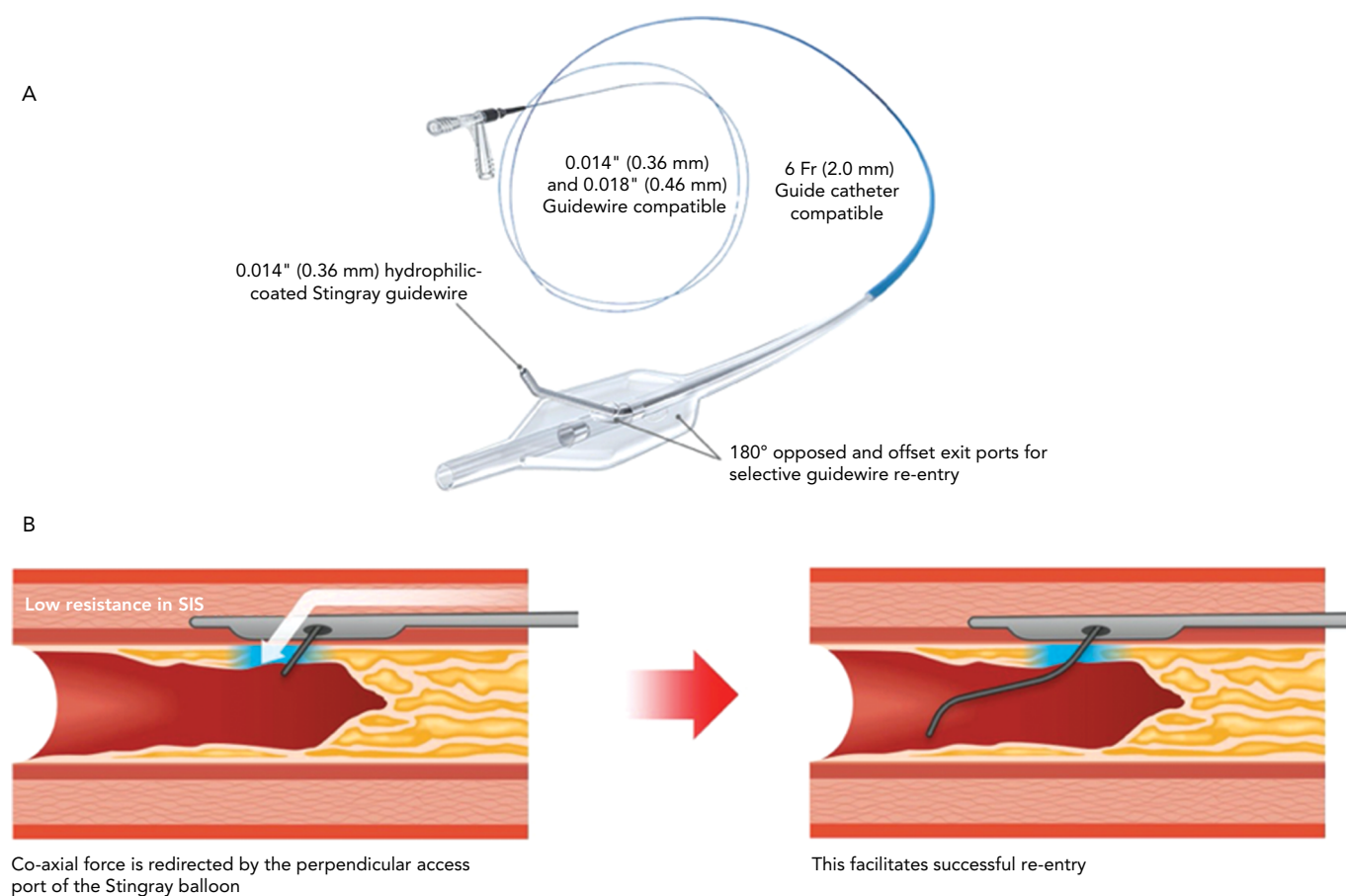
### Antegrade Dissection and Re-entry

ADR is a technique where the guidewire and/or equipment intentionally pass into a dissection plane before re-entering the distal vessel lumen at or beyond the distal cap. The technique has two main indications, first as a primary strategy for crossing long or complex CTOs, and secondly as a bailout following inadvertent extraplaque wire passage during AW that cannot be resolved.

### Wire-based Re-entry Techniques

Many AW procedures (~10%) may represent a form of inadvertent ADR, although the wire typically regains the true lumen close to the distal cap.<sup>13</sup>

Figure 3: Stingray LP Balloon



A. Stingray LP balloon. B. Stingray LP balloon positioned at distal cap allowing targeted re-entry to distal lumen. SIS = Subintimal space. Source: *Vascular Perspectives*. Reproduced with permission from *Vascular Perspectives*.

Subintimal tracking and re-entry (STAR) was the first dedicated ADR technique to be described.<sup>16</sup> This involves passage of a looped or 'knuckled' guidewire into a dissection plane and advancing it until it enters the distal lumen, often at the site of a bifurcation, risking loss of branches. The mini-STAR technique is when an attempt is made to wire the occlusion as far as possible before entering a dissection plane,<sup>17</sup> thereby theoretically minimising the length of extraplaque wire passage. Mini-STAR does not overcome the fundamental downside of STAR: that re-entry cannot be controlled. The medium- and long-term outcomes from these techniques are poor,<sup>18-20</sup> and at present, they are only used in two circumstances: when a guidewire inadvertently re-enters the lumen close to the distal cap during ADR or as a bailout manoeuvre as part of an investment or CTO body modification procedure that aims to facilitate a later second attempt.<sup>1</sup>

Limited antegrade subintimal tracking and re-entry uses targeted re-entry by advancing a microcatheter within a dissection plane and attempting wire-based re-entry beyond the distal cap.<sup>21</sup> The subintimal wire is exchanged for a penetration wire with a large primary bend, and this is directed towards the true lumen to re-enter. This technique is also not reproducible and has largely been abandoned since the development of dedicated re-entry equipment for ADR.

Another non-targeted technique for ADR has recently been reported.<sup>22</sup> Antegrade fenestration and re-entry (AFR) causes disruption within the vessel extraplaque by inflation of a 1:1-sized balloon through the

CTO segment. This aims to create tears within the vessel media, thus allowing a soft polymer wire to cross fenestrations and reach the distal true lumen. The experience of this technique is largely confined to a single centre with six successful cases reported so far. Given the established role of ballooning the subintimal space for investment and a lack of reliable ability to re-enter the distal true lumen in a long experience of these procedures,<sup>1</sup> extensive data about the reproducibility of AFR and longer-term outcomes will be required. Most likely, STAR and AFR will be reserved for bailout manoeuvres when targeted re-entry cannot be facilitated by targeted ADR or retrograde procedures.

### Device-based Re-entry Techniques

The CrossBoss and Stingray system (Boston Scientific) continues to form the mainstay of targeted re-entry devices. The CrossBoss is a blunt tipped dissection catheter that will track through intimal plaque or create a controlled extraplaque dissection that facilitates delivery of the Stingray LP balloon beyond the distal cap (*Figure 3*).

The ReCross device (IMDS) is an over-the-wire, modified dual-lumen microcatheter. It has two exit ports close to the distal end of the device, oriented at 180° from each other, thereby providing some degree of control in guidewire redirection (*Figure 4*). At present, experience with the device is limited, with no published case series.

A primary ADR procedure is typically applied to cross long and/or ambiguous CTOs where the proximal cap is well defined and there is

an LZ proximal to important side-branches.<sup>23</sup> After crossing the proximal cap, a balloon in the vessel extraplaque is used to introduce a guide catheter extension as a standard step. The Trapliner (Teleflex) allows the most efficient exchange of equipment for ADR, while also preventing haematoma formation. A knuckle wire and microcatheter can then be advanced across the CTO segment. When approaching the LZ, many operators will use the CrossBoss to create a smaller dissection plane for the last 20–30 mm to minimise haematoma formation. The Stingray LP balloon is then delivered, inflated and the correct orientation for re-entry found on fluoroscopy. Wire choice for re-entry has evolved since the introduction of the device; the Stingray wire has a small microbarb at the tip. This is helpful for re-entry when the balloon is close to a healthy distal LZ. However, in the presence of a large burden of atheroma between the balloon and lumen, it may be less effective. In this circumstance, many operators prefer a tapered penetration wire (i.e. Confianza Pro 12 or Astat 8/20 [Asahi Intecc] or Hornet 14 [Boston Scientific]). After re-entry to the distal true lumen and removal of the Stingray LP, the penetration wire is exchanged for a workhorse wire via a microcatheter to safely complete the procedure.

When the wire inadvertently passes into a dissection plane and beyond the distal cap during AW, we advocate an early switch in strategy to bailout ADR, if the anatomy is suitable. In this setting, the CrossBoss is often not required. The antegrade microcatheter can be advanced to the LZ and a MIRACLEbros 12 wire (Asahi Intecc) used to deliver the Stingray LP balloon or ReCross for re-entry. By minimising the steps in the procedure, this increases procedural efficiency without compromising safety.

### Troubleshooting During Antegrade Dissection and Re-entry

Troubleshooting CTO lesions is an important skillset. In the following section, we describe some common challenges during ADR and how these can be resolved.

### Impenetrable Proximal Cap

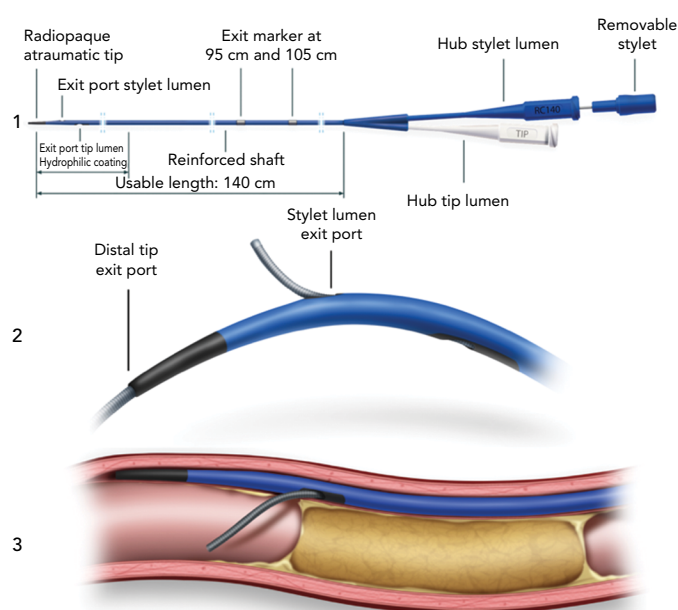
With impenetrable proximal caps or unresolvable anatomical ambiguity, one solution is the use of balloon-assisted subintimal entry (BASE) and a parallel anchor (power knuckle; *Figure 5*).<sup>24</sup> A balloon, sized 1:1 with the vessel, is inflated proximal to the CTO to create intimal disruption. A microcatheter is then positioned alongside and the balloon inflated to trap the microcatheter. This increases support and allows passage of the knuckle wire into a dissection plane.

When a side-branch is present at the proximal cap, a modification of this technique (side-BASE) can be used.<sup>25</sup> A blocking balloon is positioned in the side-branch causing deflection of the knuckle wire into a dissection plane (*Figure 5*).

### Equipment Enters a Side-branch

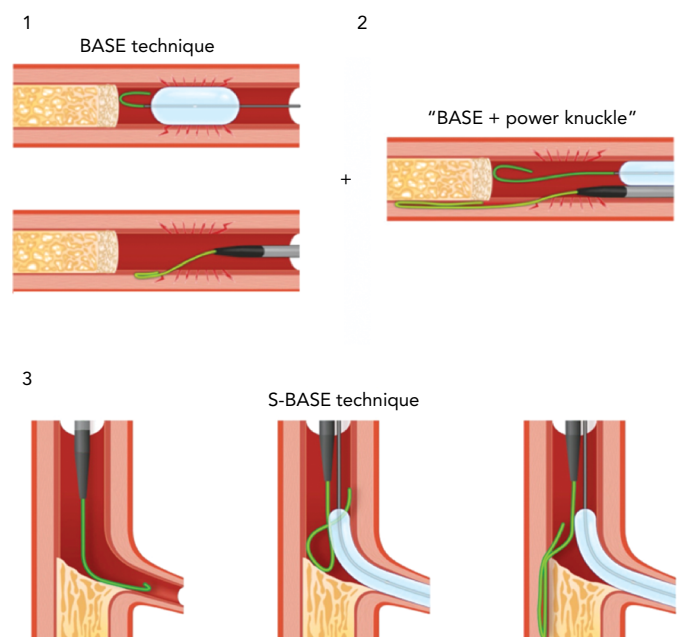
When advancing a knuckle or CrossBoss, it is important to confirm it is moving in synchrony and in plane with the main vessel architecture. If this is not the case, the most likely explanation is passage into a side-branch. This can be resolved by retracting the equipment and redirecting a wire past the side-branch before advancing the CrossBoss or microcatheter over the wire until it is beyond the side-branch. At this point, blunt dissection can be resumed. If this is not successful, a dual-lumen catheter or a blocking balloon placed in the side-branch can aid redirection.

Figure 4: ReCross Device



1. The ReCross dual-lumen over-the-wire microcatheter. 2. ReCross device with wires exiting from distal tip exit port and stylet exit port. 3. ReCross device in vessel extraplaque with wire directed from proximal exit port into distal true lumen. Source: Interventional Medical Device Solutions. Reproduced with permission from Interventional Medical Device Solutions.

Figure 5: Balloon-assisted Subintimal Entry



1. BASE. A balloon inflated proximal to the CTO creates intimal disruption and allows subintimal passage of a wire; 2. The use of a parallel anchor (power knuckle) to facilitate BASE; 3. Side-BASE. A blocking balloon is used to facilitate subintimal entry when there is a side-branch at the proximal cap. BASE = balloon-assisted subintimal entry; CTO = chronic total occlusion. Source: Vascular Perspectives. Reproduced with permission from Vascular Perspectives.

### Haematoma at the Landing Zone

Extraplaque haematoma at the LZ is a common failure mode of ADR. The use of a guide catheter extension within the proximal CTO to prevent inflow, avoiding extensive dissection beyond the distal cap with knuckled wires, and/or using the CrossBoss close to the LZ, all help reduce haematoma formation. Additionally, we recommend routinely aspirating from the end hole of the Stingray balloon prior to attempting the puncture.

The subintimal transcatheter withdrawal technique can also be used to reconstitute the LZ when there is reduced filling due to haematoma.<sup>26</sup> With the Stingray balloon in place, a second wire is advanced into the vessel extraplaque, and an over-the-wire 1:1-sized balloon is delivered and inflated, blocking any inflow to the vessel. A syringe is then used to aspirate haematoma via the tip of the over-the-wire balloon, and puncture re-attempted at the distal vessel reconstitutes.

## The Role of Intracoronary Imaging

There is now clear evidence that the routine use of intravascular imaging significantly reduces target vessel failure in non-occlusive disease.<sup>27,28</sup> IVUS is preferred over optical coherence tomography for CTO PCI, as it avoids the need for high-pressure contrast injection, which can create and propagate dissection. Many operators will be familiar with the use of IVUS for stent sizing, identifying stent LZ and assessing stent apposition and expansion, and this is invaluable in optimising results in CTO PCI. We advocate the liberal use of IVUS during CTO PCI, stent deployment and optimisation to maximise procedural durability.

In addition, IVUS can determine the course of the wire through different vascular compartments. It is important to know where the wire is in the false lumen and how this relates to side-branches that need to be preserved. This is particularly important in ADR when the site of re-entry is close to a major bifurcation. If a wire has crossed a side-branch in a dissection plane, stenting will result in loss of that branch, and potentially procedural MI.

## Complications and Outcomes Following ADR

Contemporary registries show low complication rates from CTO PCI.<sup>1,3,29</sup> When comparing complications between different strategies,

there is a higher rate of perforation and major adverse cardiovascular events (MACE) in patients treated with DART, and especially retrograde procedures, compared to AW.<sup>3,29,30</sup> This reflects the increased complexity of CTOs that require the application of DART, including longer lesions, higher Japanese CTO scores and an increased proportion of post-coronary artery bypass graft cases.

The higher rate of target vessel failure with STAR has led to some concern that stenting extraplaque in the vessel leads to poorer outcomes than intraplaque stenting.<sup>18,19</sup> Modern ADR using targeted re-entry, with a focus on preserving all important side-branches, is a different procedure. There is no evidence to suggest that this has any adverse long-term clinical consequences.<sup>13,29–31</sup> Vessel healing and stent coverage appears to be unaffected by extraplaque stenting on optical coherence tomography follow-up in the largest series reported to date.<sup>13</sup> It is unsurprising that more complex lesions that require DART and longer stent lengths are associated with an increase in both target vessel revascularisation and MACE.<sup>13</sup> This is true of every PCI, and is due to the disease burden and stent length more so than the technique that is applied during the case.

## Conclusion

Advances in equipment and technique have undoubtedly led to improvements in the field of CTO PCI, and operators must familiarise themselves with these to achieve good outcomes for patients. It is equally important to understand when to use each of these within a case, as developments in procedural strategy have had the biggest impact in improving outcomes from CTO PCI. AW remains the predominant strategy for crossing short CTOs of lower complexity. However, many CTOs can only be opened with a dissection-based strategy, and ADR offers a safe and efficient means to achieve this when used in appropriately selected cases. ■

- Wilson WM, Walsh SJ, Yan AT, et al. Hybrid approach improves success of chronic total occlusion angioplasty. *Heart* 2016;102:1486–93. <https://doi.org/10.1136/heartjnl-2015-308891>; PMID: 27164918.
- Brilakis ES, Grantham JA, Rinfret S, et al. A percutaneous treatment algorithm for crossing coronary chronic total occlusions. *JACC Cardiovasc Interv* 2012;5:367–79. <https://doi.org/10.1016/j.jcin.2012.02.006>; PMID: 22516392.
- Tajiri P, Karpaliotis D, Alaswad K, et al. The hybrid approach to chronic total occlusion percutaneous coronary intervention: update from the PROGRESS CTO Registry. *JACC Cardiovasc Interv* 2018;11:1325–35. <https://doi.org/10.1016/j.jcin.2018.02.036>; PMID: 29706508.
- Perashad A, Eddin M, Girotra S, et al. Validation and incremental value of the hybrid algorithm for CTO PCI. *Catheter Cardiovasc Interv* 2014;84:654–9. <https://doi.org/10.1002/ccd.25370>; PMID: 24403122.
- Maeremans J, Walsh S, Knaepen P, et al. The hybrid algorithm for treating chronic total occlusions in Europe: the RECHARGE Registry. *J Am Coll Cardiol* 2016;68:1958–70. <https://doi.org/10.1016/j.jacc.2016.08.034>; PMID: 27788851.
- Opolski MP, Achenbach S. CT angiography for revascularization of CTO: crossing the borders of diagnosis and treatment. *JACC Cardiovasc Imaging* 2015;8:846–58. <https://doi.org/10.1016/j.jcmg.2015.05.001>; PMID: 26183556.
- Dong S, Smorgick Y, Nahir M, et al. Predictors for successful angioplasty of chronic totally occluded coronary arteries. *J Interv Cardiol* 2005;18:1–7. <https://doi.org/10.1111/j.1540-8183.2005.00390.x>; PMID: 15788046.
- Morino Y, Abe M, Morimoto T, et al. Predicting successful guidewire crossing through chronic total occlusion of native coronary lesions within 30 minutes: the J-CTO (Multicenter CTO Registry in Japan) score as a difficulty grading and time assessment tool. *JACC Cardiovasc Interv* 2011;4:213–21. <https://doi.org/10.1016/j.jcin.2010.09.024>; PMID: 21349461.
- McEntegart MB, Badar AA, Ahmad FA, et al. The collateral circulation of coronary chronic total occlusions. *EuroIntervention* 2016;11:e1596–603. <https://doi.org/10.4244/EIJV11114A310>; PMID: 27056120.
- Sapontis J, Salisbury AC, Yeh RW, et al. Early procedural and health status outcomes after chronic total occlusion angioplasty: a report from the OPEN-CTO Registry (Outcomes, Patient Health Status, and Efficiency in Chronic Total Occlusion Hybrid Procedures). *JACC Cardiovasc Interv* 2017;10:1523–34. <https://doi.org/10.1016/j.jcin.2017.05.065>; PMID: 28797429.
- Kolkailah AA, Alreshq RS, Muhammed AM, et al. Transradial versus transfemoral approach for diagnostic coronary angiography and percutaneous coronary intervention in people with coronary artery disease. *Cochrane Database Syst Rev* 2018;4:CD012318. <https://doi.org/10.1002/14651858.CD012318.pub2>; PMID: 29665617.
- Bakker EJ, Maeremans J, Zivelonghi C, et al. Fully transradial versus transfemoral approach for percutaneous intervention of coronary chronic total occlusions applying the hybrid algorithm: insights from RECHARGE Registry. *Circ Cardiovasc Interv* 2017;10:e005255. <https://doi.org/10.1093/eurheartj/ehx504.P4219>; PMID: 28851720.
- Walsh SJ, Hanratty CG, McEntegart M, et al. Intravascular healing is not affected by approaches in contemporary CTO PCI: the CONSISTENT CTO study. *JACC Cardiovasc Interv* 2020;13:1448–57. <https://doi.org/10.1016/j.jcin.2020.03.032>; PMID: 32553333.
- Song L, Maehara A, Finn MT, et al. Intravascular ultrasound analysis of intraplaque versus subintimal tracking in percutaneous intervention for coronary chronic total occlusions and association with procedural outcomes. *JACC Cardiovasc Interv* 2017;10:1011–21. <https://doi.org/10.1016/j.jcin.2017.02.043>; PMID: 28521919.
- Muhammad KI, Lombardi WL, Christofferson R, Whitlow PL. Sub-intimal guidewire tracking during successful percutaneous therapy for chronic coronary total occlusions: insights from an intravascular ultrasound analysis. *Catheter Cardiovasc Interv* 2012;79:43–8. <https://doi.org/10.1002/ccd.21319>; PMID: 21542105.
- Colombo A, Mikhail GW, Michev I, et al. Treating chronic total occlusions using sub-intimal tracking and re-entry: the STAR technique. *Catheter Cardiovasc Interv* 2005;64:407–11. <https://doi.org/10.1002/ccd.20307>; PMID: 15789384.
- Galassi AR, Tomasello SD, Costanzo L, et al. Mini-STAR as bailout strategy for percutaneous coronary intervention of chronic total occlusion. *Catheter Cardiovasc Interv* 2012;79:30–40. <https://doi.org/10.1002/ccd.22998>; PMID: 21956876.
- Godino C, Latib A, Economou FI, et al. Coronary chronic total occlusions: mid-term comparison of clinical outcome following the use of the guided-STAR technique and conventional antegrade approaches. *Catheter Cardiovasc Interv* 2012;79:20–7. <https://doi.org/10.1002/ccd.23058>; PMID: 21805559.
- Valenti R, Vergara R, Migliorini A, et al. Predictors of reocclusion after successful drug-eluting stent-supported percutaneous coronary intervention of chronic total occlusion. *J Am Coll Cardiol* 2013;61:545–50. <https://doi.org/10.1016/j.jacc.2012.10.036>; PMID: 23273395.
- Galassi AR, Boukhris M, Tomasello SD, et al. Long-term clinical and angiographic outcomes of the mini-STAR technique as a bailout strategy for percutaneous coronary intervention of chronic total occlusion. *Can J Cardiol* 2014;30:1400–6. <https://doi.org/10.1016/j.cjca.2014.07.016>; PMID: 25442438.
- Michael TT, Papayannis AC, Banerjee S, Brilakis ES. Subintimal dissection/reentry strategies in coronary chronic total occlusion interventions. *Circ Cardiovasc Interv* 2012;5:729–38. <https://doi.org/10.1161/CIRCINTERVENTIONS.112.969808>; PMID: 23074346.
- Carlino M, Azzalini L, Mitomo S, Colombo A. Antegrade fenestration and re-entry: a new controlled subintimal technique for chronic total occlusion recanalization. *Catheter Cardiovasc Interv* 2018;92:497–504. <https://doi.org/10.1002/ccd.27470>; PMID: 29314567.
- Walsh SJ, Cosgrove C, Spratt JC, Hanratty CG. A technical focus on antegrade dissection and re-entry for coronary chronic total occlusions: a practice update for 2019. *Korean Circ J* 2019;49:559–67. <https://doi.org/10.4070/kcj.2019.0160>; PMID: 31243929.
- Vo MN, Karpaliotis D, Brilakis ES. “Move the cap” technique for ambiguous or impenetrable proximal cap of coronary total occlusion. *Catheter Cardiovasc Interv* 2016;87:742–8. <https://doi.org/10.1002/ccd.26079>; PMID: 26332640.
- Roy J, Hill J, Spratt C. The “side-BASE technique”: combined side branch anchor balloon and balloon assisted sub-intimal entry to resolve ambiguous proximal cap chronic total occlusions. *Catheter Cardiovasc Interv* 2018;92:E15–9. <https://doi.org/10.1002/ccd.27422>; PMID: 29266669.
- Smith EJ, Di Mario C, Spratt JC, et al. Subintimal Transcatheter Withdrawal (STRAW) of hematomas compressing the distal true lumen: a novel technique to facilitate distal reentry during

- recanalization of chronic total occlusion (CTO). *J Invasive Cardiol* 2015;27:E1–4. PMID: 25589704.
27. Zhang J, Gao X, Kan J, et al. Intravascular ultrasound versus angiography-guided drug-eluting stent implantation: the ULTIMATE trial. *J Am Coll Cardiol* 2018;72:3126–37. <https://doi.org/10.1016/j.jacc.2018.09.013>; PMID: 30261237.
28. Hong SJ, Mintz GS, Ahn CM, et al. Effect of intravascular ultrasound-guided drug-eluting stent implantation: 5-year follow-up of the IVUS-XPL randomized trial. *JACC Cardiovasc Interv* 2020;13:62–71. <https://doi.org/10.1016/j.jcin.2019.09.033>; PMID: 31918944.
29. Maeremans J, Avran A, Walsh S, et al. One-year clinical outcomes of the hybrid CTO revascularization strategy after hospital discharge: a subanalysis of the multicenter RECHARGE registry. *J Invasive Cardiol* 2018;30:62–70. PMID: 29138365.
30. Wilson WM, Walsh SJ, Bagnall A, et al. One-year outcomes after successful chronic total occlusion percutaneous coronary intervention: the impact of dissection re-entry techniques. *Catheter Cardiovasc Interv* 2017;90:703–12. <https://doi.org/10.1002/ccd.26980>; PMID: 28296045.
31. Kawasaki T, Abe M, Sakuada M, Kishi K. Promus stent treatment of chronic total occlusions using two different recanalization techniques in Japan – J Proctor registry: a multicenter registry to evaluate clinical outcome of drug eluting stent in subintimal area after CTO revascularization using antegrade or retrograde approach. *J Am Coll Cardiol* 2013;61(Suppl 10):e1692. [https://doi.org/10.1016/S0735-1097\(13\)61692-7](https://doi.org/10.1016/S0735-1097(13)61692-7).