

How to Implant His Bundle and Left Bundle Pacing Leads: Tips and Pearls

Shunmuga Sundaram Ponnusamy ¹ and Pugazhendhi Vijayaraman ²

1. Velammal Medical College, Madurai, India; 2. Geisinger Heart Institute, Geisinger Commonwealth School of Medicine, Wilkes Barre, PA, US

Abstract

Cardiac pacing is the treatment of choice for the management of patients with bradycardia. Although right ventricular apical pacing is the standard therapy, it is associated with an increased risk of pacing-induced cardiomyopathy and heart failure. Physiological pacing using His bundle pacing and left bundle branch pacing has recently evolved as the preferred alternative pacing option. Both His bundle pacing and left bundle branch pacing have also demonstrated significant efficacy in correcting left bundle branch block and achieving cardiac resynchronisation therapy. In this article, the authors review the implantation tools and techniques to perform conduction system pacing.

Keywords

His bundle pacing, left bundle branch pacing, cardiac resynchronisation therapy, atrioventricular block, left bundle branch block, heart failure; pacemaker

Disclosure: SSP has worked as a consultant for Medtronic. PV has received speaker fees and fellowship support from Medtronic, has acted as a consultant for Medtronic and has conducted research for Medtronic, has acted as a consultant for Abbott, Biotronik, and Boston Scientific, and has a patent (US 10,737,097 B2) for a His bundle pacing delivery tool.

Received: 30 March 2021 **Accepted:** 4 May 2021 **Citation:** *Cardiac Failure Review* 2021;7:e13. **DOI:** <https://doi.org/10.15420/cfr.2021.04>

Correspondence: Pugazhendhi Vijayaraman, Director, Cardiac Electrophysiology, Geisinger Heart Institute, MC 36–10, 1000 E Mountain Blvd, Wilkes-Barre, PA 18711, US. E: pvijayaraman1@geisinger.edu

Open Access: This work is open access under the CC-BY-NC 4.0 License which allows users to copy, redistribute and make derivative works for non-commercial purposes, provided the original work is cited correctly.

Cardiac pacing is the treatment of choice for the management of patients with symptomatic bradyarrhythmia. For nearly six decades, right ventricular (RV) apical (A) pacing has been the standard approach because it is a safe procedure with proven long-term efficacy. However, RVA pacing is fraught with limitations due to associated electrical and mechanical dyssynchrony.¹ Pre-excitation of the septum coupled with delayed activation of the left ventricular (LV) free wall produces dyssynchronous activation and less effective contraction.² Clinically, this can translate into pacing-induced cardiomyopathy in up to 20% of patients and increased risk for heart failure hospitalisation during long-term follow-up.³

The quest for alternative pacing sites has met with limited success because using the RV septum or RV outflow tract failed to demonstrate clinical pacing.⁴ Adopting biventricular pacing for all patients requiring ventricular pacing is not a cost-effective strategy. An ideal pacing site should provide synchronised ventricular activation by engaging the conduction system of the heart. The concept of conduction system pacing is not new, because temporary capture of the His bundle (HB) was demonstrated more than five decades ago by Scherlag et al.⁵ The feasibility of permanent HB pacing (HBP) was demonstrated only 30 years later by Deshmukh et al.⁶ This review provides insights into the procedural technique and clinical implications of HBP and left bundle branch pacing (LBBP).

Anatomy of the Cardiac Conduction System

The electrical impulse of the heart arises from the sinus node at the superior vena cava–right atrial junction and reaches the atrioventricular (AV) node via three internodal pathways. The AV node at the apex of Koch's triangle

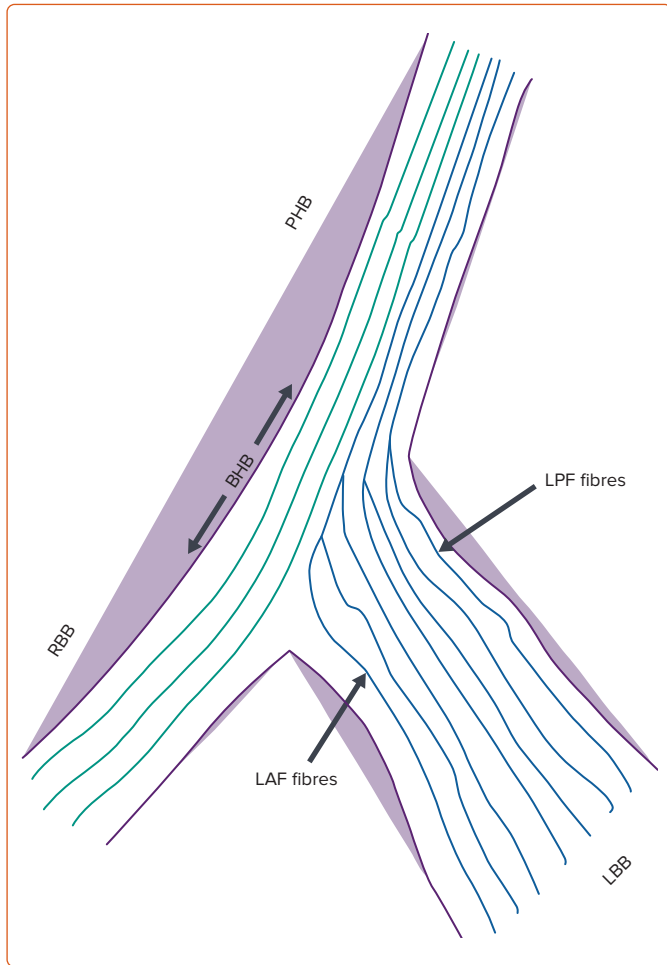
continues as the HB overlying the membranous septum.⁷ The membranous septum is divided by the septal tricuspid leaflet into an atrioventricular component and a ventriculoventricular component. The penetrating portion of the HB arises from the anterior end of the AV node with loosely arranged fibres in an interweaving pattern. It reaches the ventricle by penetrating the central fibrous body of the heart, where the fibres of left bundle branch (LBB) are given off after it emerges from the fibrous body at the level of the non-coronary aortic cusp. The branching portion of the HB starts from the point where the posterior-most fibres of the LBB arise (posterior fascicles), to the point where the HB continues as the right bundle branch (RBB) after giving rise to the anterior fascicles of the LBB (*Figure 1*). The LBB, after its origin, runs inferiorly and anteriorly for 10–15 mm, reaching its maximum width before dividing into anterior and posterior fascicles that head towards the corresponding papillary muscles of the LV.⁸

Anatomical studies have shown three common variations of HB relative to the ventricular aspect of the membranous septum.⁹ In the Type I variation (47%), the HB courses along the inferior border of the membranous septum with a thin layer of myocardial fibres spanning from the muscular septum. In the Type II variation (32%), the HB is separate to below the membranous septum and courses within the interventricular muscle. In the Type III variation (21%), the HB is exposed superficially, lying immediately below the endocardium (naked HB). Both atrial and ventricular components of the HB can be accessed for permanent HBP.

His Bundle Pacing: Implantation Technique

Deshmukh et al. first demonstrated the clinical feasibility of HBP in patients with AF and LV dysfunction using standard pacing leads by

Figure 1: Anatomy of the Conduction System



The His bundle (HB) has two components: the PHB portion and the BHB portion. The LBB branches out of the HB before the true bifurcation point and the RBB is considered as a direct continuation of the HB. Note the longitudinal dissociation as fibres are predestined inside the HB to reach the RBB or LBB. BHB = branching His bundle; LAF = left anterior fascicle; LBB = left bundle branch; LPF = left posterior fascicle; PHB = penetrating His bundle; RBB = right bundle branch.

reshaping the stylet.⁶ The lead placement was done by targeting the site with largest His deflection recorded from the electrophysiology mapping catheter. This technique was fraught with high pacing thresholds and frequent lead dislodgements. The development of specialised sheaths (C304, C315His and C304His, Selectsite; Medtronic) and a pacing lead (3830 Selectsecure; Medtronic) has made HBP technically feasible with high implant success rates.¹⁰

HBP is performed using continuous recording of intracardiac electrograms and 12-lead ECG in an electrophysiology (EP) recording system.¹⁰ His signals are recorded directly from the pacing lead tip in a unipolar connection, and are simultaneously recorded in the EP system and in the pacing system analyser (PSA). After obtaining venous access, the C315 sheath is introduced over the guidewire and placed across the tricuspid valve. The sheath has a proximal curve to point towards the tricuspid annulus and a septal curve to direct the lead towards the His region. A 3830 Selectsecure lead is then advanced just exposing the helix outside the sheath, and the His signals mapped in unipolar fashion. Both the atrial and ventricular parts of the membranous septum can be targeted for HBP. If a predominant atrial signal is recorded, the sheath is moved gently forward with clockwise rotation aiming for a larger His signal with a small or no atrial component.

Gu et al. showed that visualisation of the tricuspid valve annulus by performing contrast angiography before lead implantation resulted in a shorter fluoroscopic time (7.1 versus 10.1 minutes) with similar capture thresholds.¹¹ There was no significant difference in procedural success rates. Zanon et al. demonstrated that HBP can be performed primarily using an electrogram with zero or minimal fluoroscopy with high success rates.¹² In that study, the sheath, along with the lead, was advanced gently with counterclockwise and clockwise rotation into the right atrium through a standard 7 Fr introducer. The pacing lead was then connected to the alligator cable in a unipolar fashion. After confirming the position of the sheath in the atrium by a sharp atrial signal in the recording system, the system was advanced gently to get both atrial and ventricular signals. Further anticlockwise rotation helped reach the HB area.¹² Gentle manipulation of the system helped record a clear near-field His potential from the pacing lead. Unipolar threshold measurement was performed at a pulse width of 1 ms before fixing the lead in the membranous septum. Transient fluoroscopy was used in all patients to confirm lead stability before removing the C315 sheath. Both selective and non-selective HB capture was accepted as procedural success. HBP could be performed safely in 95% of patients (39/41) in that study using electrograms with minimal or zero fluoroscopy.¹²

Alternatively, HBP can be performed using 3D electroanatomical mapping (EAM), especially in patients with complex heart disease.¹³ Sharma et al. created EAM of the RA before lead placement using a conventional 3D mapping system.¹³ His bundle potentials were tagged. The approach to mapping was axillary or cephalic unless the patient was undergoing an AV junction ablation, in which case a femoral approach was used. Pacing was done at the sites with His potentials to note the response to pacing. The 3830 lead was implanted using a C315 or C304 sheath with continuous tracking of the lead course using the 3D system. Transient fluoroscopy was used to confirm full helix deployment and lead slack. Sharma et al. concluded that EAM-guided HBP could significantly reduce fluoroscopy duration and exposure.¹³

Once a sharp near-field His signal is identified, unipolar pacing is done to confirm the capture of the HB. Intracardiac electrograms and 12-lead ECG will help assess conduction system capture. In patients with underlying bundle branch block or His-ventricle (HV) block, mapping of the distal HB must be done to achieve complete correction of bundle branch block or to overcome HV block. If an optimal site is identified, the fluoroscopic image may be saved as a reference in orthogonal oblique views (left anterior oblique [LAO] 30° and right anterior oblique [RAO] 30°). The sheath is held firmly with a gentle counterclockwise torque to oppose it towards the septum and five to six clockwise rotations are given to the pacing lead without releasing it between rotations. Lead rotations can be best visualised in the LAO 30° fluoroscopic view. Rebound of the lead after the rotation will confirm its penetration into the membranous septum. If lead rebound is not observed, the sheath position is optimised to provide adequate support before giving further rotations. Care must be taken to avoid pinning the tricuspid leaflet into the septum when the ventricular component is targeted by using contrast angiography or echocardiography if there is difficulty in deploying the lead. Alternatively, the sheath can be moved into the RV apex and pulled back gradually to the target site.

After confirming lead fixation, the sheath is gently withdrawn into the high right atrium, providing adequate slack for the lead. The lead parameters are checked in both the unipolar and bipolar configuration. Optimal parameters include a unipolar pacing threshold of <1.5 V at a pulse width of 1 ms and a sensed R-wave of >1.5–2 mV without atrial oversensing. An

HB current of injury (COI) recorded from the pacing lead electrogram indicates lead fixation in the HB and predicts excellent pacing thresholds.

Defining Selective and Non-selective Capture of the His Bundle

Based on the paced QRS morphology, two forms of HB capture can be observed: selective (S) and non-selective (NS) HBP.¹⁴ During selective capture, pacing will result in direct activation of the HB alone and the ventricular activation occurs completely through the His–Purkinje system (HPS). Because the impulse takes 35–55 ms to reach the ventricular myocardium, there will be an isoelectric interval before the onset of QRS, and the interval from the pacing spike to the onset of QRS (S-QRS) will be equal to the native HV interval. However, in patients with significant HPS disease, the S-QRS would be less than the native HV interval. The lead electrogram will show the ventricular electrogram discrete from the pacing artefact, and the paced QRS morphology is same as the native QRS.

During NS-HBP, there will be simultaneous activation of both the HB and the surrounding myocardium (*Figure 2*). Because ventricular activation starts simultaneously with the pacing artefact due to local myocardial capture, NS-HB capture is characterised by an absent isoelectric interval and slurred QRS upstroke (pseudo-delta wave) and the absence of a discrete local electrogram. The paced QRS duration will be longer than the native QRS duration. There will be two distinct capture thresholds: RV and His capture. In patients with HPS disease, three distinct thresholds may be observed: RV, His capture with correction of bundle branch block and His capture without correction. Various characteristics of S- and NS-HBP in normal and diseased HPS are presented in *Table 1*. Although S-HBP results in ideal QRS morphology, studies using myocardial perfusion imaging have shown preserved LV electromechanical synchrony even in patients with NS-HBP.^{15,16} In patients with HV block, NS-HBP provides the advantage of myocardial safety pacing. A recent observational study showed no significant difference in clinical outcomes between S- and NS-HBP.¹⁷

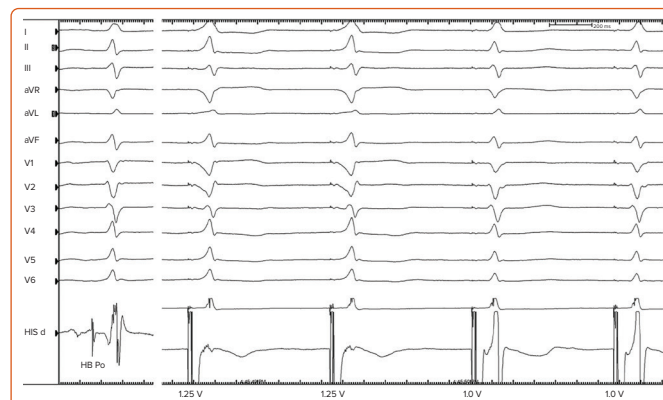
Clinical Implications of His Bundle Pacing

HBP is considered as an effective alternative to RVA pacing because it avoids many of the limitations of RVA. HBP can be considered in any patient with symptomatic bradycardia requiring ventricular pacing. Vijayaraman et al. reported an 84% success rate in 100 consecutive patients with AV block.¹⁸ The procedural success was higher in patients with AV nodal block (93%) than in patients with infranodal block (76%).¹⁸ The three proposed mechanisms for the correction of infranodal block are pacing the HB distal to the site of block, a virtual electrode polarisation effect and a differential source–sink relationship. The role of the HBP as an alternative to biventricular pacing for cardiac resynchronisation therapy (CRT) has been explored with good success.

In a retrospective study, Sharma et al. reported 90% procedural success for HBP in 106 CRT-eligible patients.¹⁹ On-treatment comparison analysis of the His-Sync Pilot trial showed that patients receiving His CRT had superior electrical resynchronisation and a non-significantly higher echocardiographic response than those receiving biventricular CRT.²⁰ In patients with dilated cardiomyopathy and left bundle branch block (LBBB), Huang et al. achieved a 76% success rate for permanent HBP to achieve CRT and demonstrated very high rates (>85%) of echocardiographic super-response (*Figure 3*).²¹

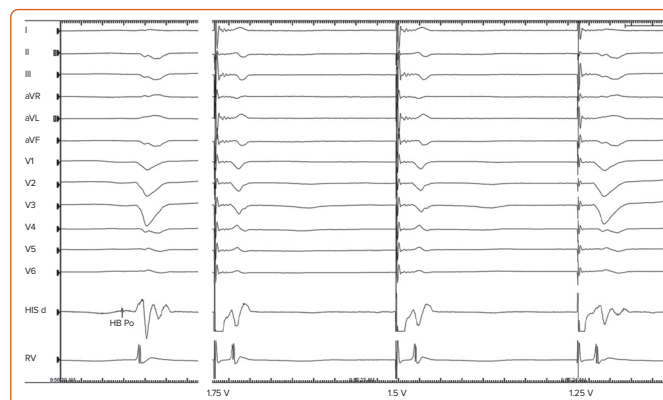
Vijayaraman et al. reported a 95% success rate for HBP in patients with AF and uncontrolled ventricular rates undergoing AV node ablation.²² LV ejection fraction improved from 43% to 50%, with a significant

Figure 2: Non-selective to Selective His Bundle Pacing



As the pacing output is reduced, note the change in QRS morphology and the local ventricular electrogram during non-selective to selective His bundle capture transition. HB Po = His potential.

Figure 3: Left Bundle Branch Block Correction by His Bundle Pacing



Complete correction of left bundle branch block could be achieved at a pacing output of 1.5 V at a pulse width of 1 ms (bundle branch block correction threshold). HB Po = His potential.

improvement in functional class.²² In another study of 94 patients undergoing AV node ablation, HBP was successful in 86% of patients with an improvement in LV ejection fraction (from $44.9 \pm 14.9\%$ [mean \pm standard deviation] at baseline to $57.6 \pm 12.5\%$ after a median follow-up of 3.0 years).²³ The efficacy of HBP may be uncertain in patients with intraventricular conduction delay, significant LV scar and in 10–30% of LBBB patients in whom the site of block may be distal to the HB.

Limitations of His Bundle Pacing

Although considered an acceptable alternative to RV pacing, HBP has some inherent limitations. Because the fibres are electrically insulated from the surrounding myocardium in the membranous septum, the capture threshold for HBP can be higher than that of RV pacing in 10–20% of patients. In our experience, HBP can be successfully achieved in >95% of patients with normal His–Purkinje conduction. In patients with a deeply seated HB, the helix may not be long enough to provide an acceptable pacing threshold. A capture threshold of >2 V at a pulse width of 1 ms may be seen in approximately 10% of patients and, before the advent of left bundle pacing, these values were accepted if NS-HB capture could be demonstrated with a significantly lower RV capture threshold. Approximately 12% of patients were noted to have an increase in pacing threshold of >1 V in our cohort of patients followed up for 5 years.²⁴ Lead revisions may be required during follow-up for an unacceptable increase in threshold in 5–7% of patients.¹⁰ During the early phase of the learning curve, RV back-up pacing with an additional

Table 1: Criteria for His Bundle Pacing

Baseline	Normal QRS		His–Purkinje Conduction Disease	
			With Correction	Without Correction
S-HBP	S-QRS = H-QRS with isoelectric interval		S-QRS ≤ H-QRS with isoelectric interval	
	Discrete local ventricular electrogram in HBP lead with S-V = H-V		Discrete local ventricular electrogram in HBP lead	
	Paced QRS = native QRS		Paced QRS < native QRS	
	Single capture threshold (His bundle)		Two distinct capture thresholds (HBP with BBB correction, HBP without BBB correction)	
NS-HBP	S-QRS < H-QRS (S-QRS usually 0, S-QRS _{end} = H-QRS _{end}) with or without isoelectric interval (pseudo-delta wave +/-)		S-QRS < H-QRS (S-QRS usually 0, S-QRS _{end} < H-QRS _{end}) with or without isoelectric interval (pseudo-delta wave +/-)	
	Direct capture of local ventricular electrogram in HBP lead by stimulus artefact (local myocardial capture)		Direct capture of local ventricular electrogram in HBP lead by stimulus artefact	
	Paced QRS > native QRS with normalisation of precordial and limb lead axes with respect to rapid dV/dt components of the QRS		Paced QRS ≤ native QRS	
	Two distinct capture thresholds (His bundle capture, RV capture)		Three distinct capture thresholds possible (HBP with BBB correction, HBP without BBB correction, RV capture)	

BBB = bundle branch block; dV/dt = rate of change in voltage; HBP = His bundle pacing; H-V = His–ventricular; H-QRS = His–QRS; NS-HBP = His bundle pacing; RV = right ventricle; S-HBP = selective His bundle pacing; S-QRS = stimulus–QRS; S-V = stimulus–ventricular. Source: Vijayaraman et al.¹⁴ Adapted with permission from Elsevier.

lead can be considered. However, if the unipolar pacing threshold is <1.5 V at a pulse width of 1 ms with COI at the time of implantation, back-up pacing may not be required. Other limitations include atrial oversensing, ventricular undersensing, premature battery depletion due to high output pacing and an inability to correct distal conduction system disease.

Left Bundle Branch Pacing

In an attempt to overcome the limitations of HBP, distal conduction system capture was first demonstrated by Huang et al. by deep septal placement of the lead.²⁵ LBBP is defined as the capture of either the proximal left bundle or one of its fascicles along with the septal myocardium at a low threshold.^{26,27} Anatomically, the left bundle branch is a wide target, with fibres fanning on the left subendocardial aspect of the proximal interventricular septum, compared with the narrow band of the HB. Criteria for confirming LBB capture have been proposed but not validated in large trials. LBB capture is confirmed by paced QRS morphology of RBB delay pattern (qR or rSR in lead V1) along with any one of the following criteria:^{26,27}

- Demonstration of non-selective to selective capture or non-selective to septal capture transition during threshold testing.
- Abrupt shortening of R-wave peak times (RWPT), as measured in leads V5 or V6 during lead implantation at the mid-septum and subsequent short and constant RWPT at the final site.
- Demonstration of LBB potential.
- Programmed deep septal stimulation from the pacing lead to demonstrate conduction system capture, especially selective capture.²⁷
- Meeting physiology-based electrocardiographic criteria, namely paced RWPT in V6 (measured from QRS onset) equals the native RWPT and paced RWPT (measured from the stimulus) equals the LBBP potential to V6.²⁹

Left Bundle Branch Pacing Implantation Techniques

The LBBP implantation tools are the same as those for HBP. Pre-implantation echocardiography should be performed to assess the

thickness of the interventricular septum in multiple views, the presence of septal scar, dilatation of cardiac chambers and valvular regurgitation. Careful assessment of the proximal septum is important because it determines procedural success.

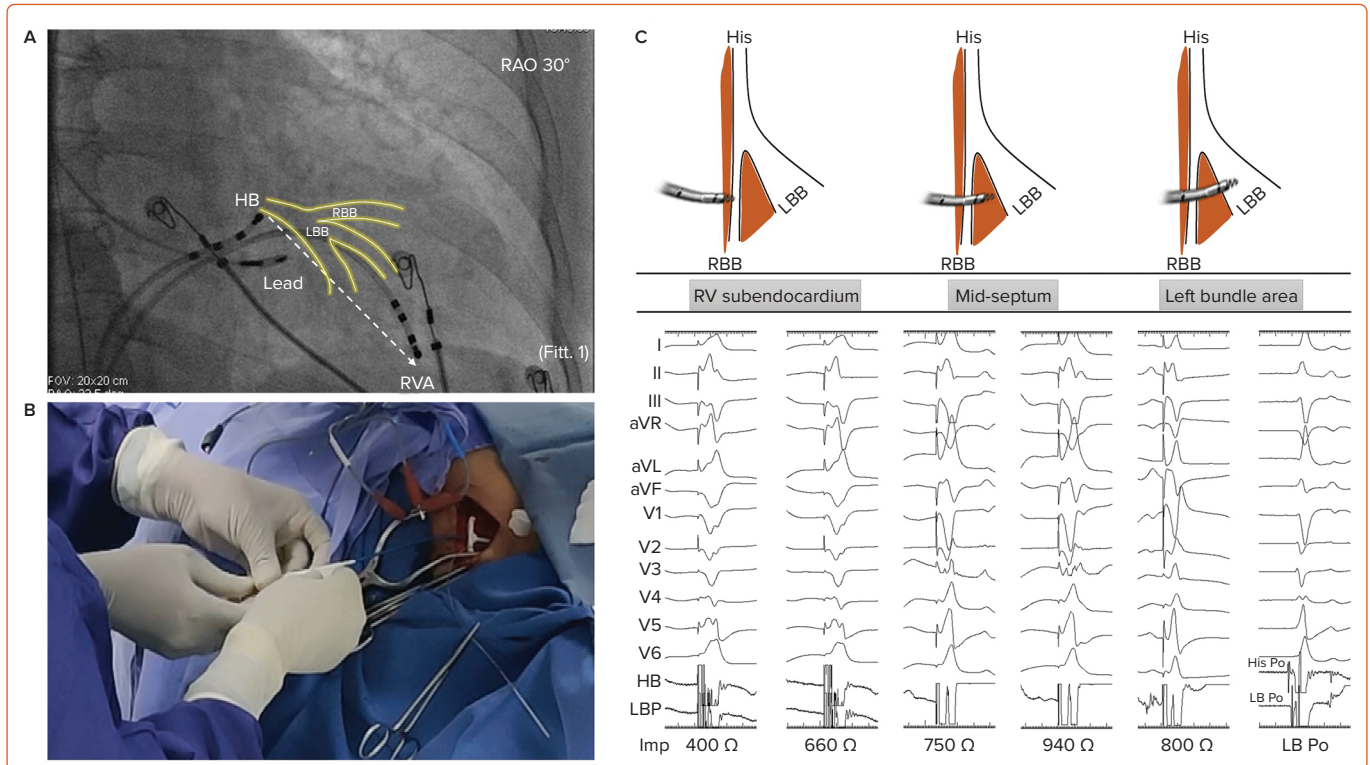
Intracardiac electrograms and 12-lead ECG are continuously recorded using an EP recording system. Placing a quadripolar mapping catheter across the HB is optional to delineate the distal extent of His electrograms. Alternatively, the pacing lead can be used to map the HB to mark its distal extent. After obtaining venous access, the C315 sheath, along with the 3830 lead (Figure 4), is placed in the proximal interventricular septum 1–1.5 cm below the distal HB along an imaginary line connecting the distal HB to the RVA in the RAO 30° fluoroscopic view. Pace mapping of the septum is done by gentle counterclockwise rotation of the sheath to obtain a paced QRS morphology of a ‘W’ pattern in lead V1 with the notch on the nadir of QRS, tall R in lead II, RS in lead III and discordant QRS complexes in leads aVR and aVL. Although classically described, the W pattern is not mandatory, and, in our experience, this is not seen in 20% of patients. The sheath should be held firmly with counterclockwise torque, with the hub of the sheath pointing towards the right hand of the implanter (3 o’clock to 4 o’clock position) to orient it perpendicular to the septum.

Once the optimal site is identified on the right side of the septum, lead deployment can be done by one of two techniques:

- conventional (gradual deployment with monitoring of paced QRS morphology and unipolar pacing impedance); or
- premature ventricular complex (PVC) guided (rapid deployment with monitoring of PVC morphology).

In the conventional technique, the lead is deployed gradually with a few rapid rotations at a time and monitoring of three important parameters: paced QRS morphology (the notch on the nadir of lead V1 will gradually ascend to form an R wave), unipolar pacing impedance (increases gradually before it drops by 100–200 Ω as the lead reaches the LV subendocardium) and myocardial COI on the lead electrogram.²⁶ A drop in pacing impedance of >200 Ω, unipolar impedance <400 Ω and a reduction

Figure 4: Left Bundle Branch Pacing Implantation Technique



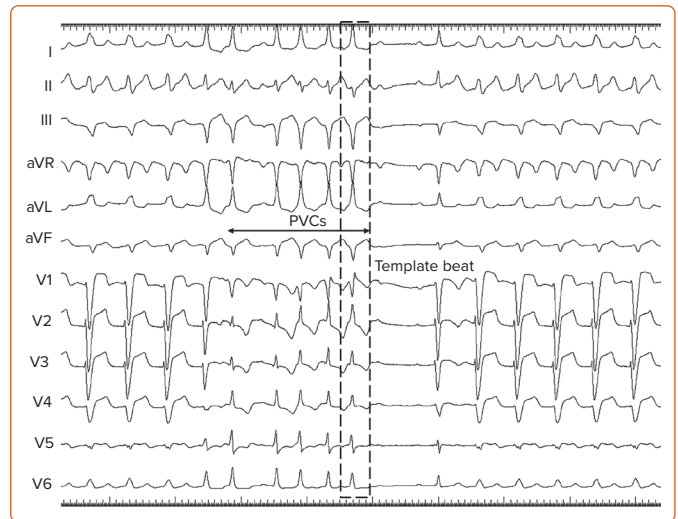
A: RAO fluoroscopic view showing the course of the HB and LBB. The ideal target site is 1–1.5 cm below the HB along an imaginary line connecting the distal HB to the RVA. B: Rapid rotation of the lead must be performed with the hub of the sheath pointing towards the 3- to 4-o'clock position, with preferably dry gloves closer to the sheath. C: Pacing the target site at the right side of the septum will show the 'W' pattern in lead V1, tall R in lead II and discordant QRS complexes in aVR and aVL. As the lead reaches the LBB area, paced QRS will show a qR pattern in lead V1 along with LB Po preceding the local ventricular electrogram. HB = His bundle; LBB = left bundle branch; LB Po = left bundle potential; RAO = Right anterior oblique; RBB = right bundle branch; RV = right ventricle; RVA = right ventricle apex.

in sensed R wave amplitude with loss of COI in the unipolar electrogram may suggest lead perforation into the LV cavity.

In the PVC-guided lead deployment technique, rapid turns are given to deploy the lead.³⁰ Lead movement during rapid deployment can be appreciated in the LAO 30° view. PVCs are commonly noted during rapid penetration of the lead into the septum (Figure 5). The morphology of PVCs changes from wide QRS with QS morphology in lead V1 to narrow QRS with an RBB delay pattern (qR/rSR) as the lead traverses from the right to left side of the septum. Template or fixation beat is defined as a PVC with an RBB delay pattern and a duration of <130 ms.^{29–31} Rotations should be stopped immediately on observing a template beat. LBB capture can be confirmed at this site by the aforementioned criteria. Template beat-guided LBBP is associated with less fluoroscopic time and minimal myocardial injury, and avoids septal perforation during lead deployment.^{29,31}

In patients with narrow QRS or RBBB morphology at baseline, a sharp high-frequency LBB potential should be seen preceding the local ventricular electrogram by 20–35 ms. In patients with LBBB, antegrade activation of LBB will not occur due to complete block of conduction in the distal HB/proximal LBB. LBB potential may be demonstrated by His-corrective pacing in patients with LBBB. In some patients the LBB potential may be masked due to significant COI. Concealed LBB potential must be considered before repositioning the lead if other parameters confirm LBB capture.³² Non-selective left bundle (NS-LB) to selective left bundle (S-LB) branch capture transition can be demonstrated during threshold testing at near-threshold output (Figure 6). S-LB capture is characterised by a distinct local ventricular electrogram on the pacing lead separate from the pacing artefact, along with a change in paced QRS morphology. NS-LB is characterised

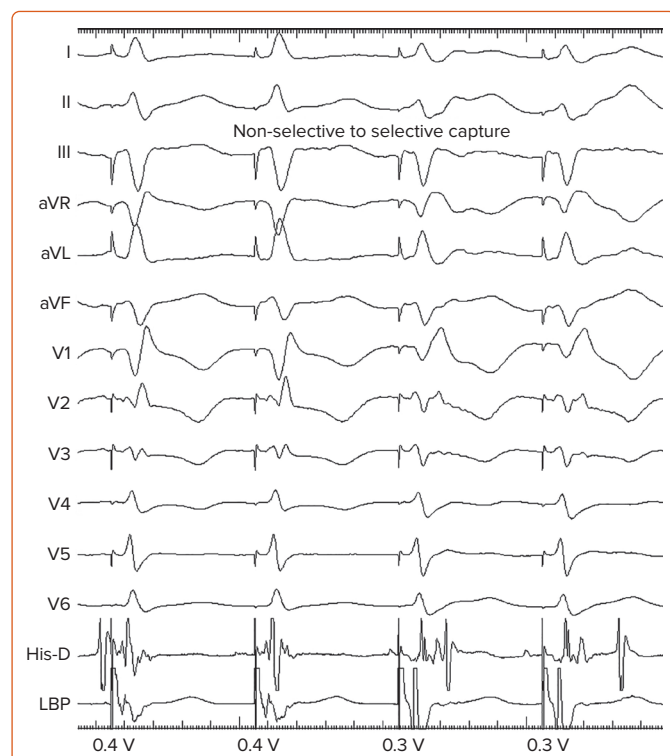
Figure 5: Template or Fixation Beats During Lead Deployment



PVCs are generated during lead deployment with morphology changing from QS to qR (template beat) in lead V1 as it reaches the left bundle branch area. PVC = premature ventricular complex.

by a pacing artefact immediately followed by a local ventricular electrogram with a pseudo-delta wave on the surface ECG. However, in many patients, demonstration of the isoelectric interval or discrete local electrogram may be difficult due to short stimulus to QRS intervals. RWPT is measured in leads V5 or V6 from the onset of the pacing spike to the peak of the R wave. Differential pacing at 10 and 2 V must produce short and constant RWPT (preferably <80 ms) to confirm the capture of the LBB. If peak LV activation time is prolonged at 2 V compared with

Figure 6: Non-selective to Selective Left Bundle Branch Capture



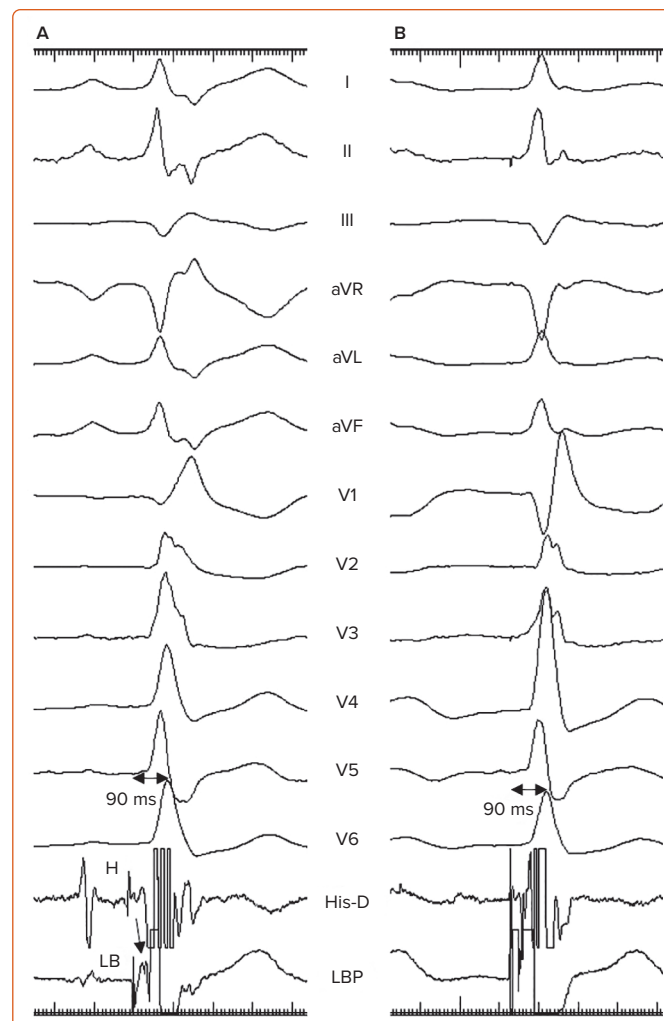
As the output is reduced from 0.4 to 0.3 V at a pulse width of 0.5 ms, non-selective to selective left bundle branch (LBB) capture is seen. Note the discrete local ventricular electrogram from the pacing artefact during selective capture of the LBB along with subtle changes in QRS morphology. LBP = left bundle pacing lead.

pacing at 10 V, additional turns are given to get the shortest RWPT. In patients with cardiomyopathy, LV hypertrophy and distal conduction system disease, RWPT is generally <90 ms, but occasionally may be longer.³³

The novel physiology-based ECG criteria for LBB capture proposed by Jastrzebski et al., namely paced RWPT in V6 (measured from QRS onset) equal to native V6 RWPT and paced RWPT (measured from stimulus) equal to the LBB potential to V6 RWPT (Figure 7), had sensitivity and specificity of 98–88% and 85–95% respectively.²⁹ When measured from stimulus, the optimal and 100% specific V6 RWPT values for differentiating LBB capture from LV septal capture in patients with narrow QRS/RBBB were 83 and 74 ms, respectively. In patients with LBBB/ventricular escape rhythm, the optimal and 100% specific values were 101 and 80 ms, respectively.²⁹

After confirming LBB capture, the sheath is gently pulled back into the right atrium with adequate lead slack. There is a tendency for the formation of an alpha loop in the lead while removing the sheath. The alpha loop can be undone in the RAO view by gently retracting the lead back with a counterclockwise rotation. Pacing parameters must be checked again in both the unipolar and bipolar configurations. Because part of the anode is often inside the septum, the anodal capture threshold must be checked by gradually reducing the pacing output in the bipolar configuration. Lead V1 will show changes in QRS morphology from the QS pattern (as the anode captures the right side of the septum) to the qR/rSR pattern once the anode loses its capture. Electroanatomical mapping with creation of 3D geometry of the atrium and ventricle, along with delineation of His signals to facilitate lead deployment, can minimise radiation exposure.³⁴

Figure 7: Physiology-based ECG Criteria for Left Bundle Branch Capture



R-Wave peak time in lead V6 during native rhythm (A), as measured from the onset of LBP, will be equal to the R-wave peak time during left bundle branch pacing (B), as measured from the onset of pacing artefact. Also note the LB current of injury immediately after the LBP (black arrow). H = His; LB = left bundle; LBP = left bundle branch potential.

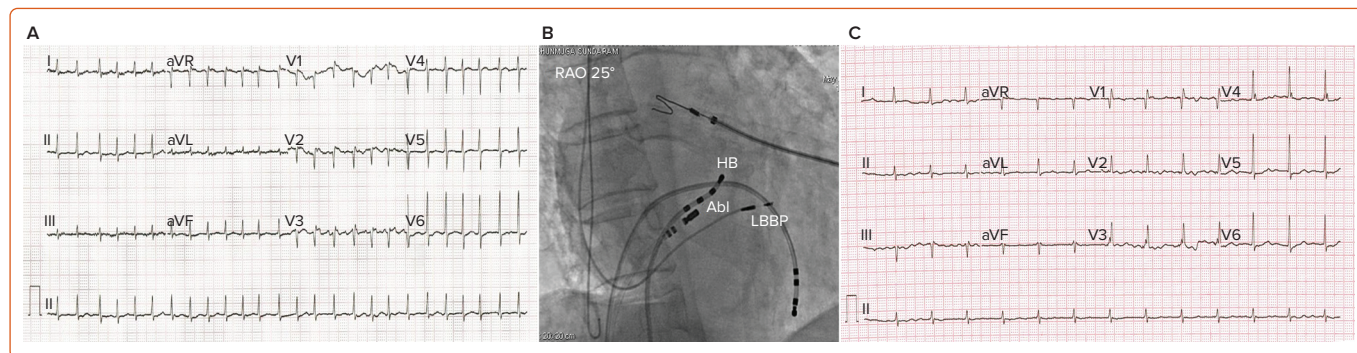
Troubleshooting Difficult Cases

The reported success rate for LBBP is between 80.5% and 97%.^{35–37} The reasons for failure include inability of the lead to penetrate deep into the septum, inadequate sheath support and improper sheath–septal orientation. Both the gloves and the lead must be dry while performing rapid rotations. If the basal septum is scarred, the left posterior fascicle can be targeted by placing the lead in mid-septum posteriorly.³⁸ Entanglement of the septal tricuspid leaflet may prevent deep septal penetration of the lead. To overcome this issue, the sheath is advanced towards the RV apex before bringing it back to the target site. RBB conduction delay created by pacing the LBB can be corrected by optimising the AV delay to allow native fusion, by programming pacing output to allow the anodal capture or by placing additional lead in the RV septum. In patients with cardiomyopathy and a diseased distal conduction system, LBBP may not result in ideal electrical resynchronisation. In these patients, LBBP may be combined with a coronary venous lead to achieve maximum electrical resynchronisation.

Clinical Implications

LBBP has the potential to overcome the limitations of HBP because it provides a low and stable threshold, excellent lead stability and the

Figure 8: Atrioventricular Junction Ablation and Left Bundle Branch Pacing



A: Baseline ECG showing AF with a fast ventricular rate. B: Note the distance between the Abl and the LBBP. C: Final paced QRS duration of 90 min with a qR pattern in V1. Abl = ablation catheter; HB = His bundle; LBBP = left bundle branch pacing lead; RAO = right anterior oblique.

ability to correct conduction disease in the distal HB/proximal LB. In patients with AV block after transcatheter aortic valve replacement, Vijayaraman et al. reported success rates of 63% and 93% for HBP and LBBP, respectively.³⁹ Huang et al. reported a 97% success rate in patients with non-ischaemic cardiomyopathy and LBBP, with significant improvement in LV function.⁴⁰

A retrospective multicentre study by Vijayaraman et al. reported an 85% acute procedural success rate for LBBP in 325 CRT-eligible patients.³³ LBBP resulted in a reduction in QRS duration from 152 to 137 ms, along with an improvement in LV ejection fraction from 33% to 44%.³³ In patients undergoing AV junction ablation, LBBP provides additional safety because the lead is away from the site of ablation compared with HBP (Figure 8).

Limitations of Left Bundle Branch Pacing

Although LBBP provides a low capture threshold, excellent lead stability and a shorter learning curve, long-term safety data are lacking. In a recent report of 632 patients, Su et al. reported a 97.8% success rate for LBBP.⁴¹

The mean follow-up time in that study was 18.6 months and the LBBP capture threshold remained stable at the 2-year follow-up. RBB injury was noted in 8.9% of patients and 1% of patients had either loss of capture or an increase in the threshold to >3 V with successful LBBP.⁴¹ Lead perforation into the LV cavity, RBB injury, myocardial trauma with troponin release, septal arterial injury and coronary cameral fistula are potential complications to be monitored.^{42–44} The implications of extraction of an LBBP lead implanted deep in the septum are unknown. Large-scale randomised multicentre studies are required to establish the long-term safety and efficacy of LBBP before it can be adopted as the main pacing strategy.

Conclusion

Conduction system pacing has gained significant interest over the past decade with the development of specially designed tools. HBP and LBBP are acceptable alternatives to RV pacing. The limitations of HBP are well addressed by LBBP, which provides a remarkably low and stable threshold. Early data suggest that HBP and LBBP may also be reasonable alternatives to biventricular pacing to achieve CRT. □

1. Tops LF, Schalij MJ, Bax JJ. The effects of right ventricular apical pacing on ventricular function and dyssynchrony implications for therapy. *J Am Coll Cardiol* 2009;54:764–76. <https://doi.org/10.1016/j.jacc.2009.06.006>; PMID: 19695453.
2. Poole JE, Singh JP, Birgersdotter-Green U. QRS duration or QRS morphology: what really matters in cardiac resynchronization therapy? *J Am Coll Cardiol* 2016;67:1104–17. <https://doi.org/10.1016/j.jacc.2015.12.039>; PMID: 26940932.
3. Kurshid S, Epstein AE, Verdino RJ, et al. Incidence and predictors of right ventricular pacing-induced cardiomyopathy. *Heart Rhythm* 2014;11:1619–25. <https://doi.org/10.1016/j.hrthm.2014.05.040>; PMID: 24893122.
4. Kaye GC, Linker NJ, Marwick TH, et al. Effect of right ventricular pacing lead site on left ventricular function in patients with high-grade atrioventricular block: results of the Protect-Pace study. *Eur Heart J* 2015;36:856–62. <https://doi.org/10.1093/eurheartj/ehu304>; PMID: 25189602.
5. Scherlag BJ, Lau SH, Helfant RH, et al. Catheter technique for recording His bundle activity in man. *Circulation* 1969;39:13–8. <https://doi.org/10.1161/01.CIR.39.1.13>; PMID: 5782803.
6. Deshmukh P, Casavant DA, Romanyshyn M, et al. Permanent, direct His-bundle pacing: a novel approach to cardiac pacing in patients with normal His–Purkinje activation. *Circulation* 2000;101:869–77. <https://doi.org/10.1161/01.CIR.101.8.869>; PMID: 10694526.
7. Tawara S. *Das Reizleitungssystem des Säugetierherzens*. Jena: Gustav Fischer, 1906;135–8.
8. Hudson REB. Surgical pathology of the conducting system of the heart. *Br Heart J* 1967;29:646–70. <https://doi.org/10.1136/hrt.29.5.646>; PMID: 6039160.
9. Kawashima T, Sasaki H. A macroscopic anatomical investigation of atrioventricular bundle locational variation relative to the membranous part of the ventricular septum in elderly human hearts. *Surg Radiol Anat* 2005;27:206–13. <https://doi.org/10.1007/s00276-004-0302-7>; PMID: 15723154.
10. Vijayaraman P, Chung MK, Dandamudi G, et al. His bundle pacing. *J Am Coll Cardiol* 2018;72:927–47. <https://doi.org/10.1016/j.jacc.2018.06.017>; PMID: 30115232.
11. Gu M, Niu H, Hu Y, et al. Permanent His bundle pacing implantation facility by visualization of the tricuspid valve annulus. *Circ Arrhythm Electrophysiol*. 2020;13:e008370. <https://doi.org/10.1161/CIRCEP.120.008370>; PMID: 32911981.
12. Zanon F, Marcantoni L, Zuin M, et al. Electrogram-only guided approach to His bundle pacing with minimal fluoroscopy: a single-center experience. *J Cardiovasc Electrophysiol* 2020;31:805–12. <https://doi.org/10.1111/jce.14366>; PMID: 31976602.
13. Sharma PS, Huang HD, Trohman RG, et al. Low fluoroscopy permanent His bundle pacing using electroanatomic mapping: a feasibility study. *Circ Arrhythm Electrophysiol*. 2019;12:e006967. <https://doi.org/10.1161/CIRCEP.118.006967>; PMID: 30704289.
14. Vijayaraman P, Dandamudi G, Zanon F, et al. Permanent His bundle pacing (HBP): recommendations from International HBP Collaborative Group for standardization of definitions, implant measurements and follow-up. *Heart Rhythm* 2018;15:460–8. <https://doi.org/10.1016/j.hrthm.2017.10.039>; PMID: 29107697.
15. Zhang J, Guo J, Hou X, et al. Comparison of the effects of selective and non-selective His bundle pacing on cardiac electrical and mechanical synchrony. *Europace* 2018;20:1010–7. <https://doi.org/10.1093/eurpace/eux120>; PMID: 28575215.
16. Upadhyay GA, Tung R. Selective versus nonselective His bundle pacing for cardiac resynchronization therapy. *J Electrocardiol* 2017;50:191–4. <https://doi.org/10.1016/j.jelectrocard.2016.10.003>; PMID: 27890282.
17. Beer D, Sharma PS, Subzposh FA, et al. Clinical outcomes of selective versus nonselective His bundle pacing. *JACC Clin Electrophysiol* 2019;5:766–74. <https://doi.org/10.1016/j.jacep.2019.04.008>; PMID: 31320004.
18. Vijayaraman P, Naperkowski A, Ellenbogen KA, Dandamudi G. Electrophysiologic insights into site of atrioventricular block: lessons from permanent His bundle pacing. *JACC Clin Electrophysiol* 2015;1:571–81. <https://doi.org/10.1016/j.jacep.2015.09.012>; PMID: 29759411.
19. Sharma PS, Dandamudi G, Herweg B, et al. Permanent His bundle pacing as an alternative to biventricular pacing for cardiac resynchronization therapy: a multicenter experience. *Heart Rhythm* 2018;15:413–20. <https://doi.org/10.1016/j.hrthm.2017.10.014>; PMID: 29031929.
20. Upadhyay GA, Vijayaraman P, Nayak HM, et al. On-treatment comparison between corrective His bundle pacing and biventricular pacing for cardiac resynchronization: a secondary analysis of His-SYNC pilot trial. *Heart Rhythm* 2019;16:1797–807. <https://doi.org/10.1016/j.hrthm.2019.05.009>; PMID: 31096064.
21. Huang W, Su L, Wu S, et al. Long-term outcomes of His bundle pacing in patients with heart failure with left bundle branch block. *Heart* 2019;105:137–43. <https://doi.org/10.1136/heartjnl-2018-313415>; PMID: 30093543.
22. Vijayaraman P, Subzposh FA, Naperkowski A. Atrioventricular node ablation and His bundle pacing. *Europace* 2017;19(Suppl 4):iv10–6. <https://doi.org/10.1093/eurpace/eux263>; PMID: 29220422.
23. Su L, Cai M, Wu S, et al. Long-term performance and risk factors analysis after permanent His-bundle pacing and atrioventricular node ablation in patients with atrial fibrillation and heart failure. *Europace* 2020;22(Suppl 2):ii19–26. <https://doi.org/10.1093/eurpace/euaa306>; PMID: 33370800.
24. Vijayaraman P, Naperkowski A, Subzposh FA, et al. Permanent His-bundle pacing: Long-term lead performance and clinical outcomes. *Heart Rhythm* 2018;15:696–702.

- <https://doi.org/10.1016/j.hrthm.2017.12.022>; PMID: 29274474.
25. Huang W, Su L, Wu S, et al. A novel pacing strategy with low and stable output: pacing the left bundle branch immediately beyond the conduction block. *Can J Cardiol* 2017;33:1736.e1–3. <https://doi.org/10.1016/j.cjca.2017.09.013>; PMID: 29173611.
 26. Huang W, Chen X, Su L, et al. A beginner's guide to permanent left bundle branch pacing. *Heart Rhythm* 2019;16:1791–6. <https://doi.org/10.1016/j.hrthm.2019.06.016>; PMID: 31233818.
 27. Ponnusamy SS, Arora V, Namboodiri N, et al. Left bundle branch pacing: a comprehensive review. *J Cardiovasc Electrophysiol* 2020;31:2462–73 <https://doi.org/10.1111/jce.14681>; PMID: 32681681.
 28. Jastrzebski M, Moskal P, Bednarek A, et al. Programmed deep septal stimulation – a novel maneuver for the diagnosis of left bundle branch capture during permanent pacing. *J Cardiovasc Electrophysiol* 2020;31:485–93. <https://doi.org/10.1111/jce.14352>; PMID: 31930753.
 29. Jastrzebski M, Keilbasa G, Curila K, et al. Physiology-based electrocardiographic criteria for left bundle branch capture. *Heart Rhythm* 2021;18:935–43. <https://doi.org/10.1016/j.hrthm.2021.02.021>; PMID: 33677102.
 30. Ponnusamy SS, Vijayaraman P. Left bundle branch pacing guided by premature ventricular complexes during implant. *HeartRhythm Case Rep* 2020;6:850–3 <https://doi.org/10.1016/j.hrcr.2020.08.010>; PMID: 33204621.
 31. Ponnusamy SS, Ganesan V, Syed T, et al. Template beat: a novel marker for left bundle branch capture during physiological pacing. *Circ Arrhythm Electrophysiol* 2021;14:e009677. <https://doi.org/10.1161/CIRCEP.120.009677>; PMID: 33858179.
 32. Ponnusamy SS, Vijayaraman P. Concealed left bundle branch potential during physiological pacing. *J Interv Card Electrophysiol* 2021;61:213–4. <https://doi.org/10.1007/s10840-020-00899-4>; PMID: 33146852.
 33. Vijayaraman P, Ponnusamy SS, Cano O, et al. Left bundle branch area pacing for cardiac resynchronization therapy: results from international LBBAP collaborative study group. *JACC Clin Electrophysiol* 2021;7:135–47. <https://doi.org/10.1016/j.jacep.2020.08.015>; PMID: 33602393.
 34. Ponnusamy SS, Bopanna D, Kumar S. Electro-anatomical mapping guided low fluoroscopy left bundle branch pacing. *JACC Clin Electrophysiol* 2020;6:1045–7. <https://doi.org/10.1016/j.jacep.2020.05.020>; PMID: 32819522.
 35. Vijayaraman P, Subzposh FA, Naperkowski A, et al. Prospective evaluation of feasibility, electrophysiologic and echocardiographic characteristics of left bundle branch area pacing. *Heart Rhythm* 2019;16:1774–82. <https://doi.org/10.1016/j.hrthm.2019.05.011>; PMID: 31136869.
 36. Ponnusamy SS, Muthu G, Kumar M, et al. Mid-term feasibility, safety and outcomes of left bundle branch pacing – single center experience. *J Interv Card Electrophysiol* 2021;60:337–46. <https://doi.org/10.1007/s10840-020-00807-w>; PMID: 32623624.
 37. Li Y, Chen K, Dai Y, et al. Left bundle branch pacing for symptomatic bradycardia: implant success rate, safety, and pacing characteristics. *Heart Rhythm* 2019;16:1758–65. <https://doi.org/10.1016/j.hrthm.2019.05.014>; PMID: 31125667.
 38. Ponnusamy SS, Syed T, Kumar S. Left posterior fascicular pacing. *J Innov Card Rhythm Manag* 2021;12:4493–6. <https://doi.org/10.19102/icrm.2021.120506>; PMID: 34035980.
 39. Vijayaraman P, Cano O, Koruth JS, et al. His–Purkinje conduction system pacing following transcatheter aortic valve replacement – feasibility and safety. *JACC Clin Electrophysiol*. 2020;6:649–57. <https://doi.org/10.1016/j.jacep.2020.02.010>; PMID: 32553214.
 40. Huang W, Wu S, Vijayaraman P, et al. Cardiac resynchronization therapy in patients with non-ischemic cardiomyopathy utilizing left bundle branch pacing. *JACC Clin Electrophysiol* 2020;6:849–58 <https://doi.org/10.1016/j.jacep.2020.04.011>; PMID: 32703568.
 41. Su L, Wang S, Wu S, et al. Long-term safety and feasibility of left bundle branch pacing in a large single-center study. *Circ Arrhythm Electrophysiol* 2021;14:e009261. <https://doi.org/10.1161/CIRCEP.120.009261>; PMID: 33426907.
 42. Ravi V, Larsen T, Ooms S, et al. Late-onset interventricular septal perforation from left bundle branch pacing. *HeartRhythm Case Rep* 2020;6:627–31. <https://doi.org/10.1016/j.hrcr.2020.06.008>; PMID: 32983881.
 43. Ponnusamy SS, Patel NR, Naperkowski A, et al. Cardiac troponin release following left bundle branch pacing. *J Cardiovasc Electrophysiol* 2021;32:851–5. <https://doi.org/10.1111/jce.14905>; PMID: 33484212.
 44. Ponnusamy SS, Vijayaraman P. Aborted ST-elevation myocardial infarction – an unusual complication of left bundle branch pacing. *HeartRhythm Case Rep* 2020;6:520–2. <https://doi.org/10.1016/j.hrcr.2020.05.010>; PMID: 32817832.