

KAMIŃSKA, Magdalena, STRZODA, Adam, JUDA, Agata, ROJEK, Kornelia, STRZODA, Anna, SOWIŃSKI, Wojciech & POLAK, Agnieszka. Osilodrostat therapy in a 26-year-old patient after ineffective surgical treatment of Cushing Disease: a case report. *Journal of Education, Health and Sport*. 2023;13(1):203-208. eISSN 2391-8306. DOI <http://dx.doi.org/10.12775/JEHS.2023.13.01.030> <https://apcz.umk.pl/JEHS/article/view/40943> <https://zenodo.org/record/7389389>

The journal has had 40 points in Ministry of Education and Science of Poland parametric evaluation. Annex to the announcement of the Minister of Education and Science of December 21, 2021. No. 32343. Has a Journal's Unique Identifier: 201159. Scientific disciplines assigned: Physical Culture Sciences (Field of Medical sciences and health sciences); Health Sciences (Field of Medical Sciences and Health Sciences). Punkty Ministerialne z 2019 - aktualny rok 40 punktów. Załącznik do komunikatu Ministra Edukacji i Nauki z dnia 21 grudnia 2021 r. Lp. 32343. Posiada Unikatowy Identyfikator Czasopisma: 201159. Przypisane dyscypliny naukowe: Nauki o kulturze fizycznej (Dziedzina nauk medycznych i nauk o zdrowiu); Nauki o zdrowiu (Dziedzina nauk medycznych i nauk o zdrowiu). © The Authors 2022. This article is published with open access at Licensee Open Journal Systems of Nicolaus Copernicus University in Torun, Poland Open Access. This article is distributed under the terms of the Creative Commons Attribution Noncommercial License which permits any noncommercial use, distribution, and reproduction in any medium, provided the original author (s) and source are credited. This is an open access article licensed under the terms of the Creative Commons Attribution Non commercial license Share alike. (<http://creativecommons.org/licenses/by-nc-sa/4.0/>) which permits unrestricted, non commercial use, distribution and reproduction in any medium, provided the work is properly cited. The authors declare that there is no conflict of interests regarding the publication of this paper. Received: 03.11.2022. Revised: 20.11.2022. Accepted: 30.11.2022.

Osilodrostat therapy in a 26-year-old patient after ineffective surgical treatment of Cushing Disease: a case report

Magdalena Kamińska¹, Adam Strzoda¹, Agata Juda¹, Kornelia Rojek¹, Anna Strzoda¹, Wojciech Sowiński¹, Agnieszka Polak²

1 Student Scientific Society at Department of Endocrinology, Diabetology and Metabolic Diseases, Medical University of Lublin, Kazimierza Jaczewskiego 8, 20-400 Lublin, Poland

2 Department of Endocrinology, Diabetology and Metabolic Diseases, Medical University of Lublin, Kazimierza Jaczewskiego 8, 20-400 Lublin, Poland

Magdalena Kamińska: <https://orcid.org/0000-0002-7624-4146> e-mail: mkaminska99@gmail.com

Adam Strzoda: <https://orcid.org/0000-0002-1928-2664> e-mail: adamjanstrzoda@gmail.com

Agata Juda: <https://orcid.org/0000-0003-3583-7305> e-mail: agatajuda15@gmail.com

Kornelia Rojek: <https://orcid.org/0000-0002-5096-1235> e-mail: rojekkornelia@gmail.com

Anna Strzoda: <https://orcid.org/0000-0002-4839-3531> e-mail: annastrzoda2000@gmail.com

Wojciech Sowiński: <https://orcid.org/0000-0002-2267-4773> e-mail: wojciechjansowinski@gmail.com

Agnieszka Polak: <https://orcid.org/0000-0003-1694-4738> e-mail: agnieszka.polak@icloud.com

Abstract

Cushing's Disease is caused by pituitary adenoma which produces adrenocorticotrophic hormone causing hypercortisolemia. First-line treatment involves operative removal of the tumor, however, in some patients it proves ineffective. In those cases, pharmacological treatment is necessary as untreated Cushing's Disease may be lethal. In 2020 a new steroidogenesis inhibitor – Osilodrostat - was approved by the European Medicines Agency and can be used in the treatment of patients who cannot undergo pituitary surgery or whose previous surgical treatment proved ineffective.

We present a case of a 26-year-old female patient who was diagnosed with endogenous Cushing's Disease and underwent two consecutive operations to remove the tumor - both were ineffective. With deteriorating laboratory results and other pharmacological treatments exhausted Osilodrostat therapy was introduced.

Osilodrostat is becoming an important drug in patients with Cushing's Disease refractory to other treatments.

Key Words: ACTH-dependent Cushing syndrome; Osilodrostat; Steroidogenesis Inhibitor.

Introduction

Cushing's disease (CD) is a rare endocrinological disorder with hypercortisolemia caused by the excess of adrenocorticotrophic hormone (ACTH) produced by the pituitary adenoma. (1) Normally ACTH is released from the pituitary gland and induces cortisol production by the adrenal glands. The excess of ACTH produced outside the pituitary gland results in Cushing syndrome (CS). (2) In disorders mentioned above symptoms such as central obesity (moon face, buffalo hump), muscle atrophy of the limbs, red stretch marks on the abdomen, thighs, breasts, and arms, hirsutism and facial plethora can be observed. (3) Based on epidemiological studies in Europe the incidence of CD is approximately 2.4 per million inhabitants per year. (3) Without treatment the 5 years survival of patients with CD is around 50%. (4)

The presented case pertains to a 26-year-old woman who was diagnosed with ACTH-dependent Cushing syndrome and was treated with Osilodrostat (Isturisa) due to a poor response to other therapeutic methods.

Case report

We report on a 26-year-old female patient who was referred to the Department of Endocrinology with suspicion of Cushing's Syndrome. Symptoms reported by the patient and observed on admission included hypertension (up to 160/110 mmHg) with co-existing headaches, amenorrhea (for 6 months), wide, red stretch marks on the abdomen, weight loss, hair loss, and rounding of the face. (Figure 1)

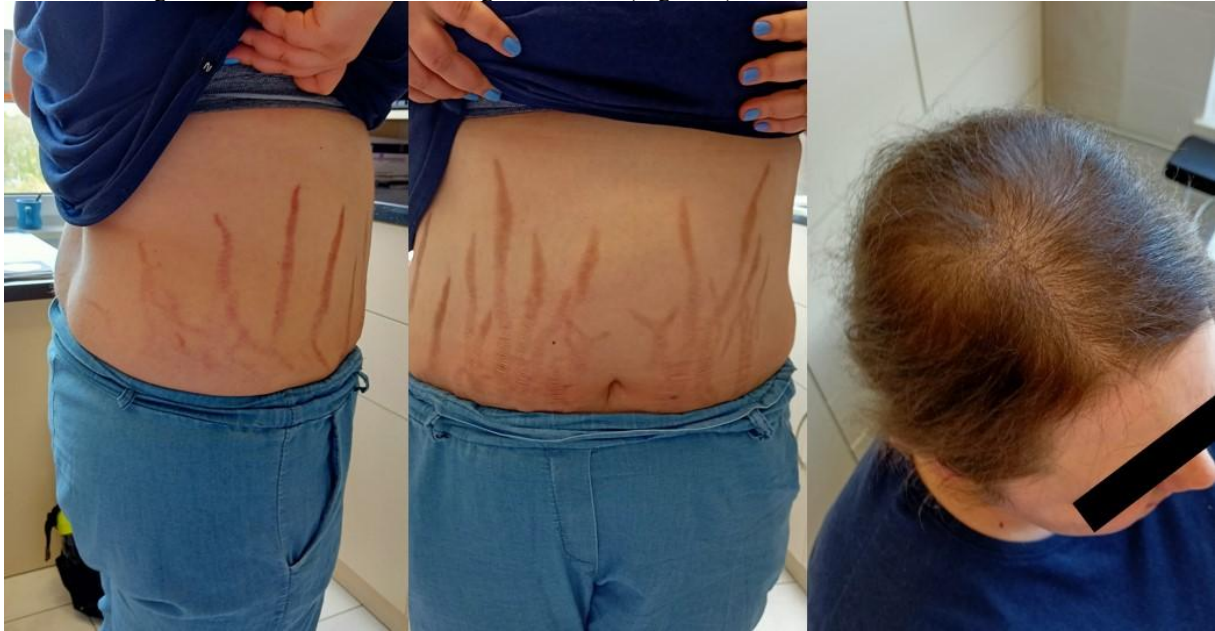

Figure 1 Symptoms noticed during admission - red stretch marks on the abdomen and hair loss

Pre-admission laboratory results indicated hyperemia (Hb=17 g/dL, RBC= $5,33 \times 10^6$ /uL, Ht=53%), showed elevated testosterone (115 ng/dL), dehydroepiandrosterone sulfate (DHEA-S) (1171 ug/dL), and morning cortisol (420 ng/mL]). The patient had a history of premature puberty (~10 years of age).

The dexamethasone suppression test (DST) with 8 mg of Dexamethasone revealed no decrease in cortisol in the serum. In the corticotropin-releasing hormone (CRH) stimulation test after 15 minutes, ACTH levels rose from 47 pg/mL to 72 pg/mL and cortisol rose from 30 μ g/dL to 34 μ g/dL. In laboratory findings, elevated levels of testosterone, androstenedione, and liver enzymes were observed alongside hypernatremia and hypokalemia. Because of high cortisolemia, Ketoconazole treatment was started with a dose of 1000 mg/day. Due to contradictory results of the DST and CRH stimulation test a pituitary magnetic resonance imaging (MRI) was taken. The pituitary gland was not enlarged with no features of microadenoma. To exclude the ectopic secretion of ACTH a positron emission tomography scan (PET) was taken. In the meantime, Ketoconazole was changed to Metyrapone in a daily dose of 1500 mg which was then enlarged to 2000 mg and later 2500 mg with good results - a significant decrease of cortisol in serum and normalization of its excretion in a 24-hour urine collection. On account of no conclusive findings in imaging tests (Figure 2), inferior petrosal sinuses sampling (IPSS) was performed, which confirmed ACTH-dependent hypercortisolemia of pituitary origin.

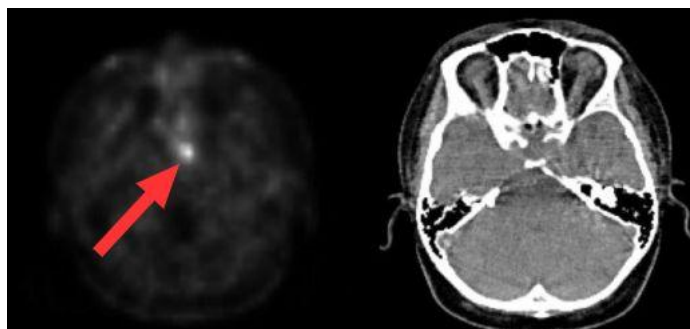


Figure 2 Pituitary imaging (PET CT - left image, CT - right image) with the possible location of the tumor pointed by the red arrow

The patient underwent two consecutive pituitary adenoma operations through the sphenoid sinus. Post-operative levels of cortisol and ACTH were long-term elevated and surgical treatment proved ineffective.

Due to the adversary effects of previous treatment – elevated testosterone levels, and androgenization symptoms a decision to use combined therapy using Pasireotide, Ketoconazole and Cabergoline was made. However, this therapy was insufficient - cortisol in serum and urine remained strongly elevated despite maximal doses. On this ground, a steroidogenesis inhibitor - Osilodrostat was prescribed. The patient received a starting dose of 4 mg/day which was consequently risen to 10 mg, 16 mg, and ultimately to 30 mg per day. The Osilodrostat therapy at first brought a significant decrease in cortisol levels in serum and cortisol excretion in a 24-hour urine collection was only slightly elevated. Unfortunately, later the drug seemed to be less successful the levels of cortisol in serum and in urine fluctuated as well as testosterone remained elevated and the patient noticed the exacerbation of androgenization symptoms. As of today, the patient remains under endocrinological care with continuous evaluation of treatment and its effects.

Discussion

When diagnosing a patient with hypercortisolemia the first step is to distinguish ACTH-dependent from independent CS. Standard procedures determining the type of CS are morning ACTH levels in serum, DST, and CRH stimulation test. Our patient's laboratory results suggested an ACTH-dependent CS. To confirm the initial diagnosis, imaging tests such as MRI and PET scan were taken as well as IPSS was performed. The latter confirmed decision to operate on the pituitary gland was made as the first-line therapy for patients with CS is an initial resection of the primary lesions. (5) (6) In our patient a surgical removal of the suspected pituitary tumor was performed twice, however soon after the operation the cortisol in serum, as well as ACTH, elevated. With no success in surgical treatment, the patient remained on pharmacological therapy.

The first drug introduced to control hypercortisolemia was Ketoconazole (600 mg/day). This antifungal agent inhibits steroidogenic enzymes 11 β -hydroxylase, 17-hydroxylase, and 18-hydroxylase and has an estimated efficacy of 70% in CS treatment. (7)

In our patient's case, no significant improvement was found after Ketoconazole treatment (Table 1) and Metyrapone was introduced into the therapy with a daily dose of 1500 mg/day.

Laboratory parameters	Reference range	Admission	Ketoconazole initiation (600 mg per day)	Ketoconazole highest dose (1000 mg per day)	Metyrapone initiation (1500 mg per day)	Metyrapone highest dose (2500 mg per day)	Pasireotide, Ketoconazole, Cabergoline	Osilodrostat initiation (4 mg per day)	Osilodrostat highest dose (30 mg per day)
ACTH [pg/mL]	7,20 – 63,60	50,27	72,72	82,71	73,81	48,15	172,10	88,06	249,30
Cortisol in serum [μ g/dL]	4,30 – 22,40	24,40	34,40	29,20	49,10	42,20	49,10	39,50	24,02
Cortisol in urine [μ g/24h]	20,90 – 292,30	635,50	876,30	430,10	577,50	525,00	577,50	869,00	433,40
Testosterone [ng/dL]	12,0 – 59,0	77,8	-	-	-	-	-	52,00	212,10
Androstenedione [ng/mL]	0,4 – 3,4	-	3,53	1,01	-	-	-	-	25,96
(DHEA-S) [μ g/dL]	98,80 – 340,00	920,70	-	431,20	-	-	-	-	-

Table 1 Laboratory parameters on various types of medication

Metyrapone is an inhibitor of 11 β -hydroxylase and blocks the last stage of steroidogenesis. The effectiveness of Metyrapone therapy in CS reaches 75%. A rare complication of Metyrapone therapy is a compensatory increase in ACTH production resulting from a decrease in cortisol-mediated negative feedback on the corticotrophic adenoma which may lead to an increase in cortisol and androgens production. (8,9) This compensatory mechanism could explain elevated testosterone which was noticed on a follow-up. During Metyrapone treatment, our patient had the best results with lowered urinary-free cortisol (UFC) and serum cortisol, however, androgenization syndromes as well as episodes of hypertension prompted the physicians to change the treatment.

A combined therapy using Pasireotide, Ketoconazole, and Cabergoline was initiated. In a study of patients with severe CD, the combination normalized UFC levels in 67% of patients. (10) Pasireotide is a somatostatin analog that is the only pituitary-directed drug approved in the EU for CS treatment aimed to decrease ACTH levels as well as cortisol levels in serum and urine. (11) Unfortunately, in our patient, the levels of cortisol in urine remained strongly elevated, however it has decreased ACTH and cortisol levels in serum. Cabergoline is another drug used in this treatment. It has a high affinity for dopamine 2 receptors (D2Rs), which are commonly expressed in 80% of human corticotroph tumors. (11) It was used in hope of minimizing the size of the pituitary tumor and consequently resolving the metabolic symptoms of CD, however it remained ineffective. With no other therapeutic options available, Osilodrostat therapy was initiated.

Osilodrostat is a novel 11- β -hydroxylase and aldosterone synthase inhibitor, approved by the European Medicines Agency in 2020 for the treatment of endogenous CS. It has been used in the treatment of patients who cannot undergo pituitary surgery or whose previous surgical treatment proved ineffective. (12)

It is an oral nonsteroidal corticosteroid inhibitor with three times higher affinity than Metyrapone. In addition, in comparison to Metyrapone lower doses of Osilodrostat may be sufficient to reach the same effects on cortisol levels. Osilodrostat has also a longer half-life than Metyrapone, which allows less frequent dosage. (6) In our patient the first 12 weeks of the therapy with Osilodrostat resulted in a decrease in UFC and cortisol in serum by nearly 50% (Tables 2 and 3), now a raise in both parameters is observed.

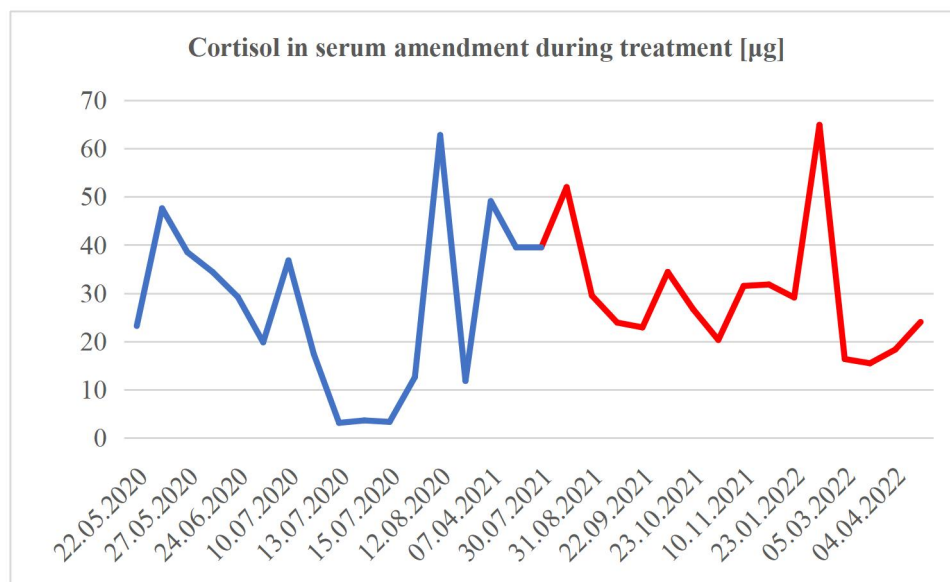


Table 2 Amendment of cortisol in serum during treatment. The red color indicates results during Osilodrostat therapy

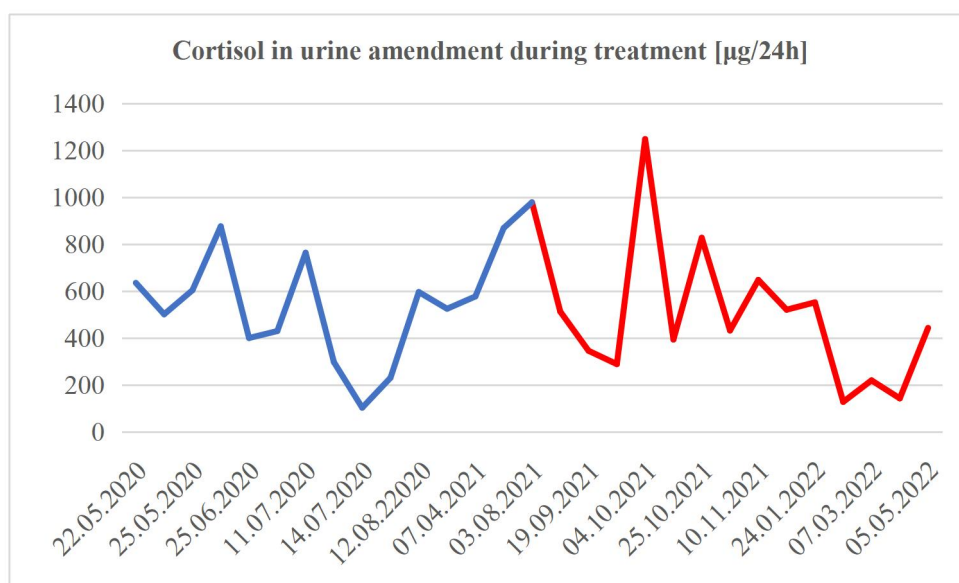


Table 3 Amendment of cortisol in urine during treatment. The red color indicates results during Osilodrostat therapy

The fluctuance in the levels of cortisol in serum and urine in our patient during Osilodrostat therapy is not coherent with most studies where after 22 weeks nearly 80% of the patients have mean urinary cortisol within the normal range. (6)(13) Some studies on animal models suggest good results in a combined Pasireotide and Osilodrostat therapy, however, no studies on humans were conducted, and possible adversary effects are expected. (14)

In most of the patients during clinical trials of Osilodrostat monotherapy, improvements in parameters such as body weight, fasting plasma glucose, and blood pressure were observed. (15) Also at least one physical feature of CS such as central obesity (moon face), muscle atrophy of the limbs, red stretch marks and facial plethora has improved in over 25% of examined, buffalo hump improvement was observed in over 50% of patients during Osilodrostat treatment. (15) Alleviation of some CD symptoms was reported by our patient - weight loss and decrease in hair loss. On the other hand, Osilodrostat can cause hypokalemia, QTc prolongation, and hypertension. (16) Fortunately none of the symptoms above were observed in our patient during Osilodrostat therapy. Moreover, patients on Osilodrostat therapy may have elevated testosterone levels which cause hirsutism, acne and secondary amenorrhea, which were observed in our patient throughout the treatment. (17) For those reasons hormone replacement therapy was introduced by the gynecologist. However, it was decided to continue the Osilodrostat treatment since the elevated testosterone levels are reported to be transient in other patients treated with this oral nonsteroidal corticosteroid inhibitor. (13,16) To this day we continue to treat our patient with Osilodrostat, due to the lack of other options, since the pros outweigh the cons, however, we are aware that the patient's affliction is floating and the alteration in treatment is likely. Higher doses of Osilodrostat might be necessary, on the other hand, more adversary effects are expected. A combined therapy using Ketoconazole (dose 600 mg/day) and Osilodrostat (30 mg/day) appears promising. That combination was reported to be highly effective in terms of cortisol secretion. Additionally lower doses than those applied in monotherapy were used which minimized the adversary effects previously observed in a single therapy. (18) However to our knowledge it was a single case stated in literature treated using this combined therapy and further data considering this treatment are awaited.

Conclusions

CD is a severe condition that left untreated deteriorates life quality and may be life-threatening. With no improvements after the first-line operative approach, our patient was treated with various medicaments including a novel nonsteroidal corticosteroid inhibitor of the 11- β -hydroxylase and aldosterone synthase – Osilodrostat. To this day the anticipated laboratory and clinical results (physical symptoms, cortisol in serum and in urine) were not met and alteration of the treatment might be necessary.

Disclosure

The authors declare no conflict of interest.

References

1. Pivonello R, De Leo M, Cozzolino A, Colao A. The Treatment of Cushing's Disease. *Endocr Rev.* 2015 Aug;36(4):385-486. <https://doi.org/10.1210/er.2013-1048>
2. Pluta RM, Burke AE, Golub RM. Cushing Syndrome and Cushing Disease. *JAMA.* 2011;306(24):2742. <https://doi.org/10.1001/jama.2011.1694>
3. Sharma ST, Nieman LK, Feelders RA. Cushing's syndrome: epidemiology and developments in disease management. *Clin Epidemiol.* 2015 Apr 17;7:281-93. <https://doi.org/10.2147/CLEP.S44336>
4. Clayton RN. Mortality in Cushing's disease. *Neuroendocrinology.* 2010;92 Suppl 1:71-6. <https://doi.org/10.1159/000315813>
5. Nieman LK, Biller BMK, Findling JW, Murad MH, Newell-Price J, Savage MO, et al. (2015). Treatment of Cushing's syndrome: An endocrine society clinical practice guideline. *Journal of Clinical Endocrinology and Metabolism* 100, 2807–2831. <https://doi.org/10.1210/jc.2015-1818>
6. Pivonello R, Ferrigno R, De Martino MC, Simeoli C, Di Paola N, Pivonello C, et al. Medical Treatment of Cushing's Disease: An Overview of the Current and Recent Clinical Trials. *Front Endocrinol (Lausanne).* 2020 Dec 8;11:648. <https://doi.org/10.3389/fendo.2020.00648>
7. Castinetti F, Morange I, Jaquet P, Conte-Devolx B, Brue T. Ketoconazole revisited: a preoperative or postoperative treatment in Cushing's disease. *Eur J Endocrinol.* 2008 Jan;158(1):91-9. <https://doi.org/10.1530/EJE-07-0514>
8. Carballeira A, Fishman LM, Jacobi JD. Dual sites of inhibition by metyrapone of human adrenal steroidogenesis: correlation of in vivo and in vitro studies. *J Clin Endocrinol Metab.* 1976 Apr;42(4):687-95. <https://doi.org/10.1210/jcem-42-4-687>
9. Verhelst JA, Trainer PJ, Howlett TA, Perry L, Rees LH, Grossman AB, et al. Short and long-term responses to metyrapone in the medical management of 91 patients with Cushing's syndrome. *Clin Endocrinol (Oxf).* 1991 Aug;35(2):169-78. <https://doi.org/10.1111/j.1365-2265.1991.tb03517.x>
10. Fleseriu M, Castinetti F. Updates on the role of adrenal steroidogenesis inhibitors in Cushing's syndrome: a focus on novel therapies. *Pituitary.* 2016 Dec;19(6):643-653. <https://doi.org/10.1007/s11102-016-0742-1>
11. Nishioka H, Yamada S. Cushing's Disease. *J Clin Med.* 2019 Nov 12;8(11):1951. <https://doi.org/10.3390/jcm8111951>
12. Groselj U, Sikonja J, Battelino T. Osilodrostat for Cushing disease and its role in pediatrics. *Horm Res Paediatr.* 2022 Jan 19. <https://doi.org/10.1159/000522054>
13. Castinetti F, Nieman LK, Reincke M, Newell-Price J. Approach to the Patient Treated with Steroidogenesis Inhibitors. *J Clin Endocrinol Metab.* 2021 Jun 16;106(7):2114-2123. <https://doi.org/10.1210/clinem/dgab122>
14. Li L, Vashisht K, Boisclair J, Li W, Lin TH, Schmid HA, et al. (2015). Osilodrostat (LCI699), a potent 11 β -hydroxylase inhibitor, administered in combination with the multireceptor-targeted somatostatin analog pasireotide: A 13-week study in rats. *Toxicology and Applied Pharmacology*, 286(3), 224–233. <https://doi.org/10.1016/j.taap.2015.05.004>
15. Gadelha M, Bex M, Feelders RA, Heaney AP, Auchus RJ, Gilis-Januszewska A, et al. Randomized Trial of Osilodrostat for the Treatment of Cushing Disease. *J Clin Endocrinol Metab.* 2022 Jun 16;107(7):e2882-e2895. <https://doi.org/10.1210/clinem/dgac178>
16. Fleseriu M, Biller BMK. Treatment of Cushing's syndrome with osilodrostat: practical applications of recent studies with case examples. *Pituitary.* 2022 Aug 24:1–15. <https://doi.org/10.1007/s11102-022-01268-2>
17. Witek P, Mehlich A, Stasiewicz A, Jawiarczyk-Przybyłowska A, Bolanowski M. Osilodrostat - an emerging drug for the medical management of Cushing's disease. *Endokrynol Pol.* 2022;73(2):371-374. <https://doi.org/10.5603/EP.a2022.0009>
18. Amodru V, Brue T, Castinetti F. Synergistic cortisol suppression by ketoconazole-osilodrostat combination therapy. *Endocrinol Diabetes Metab Case Rep.* 2021 Dec 1;2021:21-0071. <https://doi.org/10.1530/EDM-21-0071>