










Mucosal Melanoma In Situ of the Oral Cavity: A Case Report and Systematic Review of the Literature

Systematic Review

✦  Polly Jasper¹,  W. Nicholas Jungbauer¹,  Nicolas S. Poupore¹,
 Shaun A. Nguyen¹,  Jim Howell²,  Brad W. Neville³,  Terry A. Day⁴

¹Department of Otolaryngology - Head and Neck Surgery, Medical University of South Carolina, Charleston, SC, United States

²Carolinas Center for Oral and Facial Surgery, Greenville, SC, United States

³Director of Oral and Maxillofacial Pathology, HCA South Atlantic Division, Charleston, SC, United States

⁴Director of Head and Neck Oncology, Sarah Cannon National Group, Charleston, SC, United States

Abstract

Objective: Malignant mucosal melanomas of the head and neck comprise a very small portion of all melanomas, particularly in the oral cavity. These lesions are associated with high rates of local recurrence, distant metastasis, and a very poor 5-year survival rate; however, the clinical outcomes of mucosal melanoma in situ of the oral cavity are unclear. Therefore, we present a case report of mucosal melanoma in situ and a systematic review of the literature to shed light on this rare but important disease.

Methods: PubMed, Scopus, and CINAHL were searched per the Preferred Reporting Items for Systematic Reviews and Meta-Analyses guidelines. Studies were only considered for inclusion if they described oral cavity melanoma in situ and documented specific data pertaining to treatment including modality, lesion size, or outcomes.

Results: A total of 28 reported cases from the literature fulfilled the inclusion criteria, as well as one case from our own institution. Men comprised the majority (64.3%) of the cases, and the average age at presentation was 57.4 years. The hard palate was the most common location, and most cases were treated with surgical excision. Eight had no evidence of disease after a minimum of six months of follow-up, one reported spread to the cervical lymph nodes, and only one reported progression with distant metastasis.

Conclusion: Oral mucosal melanoma in situ is a rare entity and most commonly treated with surgical excision. High rates of recurrence necessitate long term follow-up. Further studies may be useful to determine whether adjuvant therapy may play a role in reducing recurrence.

Keywords: Mucosal melanoma in situ, oral cavity, hard palate, management, systematic review

ORCID ID of the authors:

P.J. 0000-0002-9060-9922;
W. N.J. 0000-0003-0223-4698;
N.S.P. 0000-0002-6907-488X;
S.A.N. 0000-0003-0664-4571;
B.W.N. 0000-0001-9667-7267;
J.H. 0000-0001-7383-7424;
T.A.D. 0000-0003-1431-4214.

Cite this article as: Jasper P, Jungbauer WN, Poupore NS, Nguyen SA, Howell J, Neville BW, Day TA. Mucosal Melanoma In Situ of the Oral Cavity: A Case Report and Systematic Review of the Literature. Turk Arch Otorhinolaryngol 2022;60(3): 161-9.

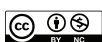Corresponding Author:

Polly Jasper,
jasperp@musc.edu

Received Date: 14.08.2022

Accepted Date: 07.09.2022

Content of this journal is licensed under a Creative Commons Attribution 4.0 International License. Available online at www.turkarchotolaryngol.net



DOI: 10.4274/tao.2022.2022-7-5

Introduction

Pigmented lesions of the upper aerodigestive tract often require tissue biopsy to determine if they represent the

highly malignant mucosal melanoma. Malignant mucosal melanomas of the head and neck are rare and represent only 1%, of all melanomas; and among these, the most common locations include the

nasal cavity, the paranasal sinuses, and the oral cavity (1). The prognosis for mucosal melanoma of the head and neck is poor, with only a 5-year survival rate of 25–30%, and it is commonly associated with local recurrence as well as distant metastasis (2). A contributing factor to this poor prognosis is the concealed locations in which these tumors arise, which make them less likely to be discovered during routine screenings. Because of this characteristic, these lesions are usually not found until late in the disease course (3). Oral mucosal melanoma in situ (OMMIS) has rarely been reported, and its actual prevalence is therefore unknown.

Mucosal melanoma of the oral cavity has unique characteristics that differentiate it from cutaneous melanoma, but pigmented changes of the oral cavity mucosa is the usual presenting finding. While melanoma in situ is considered a precursor to cutaneous melanoma, mucosal melanomas are not proven to have precursor non-invasive lesions. Oral mucosal melanoma generally is diagnosed at a later age than cutaneous melanoma with most cases occurring between ages 50 and 80, with a median age of 70 years (4). Due to the lack of exposure of the oral cavity and other mucosal regions to light, it is unlikely that UV light plays a role in the development of these lesions. Additionally, these cancers show unique genetic profiles, with BRAF mutations occurring far less frequently in mucosal melanomas relative to cutaneous melanomas. Furthermore, mucosal melanomas show an increased incidence in KIT mutations, occurring in an estimated 39% of these cancers (4). A slightly increased risk in the Japanese population suggests a possible correlation with either hereditary or environmental factors. However, the etiology and pathogenesis of mucosal melanoma still remain largely unknown (4).

Oral mucosal melanomas arise from the malignant transformation of melanocytes. This can occur in the cells found either in the basal layer of the oral epithelium or less commonly in the lamina propria of the oral mucosa. Among mucosal melanomas of the oral cavity, an exceedingly small percentage are identified as mucosal melanoma in situ. These lesions are identified histologically by a radial proliferation of malignant melanocytes along the basal cell layer, which lack invasion through the basement membrane into the lamina propria (5).

Herein, we report a rare case of OMMIS that was evaluated and diagnosed by the patient’s dentist and biopsied by her oral and maxillofacial surgeon. The pathology was reviewed and confirmed by an oral pathologist. Furthermore, we conducted a systematic literature review of the documented cases of oral melanoma in situ to further characterize this rare disease and compile diagnosis, treatment, and outcome details to aid in future early diagnosis and management of these lesions.

Case Report

A 45-year-old female was referred for evaluation of a pigmented lesion in the left floor of mouth and the lateral border of the tongue, which was discovered during a routine dental examination (Figure 1). The lesion appeared to grow quickly over the course of two months. The patient reported no history of smoking or other tobacco use and no prior cutaneous or other malignancies or premalignancies. She endorsed current alcohol use of two standard drinks per week. Past medical history and surgical history were noncontributory. Family history was significant for cutaneous melanoma in her maternal aunt. A computed tomography of the oral cavity, neck and chest was performed, showing no signs of other neoplastic signs or disease spread. The patient denied any noticeable symptoms, pain, bleeding, dysgeusia, dysarthria, dysphagia, or lymphadenopathy.

A biopsy was performed, showing an increased number of melanocytes irregularly distributed along the basal epithelial layer (Figure 2). These melanocytes exhibited a nested arrangement. Cells demonstrating nuclear atypia were also observed. Histopathologic examination determined to be consistent with mucosal melanoma in situ.

The patient was evaluated at the multidisciplinary head and neck clinic and the tumor board recommended surgical resection not only to remove the lesion but also to confirm that there were no evidence of invasive malignant melanoma that might require new staging. The initial plan was for complete resection, consisting of a 5-mm margin clearance of visible tumor and to delay reconstruction until definitive pathologic interpretation was completed. Further resection and/or reconstruction would be completed upon confirmation of final pathology clearance. Thus, left partial glossectomy, gingivectomy and floor of mouth resection was performed and the tumor oriented and mapped for the oral and head and neck pathology team. Upon resection, the lesion was found to involve the left floor of the mouth, the

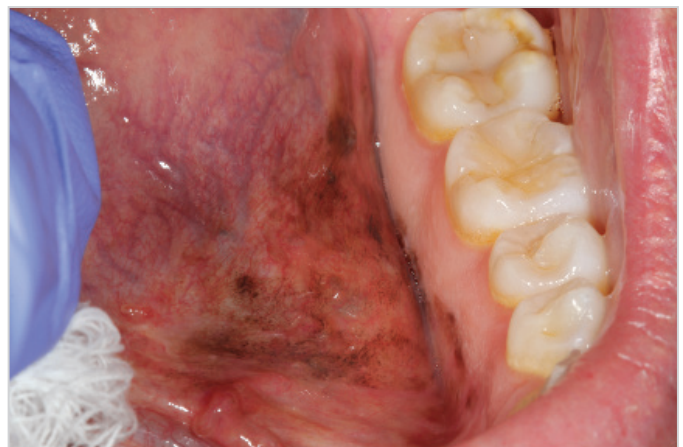

Figure 1. Clinical presentation of lesion on left side of the floor of the mouth prior to surgical resection

Wharton's duct, the ventrolateral tongue, and the lingual mandibular gingiva. A xeroform iodoform petrolatum gauze was placed as a temporary bolster to prevent scarring and tethering and to allow for orientation and resection if any of the margins were close or involved. The final pathology returned as melanoma in situ measuring 2.2x2x1.4 cm with the closest margin near the gingival edge anteriorly and at the retromolar region.

Thus, reconstruction was planned with a resection of the retromolar gingiva and the anterior gingival margin, which was determined to be free of pigmented lesion, followed by the reconstruction of the oral cavity, the floor of mouth, and the tongue with local mucosal advancement flaps, allograft, Wharton's duct sialodochoplasty, and bolster placement.

The patient is currently twelve months status post-resection, with no signs of disease (Figure 3). Speech, healing, and swallowing have returned to baseline and examination

showed scarring but no return of pigmented lesions. The current plan is to continue follow-up with oral cancer examination and surveillance for five years to rule out signs of disease recurrence.

Methods

Search Criteria

A systematic review was performed following the Preferred Reporting Items for Systematic Reviews and Meta-Analyses (PRISMA) guidelines (6). The following databases were searched: PubMed (National Library of Medicine, National Institutes of Health), Scopus (Elsevier), and CINAHL (EBSCOHost). These databases were searched from inception through January 26, 2022. Search terms were developed by two trained researchers (W.N.J. and N.S.P.) to include themes related to oral mucosal melanoma pertaining to the head and neck region. Furthermore, the databases were manually searched to include any manuscripts which were not captured by the initial search. Full strategy details are included in Appendix 1.

Selection Criteria

All report types were considered for inclusion. Studies were only included if 1) described oral cavity melanoma in situ, and 2) documented specific data pertaining to treatment modality, outcomes, lesion site, etc. Exclusion criteria were studies which did not stratify data on oral mucosal melanoma from other cancers, did not provide any follow-up or outcomes data, or studies reporting oral invasive melanoma with no reporting or cases of melanoma in situ. Exclusion criteria also included non-English studies and studies with no reported DOI.

Data Extraction

All reports from the initial search strategy were imported into the Covidence software (Veritas Health Innovation, Melbourne, Australia). Title and abstract screening and subsequent full text review was conducted independently by two of the authors (W.N.J. and N.S.P.). The data was then extracted and organized into a standardized Excel spreadsheet. Author, patient age and sex, lesion site and size, modality of treatment, and follow-up/outcomes were recorded as available.

Level of Evidence and Quality Assessment

The levels of evidence for the included reports were evaluated according to the Oxford Center for Evidence-Based Medicine (7). The Joanna Briggs Institute (JBI) critical appraisal checklist was used to assess the quality of Case Reports (8 questions) and Case Series (10 questions) (8). Two authors (W.N.J. and N.S.P) reviewed all included studies independently and rated each checklist item as "yes," "no,"

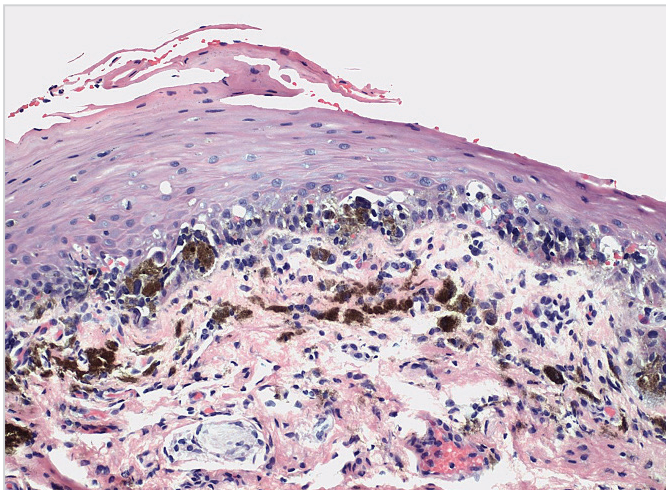


Figure 2. Medium-power photomicrograph showing an irregular proliferation of atypical pigmented melanocytes along the basilar layer of the mucosal epithelium (Note: The melanin observed in the superficial lamina propria represents pigment incontinence, not tumor invasion)

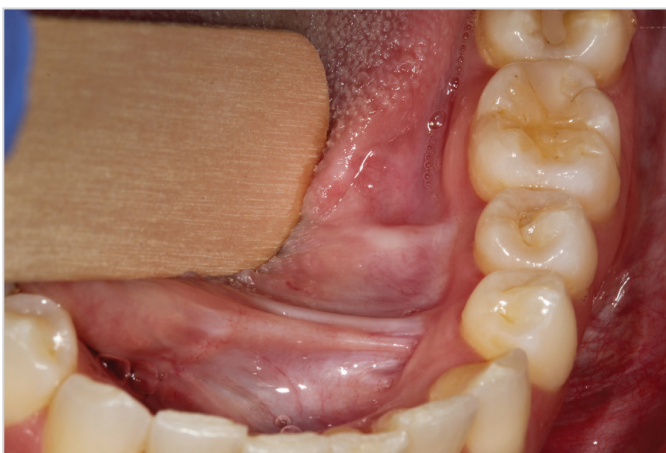

Figure 3. Surgical site 12 months status post resection showing no evidence of disease

“unclear,” or “not applicable.” In case of any disagreements, a third reviewer assisted with the appraisal by discussion of the study quality to reach a consensus. The JBI scores assigned to each reviewed report ranged from 0, if none of the criteria were met, to 8 for Case Reports and 10 for Case Series, if all criteria were met. Then the sum of individual questions represented the overall quality of a study. The risk for bias was then assigned based on number of items scored “yes.” Studies were then rated as low risk or of good quality when they scored 4 or above and were therefore included in the analysis (8).

Statistical Analysis

Summary statistics were calculated with frequency and percentage for categorical variable (gender) and mean for continuous variable (age).

Results

In total, 19 manuscripts met full inclusion criteria, presenting data on 28 patients diagnosed with melanoma in situ of the oral cavity. Figure 4 details the entire search process. The details, including patient information, description of the lesion, treatment, and outcome regarding these cases can be found in Table 1. These lesions were most common in males representing 18 (64.29%) of the cases. While the entire group age ranged from 16 to 78 years, the average age at

presentation was found as 57.35 years. The majority of these cases presented as asymptomatic pigmented lesions, and many were discovered during routine dental examination. Per the Oxford Level of Evidence stratification, all studies were deemed to be Level 4. All 19 reports in Tables 2 and 3 were found to have a low risk of publication bias.

The most common location for the lesions was the palate, which was found in 13 of the reported cases (46.42%). The gingiva was also found to be commonly affected, with involvement in five of the reported cases (17.86%). Our patient presented with a lesion centered in the floor of the mouth, a case which has not been reported to date. Of the cases reviewed, eight were found to have no evidence of disease after a minimum of six months of follow-up. However, local recurrence was found in eight cases in the series, with one of these reporting spread to the cervical lymph nodes and one reporting distant metastasis. The location of metastasis was not noted. In contrast to the poor prognosis of mucosal melanoma of the oral cavity overall, these data suggest a more promising prognosis for lesions discovered in situ but if the histopathologic examination was reported accurately in all of these cases, a low but important rate of metastasis is possible.

The majority of these lesions were treated with surgical excision, with only three of them receiving adjuvant therapy. Radiotherapy was used in one case for a 2x1.5 cm lesion that had recurred twice following surgical resection with 0.5 mm margins. Following this treatment, no further recurrence was noted after two years of surveillance. Chemotherapy was noted to have been used in two cases. The first case was administered cisplatin and thiosulfate prior to the original surgical resection, and interferon alpha 2b following surgery. The lesion recurred locally twice and following failure to achieve negative margins in the final resection, topical imiquimod was administered for six months and no further recurrence was noted. In the second case, a chemotherapy regimen of cisplatin, vinblastine, and dacarbazine was used following the discovery of spread to the cervical lymph nodes after the original surgical resection. Follow-up for this case was not reported. In the cases in which recurrence was found, the time between initial treatment and recurrence varied widely from 1 month to 84 months.

Discussion

Oral pigmented lesions that are unrelated to hereditary or amalgam related etiologies should undergo biopsy. A biopsy showing OMMIS should prompt a multidisciplinary evaluation and oral pathology review to confirm the absence of invasion. Surgical resection is indicated for treatment and to confirm adjacent sites are not invasive mucosal melanoma. Oral mucosal melanoma and OMMIS most

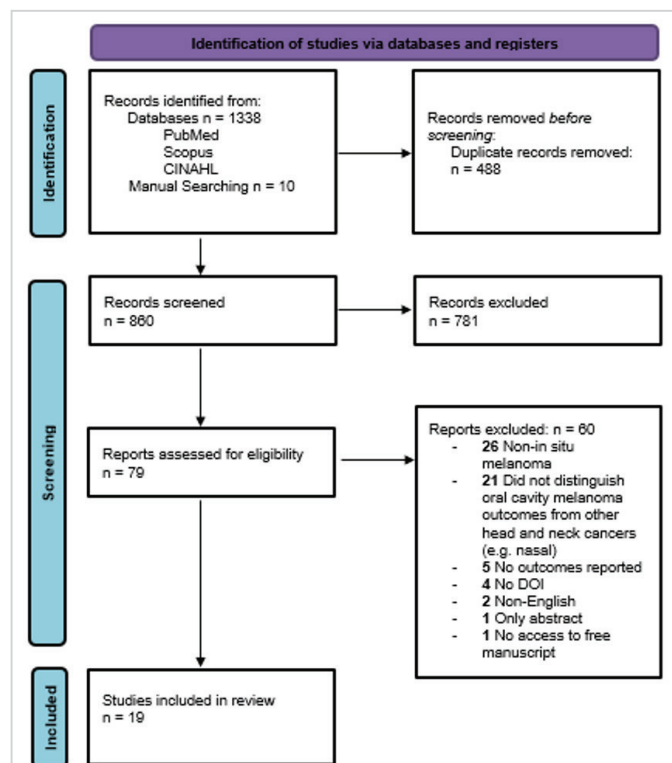


Figure 4. PRISMA diagram detailing database search procedure

PRISMA: Preferred Reporting Items for Systematic Reviews and Meta-Analyses

Table 1. Clinical features, patient characteristics, treatments, outcomes, and follow-up information for previously reported cases of oral mucosal melanoma in situ, as well as the presented case

Authors	OLE	Age, years	Sex	Site	Lesion size	Surgical treatment	Margins	Adjuvant therapy?	Outcome	Time to first recurrence, months	Follow-up, months
Becker et al. (15)	4	46	M	Hard palate	2 cm x 1.5 cm	Surgical excision (extraction of teeth 12, 11, 21)	0.5 mm	Radiotherapy (following 2 nd recurrence)	Multiple recurrences	3	24
Breik et al. (16)	4	57	M	Right buccal mucosa	16 mm	Right BM-WLE, SND, and flap reconstruction	>10 mm		No evidence of disease		6
		70	M	Right side of hard palate	14 mm	Right subtotal maxillectomy, ITF clearance, right SND, ALT free flap reconstruction	>10 mm		No evidence of disease		12
Carbone et al. (17)	4	77	M	Gingiva	NA	Hemimaxillectomy	5 mm		No evidence of disease		71
Cardoso et al. (18)	4	67	M	Maxillary alveolar mucosa	3 cm x 1.5 cm	Partial maxillectomy	NA		No evidence of disease		10
Hajar-Serviansky et al. (19)	4	40	M	Lower right half of lip	1.5 cm x 4 cm	Surgical excision and reconstruction	NA		NA		NA
Horiuchi et al. (20)	4	66	F	Internal cheek, vermillion border, perioral skin	NA	NA	NA		NA		NA
Kemp et al. (21)	4	74	M	Maxillary ridge, palate, and buccal mucosa	NA	Surgical excision; recurrence treated w/ additional surgical excision	NA		Local recurrence	25	38
Kuk et al. (22) (6 cases)	4	<58 (4), >58 (2)	M (3), F (3)	Maxilla (5), Lip (1)	NA	Surgical excision	>5 mm (4), <5 mm (2)		NA		NA
Lourenço et al. (23)	4	75	M	Hard palate	NA	None	NA		NA		NA
Luna-Ortiz et al. (24)	4	47	F	Gingiva, palate	NA	Resection of the lesion; extraction from 11 to 16	2 mm		No evidence of disease		24
		58	M	Hard/soft palate, gingiva	NA	Wide excision of the palate and gingival lesion	1.5 mm		No evidence of disease		8
Magliocca et al. (25)	4	48	M	Mid-anterior hard palate	3 cm x 2 cm	Wide local excision; additional surgery to pre-maxilla (extractions of teeth #6-13)	0.5 cm		No evidence of disease		42
Park et al. (14)	4	72	M	Upper lip, inner labial mucosa	5.3 cm x 4.7 cm	Surgical excision	5 mm	chemotherapy (cisplatin, vinblastine, dacarbazine) for recurrence	Recurrence; locoregional recurrence (cervical lymph nodes)	1	2
Prasad et al. (12)	4	NA	NA	NA	NA	Definitive surgery	NA		Recurrence; distant metastases		NA

Tremblay et al. (26)	4	16	M	Left posterolateral hard palate	4 mm	Full excisional biopsy	NA	NA	NA	NA	
Sedassari et al. (27)	4	51	F	Mandibular gingiva	NA	Surgical excision	NA	No evidence of disease		12	
Shastri et al. (28)	4	49	M	Hard palate	3 cm x 2.5 cm	Local mucosal surgical excision; recurrences treated w/ additional 10 incision and excisional biopsies over following 10 years	NA	Multiple recurrences		48	
		78	M	Hard palate	7 mm	Local mucosal surgical excision; recurrence treated w/ additional wide local excision down to the bone	NA	Local recurrence	1	54	
		57	F	Hard palate	3 cm x 2 cm	Local mucosal surgical excision	NA	Local recurrence	84	288	
Smith et al. (10)	4	32	F	Palate/gingiva	NA	NA	NA	NA		NA	
Spieth et al. (13)	4	67	M	Left side of hard palate	NA	Partial maxillectomy; two recurrences treated with second partial maxillectomy, multiple gingivectomies & mucosectomies	NA	chemotherapy (cisplatin, thiosulfate, interferon alpha 2b; recurrence treated w/ topical 5% imiquimod cream	Local recurrence post original surgery/chemo; no evidence of disease post-surgery/imiquimod	5	13
Wu et al. (29) (5 cases)	4	NA	NA	NA	NA	NA	NA	NA		60	
Presented case		45	F	Left floor of mouth	2.2x2x1.4 cm	Partial glossectomy/FOM resection		No evidence of disease		12 (ongoing)	
Total cases:		29									

OLE: Oxford Level of Evidence, cm: Centimeter/s, mm: Millimeter/s, F: Female, M: Male, NA: Not available

commonly presents asymptotically as an irregularly shaped, pigmented, single or multifocal lesion (9). This lesion can appear plaque-like, nodular, or macular. Other possible symptoms include pain, bleeding, ulceration, and difficulty wearing dentures due to the tumor (9). Because early lesions are not normally noticed by patients, they tend to present later in the disease course. Because the appearance of mucosal melanoma can mimic that of benign pigmented or inflammatory lesions, as well as other malignant lesions, it is imperative that a biopsy be performed to rule out melanoma for any suspicious lesion of the oral cavity (10).

The Breslow criteria that are used to assess cutaneous melanoma are less useful in assessing mucosal melanoma due to the lack of a granular layer in many mucosal sites (9). Staging of primary mucosal melanomas of the head and neck primarily utilizes a simplified staging system for primary mucosal melanomas of the head and neck that was

developed by Ballantyne in 1970. This system designates three stages: stage I for localized lesions, stage II for spread to regional lymph nodes, and stage III for distant metastasis (11). A more specific microstaging system is also available for further describing stage I disease, developed by Prasad et al. (12) in 2004. This system designates three levels: level I for noninvasive, in situ lesions, level II for superficially invasive disease, and level III for deep invasion into muscle, bone, or cartilage (12). The 7th edition of the American Joint Committee on Cancer Staging Manual included an additional chapter regarding the staging of mucosal melanomas, identifying all mucosal melanomas limited to the mucosa as T3 due to their aggressive nature but does not report on OMMIS. Advanced mucosal melanomas are identified as either T4a or T4b. However, due to the limited number of cases of mucosal melanoma in situ, staging of these lesions was not addressed (11).

In general, because of the potential for rapid progression of these lesions, mucosal melanoma in situ is treated similar to invasive melanoma, with surgical excision (9). For most of the reported cases, treatment consisted of surgical excision, which usually resulted in full remission with no recurrence. In one case, however, surgical excision was supplemented with chemotherapy including cisplatin, thiosulfate, and interferon alpha-2b, but a local gingival recurrence was identified five months post-surgery. Surgical excision was performed again, this time supplemented with topical imiquimod, and

resulted in full remission with no recurrence (13). Similarly, in another case, after recurrence and cervical lymph node enlargement was noted, surgical excision was supplemented with a multi-chemotherapy agent, consisting of cisplatin, vinblastine, and dacarbazine, and, at 2-month follow-up, no signs of disease were noted (14). More data are needed to determine if adjuvant radiation therapy or chemotherapy offers any additional protection from recurrence. Finally, the emerging role of immunotherapy in many cancers and cutaneous melanoma may warrant evaluation in mucosal melanoma and melanoma in situ.

Table 2. JBI critical appraisal checklist for case reports

Study	1	2	3	4	5	6	7	8	Total scores
Becker et al. (15)	Y	Y	Y	Y	Y	Y	Y	Y	8
Breik et al. (16)	U	Y	N	Y	Y	Y	Y	Y	6
Carbone et al. (17)	Y	Y	Y	Y	Y	Y	U	Y	7
Cardoso et al. (18)	Y	Y	Y	Y	Y	Y	Y	Y	8
Hajar-Serviansky et al. (19)	Y	Y	Y	Y	Y	U	U	Y	6
Horiuchi et al. (20)	Y	Y	Y	Y	N	N	N	N	4
Kemp et al. (21)	Y	Y	Y	Y	Y	Y	Y	Y	8
Lourenco et al. (23)	Y	N	Y	Y	Y	N	N	N	4
Luna-Ortiz et al. (24)	Y	Y	Y	Y	Y	Y	Y	Y	8
Magliocca et al. (25)	Y	Y	Y	Y	Y	Y	Y	Y	8
Park et al. (14)	Y	Y	Y	Y	Y	Y	N	Y	7
Prasad et al. (12)	Y	Y	Y	Y	U	U	N	N	4
Tremblay et al. (26)	Y	Y	Y	Y	Y	N	N	Y	6
Sedassari et al. (27)	Y	Y	U	Y	Y	U	Y	Y	6
Shastri et al. (28)	Y	Y	Y	Y	Y	Y	Y	N	7
Smith et al. (10)	Y	Y	Y	Y	N	N	N	N	4
Spieth et al. (13)	Y	Y	Y	Y	Y	Y	Y	Y	8

Y: Yes, N: No, U: Unclear, JBI: Joanna Briggs Institute, 1. Were patient's demographic characteristics clearly described? 2. Was the patient's history clearly described and presented as a timeline? 3. Was the current clinical condition of the patient on presentation clearly described? 4. Were diagnostic tests or assessment methods and the results clearly described? 5. Was the intervention(s) or treatment procedure(s) clearly described? 6. Was the post-intervention clinical condition clearly described? 7. Were adverse events (harms) or unanticipated events identified and described? 8. Does the case report provide takeaway lessons?

Table 3. JBI critical appraisal checklist for case series

Study	1	2	3	4	5	6	7	8	9	10	Total scores
Kuk et al. (22)	Y	Y	Y	Y	Y	Y	Y	Y	Y	Y	10
Wu et al. (29)	Y	Y	Y	Y	Y	N	Y	Y	N	Y	8

Y: Yes, N: No, 1. Were there clear criteria for inclusion in the case series? 2. Was the condition measured in a standard, reliable way for all participants included in the case series? 3. Were valid methods used for identification of the condition for all participants included in the case series? 4. Did the case series have consecutive inclusion of participants? 5. Did the case series have complete inclusion of participants? 6. Was there clear reporting of demographics of the participants in the study? 7. Was there clear reporting of clinical information of the participants? 8. Were the outcomes or follow-up results of cases clearly reported? 9. Was there clear reporting of the presenting site(s)/clinic(s) demographic information? 10. Was statistical analysis appropriate?

Limitations of this study included the retrospective nature of the analysis and lack of independent oral pathologic review to confirm the in situ nature of these pigmented diagnoses. Additionally, true surgical margin analysis and adjuvant decision making were not reported. For the presented case, surgical excision alone has been effective thus far, with no signs of recurrence at twelve months of follow-up. Given the high rate of recurrence for mucosal melanoma and limited data on OMMIS, long-term follow-up is important.

Conclusion

In this study, we reviewed 28 previously reported cases of OMMIS, as well as one case from our own institution which is the first known case of mucosal melanoma in situ of the floor of mouth. The majority of the reported malignancies were diagnosed during a routine dental visit based on visible pigmented changes and treated effectively with complete surgical resection alone. However, long term follow-up is essential given the potential risk of recurrence demonstrated in the cases presented in this review. The role of adjuvant therapy cannot be determined based on this limited data, but further studies may be useful to investigate the indications for and the role in lowering the risk of recurrence.

Peer-review: Externally and internally peer-reviewed.

Authorship Contributions

Surgical and Medical Practices: P.J., W.N.J., N.S.P., S.A.N., J.H., B.W.N., T.A.D., Concept: P.J., W.N.J., N.S.P., S.A.N., J.H., B.W.N., T.A.D., Design: P.J., W.N.J., N.S.P., S.A.N., T.A.D., Data Collection and/or Processing: P.J., W.N.J., N.S.P., Analysis and/or Interpretation: P.J., W.N.J., N.S.P., S.A.N., J.H., B.W.N., T.A.D., Literature Search: P.J., W.N.J., N.S.P., Writing: P.J., W.N.J., N.S.P., S.A.N., J.H., B.W.N., T.A.D.

Conflict of Interest: The authors have no conflicts of interest to declare.

Financial Disclosure: The authors declared that this study has received no financial support.

Main Points

- Men comprised the majority (64.3%) of the cases, and the average age at presentation was 57.4 years.
- Hard palate was the most common location.
- Out of 28 cases reported in the literature, eight reported no evidence of disease after a minimum of six-month follow-up, one reported spread to the cervical lymph nodes, and only one reported progression with distant metastasis.
- The role of adjuvant therapy needs to be further researched to define its role in reducing recurrence.

References

1. Ascierto PA, Accorona R, Botti G, Farina D, Fossati P, Gatta G, et al. Mucosal melanoma of the head and neck. *Crit Rev Oncol Hematol* 2017; 112: 136-52. [Crossref]
2. Lazarev S, Gupta V, Hu K, Harrison LB, Bakst R. Mucosal melanoma of the head and neck: a systematic review of the literature. *Int J Radiat Oncol Biol Phys* 2014; 90: 1108-18. [Crossref]
3. Postow MA, Hamid O, Carvajal RD. Mucosal melanoma: pathogenesis, clinical behavior, and management. *Curr Oncol Rep* 2012; 14: 441-8. [Crossref]
4. Spencer KR, Mehnert JM. Mucosal melanoma: epidemiology, biology and treatment. *Cancer Treat Res* 2016; 167: 295-320. [Crossref]
5. Feller L, Khammissa RAG, Lemmer J. A review of the aetiopathogenesis and clinical and histopathological features of oral mucosal melanoma. *ScientificWorldJournal* 2017; 2017: 9189812. [Crossref]
6. Page MJ, McKenzie JE, Bossuyt PM, Boutron I, Hoffmann TC, Mulrow CD, et al. The PRISMA 2020 statement: an updated guideline for reporting systematic reviews. *BMJ* 2021; 372: n71. [Crossref]
7. Howick J, Chalmers I, Glasziou P, Greenhalgh T, Heneghan C, Liberati A, et al. The 2011 Oxford CEBM Levels of Evidence (Introductory Document). Oxford Centre for Evidence-Based Medicine. 2011. Available from: URL: <https://www.cebm.ox.ac.uk/resources/levels-of-evidence/ocebmllevels-of-evidence> [Crossref]
8. Moola S, Munn Z, Tufanaru C, Aromataris E, Sears K, Sfetcu R, et al. Chapter 7: Systematic reviews of etiology and risk. Aromataris E, Munn Z, editors. *JBIManual for Evidence Synthesis*. JBI; 2017. [Crossref]
9. Maymone MBC, Greer RO, Kesecker J, Sahitya PC, Burdine LK, Cheng AD, et al. Premalignant and malignant oral mucosal lesions: clinical and pathological findings. *J Am Acad Dermatol* 2019; 81: 59-71. [Crossref]
10. Smith MH, Bhattacharyya I, Cohen DM, Islam NM, Fitzpatrick SG, Montague LJ, et al. Melanoma of the oral cavity: an analysis of 46 new cases with emphasis on clinical and histopathologic characteristics. *Head Neck Pathol* 2016; 10: 298-305. [Crossref]
11. Luna-Ortiz K, Aguilar-Romero M, Villavicencio-Valencia V, Zepeda-Castilla E, Vidrio-Morgado H, Peteuil N, et al. Comparative study between two different staging systems (AJCC TNM VS BALLANTYNE'S) for mucosal melanomas of the Head & Neck. *Med Oral Patol Oral Cir Bucal* 2016; 21: e425-30. [Crossref]
12. Prasad ML, Patel SG, Huvos AG, Shah JP, Busam KJ. Primary mucosal melanoma of the head and neck: a proposal for microstaging localized, Stage I (lymph node-negative) tumors. *Cancer* 2004; 100: 1657-64. [Crossref]
13. Spieth K, Kovács A, Wolter M, Bug R, Kaufmann R, Gille J. Topical imiquimod: effectiveness in intraepithelial melanoma of oral mucosa. *Lancet Oncol* 2006; 7: 1036-7. [Crossref]
14. Park HS, Saida T, Park SY, Cho KH, Lee JH, Cho S. Case of mucosal lentiginous melanoma in situ on the upper lip with a long radial growth phase. *J Dermatol* 2012; 39: 651-3. [Crossref]
15. Becker P, Pabst A, Bjelopavlovic M, Müller D, Kämmerer PW. Treatment modalities of recurrent oral mucosal melanoma in situ. *Medicina (Kaunas)*. 2021; 57: 965. [Crossref]
16. Breik O, Sim F, Wong T, Nastri A, Iseli TA, Wiesenfeld D. Survival outcomes of mucosal melanoma in the head and neck: case series and review of current treatment guidelines. *J Oral Maxillofac Surg* 2016; 74: 1859-71. [Crossref]
17. Carbone M, Cabras M, Conrotto D, Arduino PG, Garzino Demo P, Carrozzo M. Positive clinical outcome of an oral in situ melanoma: 6 years of follow-up. *Clin Exp Dermatol* 2018; 43: 603-5. [Crossref]
18. Cardoso DM, Bastos DB, Dos Santos DM, Conrado-Neto S, Collado FU, Crivelini MM, et al. In situ melanoma of oral cavity: diagnosis and treatment of a rare entity. *Oral Oncol* 2021; 115: 105116. [Crossref]
19. Hajar-Serviansky T, Gutierrez-Mendoza D, Galvan IL, Lammoglia-Ordiales L, Mosqueda-Taylor A, Hernandez-Cázares Mde L, et al. A case of oral mucosal melanoma. Clinical and dermoscopic correlation. *J Dermatol Case Rep* 2012; 6: 1-4. [Crossref]
20. Horiuchi N, Tsunoda T, Suetake T, Kato T. Oral mucosa malignant melanoma in situ with involvement of the perioral skin. *Dermatology* 1994; 188: 66-8. [Crossref]
21. Kemp S, Gallagher G, Kabani S, Moskal R. Persistent melanoma in situ: case report and review. *J Oral Maxillofac Surg* 2008; 66: 1945-8. [Crossref]
22. Kuk SK, Won CH, Lee WJ, Shin WJ, Yoon HJ, Hong SD, et al. Prognostic significance of nestin in primary malignant melanoma of the oral cavity. *Melanoma Res* 2016; 26: 457-63. [Crossref]

23. Lourenço SV, A MS, Sotto MN, Bologna SB, Giacomo TB, Buim ME, et al. Primary oral mucosal melanoma: a series of 35 new cases from South America. *Am J Dermatopathol* 2009; 31: 323-30. [Crossref]
24. Luna-Ortiz K, Campos-Ramos E, Pasche P, Mosqueda-Taylor A. Oral mucosal melanoma: conservative treatment including laser surgery. *Med Oral Patol Oral Cir Bucal* 2011; 16: e381-5. [Crossref]
25. Magliocca KR, Rand MK, Su LD, Helman JI. Melanoma-in-situ of the oral cavity. *Oral Oncol Extra* 2006; 42: 46-8. [Crossref]
26. Tremblay JF, O'Brien EA, Chauvin PJ. Melanoma in situ of the oral mucosa in an adolescent with dysplastic nevus syndrome. *J Am Acad Dermatol* 2000; 42: 844-6. [Crossref]
27. Sedassari BT, Lascane NA, de Freitas AL, Mautoni MC, Sotto MN, Gallottini MH, et al. In situ melanoma of the gingiva associated with dense inflammation and pigment deposition: a potential diagnostic pitfall in evaluating stromal invasion. *Head Neck Pathol* 2016; 10: 547-51. [Crossref]
28. Shastri M, Paterson T, Bisase BS, Barrett AW. Malignant melanoma in situ of the palate: Radical treatment or "watch and wait"? *Oral Oncol* 2020; 110: 104805. [Crossref]
29. Wu Y, Wang L, Ma X, Guo W, Ren G. The existence of early stage oral mucosal melanoma: a 10-year retrospective analysis of 170 patients in a single institute. *Oral Oncol* 2018; 87: 70-6. [Crossref]

Appendix 1. Search Strategy

PUBMED: "Mucosal melanoma" AND ("in situ" OR Oral OR "Oral Cavity" OR "Tongue" OR "oropharynx" OR "pharynx" OR Tonsil OR Pillar OR "Buccal Mucosa" OR "Head and neck" OR "Head & neck")

Search date: 1.26.2022

Results: 551

SCOPUS: TITLE-ABS-KEY ("Mucosal melanoma" AND ("in situ" OR oral OR "Oral Cavity" OR "Tongue" OR "oropharynx" OR "pharynx" OR tonsil OR pillar OR "Buccal Mucosa" OR "Head and neck" OR "Head & neck")) AND (LIMIT-TO (LANGUAGE, "English")) AND (LIMIT-TO (SRCTYPE, "j"))

Search date: 1.26.2022

Results: 600

CINAHL: "Mucosal melanoma" AND ("in situ" OR Oral OR "Oral Cavity" OR "Tongue" OR "oropharynx" OR "pharynx" OR Tonsil OR Pillar OR "Buccal Mucosa" OR "Head and neck" OR "Head & neck")

Search date: 1.26.2022

Results: 106
