



From Diagnosis to Treatment of Human Otoacariasis: Demographic and Clinical Characteristics of Patients

Original Investigation

Orhan Asya¹, Semih Karaketir¹, Şeyma Görçin Karaketir², Ali Bilgin Yılmaz³

¹Clinic of Otolaryngology, Malazgirt State Hospital, Muş, Turkey

²Public Health Specialist, Malazgirt District Health Directorate, Muş, Turkey

³Van University Faculty of Health Sciences, Van, Turkey

Abstract

Objective: Otoacariasis is the presence of ticks and mites in the ear canals of humans or animals, and particularly common in rural areas. This study aimed to present the clinical characteristics of patients that presented with ticks in their ear canal.

Methods: The study was conducted with a total of 425 patients with 527 ticks in their ear canal at the Muş Malazgirt State Hospital Ear-Nose-Throat Clinic between June 2019 and June 2020. The removed ticks were examined at the parasitology laboratory of Van Yüzüncü Yıl University.

Results: Of the 425 cases included in the study, 72% (n=306) were female and 28% (n=119) were male (mean age 40±20, minimum-maximum: 4 months–81 years). A total of 527 ticks were removed in the one-year period. Three-hundred-and-fifty-one patients had adult or nymph ticks, and 74 patients had a larval form of the tick. Of the patients with adult or nymph tick, foreign body sensation was the dominant symptom in 68.7% (n=242), whereas pain was the dominant symptom in 62% (n=46) of those with larval tick. In the comparison between groups, foreign body sensation was statistically significantly higher in the adult tick group, and pain was higher in the larval tick group (p<0.001). There were no systemic diseases related to the ticks in any of the cases.

Conclusion: Ticks in the ear is endemic in Eastern Anatolia and poses a public health problem. Tick infestations could be minimized with various precautions and educating the general public on preventive methods. Our study is the largest series in the literature on cases with ear ticks.

Keywords: Ticks, external auditory canal, foreign bodies, otobius megnini, patient education, public health

ORCID ID of the authors:

O.A. 0000-0003-0366-3099;
S.K. 0000-0002-6645-7105;
Ş.G.K. 0000-0002-8540-4148;
A.B.Y. 0000-0003-0749-2418.

Cite this article as: Asya O, Karaketir S, Görçin Karaketir Ş, Yılmaz AB. From Diagnosis to Treatment of Human Otoacariasis: Demographic and Clinical Characteristics of Patients. Turk Arch Otorhinolaryngol 2022; 60(3): 134-41.

Corresponding Author:

Orhan Asya;
orhan4913@gmail.com

Received Date: 29.06.2022

Accepted Date: 12.09.2022

Content of this journal is licensed under a Creative Commons Attribution 4.0 International License. Available online at www.turkarchotolaryngol.net



DOI: 10.4274/tao.2022.2022-6-14

Introduction

Ticks are major ectoparasites of animals and humans. They are mandatory blood-sucking arthropods and are found across the world, especially in tropical and subtropical regions. There are more

than 900 tick species worldwide. Ticks can transmit a variety of pathogenic microorganisms, including protozoa, rickettsiae, spirochetes, and viruses, and also cause irritation, toxic reactions, and allergies (1).

Otoacariasis involves the presence of ticks and mites in the ear canal of humans or animals, and is highly common in rural areas (2). Ixodid ticks (hard ticks) comprise 80% of all ticks, with the remainder being argasid ticks (soft ticks). *Otobius ticks* belong to the argasid tick family and can be parasitic in both animals and humans (3). Soft ticks (*Argasidae*) live near hosts, and in the parasitic stage, they only feed on the host for a short time and then leave.

Larvae and nymphs of the soft tick *Otobius megnini* (*O. megnini*) parasitize the external ear canal of many animals and occasionally humans (4). From its center of origin in Southwestern North America, *O. megnini* has spread to a vast geographic region, including Turkey (5). A typical soft tick life cycle involves four developmental stages: egg, larva, nymph, and adult (male/female). The duration of the life cycle can extend from several weeks to many years, depending on host availability (6). *O. megnini* has adapted to complete its life cycle on a single host, upon which the larvae and nymphs feed for several days to months (7). Fully engorged nymphs detach after a long parasitic phase and molt on the ground to become non-feeding adults, which are nonparasitic. *O. megnini* has a long parasitic period and short nonparasitic period. It has a single gonotrophic cycle; hence, females die soon after oviposition (4). *O. megnini* displays seasonal dynamics, with a high larval activity during warmer and dryer months (8).

In this study, we present the clinical characteristics of patients with ticks in their ear canals. And we aimed to show the possible difficulties and the coping methods that may be used in otoacariasis.

Methods

The patients diagnosed with a tick in the external auditory canal in the Otolaryngology Department or Emergency Department of Muş Malazgirt State Hospital between June 2019 and June 2020 were included in the study. The ticks in the external auditory canal of all patients included in the study were removed by two otolaryngology physicians with the same intervention. Adult or nymph ticks were removed by holding their legs or abdomen with alligator forceps. In cases where the leg of the tick is seen more prominently, it is easier to remove by holding its leg; but it isn't easier to remove the tick when the leg of the tick is relatively hidden, or the abdomen is more prominent. Sometimes ticks are so engorged with blood that they fully block the external ear canal. In such case, the only way to remove the tick is by pulling the abdomen with alligator forceps. In the larval form of ticks, legs have not yet formed, and in fact, there is no complete tick appearance, and the larval forms appear as pink or red colored, round millimetric soft tissues attached to the external ear canal. Larval forms can be removed by alligator forceps or with a curette. If the larval form is hidden behind

the only protrusion in the external ear canal, it is not possible to remove it with straight alligator forceps, in this case it can be removed more easily with a curette. Patients who did not come for follow-up after tick removal and patients whose interventions were performed by emergency physicians were not included in the study. The study was approved by the Muş Provincial Health Directorate and Muş Malazgirt State Hospital Chief Physician on 18.02.2021, and the protocol number is 35465298-799. Informed consent was not received because of retrospective design of the study.

Agriculture and livestock are the main livelihoods in our district. The land area of the district is 1527 km²; population 51,323; elevation 1530 m; mean annual rainfall 468 mm; mean annual temperature 7.1 °C; and mean relative humidity 59%.

The patients' age, gender, complaints, complaint duration, physical examination findings, need for local therapy after tick removal, side of the ear from which the tick/s was/were removed, type of tick (larva or nymph/adult), number of removed tick/s and follow-up (at least two weeks) were recorded.

The ticks were removed with alligator forceps or an ear curette with the same intervention in all patients. Endoscopy was used during the physical examination of the patients' ears and during tick removal in all patients to detect small nymphal ticks and larvae. The ear canal and tympanic membrane of all patients were examined with endoscopy once again after tick removal.

The ticks removed from the patients' external auditory canals were preserved in 70% alcohol solution and taken to the Parasitology Laboratory of Van Yüzüncü Yıl University for taxonomic classification. All removed ticks were examined under a stereomicroscope (Leica MZ16, Leica Microsystems, Switzerland). The taxonomic findings given by Walker et al. (9) were used for morphological identification.

All patients were asked for any systemic symptoms for a possible infectious disease and were followed-up for two weeks for any systemic symptoms or signs; however, we could not provide any tests for infectious diseases due to the inadequate conditions of our hospital.

Statistical Analysis

Statistical analyses were performed using SPSS software version 23 (IBM SPSS® Statistics 23.0, Armonk, N.Y., USA). The proportions were presented using tables of frequencies and percentages. The chi-square test or Fisher's Exact test was used to compare these proportions in different groups. A p-value of less than 0.05 was considered to demonstrate a statistically significant result.

Results

The study included a total of 425 patients, 306 females (72%) and 119 males (28%). The mean age of the patients was 40 years with a standard deviation of 20 years. The youngest patient was 4 months old and the eldest was 81 years old. A total of 527 ticks were removed from the external auditory canals of these 425 patients. Three-hundred-and-fifty-one patients had adult or nymph ticks in their ear canal, and a total of 413 ticks were removed from the ear canals of these patients; 74 patients had a larval form of the tick, and a total of 114 larval forms were removed from these patients' ear canals. The causative agent of otolacariasis in all of our patients was the soft tick *O. megnini*. The main symptom of the patients at admission was foreign body sensation in the ear in 256 patients (60%), pain in 75 patients (18%), itching in 53 patients (12.5%), aural fullness and hearing loss in 26 patients (6%), and restlessness and ear pulling in 15 patients (3.5%) (Table 1).

The patients were analyzed according to their complaint duration. At admission, complaints had existed for one week in 113 patients (26.6%), for two weeks in 110 patients (25.9%), for three weeks in 101 patients (23.7%), for four weeks in 70 patients (16.5%), and for more than one month in 31 patients (7.3%) (Table 1).

The ticks were in the right ear in 205 patients (48.2%), in the left ear in 190 patients (44.7%), and in both ears in 30 patients (7.1%).

During endoscopic examination, there were no pathological findings with the ear canal in 371 patients (87.3%). Fifty-four patients (12.7%) had signs of external otitis, such as hyperemia and edema of the external ear canal, and ear drops containing antibiotic and steroid were given to these 54 patients. None of the patients in the study required systemic therapy.

Removed ticks were in the nymph or adult form in 351 patients (82.6%) and in the larval form in 74 patients (17.4%) (Table 1).

When patients with nymph or adult forms of the tick were distributed according to the seasons, 191 patients (54.4%) were admitted to the hospital in summer, 67 patients (19.1%) in spring, 66 patients (18.8%) in autumn, and 27 patients (7.7%) in winter. When patients with a larval form of the tick were distributed according to the seasons, 60 patients (81.1%) were admitted to the hospital in summer, 13 patients (17.6%) in autumn, one patient (1.4%) in spring. No patients with a larval form were admitted in the winter season ($p \leq 0.001$) (Figure 1).

More than half of the patients (238 out of 425) were females between the ages of 19–65 years. Compared to men, the incidence of ticks in females in this age group was quite high, and the difference was statistically significant ($p \leq 0.001$).

There was no statistically significant difference between females and males in the 0–18-year age group or in the 66 years and over group (Table 2).

Patients were analyzed according to major complaints. In patients with adult or nymph ticks, foreign body sensation was the major complaint in 241 patients (68.7%). In patients with larval ticks, pain was the major complaint in 46 patients (62%). Clinico-demographic characteristics of the patients are shown in Table 1.

Patients were analyzed according to the number of ticks removed. Whereas a single adult tick was detected in 301 of 351 patients (85.8%), two or more adult ticks were found in 50 patients (14.2%). A single larval tick was detected in 47 of 74 patients (63.5%), whereas two or more larval ticks were found in 27 patients (36.5%).

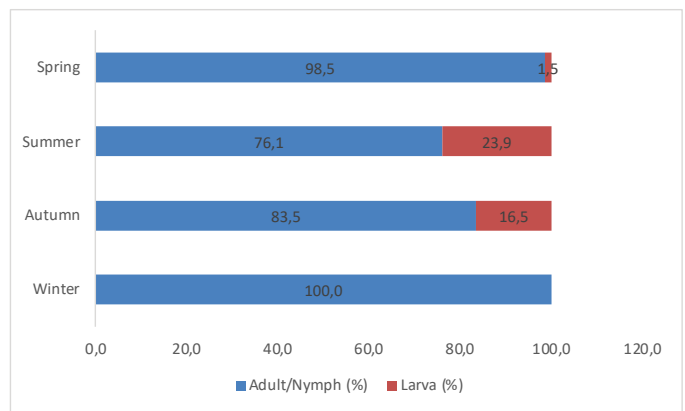


Figure 1. Distribution of adult/nymph and larva ticks by seasons

Table 1. Clinico-demographic characteristic of the patients

Adult or nymph (n)	Tick stage		p-value	
	Larva (n)			
Sex	Male	100 (28.5%)	19 (25.7%)	0.624
	Female	251 (71.5%)	55 (74.3%)	
Season	Winter	27 (7.7%)	0	0.007
	Spring	67 (19.1%)	1 (1.4%)	≤ 0.001
	Summer	191 (54.4%)	60 (81.1%)	≤ 0.001
	Autumn	66 (18.8%)	13 (17.6%)	0.804
Patient's major complaint	Pain	29 (8.3%)	46 (62.2%)	≥ 0.001
	Moving body	241 (68.7%)	15 (20.3%)	≥ 0.001
	Aural fullness or hearing loss	25 (7.1%)	1 (1.4%)	0.063
	Itching	41 (11.7%)	12 (16.2%)	0.283
Duration of complaint	Ear pulling	15 (4.3%)	0	0.085
	One week	67 (19.1%)	46 (62.2%)	≤ 0.001
	Two weeks	91 (25.9%)	19 (25.7%)	
	More than 2 weeks	193 (55.0%)	9 (12.2%)	

n: Number of patients

Table 2. Distribution of ticks in men and women by age group

Age groups (years)	Sex		p-value
	Male (n)	Female (n)	
0-18	41 (34.5%)	41 (13.4%)	>0.05
19-65	69 (58%)	238 (77.8%)	≤0.001
66 and over	9 (7.6%)	27 (8.8%)	>0.05

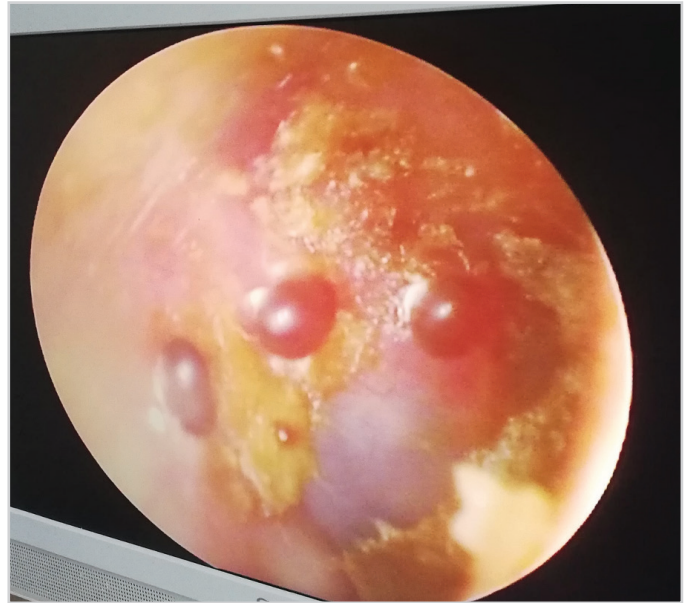
n: Number of patients

External ear canal and tympanic membrane examinations were performed in all patients during and after tick removal. There were only two types of complications: otitis externa and tympanic membrane perforation. External otitis was detected in 54 out of 425 patients (12.7%). Ear drops containing ciprofloxacin and dexamethasone sodium phosphate were administered to patients with otitis externa. After two weeks' follow-up, recovery was achieved in all patients. No treatment was given to patients with a normal ear canal, and no problems were encountered in this group during the two-week follow-up period. We detected tick-borne tympanic membrane perforation in only one patient that had a small perforation on the tympanic membrane while removing the tick attached to that membrane. This patient was not given any treatment but followed-up, and the perforation closed spontaneously during the two-week follow-up period. And no complications were encountered except minimal bleeding secondary to trauma in the external ear canal of patients, as a result of the unsuccessful tick removal attempt made by the relatives of the patients.

Discussion

Tick and tick-borne diseases affect both animals and humans directly or as a vector of different pathogens (10). Although ticks are less commonly seen in the external auditory canal (otoacariasis) compared to the other parts of the body, otoacariasis is commonly found in many parts of the world, including Madagascar, Chile, USA, Nepal, Malaysia, South Africa, India, Sri Lanka, and Turkey (11-19).

O. megnini, the spinose ear tick, displays a one-host life history and feeds on large ungulates such as horse, cattle, sheep, cow, and goats (20). It occasionally parasitizes dogs and humans. The larval and two nymphal stages of *O. megnini* feed in the ears of their host (Figures 2-5). Living conditions may differ among tick species. Ariyaratne et al. (5) investigated otoacariasis cases in five different districts of Sri Lanka, and they found that the *Dermacentor auratus* tick was the major tick species associated with human otoacariasis in all five districts, with *O. megnini* only being found in the Nuwara Eliya district. The Nuwara Eliya district is located at a higher elevation of 1800 m above the sea level with a mean annual temperature of 16 °C and an annual rainfall of 2300 mm. Our study area has an elevation and mean annual temperature similar to the Nuwara Eliya district and

**Figure 2.** A patient with four larval ticks in the right ear canal**Figure 3.** The larval form of the tick after removal

is located at a high elevation of 1530 m with a mean annual temperature of 7.1 °C and an annual rainfall of 467 mm. *O. megnini* was the only causative agent of otoacariasis in all our patients. *O. megnini* shows seasonal dynamics, with a high larval activity during the warmer and dryer months (8). In our district that is located in Eastern Anatolia, where our study was carried out, the summer season is hot and dry, and the winter season is cold and snowy. In our study, 81% of the patients with larval ticks were admitted to our hospital in summer, and there were no patients with a larval tick in the external ear canal in winter. Winter conditions of our district are not suitable for *O. megnini*. Furthermore, only 27 of the 425 patients were admitted to our hospital during winter, and there were only adult/nymph ticks in the ear canal of these 27 patients. It is likely that in these 27 patients, the tick had settled in the ears before winter. Because our district is a rural and socio-culturally underdeveloped area, patients can present to the hospital days or weeks after the onset of their

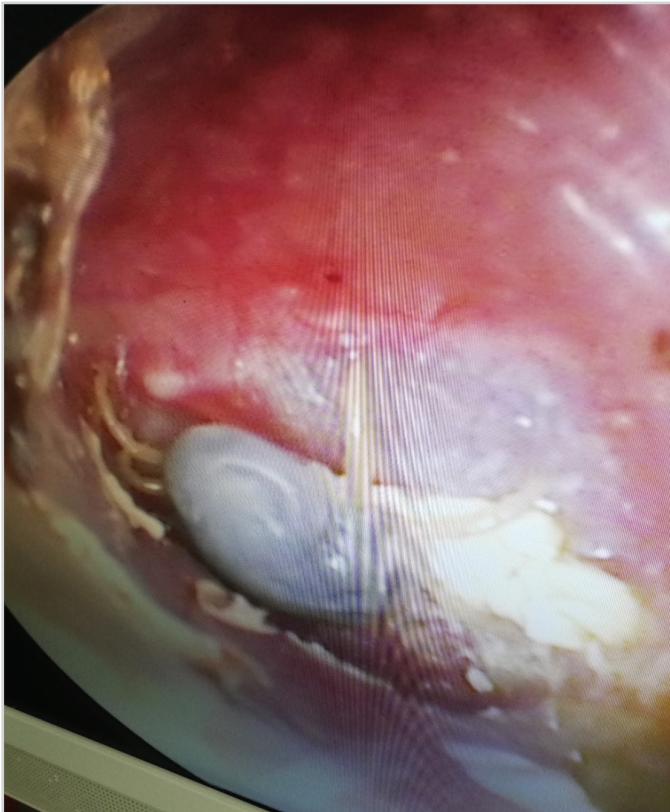


Figure 4. Nymphal form of tick in ear canal

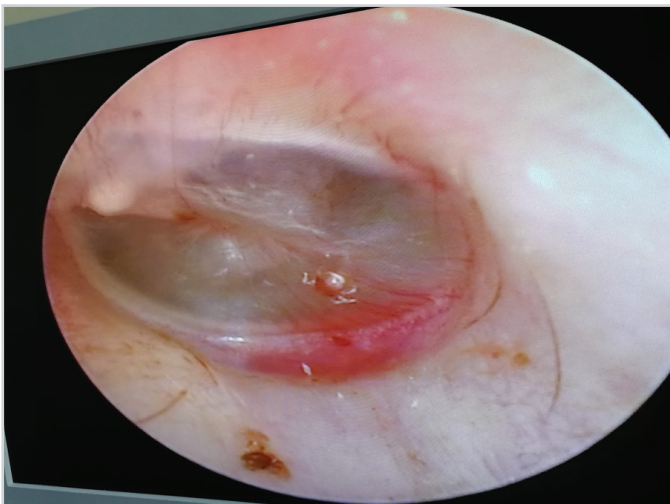


Figure 5. Nymphal form of tick on tympanic membrane

complaints. At the time of their admission to the hospital, 47.5% of our 425 patients with ticks reported that they had complaints for at least two weeks. During the interviews, the villagers stated that they knew when the ticks got into their ear, but they did not have the means or the opportunity to travel to the hospital; hence, they were late. We learned from the patients that some people in the villages attempted to remove the ticks with traditional methods, such as removing visible ticks with tweezers or by pouring milk, onion juice or oil into the ear canal to remove invisible ticks. A tick in the

outer canal is such a common and known problem in this region that most of the patients stated that they suspected they had ticks in their ear canal before the examination. Conversations with the patients and their relatives revealed that all of these methods were successful from time to time. None of our patients presented with a complication as a result of the unsuccessful tick removal attempts by their relatives, except minimal bleeding secondary to trauma in the external ear canal. We also did not observe any complication, except for bleeding from time to time due to trauma in the external auditory skin canal, in the interventions performed by the emergency physicians.

In our study, 238 of the 425 patients (56%) were women between the ages of 19–65 years. Agriculture and livestock are the main sources of income in the district. The families of all the patients in whom we detected ticks were either themselves engaged or had a neighbor within 100 meters of their home who was engaged in animal husbandry. In the district, the houses are situated very close to each other, and the barns are built in the same garden as the house. Sheep, goats, cows, and horses are reared in barns in this region, and the patients stated that they occasionally see ticks on the animals or on the ground. In the district, adult women are typically involved in gardening, animal nutrition, and breeding. These facts demonstrate why ticks are more common in adult women in this district. Indudharan et al. (21) showed that 70% of human intra-aural tick infestations in Malaysia were in children aged 0–10 years. Two subsequent studies in Sri Lanka by Dilrukshi et al. (18) and Ariyaratne et al. (5) reported that children below 10 years of age and women had a high risk for intra-aural tick infestations. In the referred studies, the higher numbers of children and women affected were attributed to these two groups being co-exposed during daily activities, such as gardening and gathering forest produce.

The literature generally recommends tick removal by mechanical methods instead of chemical methods (22). Gökdoğan et al. (19) stated that they removed ticks mechanically with the help of alligator forceps from the ear canal of 31 patients aged between 17–72 years without the need for general anesthesia. Ariyaratne et al. (5) reported 426 patients aged between 2 months–84 years, with a tick in the ear canal for a three-year period; however, they did not mention the methodology for tick removal and they stated that they saw only one tick in each patient. In our study, we had 425 patients with 527 ticks in a period of one year. As far as we know from the literature, our study is the largest series in the literature on cases with ear ticks. The ages of 425 patients included in our study ranged from 4 months to 81 years, and ticks were removed mechanically with alligator forceps or an ear curette without requiring sedation or general anesthesia in all patients except two. These two patients, aged 7 and 8 years, had a larval form of the tick, and the ticks were

removed with an ear curette under sedation. In none of the patients, local anesthesia or chemical solution was used.

In our experience, for several reasons, removing ticks from the ear canal is easier than removing any other type of other foreign bodies. Firstly, ticks engorged with blood occlude the ear canal completely or near completely and are easily visible and can be removed using alligator forceps by holding them from their soft abdomen. Secondly, ticks that have not yet occluded the ear canal are easily removed by holding their legs with alligator forceps. However, the main aspect of difficulty in tick removal involves removing the larval form of the tick. This larval form is difficult both to see and to remove. Because of its particularly small size, it is occasionally impossible to see the larval tick with an otoscope; but they can be seen in the hidden areas of the ear canal with an endoscope (Figure 6). This is a

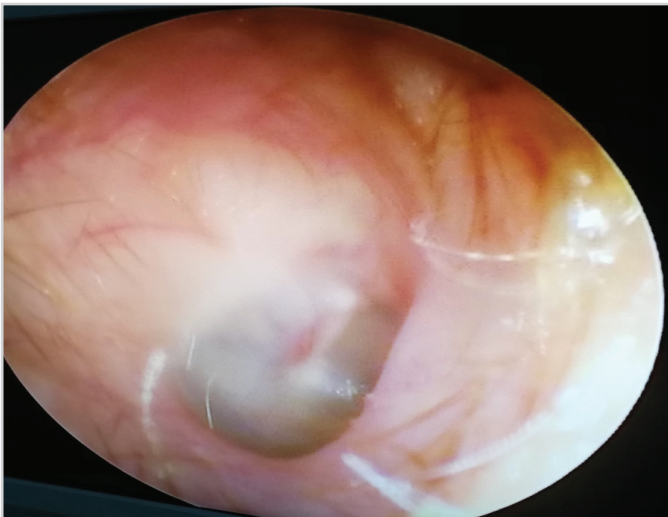


Figure 6a. A patient with hidden larval tick in the right ear canal. The photograph was taken with 30° endoscope. Although there was a larval tick, it was not visible in this position

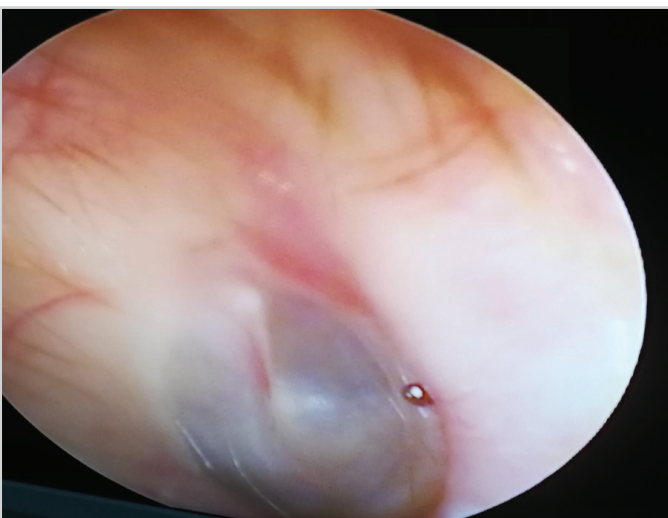


Figure 6b. The ear of the patient in **Figure 6a**. The hidden larval tick was visible by turning the 30° endoscope

significant issue, particularly in patients with a bony protrusion in the ear canal. We remove all the nymph and adult ticks and most of the larval ticks with alligator forceps, but this latter approach may not work in patients with a bony protrusion and larval ticks in the ear canal; in these patients, we remove ticks with an ear curette.

The major symptom of a larval tick in the ear canal was pain. We had many patients with ear pain and normal otoscopic findings, and with the assistance of an endoscope, we identified larval forms of the ticks in the ear canal's hidden areas. Therefore, if the otoscopic findings and complaints of the patient do not match, particularly in cases of normal otoscopy and pain complaint, we perform an ear examination with an endoscope in all of these patients.

Pain was the major complaint in 62% of the patients (46 out of 74) with a larval tick, and in 8% of the patients (29 out of 351) with an adult or nymph tick. In patients with an adult or nymph tick, sensation of a moving foreign body was the major complaint in 69% of the patients (241 out of 351). During tick removal, we observed that all of the 74 larval ticks attached to the ear canal and sucked blood. It is likely that ticks in the ear canal cause pain during feeding. Pain was documented as a major complaint in a minority of patients with a nymph or adult tick, and during removal of these ticks, we observed that more than 90% of adult or nymph ticks were freely moving in the ear canal without attaching themselves to the canal wall. Some ticks were so engorged that they completely blocked the ear canal and caused hearing loss, and patients' hearing problems resolved after tick removal. Eight of the ticks that completely blocked the ear canal were dead; most likely they were stuck in the ear canal and could not detach themselves (Figure 7).



Figure 7. An adult dead tick after removal. It was entirely obstructing the ear canal, and was probably stuck in the canal and could not get out

All other ticks were alive when they were removed. Facial paralysis or paresis and tick-related bleeding in the external ear canal were not observed in any of the patients. Tinnitus was described by some patients as a very rare symptom.

We did not encounter any systemic complications in any of our patients. Since none of the patients had a systemic finding, they were not referred to infectious diseases. No systemic symptoms or signs were observed during the follow-ups. Since tick is an endemic public health problem in the region, all patients were aware and informed about ticks and none of them described a systemic disease related to ticks in any other person in the past years. From our clinical observations and interviews with the patients and their relatives, we concluded that neither the current patients nor the previous patients that had ticks in their external ear canals in the past years had systemic disease. Fifty-three of the 425 patients had external otitis and were treated with local ear drops. In one patient, perforation was observed after the nymphal tick attached to the eardrum was removed. This perforation was in the tympanic membrane and resolved during the two-week follow-up.

Conclusion

To conclude, ticks in the ear is endemic in our district and poses a public health problem. Eradication of ticks in a rural area is not doable. Tick infestations could be minimized by taking various precautions. Ticks on livestock can be controlled by acaricides. Spraying the stables and soil areas around the house with acaricides will control the ticks on the ground. In tick-prevalent regions, increasing the presence of tick-eating animals, such as partridges, pheasants, chickens, rabbits, and geese on pasture areas where animals graze during the summer months may have an important role in controlling tick population. In addition, educating the general public on preventive methods is important. Our study is the largest series in the literature on cases with ear ticks.

Ethics Committee Approval: The study was approved by the Muş Provincial Health Directorate and Muş Malazgirt State Hospital Chief Physician on 18.02.2021, and the protocol number is 35465298-799.

Informed Consent: Informed consent was not received because of retrospective design of the study.

Peer-review: Externally and internally peer-reviewed.

Authorship Contributions

Surgical and Medical Practices: O.A., S.K., Concept: O.A., S.K., Ş.G.K., A.B.Y., Design: O.A., S.K., Ş.G.K., A.B.Y., Data Collection and/or Processing: O.A., S.K., Analysis and/or Interpretation: O.A., S.K., Ş.G.K., A.B.Y., Literature

Search: O.A., S.K., Ş.G.K., A.B.Y., Writing: O.A., S.K., Ş.G.K., A.B.Y.

Conflict of Interest: The authors have no conflicts of interest to declare.

Financial Disclosure: The authors declared that this study has received no financial support.

Main Points

- Ticks in the ear is endemic in our district (Muş, Turkey) and poses a public health problem.
- In our study, which is the largest series in the literature, we had 425 patients with 527 ticks.
- Ticks were removed mechanically with alligator forceps or an ear curette in all patients.
- Larval form of the ticks is occasionally impossible to see with an otoscope, and endoscopic examination is essential.
- Tick infestations could be minimized with various precautions and educating the general public on preventive methods.

References

1. Bursali A, Keskin A, Tekin S. A review of the ticks (Acari: Ixodida) of Turkey: species diversity, hosts and geographical distribution. *Exp Appl Acarol* 2012; 57: 91-104. [Crossref]
2. Antonelli PJ, Ahmadi A, Prevatt A. Insecticidal activity of common reagents for insect foreign bodies of the ear. *Laryngoscope* 2001; 111: 15-20. [Crossref]
3. Horak IG, Camicas JL, Keirans JE. The Argasidae, Ixodidae and Nuttalliellidae (Acari: Ixodida): a world list of valid tick names. *Exp Appl Acarol* 2002; 28: 27-54. [Crossref]
4. Diyes GCP, Rajakaruna RS. Life cycle of Spinose ear tick, *Otobius megnini* (Acari: Argasidae) infesting the race horses in Nuwara Eliya, Sri Lanka. *Acta Trop* 2017; 166: 164-176. [Crossref]
5. Ariyaratne S, Apanaskevich DA, Amarasinghe PH, Rajakaruna RS. Diversity and distribution of tick species (Acari: Ixodidae) associated with human otoacariasis and socio-ecological risk factors of tick infestations in Sri Lanka. *Exp Appl Acarol* 2016; 70: 99-123. [Crossref]
6. Salman M, Tarrés-Call J, editors. Ticks and Tick-Borne Diseases: Geographical Distribution and Control Strategies in the Euro-Asia Region. Wallingford: CABI Publishing; 2013. [Crossref]
7. Nava S, Guglielmone AA, Mangold AJ. An overview of systematics and evolution of ticks. *Front Biosci (Landmark Ed)* 2009; 14: 2857-77. [Crossref]
8. Diyes GC, Rajakaruna RS. Seasonal dynamics of spinose ear tick *Otobius megnini* associated with horse otoacariasis in Sri Lanka. *Acta Trop* 2016; 159: 170-5. [Crossref]
9. Walker AR, Bouattour A, Camicas JL, Estrada-Pena A, Horak IG, Latif AA, et al., editors. Ticks of domestic animals in Africa: a guide to identification of species. Edinburgh: Bioscience Reports; 2003. [Crossref]

10. Wikel S. Ticks and tick-borne pathogens at the cutaneous interface: host defenses, tick countermeasures, and a suitable environment for pathogen establishment. *Front Microbiol* 2013; 4: 337. [Crossref]
11. Uilenberg G, Hoogstraal H, Klein JM. Les tiques (Ixodoidea) de Madagascar et leur role vecteur. *Archives de l'Institut Pasteur de Madagascar* 1979;1-153. [Crossref]
12. Burchard L, Larenas N, Ramos P. Human otoacariasis caused by *Otobius megnini* in Calama, Chile. *Bol Chil Parasitol* 1984; 39: 15-6. [Crossref]
13. Eads RB, Campos EG. Human parasitism by *Otobius megnini* (Acari: Argasidae) in New Mexico, USA. *J Med Entomol* 1984; 21: 244. [Crossref]
14. Fegan D, Glennon J. Intra-aural ticks in Nepal. *Lancet* 1996; 348: 1313. [Crossref]
15. Indudharan R, Dharap AS, Ho TM. Intra-aural tick causing facial palsy. *Lancet* 1996; 348: 613. [Crossref]
16. Naudé TW, Heyne H, van der Merwe IR, Benic MJ. Spinose ear tick, *Otobius megnini* (Dugès, 1884) as the cause of an incident of painful otitis externa in humans. *J S Afr Vet Assoc* 2001; 72: 118-9. [Crossref]
17. Somayaji KS, Rajeshwari A. Human otoacariasis. *Indian J Otolaryngol Head Neck Surg* 2007 ;59: 237-9. [Crossref]
18. Dilrukshi PR, Yasawardene AD, Amerasinghe PH, Amerasinghe FP. Human otoacariasis: a retrospective study from an area of Sri Lanka. *Trans R Soc Trop Med Hyg* 2004; 98: 489-95. [Crossref]
19. Gökdoğan O, Çakabay T, Baran H, Karabulut B, Tasdemir C, Vatansever Z. Otoacariasis: demographic and clinical outcomes of patients with ticks in the ear canal. *Braz J Otorhinolaryngol* 2016; 82: 416-21. [Crossref]
20. Hoogstraal H. Argasid and nuttalliellid ticks as parasites and vectors. *Adv Parasitol* 1985; 24: 135-238. [Crossref]
21. Indudharan R, Ahamad M, Ho TM, Salim R, Htun YN. Human otoacariasis. *Ann Trop Med Parasitol* 1999; 93: 163-7. [Crossref]
22. Due C, Fox W, Medlock JM, Pietzsch M, Logan JG. Tick bite prevention and tick removal. *BMJ* 2013; 347: f7123. [Crossref]