

Malignant Otitis Externa: A Retrospective Analysis and Treatment Outcomes

Malign Otitis Eksterna: Geriye Dönük Analiz ve Tedavi Sonuçları

Original Investigation

Özgün Araştırma

İsa Kaya , Baha Sezgin , Sevinç Eraslan , Kerem Öztürk , Sercan Göde , Cem Bilgen ,
Tayfun Kirazlı 

Department of Otorhinolaryngology, Ege University School of Medicine, İzmir, Turkey

Abstract

Objective: The purpose of this study was to analyze previous treatments and outcomes in patients with malignant otitis externa (MOE) retrospectively. The efficacy of medical and surgical treatments was also evaluated.

Methods: This study included 25 patients diagnosed with MOE and treated at the Department of Otorhinolaryngology, Ege University School of Medicine between 2006 and 2017. The duration of hospitalization, Hemoglobin A1c (HbA1c) levels of the patients, erythrocyte sedimentation rate (ESR), source of the infection, complications, and previous medical and surgical treatments were also retrospectively assessed.

Results: The mean age of the patients (7 females and 18 males) was 69.68±11.29 years. The mean length of hospital stay in patients with HbA1c levels ≤6 and in

patients with HbA1c levels >6 was 26.86 and 33.39 days, respectively. The mean hospitalization time was significantly longer in patients with HbA1c levels >6 (p<0.05). Additionally, elderly patients (age>65 years) had a significantly longer hospital stay in our study (p<0.05). ESR was found to be 52.76±32.49 (9–108) mm/h at the first examination and 14.92±1.22 (4–32) mm/h at the time of discharge.

Conclusion: MOE is an aggressive disease that requires conservative management, and ESR proved to be a good indicator of treatment response. Long-term anti-biotherapy are recommended for treatment.

Keywords: Malignant otitis externa, treatment, temporal bone, prognosis



Öz

ORCID IDs of the authors:

İ.K. 0000-0001-7096-4858;
B.S. 0000-0002-7340-452X;
S.E. 0000-0001-6608-4508;
K.Ö. 0000-0003-0949-8653;
S.G. 0000-0002-2148-0723;
C.B. 0000-0003-0853-1095;
T.K. 0000-0002-5284-8842.

Cite this article as: Kaya İ, Sezgin B, Eraslan S, Öztürk K, Göde S, Bilgen C, Kirazlı T. Malignant Otitis Externa: A Retrospective Analysis and Treatment Outcomes. Turk Arch Otorhinolaryngol 2018; 56(2): 106-10.

Amaç: Çalışmanın amacı, malign otitis eksternalı hastalarda önceki tedavileri ve sonuçları geriye dönük olarak analiz etmektir. Bu makalede medikal ve cerrahi tedavinin etkinliği değerlendirilmiştir.

Yöntemler: Bu çalışmaya 2006–2017 yılları arasında Ege Üniversitesi Tıp Fakültesi Kulak Burun Boğaz Hastahıkları Anabilim Dalı'na yatırılarak malign otitis eksterna tedavisi gören 25 hasta dahil edildi. Hastanede kalış süresi, hastaların hemogloblinA1c (HbA1c) düzeyleri, eritrosit sedimentasyon hızı (ESH), enfeksiyon etkeni, komplikasyonlar, laboratuvar sonuçları, uygulanan medikal ve cerrahi tedaviler geriye dönük olarak değerlendirildi.

Bulgular: Malign otitis eksternalı (MOE) 25 hasta (7 kadın ve 18 erkek, ortalama yaş 69.68±11.29 yıl) çalışmaya dahil edildi. HbA1c değeri 6 ve daha düşük olan hastalarda hastanede yatış süresi 26,86 gün iken,

HbA1c değeri 6'dan yüksek olan hastalarda 33,39 gün olarak saptandı. Ortalama yatış süresi, HbA1c değeri 6'dan yüksek olan hastalarda istatistiksel olarak anlamlı şekilde daha yüksekti (p<0.05). Ayrıca yaşlı hastalarda (yaş>65) istatistiksel olarak yatış sürelerinin daha uzun olduğu saptandı (p<0.05). Birinci muayenede ortalama ESH 52.76±32.49 mm/saat (9-108 mm/saat) olarak saptandı. Taburculuk sırasında ortalama ESH 14.92±1.22 mm/saat (4-32 mm/saat) bulundu.

Sonuç: Malign otitis eksterna, konservatif şekilde yönetilmesi gereken agresif bir hastalıktır. ESH tedaviye yanıtı değerlendirmede iyi bir göstergedir. Uzun süreli antibiyoterapi tedavide önerilir.

Anahtar kelimeler: Malign otitis eksterna, tedavi, temporal kemik, prognoz

Corresponding Author/Sorumlu Yazar:
Baha Sezgin; bahasezgin18@hotmail.com

Received Date/Geliş Tarihi: 30.11.2017

Accepted Date/Kabul Tarihi: 27.02.2018

© Copyright 2018 by Official Journal of the Turkish Society of Otorhinolaryngology and Head and Neck Surgery Available online at www.turkarchotolaryngol.net

© Telif Hakkı 2018 Türk Kulak Burun Boğaz ve Baş Boyun Cerrahisi Derneği Makale metnine www.turkarchotolaryngol.net web sayfasından ulaşılabilir.

DOI: 10.5152/tao.2018.3075

Introduction

Malignant otitis externa (MOE) is a rare fatal inflammatory disease of the external auditory canal, temporal bone, and skull base (1). The disease is associated with serious complications with cranial nerve involvement and high mortality and morbidity rate (1). MOE was first reported by Toul-

mouche in 1838, and it was termed as “*malignant*” by Chandler in 1968 (2, 3). MOE is generally caused by *Pseudomonas aeruginosa*, and it is common in elderly patients with diabetes or immunocompromised patients (4). *Staphylococcus aureus*; *Proteus mirabilis*; and some species of fungi, such as aspergillus and *Candida species*, have also been de-

scribed to cause MOE (5). Clinical manifestations of the disease are otalgia persisting for longer than one month, chronic otorrhea, headache, and cranial nerve involvement (6). The disease begins in the external auditory canal and then spreads to the skull base through Santorini's fissures. Additionally, the disease spreads to the stylomastoid and jugular foramina (7). Cranial nerve involvement may occur as a result of infection progression. Facial nerve is the most common involved cranial nerve, but glossopharyngeal, vagus, accessory, or hypoglossal nerve involvements can also occur (8). MOE is also complicated by parotitis, mastoiditis, jugular vein thrombosis, meningitis, and death (9). The diagnosis of MOE is made from a combination of clinical, laboratory, and radiologic findings and nuclear imaging. According to the study conducted by Cohen and Friedman (10), the major (obligatory) and minor (occasional) diagnostic criteria of MOE are shown in Table 1.

The main treatment of MOE is long-term antimicrobial therapy (11). Other treatment strategies are close follow-up of blood glucose levels (12), repeated local debridement of necrotic tissue, and hyperbaric oxygen therapy (13). Surgery has a limited role in the treatment of MOE (14).

The aim of the present study was to evaluate the demographic data, clinical presentations, predisposing factors, and management of MOE.

Methods

This study included 25 patients diagnosed with MOE and treated at the Department of Otorhinolaryngology, Ege University School of Medicine between 2006 and 2017. The study was conducted in accordance with international ethical standards and the World Medical Association Declaration of Helsinki. The diagnosis of MOE was based on the criteria shown in Table 1. A biopsy was taken from all patients with granulations in the external auditory canal to exclude malignancy. Computed tomography (CT) was performed to identify the spread of the disease. Antibiotics were prescribed for at least 6 weeks. Microscopic examination and cleaning of the external auditory canal were performed for all patients. House Brackmann (HB) scores were used for facial nerve grading (15). The study was approved by the Research Eth-

ical Committee of Ege University. Demographic data, presence of underlying disease, cranial nerve involvement, length of hospital stay, blood glucose levels, and treatment regimens were reviewed from the medical records. Scintigraphy and magnetic resonance imaging (MRI) findings were evaluated. The patients were divided into two groups according to HbA1c levels. The patients had ≤ 6 HbA1c and >6 HbA1c levels, respectively.

Statistical analysis

Statistical analysis was made using computer software version 21.0 (IBM Corp.; Armonk, NY, USA). Chi-square exact tests were used for the comparison of categorical data. Data were expressed as "mean (standard deviation; SD)", percent (%), minimum-maximum where appropriate. $p < 0.05$ was considered statistically significant.

Results

The mean age of the patients (7 females and 18 males) was 69.68 ± 11.29 (range: 51–91) years. All patients had diabetes. No patient had any other form of immunocompromising condition. All patients were found to have otalgia upon the first examination. Headache was the second most common (80%) symptom, and otorrhea (72%) was the third most common symptom. Nine (36%) patients had facial nerve involvement. According to the HB scores, five (20%) patients had grade 6 facial paralysis and two (8%) patients had grade 3. There was not any difference in facial paralysis grade of the patients after treatment.

According to the findings of the examination, all patients had edema and granulations in the external auditory canal. Additionally, three patients had polyps in the external auditory canal.

Pseudomonas aeruginosa was identified in the swab culture of the external auditory canal from 11 (44%) patients, *S. aureus* in three patients (12%), *Aspergillus flavus* in two patients (8%), and *Acinetobacter baumannii* complex in one (4%) patient. The swab cultures of eight (32%) patients did not yield any growth.

The mean total leukocyte count was $9.62 \pm 3.61 \times 10^3/\mu\text{L}$ (11.38 – $20.24 \times 10^3/\mu\text{L}$), and the mean C-reactive protein (CRP) level was 2.54 ± 1.90 (0.15–6.30) mg/dL at the first examination.

The mean erythrocyte sedimentation rate (ESR) was 52.76 ± 32.49 (9–108) mm/h at the first examination and 14.92 ± 1.22 (4–32) at the time of discharge.

The mean blood glucose level was 183.24 ± 79.84 (70–371) mg/dL, and the mean HbA1c level was 7.53 ± 1.56 (5.80–11.20) at the first examination. Additionally, the mean blood glucose level was 117.44 ± 4.22 (80–168) mg/dL at the time of discharge.

We found that 12 patients (48%) had positive CT findings and 14 patients (56%) had positive MRI findings (Figure 1, 2). Eight (32%) patients had bone erosion, two (8%) patients had soft-tissue involvement, and two (8%) patients had mastoid involvement in their CT scans. Scintigraphy using technetium-99 was performed for all patients, and nine (36%) patients had pos-

Table 1. Diagnostic criteria of malignant external otitis (10). All of the obligatory criteria must be present in order to establish the diagnosis. The presence of occasional criteria alone does not establish it

Major Criteria (Obligatory)	Minor Criteria (Occasional)
Pain	<i>Pseudomonas</i> in culture
Exudate	Diabetes mellitus
Edema	Old age
Granulations	Cranial nerve involvement
Microabscesses (when operated)	Positive radiograph
Positive Technetium-99 (99Tc) bone scan of failure of local treatment after more than 1 week	Debilitating conditions

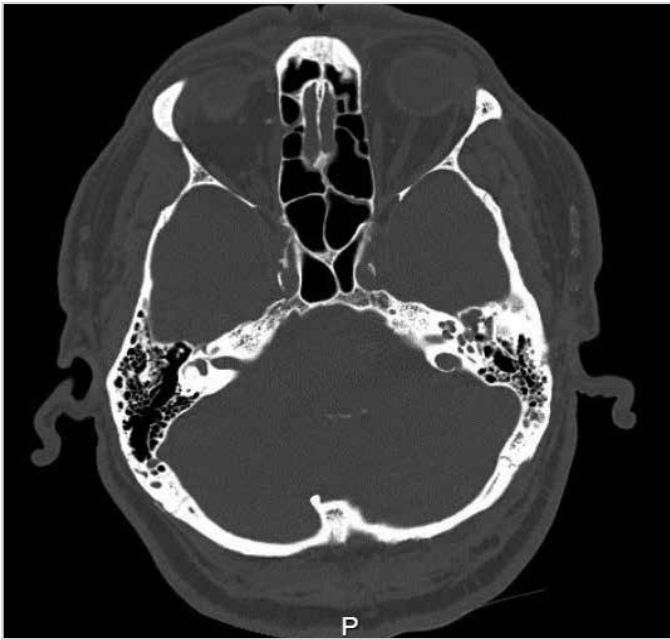


Figure 1. Computed tomography view of the patient with left malignant otitis externa

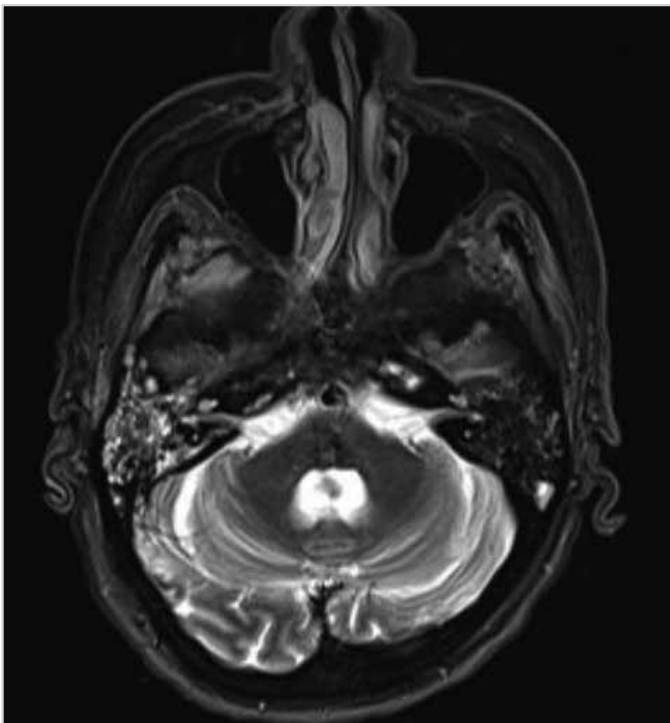


Figure 2. Magnetic resonance imaging view of the patient with bilateral malignant otitis externa

itive signs. Nine (36%) patients showed high tissue activity at the skull base, temporal bone, and mastoid bone on scintigraphy.

All patients were treated with intravenous antibiotherapy for at least 6 weeks. Eighteen (72%) patients were treated with ciprofloxacin (Cipro 400 mg flakon, Biopharma, Istanbul, Turkey), two (8%) patients with ciprofloxacin (Cipro 400 mg flakon, Biopharma, Istanbul, Turkey) and piperacillin tazobactam (Tazocin 4.5 g flakon, Pfizer, New York, USA), two (8%) patients with meropenem (Meronem 1 g flakon, Astra Zeneca, Cambridge,

England), two (8%) patients with ciprofloxacin (Cipro 400 mg flakon, Biopharma, Istanbul, Turkey) and daptomycin (Cubicin 500 mg flakon, Novartis, Basel, Switzerland), and one (4%) patient with meropenem (Meronem 1 g flakon, Astra Zeneca, Cambridge, England) and linezolid (Zyvoxid 600 mg flakon, Pfizer, New York, USA).

A biopsy was taken from all patients with granulation tissue in the external auditory canal (80%), and histopathological examination of the biopsy showed features of inflammatory granulation tissue. This biopsy was conducted with the aim of excluding malignancy.

The Shepard ventilation tube was used in four patients, and, in one of these patients, the ventilation tube was used after local debridement of necrotic material. Two (8%) patients with cholesteatoma in the middle ear were operated. Canal wall-down tympanomastoidectomy (type 4) and facial nerve decompression surgery were performed in one patient, and canal wall-up tympanomastoidectomy was performed for the other patient.

The mean length of hospital stay was 31.56 ± 15.91 (16-95) days, and the mean follow-up duration was 29.72 ± 27.81 (1-99) months. According to the findings, the mean length of hospital stay in patients with HbA1c levels ≤ 6 and in patients with HbA1c levels > 6 was 26.86 and 33.39 days, respectively. The mean hospitalization time was significantly longer in patients with HbA1c levels > 6 ($p=0.035$). Additionally, elderly patients (age > 65 years) had a statistically significant longer hospital stay in our study ($p=0.024$). Hyperbaric oxygen treatment was administered to eight (32%) patients. The mean length of hospital stay was not significantly different in these patients ($p=0.65$).

Discussion

Malignant otitis externa is a necrotizing infection of the external auditory canal, temporal bone, and surrounding soft tissue. The most common symptoms of the disease are severe otalgia and chronic otorrhea. Moreover, the occurrence of dysphagia, dysphonia, and facial paralysis may be associated with cranial nerve involvement (8). According to a study conducted by Bhat et al. (16), the most common symptom of MOE is earache, and the second most common symptom is ear discharge. In addition, they reported that polyps in the external auditory canal were found in 14% of the patients. All the patients in our study had severe otalgia; 72% of them had chronic otorrhea, and 12% of them had polyps in the external auditory canal.

Malignant otitis externa usually affects elderly patients with diabetes. In our study, all the patients had diabetes, and the mean age was 69.68 ± 11.29 years. In our study, elderly patients had a longer hospital stay in comparison to adult patients. Rubin and Yu (4) reported that microangiopathy and impaired blood circulation in patients with diabetes may play a main role in the pathogenesis of MOE. Additionally, elderly patients have more inpatient procedures and longer hospitalizations (17).

The facial nerve is the most commonly affected cranial nerve because of its proximity to the external auditory canal. Mani et al. (8) and Soudry et al. (18) compared patients with facial paralysis and without facial paralysis who were diagnosed with MOE and found no significant difference in survival. According to a study conducted by Franco-Vidal et al. (19), 9 (20%) of 46 patients had facial nerve involvement. Similarly, in our study, 20% of the 25 patients had grade 6 facial paralysis, and 8% of them had grade 3 facial paralysis. Intracranial abscess occurred in one of the patients with grade 6 facial paralysis.

Most studies have shown that *Pseudomonas aeruginosa* is the most commonly isolated microbiological agent (1, 5, 16). In a study conducted by Shavit et al. (5), *Pseudomonas aeruginosa* was isolated in 39 (44.3%) of 88 patients and *S. aureus* in 7 (8%) patients (5). Bhat et al. (16) isolated *Pseudomonas aeruginosa* in 11 (73%) of 15 patients. We identified *Pseudomonas aeruginosa* in 11 (44%) of 25 swab cultures of the external auditory canal. Moreover, we identified *S. aureus* in three patients (12%) and *A. flavus* in two patients (8%).

Inflammatory markers, such as ESR, white blood cell count, or CRP, may be increased in patients with MOE (6, 8). In a study of 28 patients by Lee et al. (6), the mean ESR and CRP levels were found to be 34.8 mm/h and 5.33 mg/dL, respectively, in 12 patients whose disease could be controlled with therapy. Additionally, the mean ESR and CRP levels were found to be 96.1 mm/h and 15.46 mg/dL, respectively, in 16 patients who did not respond to treatment. They reported a statistically significant difference between the groups (6). According to a study by Mani et al. (8), ESR was measured in 16 patients, and they found the mean ESR level to be 53 mm/h, with a range of 3-144 mm/h. However, they did not find any association between the ESR level and CT findings. Bhat et al. (16) found that ESR was greater than 100 mm/h in 3 of 15 patients, and it was between 50 and 100 mm/h in four patients. In our study, the mean ESR and CRP levels were found to be 52.76±32.49 mm/h and 2.54±1.90 mg/dL, respectively. At the first examination, ESR levels were found to be increased by 50%-80% and CRP levels by 66.7%-78.6% in our study. As a result, ESR and CRP may be useful laboratory markers for the screening of MOE (20).

Although there are no unified guidelines regarding the treatment of MOE and the optimal duration of treatment is unknown, oral or intravenous antibiotherapy is usually administered for 4-6 weeks (21). Bacterial culturing provides the basis for antibiotic selection. If culture results are negative, ciprofloxacin with or without rifampin, newer generation fluoroquinolones, or third-generation cephalosporin are commonly used (22). Shavit et al. (5) reported that almost 65 (73%) of 88 patients were treated with intravenous ceftazidime, whereas the remaining were treated with high-dose oral quinolones. Moreover, voriconazole was administered to five patients. In a study by Rubin Grandis et al. (23), systemic or topical fluoroquinolones have allowed effective outpatient treatment and have decreased the length of hospital stay. In our study, 3 (12%) patients were treated with

antifungal therapy and all of the patients were treated intravenous antibiotherapy.

Aspergillus fumigatus is the most common fungal organism causing MOE (24). *A. flavus* is a less frequent pathogen and is very rarely isolated in MOE. *A. flavus* was isolated from two patient specimens in our study. Antifungal therapy is warranted because MOE can be caused by fungal organisms or a mixed bacterial and fungal infection (22). Voriconazole is the first treatment option for aspergillus infections (25). Both intravenous and oral forms can be used in fungal MOE. In our study, intravenous voriconazole treatment was administered to two patients at 200 mg twice daily. Hyperbaric oxygen therapy was also administered to these two patients. There may be renal side effects of voriconazole, and the renal function should thus be closely monitored (26). Amphotericin B and/or Iitraconazole therapies are the other treatment options for fungal MOE. We should decrease the dosage of amphotericin B, because of the side effects, especially renal failure. Fungal MOE is a refractory disease, and therefore, radical mastoidectomy is required in the majority of cases (27). In our study, no patient with fungal MOE required radical mastoidectomy, and the regression of disease was detected with intravenous voriconazole treatment.

The efficacy of hyperbaric oxygen therapy has not been demonstrated when compared with treatment with antibiotics and/or surgery (13). Shupak et al. (28) recommended hyperbaric oxygen as an adjuvant therapy. Narozny et al. (27) assessed the effectiveness of hyperbaric oxygen therapy and reported that 93.3% of patients had no ear discharge and pain in the second month. Additionally, they found subjective radiological improvement in the CT images, and the patients were discharged early from the hospital. Hyperbaric oxygen therapy was administered to eight refractory cases in our study, and there was no statistically significant difference in the length of hospital stay. We administered hyperbaric oxygen therapy only for refractory patients. Therefore, the effect of oxygen therapy on the length of hospital stay was not found to be statistically significant.

According to our analysis, uncontrolled diabetes mellitus and older age are associated with the length of hospital stay. On the other hand, the hospitalization time decreased after the use of oral newer generation fluoroquinolones.

Conclusion

Malignant otitis externa is an aggressive disease that requires conservative management, and ESR proved to be a good indicator of treatment response. Long-term antibiotherapy are recommended for treatment.

Ethics Committee Approval: Ethics committee approval was received for this study from the Ethics Committee of Ege University Clinical Research (22.02.2016 - 15-12/5).

Informed Consent: Written informed consent was obtained from patients who participated in this study

Peer-review: Externally peer-reviewed.

Author Contributions: Concept - İ.K., B.S., S.E., K.Ö., S.G., C.B., T.K.; Design - İ.K., B.S., S.E., K.Ö., S.G., C.B., T.K.; Supervision - İ.K., B.S., S.E., K.Ö., S.G., C.B., T.K.; Resource -T.K., C.B., İ.K., K.Ö.; Data Collection and/or Processing - B.S., S.G., S.E.; Analysis and/or Interpretation - İ.K., K.Ö., B.S.; Literature Search - S.G., B.S., İ.K.; Writing - K.Ö., B.S., S.G.; Critical Reviews - S.E., S.G., B.S., C.B., İ.K.

Conflict of Interest: The authors have no conflicts of interest to declare.

Financial Disclosure: The authors declared that this study has received no financial support.

Etik Komite Onayı: Bu çalışma için etik komite onayı Ege Üniversitesi Tıp Fakültesi Klinik Araştırmalar Etik Kurulu'ndan alınmıştır (22.02.2016 - 15-12/5).

Hasta Onamı: Yazılı hasta onamı bu çalışmaya katılan hastalardan alınmıştır.

Hakem Değerlendirmesi: Dış bağımsız.

Yazar Katkıları: Fikir - İ.K., B.S., S.E., K.Ö., S.G., C.B., T.K.; Tasarım - İ.K., B.S., S.E., K.Ö., S.G., C.B., T.K.; Denetleme - İ.K., B.S., S.E., K.Ö., S.G., C.B., T.K.; Kaynaklar - T.K., C.B., İ.K., K.Ö.; Veri Toplanması ve/veya İşlemesi - B.S., S.G., S.G.; Analiz ve/veya Yorum - İ.K., K.Ö., B.S.; Literatür Taraması - S.G., B.S., İ.K.; Yazıyı Yazan - K.Ö., B.S., S.G.; Eleştirel İnceleme - S.E., S.G., B.S., C.B., İ.K.

Çıkar Çatışması: Yazarlar çıkar çatışması bildirmemişlerdir.

Finansal Destek: Yazarlar bu çalışma için finansal destek almadıklarını beyan etmişlerdir.

References

- Karaman E, Yilmaz M, Ibrahimov M, Hacıyev Y, Enver O. Malignant otitis externa. *J Craniofac Surg* 2012; 23: 1748-51. [\[CrossRef\]](#)
- Bhandary S, Karki P, Sinha BK. Malignant otitis externa: A review. *Pac Health Dialog* 2002; 9: 64-7.
- Chandler JR. Malignant otitis externa. *Laryngoscope* 1968; 78: 1257-94. [\[CrossRef\]](#)
- Rubin J, Yu VL. Malignant external otitis: insights into pathogenesis, clinical manifestations, diagnosis, and therapy. *Am J Med* 1988; 85: 391-8. [\[CrossRef\]](#)
- Shavit SS, Soudry E, Hamzany Y, Nageris B. Malignant external otitis: Factors predicting patient outcomes. *Am J Otolaryngol* 2016; 37: 425-30. [\[CrossRef\]](#)
- Lee SK, Lee SA, Seon SW, Jung JH, Lee JD, Choi JY, et al. Analysis of prognostic factors in malignant external otitis. *Clin Exp Otorhinolaryngol* 2017; 10: 228-35. [\[CrossRef\]](#)
- Nadol JB Jr. Histopathology of Pseudomonas osteomyelitis of the temporal bone starting as malignant external otitis. *Am J Otolaryngol* 1980; 1: 359-71. [\[CrossRef\]](#)
- Mani N, Sudhoff H, Rajagopal S, Moffat D, Axon PR. Cranial nerve involvement in malignant external otitis: Implications for clinical outcome. *Laryngoscope* 2007; 117: 907-10. [\[CrossRef\]](#)
- Giamarellou H. Malignant otitis externa: The therapeutic evolution of a lethal infection. *J Antimicrob Chemother* 1992; 30: 745-51. [\[CrossRef\]](#)
- Cohen D, Friedman P. The diagnostic criteria of malignant external otitis. *J Laryngol Otol* 1987; 101: 216-21. [\[CrossRef\]](#)
- Strauss M, Aber RC, Conner GH, Baum S. Malignant external otitis: Long-term (months) antimicrobial therapy. *Laryngoscope* 1982; 92: 397-406. [\[CrossRef\]](#)
- Resouly A, Payne DJH, Shaw KM. Necrotizing otitis externa and diabetes control. *Lancet* 1982; 1: 805-6. [\[CrossRef\]](#)
- Phillips JS, Jones SE. Hyperbaric oxygen as an adjuvant treatment for malignant otitis externa. *Cochrane Database Syst Rev* 2005; CD004617. [\[CrossRef\]](#)
- Reines JM, Schindler RA. The surgical management of recalcitrant malignant external otitis. *Laryngoscope* 1980; 90: 369-78. [\[CrossRef\]](#)
- House JW, Brackmann DE. Facial nerve grading system. *Otolaryngol Head Neck Surg* 1985; 93: 146-7. [\[CrossRef\]](#)
- Bhat V, Aziz A, Bhandary SK, Aroor R, Kamath P SD, Saldanha M. Malignant otitis externa - A retrospective study of 15 patients treated in a tertiary healthcare center. *Int Adv Otol* 2015; 11: 72-6. [\[CrossRef\]](#)
- Sylvester MJ, Sanghvi S, Patel VM, Eloy JA, Ying YM. Malignant otitis externa hospitalizations: Analysis of patient characteristics. *Laryngoscope* 2017; 127: 2328-36. [\[CrossRef\]](#)
- Soudry E, Joshua BZ, Sulkes J, Nageris BI. Characteristics and prognosis of malignant external otitis with facial paralysis. *Arch Otolaryngol Head Neck Surg* 2007; 133: 1002-4. [\[CrossRef\]](#)
- Franco-Vidal V, Blanchet H, Bebear C, Dutronc H, Darrouzet V. Necrotizing external otitis: A report of 46 cases. *Otol Neurotol* 2007; 28: 771-3. [\[CrossRef\]](#)
- Chen JC, Yeh CF, Shiao AS, Tu TY. Temporal bone osteomyelitis: The relationship with malignant otitis externa, the diagnostic dilemma and changing trends. *Scientific World Journal* 2014; 2014: 591714. [\[CrossRef\]](#)
- Conterno LO, da Silva Filho CR. Antibiotics for treating chronic osteomyelitis in adults. *Cochrane Database Syst Rev* 2009; 3: CD004439. [\[CrossRef\]](#)
- Liu XL, Peng H, Mo TT, Liang Y. Malignant otitis externa in a healthy non-diabetic patient. *Eur Arch Otorhinolaryngol* 2016; 273: 2261-5. [\[CrossRef\]](#)
- Rubin Grandis J, Branstetter BFT, Yu VL. The changing face of malignant (necrotising) external otitis: Clinical, radiological, and anatomic correlations. *Lancet Infect Dis* 2004; 4: 34-9. [\[CrossRef\]](#)
- Ling SS, Sader C. Fungal malignant otitis externa treated with hyperbaric oxygen. *Int J Infect Dis* 2008; 12: 550-2. [\[CrossRef\]](#)
- Walsh TJ, Anaissie EJ, Denning DW, Herbrecht R, Kontoyiannis DP, Marr KA, et al. Treatment of aspergillosis: Clinical practice guidelines of the Infectious Diseases Society of America. *Clin Infect Dis* 2008; 46: 327-60. [\[CrossRef\]](#)
- Walton J, Coulson C. Fungal malignant otitis externa with facial nerve palsy: Tissue biopsy AIDS diagnosis. *Case Rep Otolaryngol* 2014; 192318. [\[CrossRef\]](#)
- Narozny W, Kuczkowski J, Stankiewicz C, Kot J, Mikaszewski B, Przewozny T. Value of hyperbaric oxygen in bacterial and fungal malignant external otitis treatment. *Eur Arch Otorhinolaryngol* 2006; 263: 680-4. [\[CrossRef\]](#)
- Shupak A, Greenberg E, Hardoff R, Gordon C, Melamed Y, Meyer WS. Hyperbaric oxygenation for necrotizing (malignant) otitis externa. *Arch Otolaryngol Head Neck Surg* 1989; 115: 1470-5. [\[CrossRef\]](#)