

Evaluation of Cases Who Underwent Reconstruction Through Pectoralis Major Myocutaneous Flap after Laryngopharyngectomy

Larengofarenjektomi Sonrası Pectoralis Major Myokutan Flep ile Rekonstrüksiyon Uygulanan Olguların Değerlendirilmesi

Battal Tahsin Somuk¹, Onur Çiftçi², Erdinç Aygenc²

Original Investigation
Özgün Araştırma

¹Department of Otorhinolaryngology, Gaziosmanpaşa University School of Medicine, Tokat, Turkey

²Department of Otorhinolaryngology, Private Güven Hospital, Ankara, Turkey

Abstract

Objective: In this retrospective study, we discussed the results of patients who underwent hypopharynx reconstruction through a pectoralis major myocutaneous flap (PMMF) after laryngopharyngectomy.

Methods: Twenty-three patients who underwent total laryngectomy, subtotal pharyngectomy, and/or esophagus upper segment resection due to advanced-stage (T3 and T4) laryngeal, hypopharyngeal, and esophagus upper segment-located squamous cell carcinoma and subsequent reconstruction with PMMF were retrospectively evaluated. While the minor complications were determined to be wound site infection, hemorrhage, and disruption of suture at the donor site, major complications were determined to be anastomotic line disruption, fistula, and dysphagia.

Results: Eighteen (78.2%) patients were male and five (21.7%) were female; their ages varied between 33

and 72 years (mean: 60.1). According to lesion localization, 11 patients were evaluated as having laryngeal cancer, seven as having hypopharyngeal cancer, and five as having esophagus upper segment-located cancer. The rate of minor complications was 30.4%: fistula was observed in 11 (47.8%) patients and 13 (56.5%) patients mentioned difficulty swallowing only solid foods. The total follow-up period ranged from 4 to 60 (mean: 31.6) months.

Conclusion: PMMF is continuing to be a good alternative reconstruction method for the reconstruction of partial hypopharyngeal defects because it is easily obtainable, one surgical team is sufficient when using the flap, and it is associated with low morbidity and mortality rates.

Keywords: Hypopharynx, reconstructive surgical procedure, complications, pectoralis muscle

Öz

Amaç: Bu geriye dönük çalışmada larengofarenjektomi sonrası pektoralis major myokutan flep ile hipofarenks rekonstrüksiyonu uygulanan hastaların sonuçları tartışılmıştır.

Yöntemler: İleri evre larenks (T3 ve T4), hipofarenks ve özefagus üst segment yerleşimli yassı hücreli karsinom nedeniyle total larenjektomi, subtotal farenjektomi ve/veya özefagus üst segment rezeksiyonu uygulanan ve sonrasında pektoralis major myokutan flebiyle (PMMF) rekonstrüğe edilen 23 hasta geriye dönük olarak değerlendirildi. Minör komplikasyonlar yara yeri enfeksiyonu, kanama ve donör sahada sütür açılması; majör komplikasyonlar olarak anastomoz hattında açılma, fistül ve disfaji olarak belirlendi.

Bulgular: Hastalarımızın 18'i (%78.2) erkek, beşi (%21.7) kadın olup yaşları 33 ile 72 arasında (orta-

lama:60.1) değişmekteydi. Lezyon lokalizasyonuna göre 11 hasta larenks, yedi hasta hipofarenks ve beş hasta özefagus üst segment kanseri olarak değerlendirildi. Minör komplikasyon oranımız %30.4, fistül 11 (%47.8) hastada, katı gıdalara yutma gücü 13 (%56.5) hastada saptandı. Hastalarımızın izlem süreleri 4 ile 60 ay arasında değişmekte olup ortalama 31.6 ay olarak saptandı.

Sonuç: Hipofarengeal parsiyel defektlerin rekonstrüksiyonunda PMMF kolay elde edilebilir olması, aynı seansta uygulanabilirliği, tek cerrahi ekibin yeterli olması, mortalite ve morbidite oranının düşük olması nedeniyle iyi bir alternatif rekonstrüksiyon yöntemi olmaya devam etmektedir.

Anahtar Kelimeler: Hipofarenks, rekonstrüktif cerrahi girişim, komplikasyonlar, pektoral kas



This study was presented at the 11th International Congress of Otorhinolaryngology and Head Neck Surgery, 17-19 April 2014, Ankara, Turkey.

Bu çalışma, 11. Uluslararası Kulak Burun Boğaz ve Baş Boyun Cerrahisi Kongresi'nde poster bildirisi olarak sunulmuştur, 17-19 Nisan 2014, Ankara, Türkiye.

Address for Correspondence/Yazışma Adresi:
Battal Tahsin Somuk
E-mail: btahsin@hotmail.com

Received Date/Geliş Tarihi: 04.03.2016

Accepted Date/Kabul Tarihi: 07.06.2016

© Copyright 2016 by Official Journal of the Turkish Society of Otorhinolaryngology and Head and Neck Surgery Available online at www.turkarchotorhinolaryngol.org

© Telif Hakkı 2016 Türk Kulak Burun Boğaz ve Baş Boyun Cerrahisi Derneği Makale metnine www.turkarchotorhinolaryngol.org web sayfasından ulaşılabilir.

DOI: 10.5152/tao.2016.1603

Introduction

The treatment of laryngopharyngeal cancers is one of the basic problems of head and neck surgery. The method of treatment to be preferred and the

method to repair the surgical defect that will develop after primary or salvage surgery are important parameters in determining the morbidity and mortality. The reconstruction of the defect that oc-

Table 1. Demographic data, treatment modality, and follow-up periods

Patient	Age	Gender	Tumor location	Preop. RT	Postop. RT	Adj. CT	Follow-up period (month)
1	67	M	Larynx		+		36
2	71	M	Larynx		+		19
3	63	M	EUS	+		+	7
4	66	M	Larynx		+	+	13
5	59	M	Larynx		+		7
6	68	M	EUS		+	+	8
7	48	M	Larynx		+		16
8	62	F	Hypopharynx		+	+	13
9	45	M	Hypopharynx	+		+	5
10	56	M	EUS		+		22
11	72	M	Larynx		+		11
12	66	M	Hypopharynx		+		60
13	61	F	Hypopharynx		+		48
14	60	M	Larynx		+		60
15	59	M	Larynx		+		60
16	42	F	Hypopharynx		+	+	60
17	33	M	Hypopharynx		+		60
18	62	M	EUS		+		24
19	61	M	Larynx		+		60
20	68	F	Hypopharynx		+		40
21	65	F	Hypopharynx		+	+	36
22	63	M	Larynx		+		60
23	67	M	EUS	+		+	4

M: male; F: female; EUS: esophagus upper segment; Preop: preoperative; Postop: postoperative; RT: radiotherapy; Adj. CT: adjuvant chemotherapy

curs after the surgical treatment of laryngopharyngeal cancers is associated with a number of difficulties. The basic purpose of pharyngeal reconstruction is to create a lumen covered with the epithelium that provides deglutition.

A pectoralis major myocutaneous flap (PMMF) is an easily applicable flap that provides opportunity for primary reconstruction in closure of the large subtotal pharyngeal defects that occur after the resection of laryngopharyngeal tumors. This flap was first defined by Ariyan (1) in 1970 and has been recently used for the reconstruction of pharyngeal defects. In this study, we aimed to reveal the functional results of reconstruction with PMMF in case of subtotal pharyngeal defects and to evaluate its efficiency.

Methods

This was a retrospective study that was approved by the ethics review board (Ankara Numune Training and Research Hospital, 2010/050). Informed consent was obtained from all patients. Twenty-three patients who underwent total laryngectomy, subtotal pharyngectomy, and/or esophagus upper segment resection

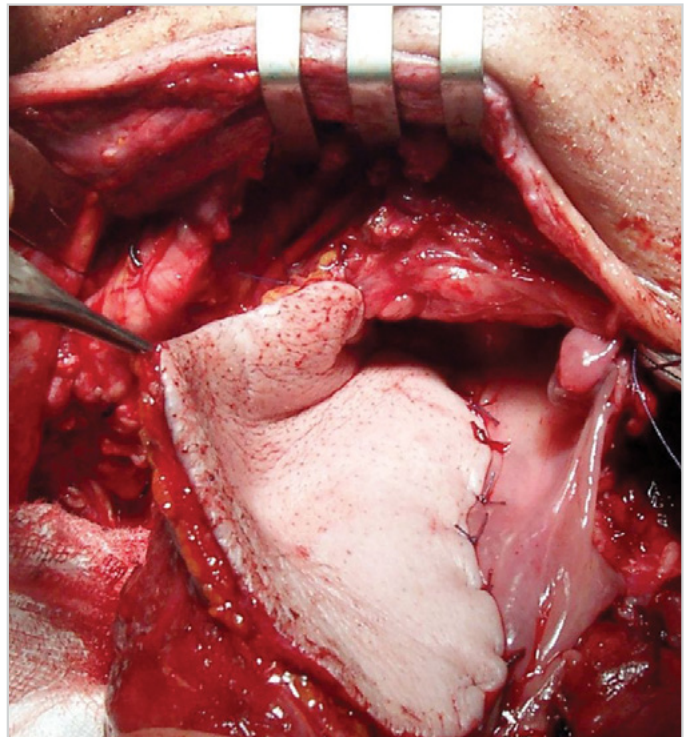


Figure 1. Prepared flap is sutured to the residual posterior pharyngeal mucosa to create neopharynx

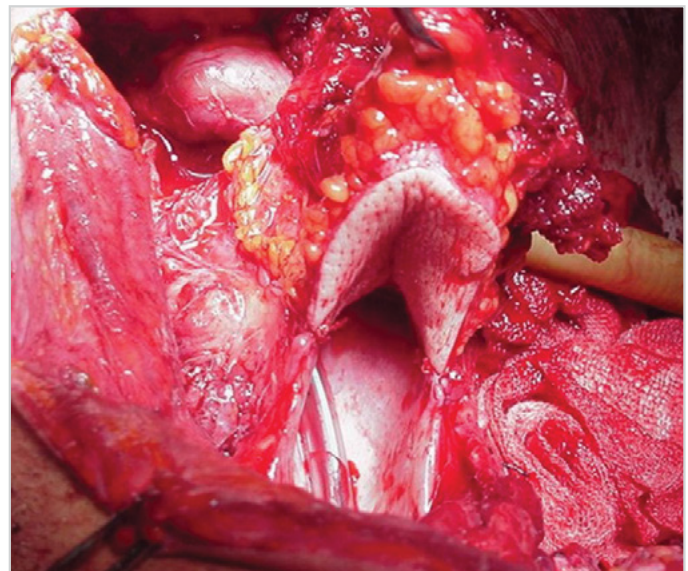


Figure 2. U-shaped flap sutured to posterior pharyngeal wall

due to advanced-stage (T3 and T4) laryngeal, hypopharyngeal, and esophagus upper segment-located squamous cell carcinoma and subsequent reconstruction with PMMF were retrospectively evaluated between January 1998 and December 2009. Three patients underwent preoperative radiotherapy and operation due to the presence of residual tumor, while the other 20 patients were selected for surgical operation as the primary treatment method. The data related to the patients are presented in Table 1. Eighteen patients were male and 5 were female; their ages varied between 33 and 72 years (mean: 60.1). All patients underwent total laryngectomy, subtotal pharyngectomy, and/or

Table 2. Postoperative complications

Complication	Count (n)	Percent (%)
Major		
Pharyngocutaneous fistula	11/23	47.8
Swallowing difficulty (solid)	13/23	56.5
Swallowing difficulty (solid and liquid)	5/23	21.7
Minor		
Infection	2/23	8.6
Hemorrhage	0	0
Wound dehiscence (cervical and donor site)	5/23	21.7

esophagus upper segment resection according to the location of the tumor and unilateral and/or bilateral Type 3 modified radical neck dissection, according to the cervical nodal status. Twenty patients underwent postoperative radiotherapy, while eight patients underwent chemotherapy. Radiotherapy was started for patients without fistula in the 6th postoperative week. Radiotherapy was administered 3 weeks after the closure of fistula in patients with fistula.

After tumor resection, PMMF was sutured to the residual posterior pharyngeal mucosa to create the neopharynx. In order to create U-shaped anterior and lateral walls of the neopharynx, the defect was closed by suturing the upper end of flap to the tongue base mucosa, lateral sides to the residual pharyngeal mucosa, and lower end to the upper part of the esophagus with 3.0 vicryl suture (Figure 1, 2). The most important point in this step is to have minimal tension on the suture line between the flap and pharynx; the flap should freely and completely come over the defect. The second layer was formed using the lateral fascia of the muscle and peripheral tissues. The third layer was provided by suturing the medial fascia of muscle with platysma with 4.0 vicryl suture. The outer layer was closed with 4.0 prolene such that no pressure would be caused if the skin flap was appropriate. A suction drainage system was used in all cases. Before closing the defect, a nasogastric tube was placed. Postoperative follow-up of all patients was similar. During the postoperative period, all the patients were observed in the intensive care unit for the first 24 hours, and then, they were transferred to the service rooms. Feeding of the patients was started on the 2nd postoperative day through a nasogastric feeding tube. The time for oral feeding was determined to be the 21st postoperative day. Oral feeding was delayed in cases in which fistula developed before the 21st day. The preliminary findings for fistula development were determined to be high fever, high C-reactive protein (CRP), infected fluid or salivary drainage, hyperemia developed around skin sutures, and pain at the surgical site. Before starting oral feeding, the status of the neopharynx was evaluated through barium esophagography in all patients (Figure 3). The oral feeding was primarily started with soft food; in subsequent days, a normal solid diet was initiated. Oral toleration was attempted slowly with swallowing exercises in patients experiencing difficulty. Oral feeding was stopped in patients considered to have fistula de-

velopment. In these patients, feeding was continued through a nasogastric feeding tube. The evaluation of deglutition was performed upon subjective complaints of the patients. When the patients were discharged from the hospital, their food types and feeding habits were investigated in subsequent follow-ups. On the 21st postoperative day, oral feeding was started in patients who had no fistula. Examination of swallowing was performed in the 2nd month in patients without fistula and 2 months after the closure of fistula in patients with fistula. The patients were asked to evaluate their swallowing difficulties after each meal. While evaluating the deglutition, the patients were requested to mention one of the following situations: 1, normal nutrition; 2, difficulty swallowing solid foods; and 3, difficulty swallowing both solid and liquid foods.

The patients discharged from the hospital were called for their outpatient follow-ups. Routine follow-ups were performed every month during the 1st year, every 3 months during the 2nd year, and once a year subsequently. In our study, the patients were evaluated in terms of postoperative infection, hemorrhage, suture disruption, fistula development, and deglutition parameters.

Statistical Analysis

The Statistical Package for Social Sciences software (version 20.0 for Windows, SPSS Inc.; Chicago, IL, USA) was used to perform all analyses. Survival was calculated by the Kaplan-Meier product-limit method from the date of surgery to the time of death [overall survival (OS)] or last visit.

Results

According to lesion localization, 11 patients were evaluated as having primary laryngeal cancer, seven as having hypopharyngeal cancer, and five as having esophagus upper segment-located cancer; all of the female patients were observed to have hypopharyngeal tumor. The other patients, except for the ones administered preoperative radiotherapy, were treated with postoperative radiotherapy and/or chemotherapy according to the pathological stage of the disease (Table 1).

Histopathological examination of all the specimens revealed negative surgical margins. The total follow-up period ranged from 4 to 60 months (mean: 31.6) (Table 1). The overall survival was 47.8% at 2 years, 39.1% at 3 years, and 34.7% at 5 years. The mean overall survival was 32 months, and the 95% confidence interval (CI) was 23 to 41.

No flap necrosis and flap loss were observed. The complications encountered during the postoperative follow-up period were analyzed in 2 categories: minor and major (Table 2).

In total, three patients had wound dehiscence in cervical skin incisions, and one of the three patients had received preoperative radiotherapy. The reason was considered to be the delay in wound healing, based on preoperative radiotherapy and chronic malnutrition. Moreover, there were disruptions at the donor site in two patients. These lesions were closed in nearly 1 week through local care and dressing. Uncomplicated local infection was observed in two patients. No postoperative hemorrhage was seen.

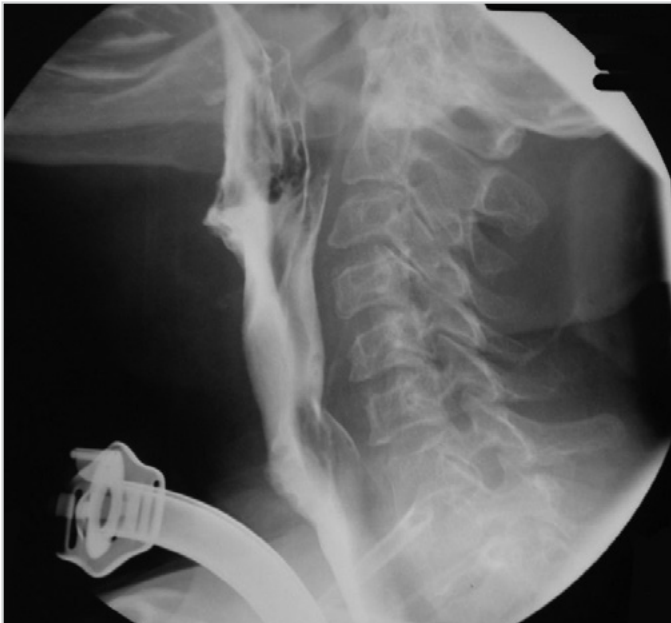

Figure 3. Postoperative barium esophagography showing a functioning neopharynx

Fistula was observed in 11 patients (47.8%). Six of these patients had laryngeal tumors, three had hypopharyngeal tumors, and two had esophagus upper segment-located tumors. All the fistulas were observed in the anastomose region between the upper side of the flap and tongue base. In all patients, the fistula was closed with conservative methods without the need of an additional surgical operation within nearly four weeks.

In terms of difficulty in swallowing two months after oral feeding, five (21.7%) patients mentioned no difficulty in swallowing, five (21.7%) mentioned difficulty in swallowing of solid and liquid foods, and 13 (56.5%) mentioned difficulty in swallowing of only solid foods.

Percutaneous gastrostomy was necessary in two of the five patients experiencing difficulty in swallowing of both liquid and solid foods.

Discussion

The reconstruction of large defects that occur after large surgical resection of cancers in the head and neck region is problematic. Different reconstruction methods are administered according to the location and size of the defect and the professional judgment of the head and neck reconstruction team (2, 3).

For the reconstruction of hypopharyngeal defects that occur after laryngopharyngeal cancer excision, local pedicled flaps such as PMMF can be used according to the type of defect, and organ transposition flaps such as radial forearm, anterolateral leg, and jejunal free vascularized flaps or gastric pull-up can also be administered. While the jejunal free vascularized flap is used for total defects over the thoracic inlet, the gastric pull-up is preferred for the hypopharyngeal and esophageal defects below the thoracic inlet (4).

The radial forearm and jejunal free vascularized flaps are the most frequently used ones in partial and total defects of the hypopharynx. The jejunal free flap is the best choice when administered by experienced surgeons (5, 6). The advantages of free flaps are their flexibility, their ability to be vascularized perfectly, and their ability to be transferred to large defects. Furthermore, the necessity of laparotomy and bowel anastomosis are disadvantages when compared with free myocutaneous flaps.

Free myocutaneous flaps and PMMFs are the most frequently used flaps in repairing partial pharyngeal defects (4). An ideal reconstructive technique should meet the requirements such as having oncologic reliability, enabling reconstruction in the same session as surgery, having an easily applicable procedure, having a short operation period, having a low complication rate, and having satisfactory functional results.

PMMF was first defined by Fabian (7) in 1984 for hypopharyngeal reconstruction and developed by Spriano et al. (6). After the first report of Fabian (7), notifications were provided in small-sized series by 4 researchers (6, 8-10). A skin graft on the posterior wall was used by Fabian (7), Lee et al. (8), and Leon et al. (9) but was not used by Spriano et al. (6) and Morshed et al. (10). A myofascial flap lacking the skin graft has been recently used by Montemari et al. (4) in a series of 45 patients. Because the basic purpose of pharyngeal reconstruction is to provide a lumen covered with the epithelium, we considered the necessity of using the skin over the muscle for the reconstruction of mucosa. The role of a Montgomery salivary by-pass tube upon the prevention of fistula should be discussed; however, the tube is expensive and not well tolerated (11). In their study, Leon et al. (9) mentioned that they used a by-pass tube and reported a lower rate of fistula in patients with the tube than in those without the tube. Because we did not use a salivary by-pass tube in any of our patients, we cannot make any positive or negative comments.

In a study in which the prevertebral fascia was directly sutured to PMMF in a U shape, Fabian (7) reported the rate of fistula to be 27% and the rate of stenosis to be 6%. In their study, Lee et al. (8) reported that fistula developed in all patients and the rate of stenosis was 25%. In their study, Spriano et al. (6) mentioned that a salivary by-pass tube prevented the re-opening of sutures and decreased salivary fistula occurrence as well as prevented stenosis based on flap contraction (6). Cristalli et al. (12) reported 13.4% salivary fistulas in their long-term results and observed functional stenosis in none of their patients. In their study, they also evaluated swallowing difficulty and stated 63.4% good swallowing, 26.9% adequate swallowing, and 9.6% bad swallowing rates. In our study, the fistula rate was 47.8%. Fistulas developed in our 3 patients who underwent preoperative radiation. In the literature, the fistula rates in patients treated with preoperative radiation varied between 13% and 50% (6-8). In our study, difficulty in swallowing of solid foods was noticed in 56.5% patients and difficulty in swallowing of both solid and liquid foods was noticed in 21.7% patients. Compared with the literature findings, we noticed a higher difficulty in swallowing rate. Montemari et al. (4) did not use a skin island in pectoralis

myocutaneous flap considering that it would deform the flexibility of the flap and create a bulk effect. In their series of 45 patients, they noticed hypopharyngeal stenosis only in 2 patients. One of the reasons that caused difficulty in swallowing in our patients could be the use of a skin island in the flap. The second reason could be not using a salivary by-pass tube mentioned in the literature to prevent difficulty in swallowing based on flap contraction in our patients.

Conclusion

Consequently, the use of PMMF in the reconstruction of hypopharyngeal partial defects can be a good alternative method because it is easily obtainable, one surgical team is sufficient when using the flap, and it is associated with low morbidity and mortality rates.

Ethics Committee Approval: Ethics committee approval was received for this study from the ethics committee of Ankara Numune Training and Research Hospital (No: 2010-050).

Informed Consent: Written informed consent was obtained from patients who participated in this study.

Peer-review: Externally peer-reviewed.

Author contributions: Concept - E.A.; Design - B.T.S.; Supervision - E.A.; Resource - E.A., B.T.S.; Data Collection &/or Processing - B.T.S., E.A.; Analysis &/or Interpretation - B.T.S., O.Ç.; Literature Search - O.Ç.; Writing - B.T.S.; Critical Reviews - E.A., O.Ç.

Conflict of Interest: No conflict of interest was declared by the authors.

Financial Disclosure: The authors declared that this study has received no financial support.

Etik Komite Onayı: Bu çalışma için etik komite onayı Ankara Numune Eğitim ve Araştırma Hastanesi Etik Komitesi'nden alınmıştır (No: 2010-050).

Hasta Onamı: Yazılı hasta onamı bu çalışmaya katılan hastalardan alınmıştır.

Hakem Değerlendirmesi: Dış bağımsız.

Yazar Katkıları: Fikir - E.A.; Tasarım - B.T.S.; Denetleme - E.A.; Kaynaklar - E.A., B.T.S.; Veri Toplanması ve/veya işleme - B.T.S., E.A.; Analiz ve/veya Yorum - B.T.S., O.Ç.; Literatür taraması - O.Ç.; Yazıyı Yazan - B.T.S.; Eleştirel İnceleme - E.A., O.Ç.

Çıkar Çatışması: Yazarlar çıkar çatışması bildirmemişlerdir.

Finansal Destek: Yazarlar bu çalışma için finansal destek almadıklarını beyan etmişlerdir.

References

1. Ariyan S. The pectoralis major myocutaneous flap. *Plast Reconstr Surg* 1979; 63: 73-81. [\[CrossRef\]](#)
2. Hanasono MM, Matros E, Disa JJ. Important aspects of head and neck reconstruction. *Plast Reconstr Surg* 2014; 134: 968-80. [\[CrossRef\]](#)
3. Calli C, Teknos TN, Agrawal A, Schuller DE, Ozer E, Songu M. Does body mass index matter while selecting the flap type for pharyngeal reconstructions? *J Craniofac Surg* 2014; 25: 780-2. [\[CrossRef\]](#)
4. Montemari G, Rocco A, Galla S, Damiani V, Bellocchi G. Hypopharynx reconstruction with pectoralis major myofascial flap: our experience in 45 cases. *Acta Otorhinolaryngol Ital* 2012; 32: 93-7.
5. Spriano G, Pellini R, Roselli R. Pectoralis major myocutaneous flap for hypopharyngeal reconstruction. *Plast Reconstr Surg* 2002; 110: 1408-13. [\[CrossRef\]](#)
6. Spriano G, Piantanida R, Pellini R. Hypopharyngeal reconstruction using pectoralis major myocutaneous flap and pre-vertebral fascia. *Laryngoscope* 2001; 111: 544-7. [\[CrossRef\]](#)
7. Fabian RL. Reconstruction of the laryngopharynx and cervical esophagus. *Laryngoscope* 1984; 94: 1334-50. [\[CrossRef\]](#)
8. Lee KY, Loré JM Jr. Two modifications of pectoralis major myocutaneous flap (PMMF). *Laryngoscope* 1986; 96: 363-7. [\[CrossRef\]](#)
9. León X, Quer M, Burgués J. Montgomery salivary bypass tube in the reconstruction of the hypopharynx. Cost-benefit study. *Ann Otol Rhinol Laryngol* 1999; 108: 864-8. [\[CrossRef\]](#)
10. Morshed K, Szymański M, Golabek W. Reconstruction of the hypopharynx with U-shaped pectoralis major myocutaneous flap after total pharyngo-laryngectomy. *Eur Arch Otorhinolaryngol* 2005; 262: 259-62. [\[CrossRef\]](#)
11. Cusumano RJ, Silver CE, Brauer RJ, Strauch B. Pectoralis myocutaneous flap for replacement of cervical esophagus. *Head Neck* 1989; 11: 450-6. [\[CrossRef\]](#)
12. Cristalli G, Pellini R, Roselli R, Manciooco V, Pichi B, Spriano G. Pectoralis major myocutaneous flap for hypopharyngeal reconstruction: long-term results. *J Craniofac Surg* 2011; 22: 581-4. [\[CrossRef\]](#)