

A Rare Cause of Acute Respiratory Distress: Cervical Ranula

Akut Solunum Sıkıntısının Nadir Bir Nedeni: Servikal Ranula

Case Report
Olgu Sunumu

Gültekin Övet, Necat Alataş, Fatih Güzelkara, Fatma Nur Kocacan, Habibe Övet, Merih Önal
Department of Otorhinolaryngology, Konya Training and Research Hospital, Konya, Turkey

Abstract

Plunging or cervical ranula is a mucus extravasation pseudocyst arising from the sublingual gland that is located below the mylohyoid muscle. Clinically, if large enough, cervical ranulas can affect swallowing, speech, chewing, and even breathing. The acute presentation of ranulas, which are clinically known as slow-growing,

painless masses, is rare. In this study, we present a case of cervical ranula that grew in a short period of 3 days and resulted in respiratory distress and that was operated in our clinic.

Keywords: Ranula, acute, respiratory distress

Özet

Plunging veya servikal ranula sublingual bezden kaynaklanan ve milohyoid kasın altına yerleşen bir mukus ekstrasvazasyon kistidir. Klinik olarak servikal ranulalar, eğer boyutları artarsa yutmayı, konuşmayı, çiğnemeyi ve hatta nefes almayı bile etkileyebilmektedir. Klinik olarak yavaş büyüyen ağrısız kitleler olarak bilinen ranulanın

akut presentasyonu nadirdir. Bu makalede akut olarak ortaya çıkan üç gün gibi kısa bir süre içinde solunum sıkıntısı ortaya çıkaracak kadar büyüyen ve kliniğimizde opere edilen servikal ranula olgusu sunulacaktır.

Anahtar Kelimeler: Ranula, akut, solunum sıkıntısı

Introduction

Ranulas are mainly cystic lesions arising from the sublingual glands. Also known as plunging ranula, cervical ranula (CR) is a mucous extravasation cyst that presents with swelling in the neck, and it emerges from the sublingual gland and spreads to the inferior mylohyoid muscle (1). It emerges as secretions accumulate and move to the posterior through the free edge or dehiscence of the mylohyoid muscle. Ranula may develop because of the removal of submandibular gland stones or because of a complication of surgical interventions performed in the maxillofacial area (2).

Although most plunging ranulas appear in the second or third decades of life, cases in which they present in infancy have been reported (3). Clinically, cervical ranulas appear as soft, slow-growing masses, and they can affect swallowing, speech, chewing, and even breathing (if particularly large) (4). The acute presentation of ranulas is rare (5). In this study, we present a case of cervical ranula that grew over a short period of 3 days, resulted in respiratory distress, and was operated in our clinic. To the best of our knowledge, cases of cervical ranula that cause respiratory distress are rarely encountered in the literature, and only one case has been previously reported (6). Here we report the second case.

Case Report

A 32-year-old male patient with swelling in the left submandibular area and in the left half of the neck was admitted to the emergency department because of respiratory distress. The patient was referred to our clinic from the emergency department and then hospitalized. The swelling in the patient's neck had emerged approximately 3 days prior to hospital admission and had quickly grown. The main complaint of the patient was respiratory distress. Patient history revealed that he had an accident 8 years ago and had undergone surgery because of a mandibular fracture.

In the neck examination, a diffuse, soft, fluctuant, non-tender swelling was present in the left submandibular region. No redness, heat, and pain were observed. The partially mobile mass had a smooth surface without a clear extent. Oral examination revealed a slightly hyperemic smooth, soft mass localized in the sublingual gland under the tongue (Figure 1). No signs of infection in the tonsils, pharynx, and teeth were observed. Endoscopic examination revealed that the tongue and epiglottis were being pushed backward by a mass that was narrowing the airway. Urgent magnetic resonance imaging (MRI) was performed because of the patient's respiratory distress. MRI revealed an approximately 10x15-



Address for Correspondence/Yazışma Adresi:

Gültekin Övet
E-mail: gultekinovet@gmail.com

Received Date/Geliş Tarihi: 11.12.2014

Accepted Date/Kabul Tarihi: 14.05.2015

© Copyright 2015 by Official Journal of the Turkish Society of Otorhinolaryngology and Head and Neck Surgery Available online at

www.turkarchotorhinolaryngol.org

© Telif Hakkı 2015 Türk Kulak Burun Boğaz ve Baş

Boyun Cerrahisi Derneği Makale metnine

www.turkarchotorhinolaryngol.org web

sayfasından ulaşılabilir.

DOI: 10.5152/tao.2015.834

cm cystic mass that started from the sublingual region and extended to the tongue base. The cystic mass was responsible for the respiratory distress because it was pushing the tongue base and epiglottis posteriorly. The left pyriform sinus was found to be obliterated (Figure 2). Written informed consent was obtained from the patient. On the basis of the examination and MRI results and in consideration of the respiratory distress, the patient was diagnosed with cervical ranula and underwent immediate surgery. The tracheotomy set was kept ready as emergency tracheotomy could be required. Nasal intubation was performed with the help of video laryngoscopy (Aircraft Medical Ltd.; Edinburgh, United Kingdom) by an experienced anesthesiologist. Because the mass was large and extended to the tongue base, the submandibular gland was excised by a cervical approach to provide a better view. The mass was followed upward and observed to pass through the mylohyoid muscle. A thin-walled cystic mass was anteriorly followed to the mouth base and posteriorly to the tongue base, and it was excised together with the sublingual gland. The patient completely recovered after the operation. No paresthesia was observed in the innervation area of the lingual nerve. No recurrence was observed during 1 year post-operative follow-up.

Discussion

Plunging ranula, also known as a diving or a cervical ranula, is a pseudocyst formed by the extravasation of mucous from the sublingual gland to the submandibular space. It may or may not have an additional oral component (7).

Explaining the reasons for the acute and progressive clinical course of ranula observed in the patient presented in this study is difficult. A dramatic increase in salivary secretion indicates an acinar injury in the sublingual gland. Histopathological examination of the excised sublingual glands revealed that the ranula had developed in the traumatized area in a particular region in the sublingual glands (8). One possible explanation for the abnormal salivary secretions that caused the rapid growth of the ranula in this case is the aberrant parasympathetic stimulation of the sublingual gland, which normally has a spontaneous secretion (9). Blood flow has been reported to increase in the sublingual gland by parasympathetic nerve stimulation through the kallikrein–bradykinin system, and this stimulation may cause acinar hyper secretion (9). Moreover, the local hypersecretion in acinar rupture (in the damaged area) correlates with an increased blood flow (9). However, mucus is extravasated from the damaged acinar area in accordance with the acinar hypersecretion, and this extravasation may lead to acute cervical ranula and subsequent respiratory distress within a short time, contrary to expectations (9, 10).

Depending on the location, many lesions should be considered in the differential diagnosis. Diseases, such as branchial cleft cysts, dermoid cysts, abscesses, cystic hygroma, laryngocele, lymphadenopathy, thyroglossal duct cyst, and salivary gland

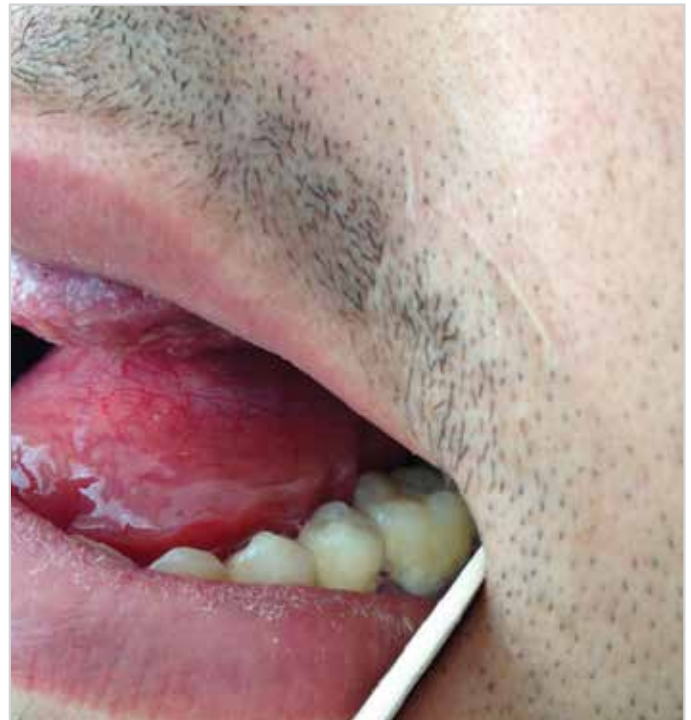

Figure 1. Appearance of the ranula in oral examination

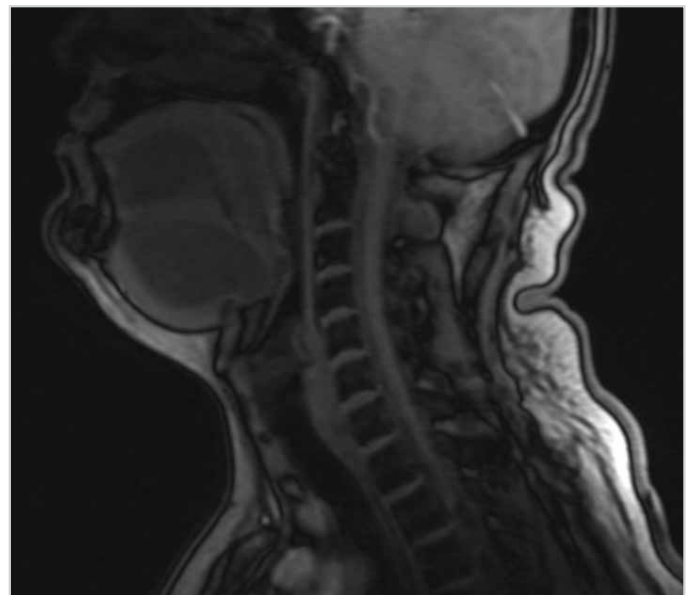


Figure 2. MRI of the ranula extending posteriorly

tumors, should be considered in the differential diagnosis. If the lesion quickly grows, deep neck infections should be considered (10).

Various surgical procedures can be used in the treatment of cervical ranula, such as simple excision, marsupialization, and excision of the ranula and sublingual gland through intraoral or cervical approaches. A relationship between the recurrence and surgical technique is evident in the literature. In patients with excised sublingual glands, the rate of recurrence was found to be <2% (11). In another study, the recurrence rates in

marsupialization, excision of ranula, and ranula excision together with sublingual gland excision were reported as 66.7%, 57.7%, and 1.2%, respectively (12).

Non-surgical treatment options have also been reported in the literature because of the high recurrence rate and possible surgical complications after an inadequate excision. These options include botulinum toxin injection and injection of OK-432 as a sclerosing agent for the biochemical denervation of the gland (12).

Conclusion

The acute presentation of cervical ranula with respiratory distress is rare. Immediate surgical intervention may be necessary in case of respiratory distress.

Informed Consent: Written informed consent was obtained from the patient who participated in this study.

Peer-review: Externally peer-reviewed.

Author Contributions: Concept - G.Ö., N.A.; Design - G.Ö.; Supervision - N.A., G.Ö.; Resources - F.N.K., F.G.; Materials - F.N.K., F.G.; Data Collection and/or Processing - F.G., H.Ö.; Analysis and/or Interpretation - G.Ö., N.A.; Literature Search - H.Ö., M.Ö.; Writing Manuscript - G.Ö.; Critical Review - G.Ö., N.A.

Conflict of Interest: No conflict of interest was declared by the authors.

Financial Disclosure: The authors declared that this study has received no financial support.

Hasta Onamı: Yazılı hasta onamı bu çalışmaya katılan hastadan alınmıştır.

Hakem Değerlendirmesi: Dış bağımsız.

Yazar Katkıları: Fikir - G.Ö., N.A.; Tasarım - G.Ö.; Denetleme - N.A., G.Ö.; Kaynaklar - F.N.K., F.G.; Gereçler - F.N.K., F.G.; Veri

Toplanması ve/veya İşlemesi - F.G., H.Ö.; Analiz ve/veya Yorum - G.Ö., N.A.; Literatür Taraması - H.Ö., M.Ö.; Yazıyı Yazan - G.Ö.; Eleştirel İnceleme - G.Ö., N.A.

Çıkar Çatışması: Yazarlar çıkar çatışması bildirmemişlerdir.

Finansal Destek: Yazarlar bu çalışma için finansal destek almadıklarını beyan etmişlerdir.

References

1. Servikal (plunging) ranula. Cengiz Özcan, Murat Ünal, Kemal Görür. Turk Arch Otolaryngol 2001; 39: 47-50.
2. Balakrishnan A, Ford GR, Bailey CM. Plunging ranula following bilateral submandibular duct transposition. J Laryngol Otol 1991; 105: 667-9. [CrossRef]
3. Matt BH, Crockett DM. Plunging ranula in an infant. Otolaryngol Head Neck Surg 1988; 99:330-3. [CrossRef]
4. Ghani NA, Ahmad R, Rahman RA, Yunus MR, Putra SP, Ramli R. A retrospective study of ranula in two centres in Malaysia. J Maxillofac Oral Surg 2000; 8: 316-9. [CrossRef]
5. Zhao Y, Jia Y, Chen X, Zhang W. Clinical review of 580 ranulas. Oral Surg Oral Med Oral Pathol Oral Radiol Endod 2004; 98: 281-7. [CrossRef]
6. Effat KG. Acute presentation of a plunging ranula causing respiratory distress: case report. J Laryngol Otol 2012; 126: 861-3. [CrossRef]
7. Gossett JD, Smith KS, Sullivan SM, Harsha BC: Sudden sublingual and submandibular swelling. J Oral Maxillofac Surg 1999; 57: 1353-6. [CrossRef]
8. McGurk M, Eyleson J, Thomas B, Harrison JD. Conservative treatment of oral ranula by excision with minimal excision of the sublingual gland: histological support for a traumatic etiology. J Oral Maxillofac Surg 2008; 66: 2050-7. [CrossRef]
9. McClatchey KD, Haley Appelblatt N, Zarbo RJ, Merrel DM. Plunging ranula. Oral Surg 1984; 57: 408-12. [CrossRef]
10. Gossett JD, Smith KS, Sullivan SM, Harsha BC. Sudden sublingual and submandibular swelling. J Oral Maxillofac Surg 1999; 57: 1353-6. [CrossRef]
11. Lida S, Kogo M, Tominaga G, Matsuya T. Plunging ranula as a complication of intraoral removal of a submandibular sialolith. Br J Oral Maxillofac Surg 2001; 39: 214-6. [CrossRef]
12. Mahadevan M, Vasan N. Management of pediatric plunging ranula. Int J Pediatr Otorhinolaryngol 2006; 70: 1049-54. [CrossRef]