

## Evaluation of bcl-2, bax and c-erbB-2 Levels in Chronic Otitis Patients with or without Cholesteatoma

### *Kolesteatomlu ve Kolesteatomsuz Kronik Otitli Hastalarda bcl-2, bax ve c-erbB-2 Düzeylerinin Değerlendirilmesi*

Özgür Işık<sup>1</sup>, Turgut Karlıdağ<sup>1</sup>, Bengü Çobanoğlu Şimşek<sup>2</sup>, Erol Keleş<sup>1</sup>, İrfan Kaygusuz<sup>1</sup>, Şinasi Yalçın<sup>1</sup>, İsrail Orhan<sup>3</sup>, Emrah Sapmaz<sup>4</sup>

<sup>1</sup>Department of Otorhinolaryngology, Fırat University Faculty of Medicine, Elazığ, Turkey

<sup>2</sup>Department of Pathology, Fırat University Faculty of Medicine, Elazığ, Turkey

<sup>3</sup>Department of Otorhinolaryngology, Kahramanmaraş Sütçü İmam Faculty of Medicine, Kahramanmaraş, Turkey

<sup>4</sup>Department of Otorhinolaryngology, Gaziosmanpaşa University Faculty of Medicine, Tokat, Turkey

Original Investigation

Özgün Araştırma

Abstract

**Objective:** The aim of this study was to evaluate bcl-2, bax, and c-erbB-2 expressions in primary and secondary acquired cholesteatoma and to indicate the role of apoptosis and accompanying increased cellular proliferation in the pathogenesis of cholesteatoma.

**Methods:** Samples obtained from the skin of the external ear canal (EEC) of patients operated for chronic otitis media (COM) without cholesteatoma constituted Group 1; samples from the EEC skin of patients in Group 3 operated for COM with cholesteatoma and from the EEC skin of patients in Group 4 constituted Group 2; samples obtained from the cholesteatoma matrix of patients operated for COM with primary acquired cholesteatoma constituted Group 3; and samples obtained from the cholesteatoma matrix of patients operated for COM with secondary acquired cholesteatoma constituted Group 4. The assessment of the positive cell ratio was based on the presence of the following findings and was semiquantitatively classified into four groups: 0, no staining; + cell staining (weak positive staining:

1%-33%); ++ cell staining (moderately positive staining: 34%-66%); and +++ cell staining (strong positive staining: 67%-100%).

**Results:** Comparison of the staining scores of bcl-2, bax, and c-erbB-2 revealed a statistically insignificant difference in the staining of samples obtained from the EEC skin ( $p>0.05$ ). Decreased bcl-2 expression and increased bax and c-erbB-2 expressions were determined in primary and secondary acquired cholesteatoma epithelium compared with the EEC skin of patients operated for COM with or without cholesteatoma, and the differences were found to be statistically significant ( $p<0.05$ ).

**Conclusion:** In acquired cholesteatoma epithelium, the finding of decreased bcl-2 expression as well as increased bax and c-erbB-2 expressions compared with the EEC skin is an indicator of the increase in both cellular proliferation and apoptosis.

**Keywords:** Cholesteatoma, apoptosis, cell proliferation, bcl-2, bax, c-erbB-2



Özet

**Amaç:** Bu çalışmanın amacı primer ve sekonder akkiz kolesteatomlardaki bcl-2, bax ve c-erbB-2 ekspresyonlarını değerlendirmek ve kolesteatom patogenezindeki hücre proliferasyonu ve apoptozisin rolünü belirlemektir.

**Yöntemler:** Kolesteatomsuz kronik otitis media (KOM) nedeniyle opere edilen hastaların dış kulak yolu cildinden (DKY) alınan örnekler grup 1; kolesteatomlu KOM nedeniyle opere edilen grup 3 ve grup 4'deki hastaların DKY cildinden alınan örnekler grup 2; primer akkiz kolesteatomlu KOM nedeniyle opere edilen hastaların kolesteatom matriksinden alınan örnekler grup 3; sekonder akkiz kolesteatomlu KOM nedeniyle opere edilen hastaların kolesteatom matriksinden alınan örnekler grup 4'ü oluşturdu. Pozitif hücrelerin oranının değerlendirilmesi belirtilen bulguların varlığı bazında yapıldı ve semikantitatif olarak dört grupta sınıflandı: 0, boyama yok; + hücre boyanması (hafif derecede boyanma: %1-33); ++ hücre boyanması (orta derecede boyanma: %34-66); +++

hücre boyanması (iyi derecede boyanma: %67-100) varlığı olarak kabul edildi.

**Bulgular:** Bcl-2, bax ve c-erbB-2 boyanma skorları karşılaştırıldığında; DKY cildinden alınan örneklerin boyanması ile grup 1 ve grup 2 arasında istatistiksel olarak anlamlı farklılık saptanmadı ( $p>0.05$ ). Primer ve sekonder akkiz kolesteatom epitelinde kolesteatomlu ve kolesteatomsuz KOM nedeniyle opere edilen hastaların DKY cildine göre bcl-2 ekspresyonunun azalmış, bax ve c-erbB-2 ekspresyonunun artmış olduğu ve bunun istatistiksel olarak anlamlı olduğu görüldü ( $p<0.05$ ).

**Sonuç:** Edinilmiş kolesteatom ile dış kulak yolu cildi karşılaştırıldığında edinilmiş kolesteatom epitelindeki bcl-2 ekspresyonunun azalması aynı zamanda bax ve c-erbB-2 ekspresyonunun artması apoptozis ve hücre proliferasyonunun arttığı bir göstergesidir

**Anahtar Kelimeler:** Kolesteatom, apoptozis, hücre proliferasyonu, bcl-2, bax, c-erbB-2

This study was presented at Fırat University Faculty of Medicine Department of Otorhinolaryngology.

Bu çalışma, Fırat Üniversitesi Tıp Fakültesi Kulak Burun Boğaz Anabilim Dalı'nda gerçekleştirildi.

Address for Correspondence/Yazışma Adresi:

Emrah Sapmaz, Gaziosmanpaşa Üniversitesi Tıp Fakültesi, Kulak Burun Boğaz Hastalıkları Anabilim Dalı, Tokat, Türkiye

Phone: +90 535 274 00 00

E-mail: emrhills@yahoo.com

Received Date/Geliş Tarihi: 18.05.2015

Accepted Date/Kabul Tarihi: 05.02.2015

© Copyright 2015 by Official Journal of the Turkish Society of Otorhinolaryngology and Head and Neck Surgery Available online at

www.turkarchotorhinolaryngol.org

© Telif Hakkı 2015 Türk Kulak Burun Boğaz ve Baş

Boyun Cerrahisi Derneği Makale metnine

www.turkarchotorhinolaryngol.org web

sayfasından ulaşılabilir.

DOI:10.5152/tao.2015.1159

## Introduction

Cholesteatoma is a benign and destructive tumor of the middle ear, characterized by the progressive accumulation of hyperproliferative epithelium with keratin (1). Irrespective of the pathogenesis, cholesteatoma is a skin-derived heterotopic squamous epithelial tissue (2).

Histopathogenesis of cholesteatoma is not yet fully understood. Invagination, hyperplasia, metaplasia, migration, proliferation, differentiation, and apoptosis of epithelial cells were suggested to play a role in pathogenesis (3-5). Various factors were evaluated in trials investigating this topic. In recent years, a special emphasis was attributed to the role of apoptosis in the pathogenesis of cholesteatoma.

Apoptosis develops through three different mechanisms such as intrinsic (bcl-2 plays a role) or extrinsic mechanisms and oxygen radicals (6). The bcl-2 family (bcl-2, bcl-xL, bax, bak, bad) is composed of a wide range of anti-apoptotic and pro-apoptotic proteins. The bcl-2 protein plays a role in the regulation of cell death and survival as well as in epithelial differentiation, morphogenesis, and tumorigenesis (7). The bax gene belongs to the bcl-2 family and induces apoptosis (8). While the cell is kept alive in a bcl-2/bax balance in favor of Bcl-2, an unbalance in favor of bax results in apoptosis (9).

C-erbB-2 (HER2) is the second member of the epidermal growth factor receptor family. C-erbB-2 protooncogene codes a transmembrane glycoprotein, which possesses tyrosine kinase activity and growth factor receptor functions (10). The activation of the erbB gene family members may stimulate cellular proliferation, cell differentiation, cessation of cell cycle, and even apoptosis (11).

The purpose of this trial was to evaluate bcl-2, bax, and c-erbB-2 expressions in primary and secondary acquired cholesteatoma and to investigate the role of apoptosis and associated cellular proliferation in the pathogenesis of cholesteatoma.

## Methods

### Study Groups

The trial was conducted in a total of 60 patients subjected to surgical operation for chronic otitis media (COM) with (n=40) and without cholesteatoma (n=20) between October 2008 and September 2009 at the Department of Otorhinolaryngology in Firat University Faculty of Medicine. Patients with an age range of 19-64 years were enrolled in the trial [35 men (58.3%) and 25 women (41.6%)]. Patients were informed regarding the trial, necessary permits were obtained, and the trial protocol was approved by the local ethics committee. Data such as age, gender, cause of referral to the hospital, duration of symptoms, presence and duration of ear discharge, as well as findings of physical examination and the type of cholesteatoma (primary or secondary acquired) were recorded for all patients. Patients previously operated in the same ear as well as cases with a systemic disease (such as diabetes

mellitus and chronic renal disease), autoimmune disease, and a known malignant disease were excluded from the trial.

Patients were classified into four groups.

**Group 1 (n=20):** Group of samples obtained from the external ear canal (EEC) skin of patients operated for COM without cholesteatoma.

**Group 2 (n=20):** Group of samples obtained from the EEC skin of patients operated for COM with cholesteatoma in Group 3 and from the EEC skin in Group 4.

**Group 3 (n=20):** Group of samples obtained from the cholesteatoma matrix in the middle ear and/or mastoid of patients operated for COM with primary acquired cholesteatoma.

**Group 4 (n=20):** Group of samples obtained from the cholesteatoma matrix in the middle ear and/or mastoid of patients operated for COM with secondary acquired cholesteatoma.

Patients in Group 2 were composed of a total of 20 cases, with 10 randomized (with systematic sampling method) patients each from Groups 3 and 4 operated for COM with cholesteatoma. Samples obtained during the operation were fixed in formalin and forwarded to the Department of Pathology for the immunohistochemical evaluation of bcl-2, bax, and c-erbB-2.

### Immunohistochemical Evaluation

Cross-sections of 4  $\mu$  were prepared for samples obtained from all groups and were placed on microscope slides coated with poly-L-lysine. As an initial step, slides were kept in an incubator at 37°C for 15 min. This was followed by staining for bcl-2 (DBS anti-bcl-2 antibody, 1 ml, clone 100/D5, 1/100), bax (Invitrogen, anti-bax antibody 1 ml, clone 2D2, 1/100), and c-erbB-2 (Invitrogen, mouse anti-HER, clone CB11) using an automated staining system (Ventana Medical System, SN: 712299, ref: 750-700, Arizona, USA). Following processing with primary antibodies, the slides were washed under running tap water and cover-slipped with Ultramount.

Immunohistochemical staining of bcl-2, bax, and c-erbB-2 was evaluated under the Olympus BX51 light microscope. The samples were scored by two independent observers without any pathological or clinical information about the cases under study. Nuclear and cytoplasmic staining for bcl-2, bax, and c-erbB-2 antibodies was assessed during the evaluation. The ratio of positive cells was semiquantitatively evaluated as follows and classified in four groups: 0, no staining; + cell staining (weak positive staining: 1%-33%); ++ cell staining (moderately positive staining: 34%-66%); and +++ cell staining (strong positive staining: 67%-100%).

### Statistical Method

The Statistical Package for the Social Sciences (SPSS) version 15 package program (2006 SPSS Inc. USA) was used

**Table 1.** Distribution and comparison of bcl-2, bax, and c-erbB-2 staining scores of patient groups

Staining scores	Group 1		Group 2		Group 3		Group 4		Total	
	n	%	n	%	n	%	n	%	n	%
<b>bcl-2</b>										
0	0	0	0	0	9	45	8	40	17	21.3
1	3	15	3	15	9	45	11	55	26	32.5
2	8	40	11	55	2	10	1	5	22	27.5
3	9	45	6	30	0	0	0	0	15	18.8
<b>bax</b>										
0	16	80	12	60	0	0	0	0	28	35
1	4	20	8	40	0	0	3	15	15	18
2	0	0	0	0	9	45	8	40	17	21.3
3	0	0	0	0	11	55	9	45	20	25.8
<b>c-erbB-2</b>										
0	10	50	13	65	0	0	0	0	23	28.8
1	8	40	5	25	4	20	6	30	23	28.8
2	2	10	2	10	11	55	13	65	28	35.0
3	0	0	0	0	5	25	1	5	6	7.5

bcl-2  $\chi^2=33.818$  ( $p<0.05$ ) (Groups 1–3, 4), ( $p<0.05$ ) (Groups 2–3, 4), ( $p>0.05$ ) (Groups 1–2 and 3–4)

bax  $\chi^2=52.793$  ( $p<0.05$ ) (Groups 1–3, 4), ( $p<0.05$ ) (Groups 2–3, 4), ( $p>0.05$ ) (Groups 1–2 and 3–4)

c-erbB-2  $\chi^2=51.209$  ( $p<0.05$ ) (Groups 1–3, 4), ( $p<0.05$ ) (Groups 2–3, 4), ( $p>0.05$ ) (Groups 1–2 and 3–4)

in this trial. Fisher's chi-square (exact chi Square) analysis was used in the inter-group comparison of bcl-2, bax, and c-erbB-2 staining scores. The level of statistical significance was accepted as 0.05.

## Results

A total of 60 patients in this study was classified into four groups based on their age: Group 1, 19–64 years (mean 27.6±9.01 years); Group 2, 23–58 years (mean 32.4±11.53 years); Group 3, 23–61 years (mean 30.5±10.55 years); and Group 4, 28–58 years (mean 30.4±12.36 years). No statistical difference was found between the groups in terms of demographic characteristics.

## Histopathological Findings

Immunohistochemical scoring was based on nuclear and cytoplasmic staining. The distribution and comparison of bcl-2, bax, and c-erbB-2 staining scores of patient groups are shown in Table 1.

In samples obtained from the EEC skin of patients in Group 1, the best staining was observed with bcl-2. Moderately positive and strong positive staining (staining scores ++ and +++) were observed in a majority of patients with bcl-2, whereas weak positive staining (staining score +) was found in a small number of patients. No staining was observed in samples obtained from the EEC skin of a majority of patients with bax and c-erbB-2 (staining score 0). In Group 2, similar to Group 1, the best staining result was obtained with bcl-2 in samples obtained from the EEC skin of patients.

In Group 3, the best staining result was attained with bax in samples obtained from the cholesteatoma epithelium of patients. With bax, moderately positive and strong positive staining was observed in a majority of patients (staining scores ++ and +++)). The second best staining result in this group was detected with c-erbB-2. In samples obtained from the cholesteatoma epithelium of a majority of patients, C-erbB-2 provided moderately positive and strong positive staining results (staining score ++ and +++)). With bcl-2, no staining was observed in approximately half of the cases (staining score 0), or weak positive and moderately positive staining was observed in a small number of samples (staining score + and ++). In samples obtained from the cholesteatoma epithelium of patients in Group 4, the staining results were similar to Group 3. The best staining results were observed with bax. Moderately positive and strong positive staining (staining scores ++ and +++) was observed with bax in a majority of patients.

Evaluation of the hematoxylin–eosin-stained cross-sections in Group 1 revealed superficial hyperkeratosis, epidermal spongiosis, and lymphocyte infiltration in the dermis as well as perivascular lymphocytes and neutrophils in two cases. In Group 2, hyperkeratosis in the superficial epithelium, spongiosis in the epidermis, and perivascular and periadnexal lymphocyte infiltration in the dermis were observed in addition to psoriasiform hyperplasia in two cases and the presence of eosinophils in inflammation areas in one case. In Groups 3 and 4, squamous epithelium, calcification and lamellar keratinization were observed, in addition to intensive inflammatory infiltration in five cases. In Group 1, assessment of the bcl-2-stained

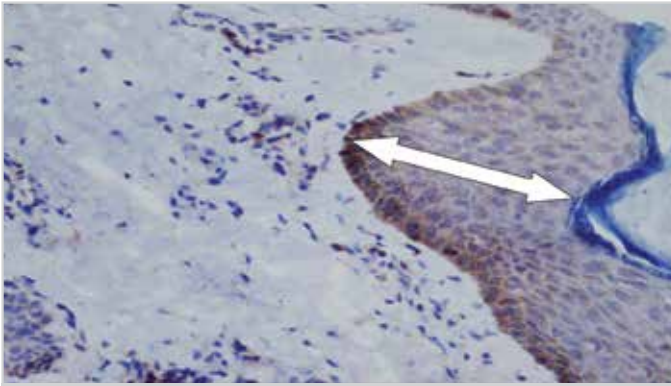


Figure 1. +++ nuclear and cytoplasmic bcl-2 staining of the external ear canal skin of the chronic otitis media group without cholesteatoma (Group 1) (white arrow) (400x)

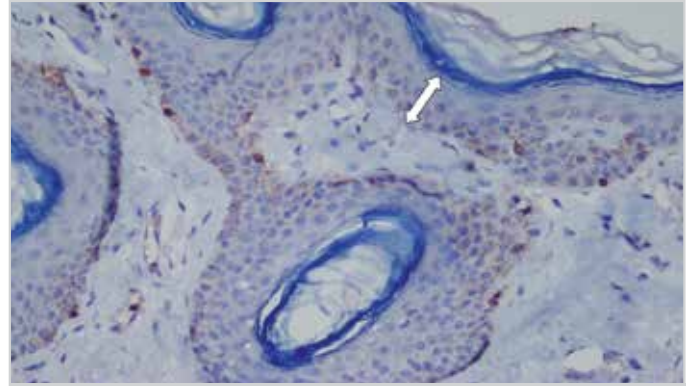


Figure 4. + nuclear and cytoplasmic bax staining in the external ear canal skin of the chronic otitis media group with cholesteatoma (Group 2) (white arrow) (400x)

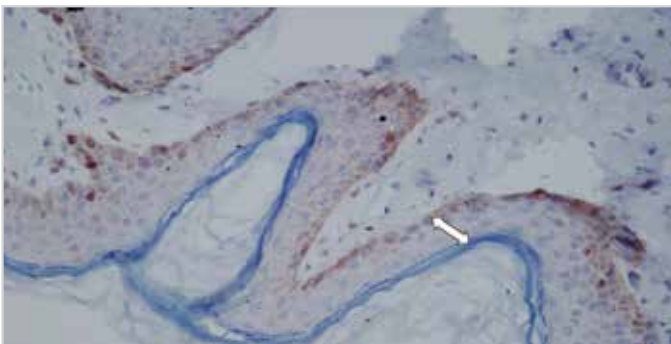


Figure 2. +++ nuclear and cytoplasmic bcl-2 staining of the external ear canal skin of the chronic otitis media group with cholesteatoma (Group 2) (white arrow) (400x) (white arrow) (400x)

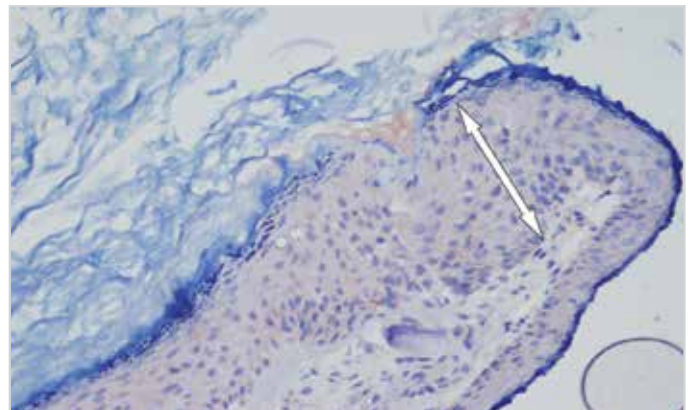


Figure 5. +++ nuclear and cytoplasmic bax staining in the primary acquired cholesteatoma group (Group 3) (white arrow) (400x)

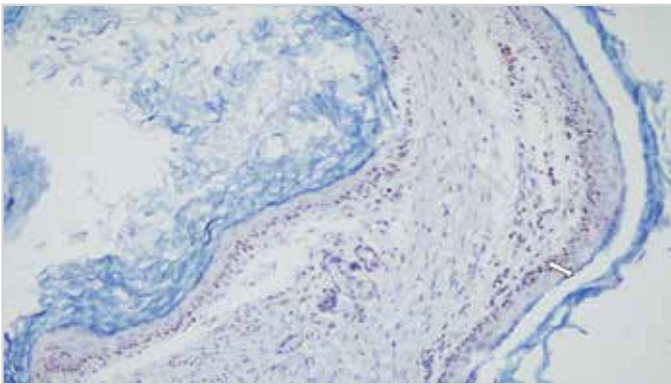


Figure 3. ++ nuclear and cytoplasmic bcl-2 staining in the secondary acquired cholesteatoma group (Group 4) (white arrow) (200x)

cross-sections revealed a more intense nuclear and cytoplasmic staining in the areas of inflammation than hematoxylin–eosin staining (Figure 1). In Group 2, diminished nuclear and cytoplasmic staining was observed in the areas of psoriasiform hyperplasia with bcl-2 (Figure 2). In Groups 3 and 4, relatively more intensive nuclear and cytoplasmic staining was found in the basal layer in addition to the evaluation of hematoxylin–eosin staining (Figure 3).

Assessment of cross-sections stained with bax revealed no staining in the EEC skin of a majority of patients in Groups 1 and 2; however, + nuclear and cytoplasmic staining was ob-

served in the basal layer and in regions surrounding the skin appendages in a few patients (Figure 4). In cholesteatoma samples of patients in Groups 3 and 4, intensive nuclear and cytoplasmic staining was found with bax in addition to hematoxylin–eosin evaluation (Figure 5). Evaluation of cross-sections stained with c-erbB-2 revealed diminished nuclear and cytoplasmic staining in the areas of increased inflammation in Groups 1 and 2 (Figure 6). In Groups 3 and 4, intensive nuclear and cytoplasmic staining was observed in addition to hematoxylin–eosin evaluation (Figure 7).

## Discussion

Compared with normal skin, increased proliferation is observed in keratinocytes in the basal and suprabasal layers of cholesteatoma (12). In cholesteatoma, the mechanism of hyperproliferation in the epidermis is not clarified yet. Various factors were explored in trials performed on this topic. Inflammatory parameters such as interleukins, growth factors such as epidermal growth factors (EGF) and transforming growth factor-alpha (TGF- $\alpha$ ), mitotic factors (Ki-67, PCNA, P27, P21, P53, active caspase 3, collagen 4), and epithelial markers (filaggrin; cytokeratin 1,13,19; BerEp4; EMA) were investigated (1, 13-17).

Yetiser et al. (15) determined that the cholesteatoma epithelium contains high levels of EGF and expresses a more invasive char-

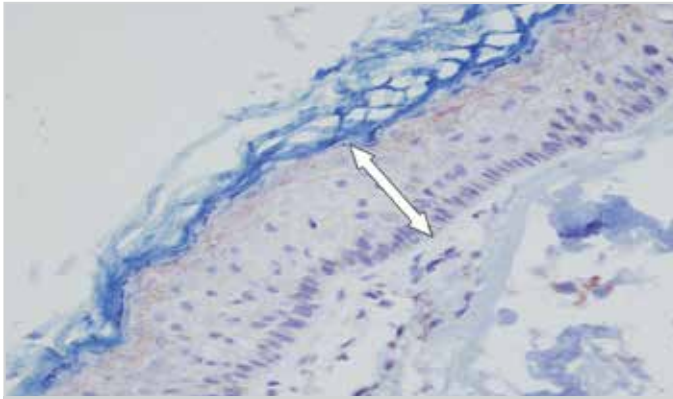


Figure 6. + nuclear and cytoplasmic c-erbB-2 staining in the external ear canal skin of the chronic otitis media group without cholesteatoma (Group 1) (white arrow) (400x)

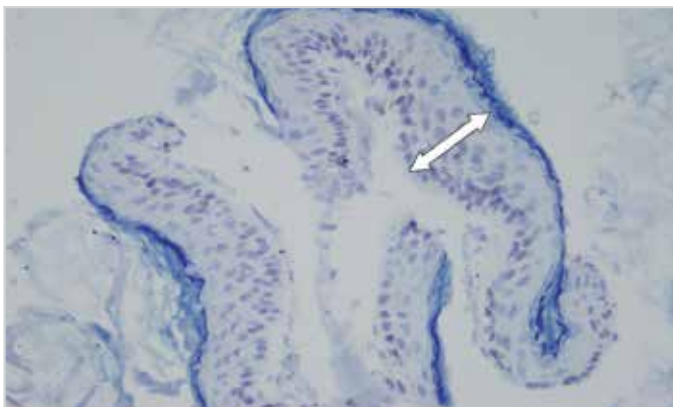


Figure 7. + nuclear and cytoplasmic c-erbB-2 staining in the primary acquired cholesteatoma group (Group 3) (white arrow) (400x)

acteristic than normal skin. In the trial performed by Sudhoff et al. (16), Ki-67 was reported to be expressed with a rate of 7% in normal EEC skin, while the corresponding rate in cholesteatoma was 17%. The rate of proliferation in the keratinocytes of cholesteatoma was found to be significantly higher than normal EEC.

In recent years, apoptosis in particular was suggested to play a role in the pathogenesis of cholesteatoma, and various views were proposed in this regard. Park et al. (18) determined that in cholesteatoma, survival is significantly increased; hence, apoptosis is suppressed in such cases. Olszewska et al. (19) investigated APO2.7, an indicator of apoptosis, in the cholesteatoma epithelium and found that the percentage of APO2.7 (+) cells is significantly high compared with normal skin, while the rates of apoptotic cells in the cholesteatoma epithelium was found to be higher than the EEC skin. In a trial conducted using the TUNEL method, the rate of apoptosis in cholesteatoma was found to be significantly higher than normal skin, and the proliferation/apoptosis ratio was reported to have a prognostic value (20). On the other hand, Miyazaki et al. (21) determined that although a keratinocyte hyperproliferation is present in cholesteatoma because of an elevation in various cytokine levels, the process of apoptosis does not demonstrate a significant difference from the EEC skin. This was suggested to cause a

high level of accumulation of keratin debris, which is the specific characteristic of middle ear cholesteatoma, thereby leading to the progression of cholesteatoma.

bcl-xL is a bcl-2-related gene that inhibits the apoptosis of tumor cells in DNA damage, as observed with the bcl-2 protein (22, 23). Kojima et al. (24) investigated the role of the bcl-xL protein on differentiation and apoptosis in the cholesteatoma epithelium and determined that apoptotic cells are mutually present in the superficial epidermal layers; however, they are not observed in the basal cells, and no difference was found between the cholesteatoma epithelium and normal EEC skin.

The activation of members of the erbB gene family leads to cellular proliferation. In addition, the activation of a erbB receptor in certain conditions may stimulate cell differentiation, cessation of the cell cycle, and even apoptosis. Lewis et al. (11) showed that the rate of apoptosis in keratinocytes is statistically insignificant, but the inhibition of c-erbB-2 decreased the rate of apoptosis. These results seem to support the correlation between c-erbB-2 expression and apoptosis. Sakamoto et al. (25) described an c-erbB-2 expression in the cholesteatoma tissue and apoptotic cells using polyclonal antibodies against single-stranded deoxyribonucleic acid (ssDNA). The cholesteatoma tissue expressed ssDNA immunoreactivity in keratinocytes in all cell layers. Comparison with retroauricular skin revealed similar immune staining patterns; however, very high levels of anti-ssDNA immunoreactivity were detected in cholesteatoma. These findings indicate that apoptosis and cellular differentiation are increased in cholesteatoma. Increased apoptosis associated with elevated c-erbB-2 levels was indicated to cause an accumulation in keratin debris and played a significant role in the pathogenesis of cholesteatoma.

To specify the role of apoptosis and related elevation in cellular proliferation in the pathogenesis of cholesteatoma, the expressions of anti-apoptotic gene bcl-2, bax from the same family with apoptotic activity, and c-erbB-2 oncogene, which has a role in cellular proliferation and apoptosis, were investigated. Upon comparison of the staining scores with bcl-2, bax, and c-erbB-2, no statistically significant difference was found in samples obtained from the EEC skin of patients operated for COM with and without cholesteatoma ( $p > 0.05$ ). Based on these results, we may indicate that the rate of apoptosis in the EEC skin of patients operated for COM with and without cholesteatoma are similar. No statistically significant difference was found between primary and secondary acquired cholesteatoma epithelium in terms of bcl-2, bax, and c-erbB-2 expressions ( $p > 0.05$ ). These results show that the rate of apoptosis does not differ in various acquired cholesteatoma epithelium.

Compared with the EEC skin of patients operated for COM with cholesteatoma, decreased bcl-2 expression and increased bax and c-erbB-2 expressions were found in primary and acquired cholesteatoma epithelium, and these values were found to be statistically significant ( $p < 0.05$ ). Decreased bcl-2 expres-

sion and increased bax and c-erbB-2 expressions indicate that the rate of apoptosis is high in primary and secondary acquired cholesteatoma epithelium as compared with the EEC skin. In addition, particularly high expression of c-erbB-2 in primary and secondary acquired cholesteatoma epithelium compared with the EEC skin is an indicator of increased proliferation in the cholesteatoma epithelium.

## Conclusion

Our results indicate that increased cellular proliferation and apoptosis may play a significant role in the pathogenesis of cholesteatoma by leading to the accumulation of keratin debris, a substance responsible for the progression of cholesteatoma. These data suggests that increased proliferation and apoptosis play a significant role in the pathogenesis of cholesteatoma. However, further trials are required to clearly identify the mechanisms involved in pathogenesis.

**Ethics Committee Approval:** Ethics committee approval was received for this study from the ethics committee of Firat University Ethics Committee.

**Informed Consent:** Written informed consent was obtained from patients who participated in this study.

**Peer-review:** Externally peer-reviewed.

**Author Contributions:** Concept - Ö.I., T.K.; Design - Ö.I., T.K.; Supervision - T.K., Ş.Y.; Data Collection and/or Processing - Ö.I., E.S., B.Ç.Ş.; Analysis and/or Interpretation - İ.O., E.K.; Literature Review - İ.K., E.K.; Writing - Ö.I., T.K.; Critical Review - Ş.Y., İ.K.

**Conflict of Interest:** No conflict of interest was declared by the authors.

**Financial Disclosure:** The authors hereby declare that the study was financed by Firat University Scientific Researches Coordination Unit.

**Etik Komite Onayı:** Bu çalışma, Firat Üniversitesi Tıp Fakültesi Etik Komitesi tarafından onaylanmıştır.

**Hasta Onamı:** Yazılı hasta onamı bu çalışmaya katılan hastalardan alınmıştır.

**Hakem Değerlendirmesi:** Dış bağımsız.

**Yazar Katkıları:** Yazar Katkıları: Fikir - Ö.I., T.K.; Tasarım - Ö.I., T.K.; Denetleme - T.K., Ş.Y.; Veri Toplanması ve/veya İşlemesi - Ö.I., E.S., B.Ç.Ş.; Analiz ve/veya Yorum - İ.O., E.K.; Literatür Taraması - İ.K., E.K.; Yazıyı Yazan - Ö.I., T.K.; Eleştirel İnceleme - Ş.Y., İ.K.

**Çıkar Çatışması:** Yazarlar çıkar çatışması bildirmemişlerdir.

**Finansal Destek:** Bu çalışma Firat Üniversitesi Bilimsel Araştırma Birimi tarafından desteklenmiştir.

## References

- Huisman MA, De Heer E, Grote JJ. Cholesteatoma epithelium is characterized by increased expression of Ki-67, p53 and p21, with minimal apoptosis. *Acta Otolaryngol* 2003; 123: 377-82.
- Jahn AF. Cholesteatoma: what is it, how did it get there, and how do we get rid of it? *Otolaryngol Clin North Am* 1989; 22: 847-57.
- Olszewska E, Wagner M, Bernal-Sprekelsen M, Ebmeyer J, Dazert S, Hildmann H, et al. Etiopathogenesis of cholesteatoma. *Eur Arch Otorhinolaryngol* 2004; 261: 6-24. [CrossRef]
- Choufani G, Roper N, Delbrouck C, Hassid S, Gabius HJ. Animal model for cholesteatoma induced in the gerbil: will the profiles of differentiation/growth-regulatory markers be similar to the clinical situation? *Laryngoscope* 2007; 117: 706-11. [CrossRef]
- Maniu A, Harabagiu O, Schrepler MP, Catana A, Fanuta A, Mogoanta CA. Molecular biology of Cholesteatoma. *Rom J Morphol Embryol* 2014; 55: 7-13.
- Chiarugi V, Magnelli L, Cinelli M. Complex interplay among apoptosis factors: RB, p53, E2F, TGF-beta, cell cycle inhibitors and the bcl2 gene family. *Pharmacol Res* 1997; 35: 257-61. [CrossRef]
- Lu QL, Poulosom R, Wong L, Hanby AM. Bcl-2 expression in adult and embryonic non-haematopoietic tissues. *J Pathol* 1993; 169: 431-7. [CrossRef]
- Oltvai ZN, Milliman CL, Korsmeyer SJ. Bcl-2 heterodimerizes in vivo with a conserved homolog, Bax, that accelerates programmed cell death. *Cell* 1993; 74: 609-19. [CrossRef]
- Marzo I, Brenner C, Zamzami N, Susin SA, Beutner G, Brdiczka D, et al. The permeability transition pore complex: a target for apoptosis regulation by caspases and bcl-2-related proteins. *J Exp Med* 1998; 187: 1261-71. [CrossRef]
- Yarden Y. Biology of HER2 and its importance in breast cancer. *Oncology* 2001; 61: 1-13. [CrossRef]
- Davina AL, Bryan Z, Steven AH, Dan FS. Inhibition of erbB receptor family members protects HaCaT keratinocytes from ultraviolet-B-induced apoptosis. *J Invest Dermatol* 2003; 120: 483-8. [CrossRef]
- Bujia J, Schilling V, Holly A, Stammberger M, Kastenbauer E. Hyperproliferation-associated keratin expression in human middle ear cholesteatoma. *Acta Otolaryngol* 1993; 113: 364-8. [CrossRef]
- Bayazit YA, Karakok M, Ucak R, Kanlikama M. Cyclin-dependent kinase inhibitor, p27 (KIP1), is associated with cholesteatoma. *Laryngoscope* 2001; 111: 1037-41. [CrossRef]
- Ergun S, Zheng X, Carlsoo B. Antigen expression of epithelial markers, collagen IV and Ki67 in middle ear cholesteatoma. An immunohistochemical study. *Acta Otolaryngol* 1994; 114: 295-302. [CrossRef]
- Yetiser S, Satar B, Aydin N. Expression of epidermal growth factor, tumor necrosis factor-alpha, and interleukin-1alpha in chronic otitis media with or without cholesteatoma. *Otol Neurotol* 2002; 23: 647-52. [CrossRef]
- Sudhoff H, Bujia J, Fisseler-Eckhoff A, Holly A, Schulz-Flake C, Hildmann H. Expression of a cell-cycle-associated nuclear antigen (MIB 1) in cholesteatoma and auditory meatal skin. *Laryngoscope* 1995; 105: 1227-31. [CrossRef]
- Caliman e Gurgel JD, Pereira SB, Alves AL, Ribeiro FQ. Hyperproliferation in ear canal epidermis. *Braz J Otorhinolaryngol* 2010; 76: 667-71.
- Park HR, Min SK, Min K, Jun SY, Seo J, Kim HJ. Increased expression of p63 and survivin in cholesteatomas. *Acta Otolaryngol* 2009; 129: 268-72. [CrossRef]
- Olszewska E, Chodynicky S, Chyczewski L. Apoptosis in the pathogenesis of cholesteatoma in adults. *Eur Arch Otorhinolaryngol* 2006; 263: 409-13. [CrossRef]
- Ergun S, Carlsoo B, Zheng X. Apoptosis in meatal skin, cholesteatoma and squamous cell carcinoma of the ear. *Clin Otolaryngol Allied Sci* 1999; 24: 280-5. [CrossRef]

21. Miyazaki H, Kojima H, Tanaka Y, Shiwa M, Koga T, Moriyama H. Terminal differentiation of epithelial cells in middle ear cholesteatoma: investigation of patterns of expression of protein kinase C-delta and protein kinase C-eta. *Laryngoscope* 1999; 109: 1785-92. [\[CrossRef\]](#)
22. Datta R, Manome Y, Taneja N, Boise LH, Weichselbaum R, Thompson CB, et al. Overexpression of Bcl-XL by cytotoxic drug exposure confers resistance to ionizing radiation-induced internucleosomal DNA fragmentation. *Cell Growth Differ* 1995; 6: 363-70.
23. Kojima H, Endo K, Moriyama H, Tanaka Y, Alnemri ES, Slapak CA, et al. Abrogation of mitochondrial cytochrome c release and caspase-3 activation in acquired multidrug resistance. *J Biol Chem* 1998; 273: 16647-50. [\[CrossRef\]](#)
24. Kojima H, Miyazaki H, Tanaka Y, Shiwa M, Koga T, Moriyama H. Role of Bcl-xL protein in differentiation and apoptosis of human middle ear cholesteatoma epithelium. *Arch Otolaryngol Head Neck Surg* 1999; 125: 738-42. [\[CrossRef\]](#)
25. Sakamoto T, Kondo K, Yamasoba T, Suzuki M, Sugasawa M, Kaga K. Overexpression of ErbB-2 protein in human middle ear cholesteatomas. *Laryngoscope* 2004; 114: 1988-91. [\[CrossRef\]](#)