

Infectious and Noninfectious Causes of Epiglottitis in Adults, Review of 24 Patients

Erişkinlerde Enfeksiyöz ve Enfeksiyöz Olmayan Epiglottit Sebepleri, 24 Hastanın Gözden Geçirilmesi

Original Investigation
Özgün Araştırma

İsrafil Orhan¹, Salih Aydın², Turgut Karlıdağ³

¹Department of Otolaryngology, Sütçü İmam University Faculty of Medicine, Kahramanmaraş, Turkey

²Clinic of Otolaryngology, Bağcılar Training and Research Hospital, İstanbul, Turkey

³Department of Otorhinolaryngology, Fırat University Faculty of Medicine, Elazığ, Turkey

Abstract

Objective: The present study reports the etiological differences, clinical features, management, and patient outcomes between infectious and noninfectious causes of epiglottitis in adult patients.

Methods: The medical records of 24 patients with infectious and noninfectious epiglottitis were investigated. Diagnosis was made by anamnesis and endoscopic examination. On admission, respiratory distress of patients was classified according to Freidman's classification.

Results: Fifteen patients were male, and nine patients were female. Their ages ranged between 24 and 69 years of age (mean, 43.4±11.6). In total, 16 patients were diagnosed with infectious epiglottitis, and eight patients were diagnosed with noninfectious epiglottitis. Of patients with noninfectious epiglottitis, two had angioedema, two had experienced organophosphate ingestion,

one had experienced hot water aspiration, one had experienced hot milk aspiration, one had experienced foreign body aspiration (fishbone), and one had epiglottitis due to Behçet's disease. Sore throat was the most common symptoms of infectious and noninfectious epiglottitis in our patients. Odynophagia was the second most common symptom of infectious epiglottitis, and muffled voice was the second most common symptom in non-infectious patients.

Conclusion: Epiglottit is an emergency situation; when a patient is diagnosed with epiglottitis, close follow-up should be performed, and airway support should properly be maintained according to the degree of respiratory distress. Tracheostomy should be performed without hesitation, as needed.

Keywords: Epiglottitis, adult, etiology, diagnosis

Özet

Amaç: Bu çalışmanın amacı erişkinlerde enfeksiyöz ve enfeksiyöz olmayan epiglottitlerin etyolojisini, klinik bulgularını, hasta şikayetlerini değerlendirmektir.

Yöntemler: Enfeksiyöz ve enfeksiyöz olmayan epiglottit tanısı olan 24 hastanın kayıtları üçüncü basamak sağlık merkezinde retrospektif olarak araştırıldı. Hastaların tanıları anamnez ve endoskopik görüntüleme ile konuldu. Başvuru sırasındaki solunum sıkıntısını değerlendirmek için Freidman sınıflaması kullanıldı.

Bulgular: Hastalardan 15'i erkek, 9'u kadın idi. Hastaların yaş ortalaması 43.4±11.6 yıl (24-69) idi. Hastaların 16'sında enfeksiyöz, 8'inde enfeksiyöz olmayan epiglottit vardı. Enfeksiyöz olmayan epiglottit sebepleri; 2 hastada anjiyödem, 2 hastada organofosfat maruziyeti, 1

hastada sıcak su maruziyeti, 1 hastada sıcak süt maruziyeti, 1 hastada yabancı cisim (balık kılıcı), 1 hastada Behçet hastalığı idi. Boğaz ağrısı enfeksiyöz ve enfeksiyöz olmayan epiglottitlerde en sık şikayet idi. Enfeksiyöz epiglottitlerde odinofaji ikinci en sık şikayet iken, enfeksiyöz olmayan epiglottitlerde boğuk ses ikinci en sık şikayet idi.

Sonuç: Epiglottit acil bir durumdur. Epiglottit tanısı alan hastalar solunum sıkıntısı açısından yakın takip edilmeli ve gerekli durumlarda havayolunu sağlamak için müdahale edilmelidir. Gerekli durumlarda tereddüt etmeden trakeostomi açılmalıdır.

Anahtar Kelimeler: Epiglottit, erişkin, etiyoloji, tanı

Introduction

Acute epiglottitis is a local inflammation of the supraglottic structures and affects mainly the epiglottis (1). Although epiglottitis is common in childhood, it has been recognized that its frequen-

cy has increased in adults in recent years. The upper airway is more rigid and wider in adults than in pediatric patients, so that adults have a lower risk of upper airway obstruction. However, the reported mortality rate is 18%-21% (2, 3). In adults,



Address for Correspondence/Yazışma Adresi:

İsrafil Orhan, Sütçü İmam Üniversitesi, Kulak Burun Boğaz Hastalıkları Anabilim Dalı, Kahramanmaraş, Türkiye

Phone: +90 532 777 65 84

E-mail: israfil.orhan@gmail.com

Received Date/Geliş Tarihi: 19.08.2014

Accepted Date/Kabul Tarihi: 22.12.2014

© Copyright 2015 by Official Journal of the Turkish Society of Otorhinolaryngology and Head and Neck Surgery Available online at www.turkarchotorhinolaryngol.org
© Telif Hakkı 2015 Türk Kulak Burun Boğaz ve Baş Boyun Cerrahisi Derneği Makale metnine www.turkarchotorhinolaryngol.org web sayfasından ulaşılabilir.
DOI:10.5152/tao.2015.718

epiglottitis can easily be overlooked due to its equivocal initial symptoms and rarity. Therefore, it can sometimes be life-threatening and lead rapidly to upper airway obstruction.

The most common symptoms of acute epiglottitis in adults are odynophagia, difficulty in swallowing secretions, increased oral saliva, sore throat, dyspnea, muffled voice, and stridor (2-4). Although epiglottitis is mainly caused by bacterial infections, noninfectious agents such as viral, caustic, and thermal injuries can also be causes (5-7). Diagnosis is best made by examination using direct, indirect, or flexible laryngoscopy (3).

In this study, 24 patients having infectious and noninfectious epiglottitis were analyzed to establish their diagnostic, therapeutic differences, and emergency situation.

Methods

Ethical board approval was received from Medipol University Hospital (number:10840098-08). Informed consent was taken from the patient. The study included 24 adult patients who were admitted to our outpatient clinics over a 4-year period with the complaints of sore throat, dysphagia, and respiratory distress. Of these, 16 patients were diagnosed as having infectious epiglottitis and eight patients as having noninfectious epiglottitis. Diagnosis was made by anamnesis and endoscopic examination. On admission, respiratory distress of patients was classified according to Friedman's classification (Table 1) (8).

Statistical Analysis

Mean, standard deviation, median, min-max, ratio, frequency values were used in the descriptive statistics of the data in this study. The SPSS 20.0 (IBM, Chicago, USA) program was used in the analysis.

Results

Fifteen patients were male, and nine patients were female. The mean age was 43.4±11.6 year (24-69 years). Patients' age, gender, complaints on admission, etiologic factors, and Friedman's stage according to the respiratory distress are summarized in Tables 2 and 3. In total, 16 patients were diagnosed with infectious epiglottitis (Figure 1), and eight patients were diagnosed with noninfectious epiglottitis. Causes of noninfectious epiglottitis were angioedema in two patients (Figure 2), organophosphate ingestion in two patients (Figure 3), hot water aspiration in one patient (Figure 4), hot milk aspiration in one patient, foreign body aspiration (fishbone) in one patient, and Behçet's disease in one patient.

The main presenting symptoms in all patients were sore throat (79%) and odynophagia (62.5%). The main presenting symptoms in patients with infectious epiglottitis were sore throat (93.7%) and odynophagia (81.2%), while dyspnea was common in epiglottitis caused by angioedema, and muffled voice and sore throat were common in epiglottitis due to thermal and caustic injury. Respiratory distress did not occur in patients with epiglottitis due to Behçet's disease, but odynophagia was the most prominent symptom. Fever was a significant symptom (62%)

Table 1. Friedman classification of acute epiglottitis in adults

Clinical stage	
Stage I	No respiratory complaints, respiratory rate less than 20
Stage II	Subjective respiratory complaint, respiratory rate greater than 20
Stage III	Moderate respiratory distress, stridor, retractions, perioral cyanosis, respiratory rate greater than 30
Stage IV	Severe respiratory distress, stridor, retractions, cyanoses, delirium, decreased consciousness, respiratory arrest

Table 2. Clinical characteristics of 16 patients with infectious epiglottitis

Patient	Age	Sex	Symptoms	Friedman classification	Etiology
1	32	M	Sore throat, odynophagia, dyspnea	3	Infectious
2	44	M	Sore throat, odynophagia, dyspnea	3	Infectious
3	24	M	Sore throat, odynophagia, dyspnea	3	Infectious
4	37	M	Sore throat, odynophagia, dyspnea	4	Infectious
5	56	M	Sore throat, odynophagia	2	Infectious
6	30	M	Sore throat, odynophagia	1	Infectious
7	47	F	Sore throat, odynophagia, dyspnea	3	Infectious
8	39	M	Sore throat, odynophagia, dyspnea	3	Infectious
9	62	F	Dyspnea, stridor	3	Infectious
10	59	M	Sore throat, dyspnea	3	Infectious
11	41	M	Sore throat, odynophagia, dyspnea	2	Infectious
12	25	F	Sore throat, odynophagia	2	Infectious
13	49	M	Sore throat, odynophagia	2	Infectious
14	52	M	Sore throat, dyspnea	3	Infectious
15	53	F	Sore throat, odynophagia	1	Infectious
16	43	M	Sore throat, odynophagia, dyspnea	3	Infectious

M: male; F: female

of infectious epiglottitis but was not seen in noninfectious epiglottitis.

Two patients with infectious epiglottitis had concurrent tonsillitis. One had an epiglottic abscess due to aspiration of a foreign body (fishbone). Bacteriological cultures were taken from five patients, but *Streptococcus pneumoniae* growth was observed only in one patient with tonsillitis. Stages of infectious epiglottitis, according to Friedman, are summarized in Table 2. One patient with stage 4 epiglottitis underwent unsuccessful endotracheal intubation, and a tracheotomy was subsequently performed.

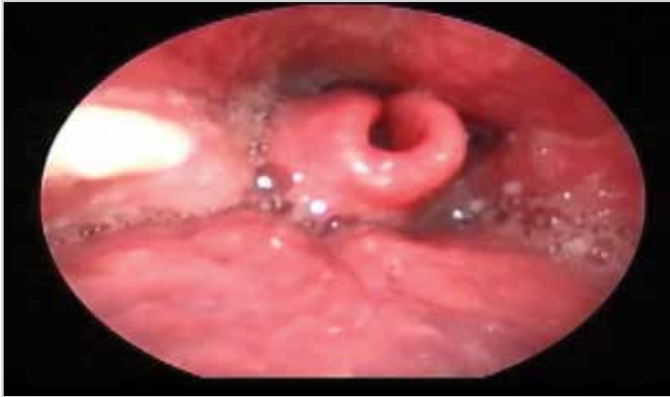

Figure 1. Fiberoptic appearance of the infected epiglottis

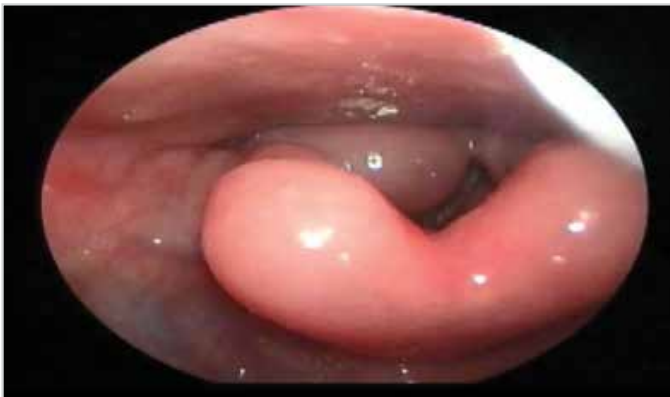


Figure 2. Epiglottitis due to angioedema associated with enalapril

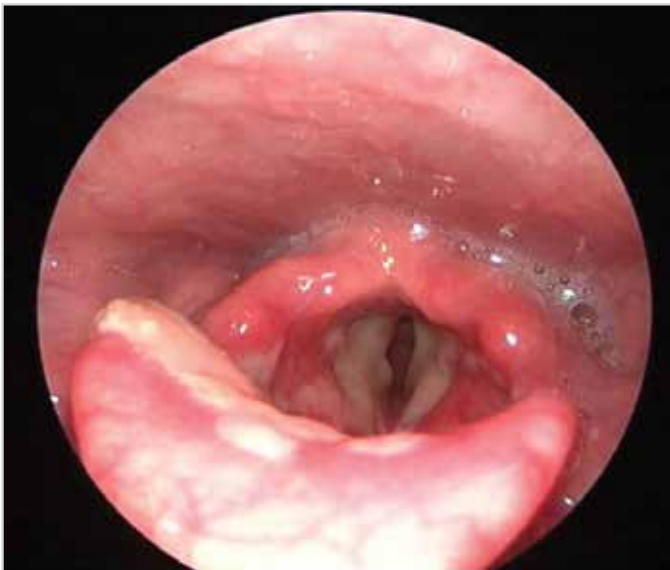

Figure 3. Fiberoptic appearance of epiglottic chemical injury after organophosphate ingestion

A patient with an epiglottic abscess underwent an immediate tracheotomy, and the abscess was drained at the same time.

Endotracheal intubation was not performed for epiglottitis following thermal and caustic injuries, but one of two patients with epiglottitis due to angioedema required intubation. No prominent respiratory distress was observed in patients with Behçet's

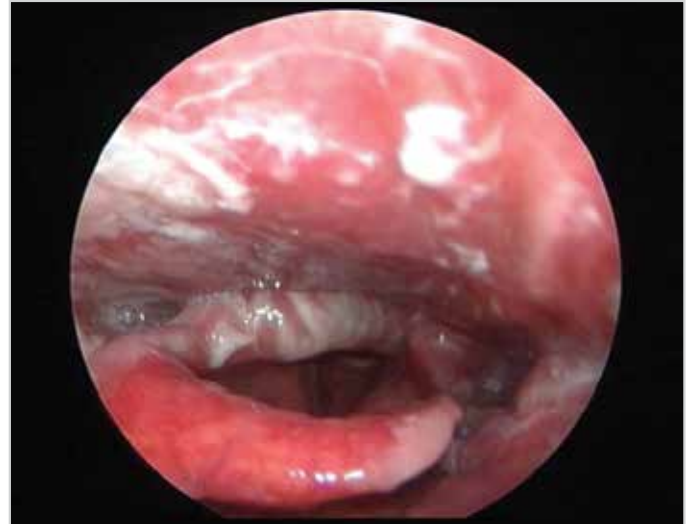

Figure 4. Fiberoptic appearance of epiglottic thermal burn in an adult following hot water aspiration

Table 3. Clinical characteristics of eight patients with noninfectious epiglottitis

Patient	Age	Sex	Symptoms	Friedman classification	Etiology
1	69	F	Dyspnea, stridor	4	Angioedema (ACE inhibitor)
2	49	M	Dyspnea	3	Angioedema (ACE inhibitor)
3	38	F	Dyspnea	2	Organophosphate ingestion
4	25	F	Dyspnea	2	Organophosphate ingestion
5	43	M	Hoarseness, sore throat	2	Hot water aspiration
6	52	F	Sore throat, hoarseness, dyspnea	3	Hot milk aspiration
7	40	F	Sore throat, odynophagia	1	Behçet's disease
8	34	M	Sore throat, odynophagia, dyspnea	4	Foreign body

M: male; F: female

disease. Antibiotic treatment, including cefotaxime and metronidazole, was the main therapy for infectious epiglottitis, while steroid treatment was commonly applied for noninfectious epiglottitis.

Discussion

Acute epiglottitis is a life-threatening condition characterized by inflammation, primarily, of the epiglottis and other supraglottic laryngeal structures, and such clinical cases require urgent intervention (9, 10). Although it is common in children between the age of 2 and 5 years, it can also be seen in adults.

In adults, it is common in males between the age of 30 and 70 years (11). Epidemiological studies have shown that the number of acute epiglottitis cases has decreased in children due to proper vaccinations, while the number of adult cases has increased significantly (11, 12).

Although adult epiglottitis is usually bacterial, some cases have been reported in which no pathogen could be isolated; therefore, viral agents have been suspected in their etiology (5). Unlike the case of the pediatric age group, the causative microbiological agent in adults is not easily identified, and the seasonal differences in the incidence of infection in adults are not as pronounced as they are in children (11). In our study, bacterial cultures were only taken from five patients, and one patient showed *S. pneumoniae* growth.

The existing literature indicates that noninfectious causes such as thermal and caustic injuries, autoimmune diseases, epiglottic ulcers, and angioedema are implicated in the etiology of epiglottitis (6, 7, 13-15). In our study, although 16 patients had the infectious cause of epiglottitis, eight patients had noninfectious causes. Among noninfectious epiglottitis cases, two patients had angioedema, two had experienced organophosphate ingestion, one had experienced hot water aspiration, one had experienced hot milk aspiration, one had experienced foreign body aspiration (fishbone), and one had epiglottitis due to Behçet's disease.

The most common symptoms of epiglottitis in adults are odynophagia, sore throat, respiratory distress, dysphagia, hoarseness, muffled voice, and fever (2, 3, 9). Sore throat was the most common symptoms of infectious and noninfectious epiglottitis in our patients. Odynophagia was the second most common symptom in infectious patients, and muffled voice was the second most common symptom in noninfectious patients. Fever was not a significant sign in patients with noninfectious epiglottitis, although it was found in 10 patients with infectious epiglottitis. Leucocytosis was not observed in noninfectious epiglottitis, although it was found in four patients with infectious epiglottitis.

In children, acute epiglottitis symptoms progress within hours, whereas progression takes days in adults (3). The risk of upper airway obstruction is higher in children due to the narrowness of their airways and their more reactive lymphoid tissue in their supraglottic areas (1). In our patients, the symptoms of acute epiglottitis appeared within 5 hours to 2 days, whereas symptoms appeared within minutes in noninfectious epiglottitis.

Acute epiglottitis is best diagnosed by indirect, direct, or flexible laryngoscopic examination. Particularly, in children, indirect laryngoscopy can induce laryngeal spasm and acute respiratory distress. However, in adults, the most appropriate diagnostic tool is flexible laryngoscopy due to the advantages of the wideness of the adult upper airway, adult patient's tolerance of the examination, the lack of requirement for anesthesia, and the ability of naked eye examination of supraglottic and epiglottic edema.

Laryngoscopic examination can safely be performed in adults, unlike children (2, 3, 12).

Another diagnostic examination is the lateral radiograph taken with a soft tissue dose for acute epiglottitis. The lateral radiograph shows a typical thumb sign that is characterized by swelling of the epiglottis and/or other supraglottic structures (16, 17). However, it gives false-positive and false-negative results. Wong and Berkowitz (16) reported that the thumb sign had a 16% probability of being a false-negative result. Chan et al. (18) reported that the thumb sign was observed in 65% of 32 adult patients. In our study, none of our patients underwent lateral radiography. In patients suffering from respiratory distress, a safer method of flexible laryngoscopy was preferred to conserve time. Congested epiglottitis was the most prominent sign in infectious epiglottitis. However, in noninfectious epiglottitis caused by angioedema, no saliva accumulation and erythematous mucosa were observed; only edema of the supraglottic structures was observed. In epiglottitis caused by thermal or caustic injury, besides the edema of the epiglottis, ulcerative lesions on the vocal cords and pharynx due to thermal or chemical burns were prominent on larynx examination. In Behçet's disease, the main laryngoscopic finding was epiglottic ulcer and edema.

The mainstay of the treatment of epiglottitis is to maintain an open airway and to provide medical therapy. First, an intravenous line should be established, and the patient should be monitored to assess oxygen saturation, cardiac, and vital findings. The most important step in this treatment is to maintain the airway (3, 4, 12). Therefore, two of our patients underwent tracheostomy, and one patient was intubated. Etiology has an important role in medical treatment. Steroid treatment was given when the patient was first admitted to the hospital. None of our patients had serious respiratory distress; therefore, cefotaxime and metronidazole were started, and the maintenance dose of steroids was not applied. On the other hand, noninfectious epiglottitis did not require antibiotic therapy, and steroid treatment was applied as an essential treatment option.

Conclusion

Adult epiglottitis differs from childhood epiglottitis, both clinically and etiologically. In patients suspected of acute epiglottitis, examining the larynx is essential after taking control of respiratory distress, rather than taking lateral radiographs.

Once the patient is diagnosed with epiglottitis, close follow-up should be performed, and airway support should properly be maintained according to the degree of respiratory distress. Tracheostomy should be performed without hesitation, as needed.

Ethics Committee Approval: Ethics committee approval was received for this study from Medipol University Hospital (10840098-08).

Informed Consent: Written informed consent was obtained from the patients who participated in this study.

Peer-review: Externally peer-reviewed.

Author Contributions: Concept - İ.O., T.K.; Design - İ.O.; Supervision - S.A.; Funding - S.A., İ.O.; Materials - S.A., İ.O.; Data Collection and/or Processing - S.A., İ.O.; Analysis and/or Interpretation - S.A., T.K.; Literature Review - S.A., İ.O.; Writing - İ.O.; Critical Review - T.K.

Conflict of Interest: No conflict of interest was declared by the authors.

Financial Disclosure: The authors declared that this study has received no financial support.

Etik Komite Onayı: Bu çalışma için etik komite onayı Medipol Üniversitesi Hastanesi'nden alınmıştır (10840098-08).

Hasta Onamı: Yazılı hasta onamı bu çalışmaya katılan hastalardan alınmıştır.

Hakem Değerlendirmesi: Dış bağımsız.

Yazar Katkıları: Fikir - İ.O., T.K.; Tasarım - İ.O.; Denetleme - S.A.; Veri Toplanması ve/veya İşlemesi - S.A., İ.O.; Kaynaklar - S.A., İ.O.; Malzemeler - S.A., İ.O.; Analiz ve/veya Yorum - S.A., T.K.; Literatür Taraması - S.A., İ.O.; Yazıyı Yazan - İ.O.; Eleştirel İnceleme - T.K.

Çıkar Çatışması: Yazarlar çıkar çatışması bildirmemişlerdir.

Finansal Destek: Yazarlar bu çalışma için finansal destek almadıklarını beyan etmişlerdir.

References

1. Briem B, Thorvardsson O, Petersen H. Acute epiglottitis in Iceland 1983-2005. *Auris Nasus Larynx* 2009; 36: 46-52. [\[CrossRef\]](#)
2. Berger G, Landau T, Berger S, Finkelstein Y, Bernheim J, Ophir D. There is ingincidence of adult acute epiglottitis and epiglottic abscess. *Am J Otolaryngol* 2003; 24: 374-83. [\[CrossRef\]](#)
3. Al-Qudah M, Shetty S, Alomari M, Alqdah M. Acute adult supraglottitis: current management and treatment. *South Med J* 2010; 103: 800-4. [\[CrossRef\]](#)
4. Hafidh MA, Sheahan P, Keogh I, Walsh RM. Acute epiglottitis in adults: a recent experience with 10 cases. *J Laryngol Otol* 2006; 120: 310-3. [\[CrossRef\]](#)
5. Lotfzadeh A, Chhetri DK. Viral supraglottitis in an adult. *Ear Nose Throat J* 2009; 88: 768-70.
6. Alpay HC, Kaygusuz I, Karlidag T, Orhan I. Thermal burn of the larynx in an adult following hot water aspiration. *Otolaryngol Head Neck Surg* 2008; 139: 164-5. [\[CrossRef\]](#)
7. Alpay HC, Keles E, Orhan I, S. Yalcin. Chemical injury of larynx after organophosphate ingestion. *Otolaryngol Head Neck Surg* 2009; 140: 604-5. [\[CrossRef\]](#)
8. Friedman M, Toriumi DM, Grybauskas V, Applebaum EL. Epiglottitis in the adults. A proposition for a clinical classification and therapeutic strategy. *Ann Otolaryngol Chir Cervicofac* 1989; 106: 306-9.
9. Guldred LA, Lyhne D, Becker BC. Acute epiglottitis: epidemiology, clinical presentation, management and outcome. *J Laryngol Otol* 2008; 122: 818-23. [\[CrossRef\]](#)
10. Isakson M, Hugosson S. Acute epiglottitis: epidemiology and Streptococcus pneumoniae serotype distribution in adults. *J Laryngol Otol* 2011; 125: 390-3. [\[CrossRef\]](#)
11. Frantz TD, Rasgon BM, Quesenberry CP Jr. Acute epiglottitis in adults. Analysis of 129 cases. *JAMA* 1994; 272: 1358-60. [\[CrossRef\]](#)
12. Katori H, Tsukuda M. Acute epiglottitis: analysis of factors associated with airway intervention. *J Laryngol Otol* 2005; 119: 967-72. [\[CrossRef\]](#)
13. Goto R, Miyabe K, Mori N. Thermal burn of the pharynx and larynx after swallowing hot milk. *Auris Nasus Larynx* 2002; 29: 301-3. [\[CrossRef\]](#)
14. Orhan I, Yilmaz F, Eken M. Laryngeal ulceration in Behcet's Disease. *Int J Phonosurg Laryngol* 2012; 2: 49-51. [\[CrossRef\]](#)
15. Tsunoda K, Hozaki F, Aikawa J. Angioedema for the epiglottitis associated with enalapril. *Laryngoscope* 2000; 110: 2147-8. [\[CrossRef\]](#)
16. Wong EY, Berkowitz RG. Acute epiglottitis in adults: the Royal Melbourne Hospital experience. *ANZ J Surg* 2001; 71: 740-3. [\[CrossRef\]](#)
17. Rizk SS, Kacker A, Komisar A. Need for tracheotomy is rare in patients with acute supraglottitis: Findings of a retrospective study. *Ear Nose Throat J* 2000; 79: 952-7.
18. Chan KO, Pang YT, Tan KK. Acute epiglottitis in the tropics: is it an adult disease? *J Laryngol Otol* 2001; 115: 715-8. [\[CrossRef\]](#)