

Dermoid Cyst Arising from the Epiglottis

Case Report ▶

Çağatay Han Ülkü, Hilal Yücel

Department of Otorhinolaryngology, Necmettin Erbakan University Meram Faculty of Medicine, Konya, Turkey

Abstract ▶

Dermoid cysts arising from the head and neck region are rare, slow-growing, and well-circumscribed neoplasms. Symptoms are non-specific and usually related to the size and the location of the lesion. A dermoid cyst of the epiglottis is extremely rare. To the best of our knowledge, only one case has been previously reported in the English literature. In this study, a case of a der-

moid cyst arising from the epiglottis was presented as an extremely rare clinical condition. The characteristics, differential diagnosis, and treatment of the disease are summarized.

Keywords: Dermoid cyst, epiglottis, head-neck, treatment

Introduction

A dermoid cyst is a rare, benign, and developmental tumor. It primarily occurs in the gonads. Moreover, it can display localization near the midline in any region of the body (1, 2). The head and neck region is an occasional area for the development of this tumor (3). It is a slow-growing and painless lesion. It can occur at any age, but it is more common among young adults (1). To the best of our knowledge, in English literature, the first and only dermoid cyst case originating from the epiglottis was reported by McKenzie in 1930 (4). In Russian literature, a total of three cases were presented in two studies published in 1980 and 1991 (5, 6).

In this study, a case of a dermoid cyst arising from the epiglottis is presented because it is an extremely rare clinical condition and the characteristics, differential diagnosis, and treatment of the cyst are summarized.

Case Report

A 41-year-old male patient presented to our clinic with complaints of muffled voice and difficulty in swallowing lasting for one year. An endoscopic examination of his larynx revealed a smooth-surfaced mass of 3.0×2.0 cm, arising from the left upper margin of the epiglottis and extending to the left sinus piriformis. The patient had no apparent respiratory distress. The results of other ear–nose–throat and system examinations were normal. His medical history did not include any important feature. In magnetic resonance imaging (MRI), a 3.0×2.0-cm soft tissue mass located in the left upper outer margin of the epiglottis and extending to the left sinus piriformis and vallecula was observed (Figure 1, 2). Complete

surgical excision was planned for the final diagnosis and treatment. The patient was informed about the surgical procedure, and his written informed consent was obtained. The patient was operated under general anesthesia. The mass with a wide base in the left upper outer margin of the epiglottis was revealed using an automatic mouth gag with the endoscope-assisted transoral approach. Complete surgical excision was performed using a plasma blade (PEAK Plasma Blade Surgery System) Plasma Blade Surgery System, PEAK Surgical Inc., Palo Alto, CA, USA (Figure 3a-d). Histopathological diagnosis reported a dermoid cyst (Figure 4a, b). The postoperative period was uneventful. In the last control examination conducted 6 months after the operation, laryngeal structures were normal, and the patient was asymptomatic. The patient is still routinely followed-up.

Discussion

Dermoid cysts, which are developmental anomalies, are also called dysontogenetic cysts. They originate from some epithelial cell residues occurring during the midline fusion of the first and second branchial arches in the 3rd and 4th week of embryologic life. In addition, it has been specified in literature that they can be acquired as a result of traumatic or iatrogenic implantation (1).

These lesions can be divided into three histopathological subgroups. A real dermoid cyst is a cyst bound by stratified squamous epithelium and also involves additional skin-related structures such as hair, hair follicle, and sebaceous and sweat glands. Its components have an ectodermal and mesodermal origin. An epidermoid cyst or epidermal inclusion cyst is an ectodermal lesion bound by



This study was presented as a poster at the 35th National Otorhinolaryngology-Head and Neck Surgery, 2-6 November, Antalya, Turkey.

Address for Correspondence:
 Çağatay Han Ülkü, Necmettin Erbakan Üniversitesi
 Meram Tıp Fakültesi, Kulak Burun Boğaz
 Hastalıkları Anabilim Dalı, Konya, Turkey
Phone: +90 532 317 17 65
E-mail: chanulku@yahoo.com
Received Date: 23.06.2014
Accepted Date: 12.08.2014
Available Online Date/Çevrimiçi Yayın Tarihi:
 14.11.2014

© Copyright 2015 by Official Journal of the Turkish Society of Otorhinolaryngology and Head and Neck Surgery Available online at www.turkarchotorhinolaryngol.org
 © Telif Hakkı 2015 Türk Kulak Burun Boğaz ve Baş Boyun Cerrahisi Derneği Makale metnine www.turkarchotorhinolaryngol.org web sayfasından ulaşılabilir.
 DOI:10.5152/tao.2014.664

simple squamous epithelium and does not include an additional structure. On the other hand, a teratoid cyst is bound by various epithelial structures including stratified squamous and ciliated respiratory epithelium, and it involves components with ectodermal, endodermal, and/or mesodermal origin (1).

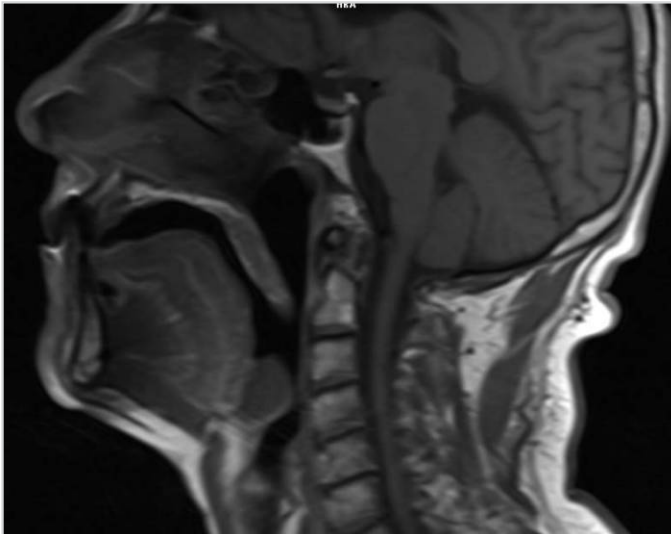


Figure 1. In the section of pre-contrast sagittal T1-weighted MRI, a mass originating from the epiglottis, which causes airway obstruction, is observed.

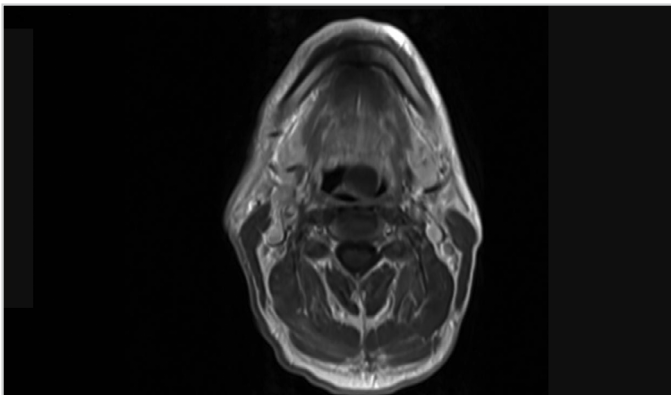


Figure 2. In the section of post-contrast axial T1-weighted MRI, a mass originating from the left margin of the epiglottis is observed

Dermoid cysts can occur in any region of the body (2). Of all dermoid cysts, 6.9% develop in the head and neck region and 1.6% develop in the oral cavity (3). In the head and neck region, it mostly occurs in the 1/3 lateral of the eyebrow and the orbit and nasal cavity follow it (1, 2). Within our knowledge, only four cases of dermoid cysts originating from the epiglottis have been reported (one in English literature and three in Russian literature) (4-6).

Dermoid cysts generally appear as slow-growing, painless, and doughy swellings. They equally occur in both sexes, frequently between the ages of 20 and 30 years (7). Symptoms are not specific, and they differ depending on the anatomic regions where they develop (8, 9). In addition, a dermoid cyst may not present with a clinical sign before reaching a certain size or putting pressure on vital structures. A dermoid cyst that develops in the epiglottis can cause dyspnea, dysphonia, and airway obstruction. In the case reported, muffled voice and difficulty in swallowing were the most remarkable symptoms. An apparent respiratory distress was not observed.

In dermoid cysts, fine-needle aspiration biopsy (FNAB) is often insufficient and gives unsteady or non-diagnostic results (7). In the case presented in this study, FNAB was not performed because of the deep localization of the lesion and the abovementioned reasons.

In the preoperative period, MRI and/or computed tomography is very significant for revealing the nature of the lesion, its structural features, place of localization, and adjacencies. In this way, it is possible to establish an accurate diagnosis and to determine the most appropriate surgical approach for dermoid cysts to a great extent (8).

Benign, malignant salivary gland tumors, cystic hygromas, ectopic thyroid tissues, thyroglossal duct cysts, and vallecular cysts should be considered in the differential diagnosis (9).

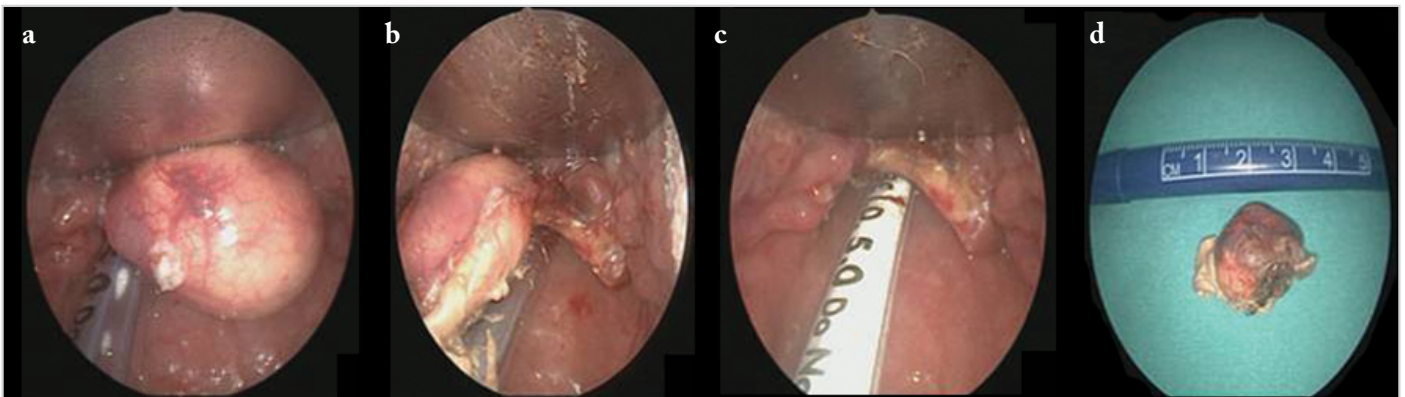


Figure 3. a-d. Peroperative endoscopic image of the mass arising from the left margin of the epiglottis and extending to the pyriform sinus (a); excision of the mass from the midline epiglottis toward the left lateral edge with a plasma blade (b); the appearance of the epiglottis after complete excision (c); and macroscopic appearance and size of the mass after excision (d)

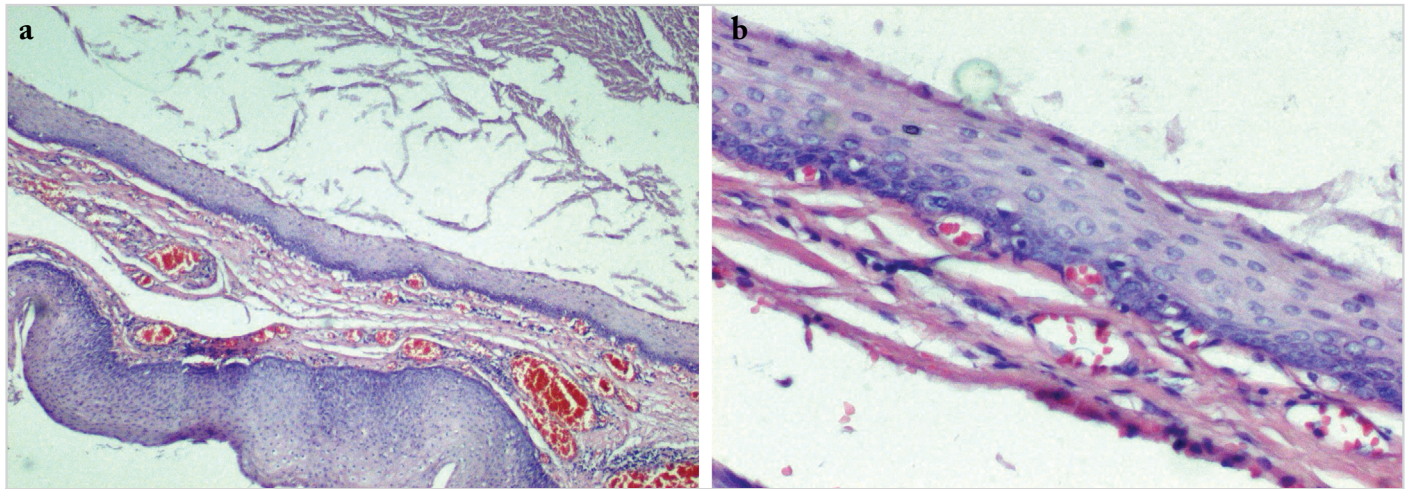


Figure 4. a, b. Histopathological appearance of the actual dermoid cyst; Hematoxylin eosin ×40 (a), Hematoxylin eosin ×200 (b)

Treatment is performed with a complete excision of the mass. Conventional methods, plasma blade, or laser can be used according to the localization of the mass and the existing technical equipment. In cases where the wall of the cyst is removed, the rate of recurrence is very low and prognosis is good (3, 4). However, in literature, it has been reported that 5% of oral dermoid cysts display a malignant transformation (10).

In the case presented, the margins of the mass localized in the left border of the epiglottis were detected through preoperative endoscopic and radiological examinations. It was decided to perform excision with the transoral approach. The lesion with a wide base was completely excised with a plasma blade using an automatic mouth gag and endoscope. No significant bleeding developed during the surgery. It was observed that the lesion did not reach the laryngeal surface of the epiglottis, and any procedure that could risk airway safety during excision was not performed. In the control examination conducted in the post-operative 6th month, the patient was asymptomatic, and the endolaryngeal structures had normal appearance and functions.

Conclusion

A dermoid cyst arising from the epiglottis is rare. It is a painless, slow-growing, and encapsulated lesion, and it does not cause any symptom until it reaches a certain volume. Its main symptoms are muffled voice, dyspnea, and difficulty in swallowing. Radiological imaging techniques are important for determining the nature of lesion and for surgical planning. Treatment is performed with complete surgical excision. The lesions growing in the epiglottis, despite it being a rare location for dermoid cysts, should be taken into consideration in the differential diagnosis.

Informed Consent: Written informed consent was obtained from the patient.

Peer-review: Externally peer-reviewed.

Author Contributions: Concept - Ç.H.Ü., H.Y.; Design - Ç.H.Ü.; Supervision - Ç.H.Ü.; Funding - H.Y., Ç.H.Ü.; Materials - H.Y.; Data

Collection and/or Processing - Ç.H.Ü.; Analysis and/or Interpretation - Ç.H.Ü.; Literature Review - H.Y.; Writing - Ç.H.Ü.; Critical Review - Ç.H.Ü., H.Y.

Acknowledgements: Thanks to Lema Tavlı, MD, Professor at Department of Pathology who prepared histopathologic sections of the dermoid cyst.

Conflict of Interest: No conflict of interest was declared by the authors.

Financial Disclosure: The authors declared that this study has received no financial support.

References

1. Meyer I. Dermoid cysts (dermoids) of the floor of the mouth. *Oral Surgery, Oral Medicine, Oral Pathology* 1955; 8: 1149-64. [\[CrossRef\]](#)
2. Zhao D, Han Y, Chen Y, Qiu J. An unusual dermoid cyst in subcutaneous tissue of the mastoid region: A case report. *Experimental and therapeutic medicine* 2013; 6: 75-6.
3. Jhams BC, Duraes GV, Jhams AC, Santos CR. Epidermoid cyst of the floor of the mouth: A case report. *J Can Dent Assoc* 2007; 73: 525-8.
4. McKenzie D. Dermoid Cyst attached to the Epiglottis. *Proc R Soc Med* 1930; 23: 786-7.
5. Alimov AI, Danilova RD, Akberov AB. 2 cases of epidermoid cyst of the epiglottis. *Vestn Otorinolaringol* 1991; 6: 66-7.
6. Som NZ. Dermoid cyst of the epiglottis. *Vestn Otorinolaringol* 1980; 5: 85.
7. Lin HW, Silver AL, Cunnane ME, Sadow PM, Kieff DA. Lateral dermoid cyst of the floor of mouth: unusual radiologic and pathologic findings. *Auris Nasus Larynx* 2011; 38: 650-3. [\[CrossRef\]](#)
8. Hunter TB, Paplanus SH, Chemin MM, Coulthard SW. Dermoid cyst in the floor of the mouth: CT appearance. *AJR Am Roentgenol* 1983; 141: 1239-40. [\[CrossRef\]](#)
9. Ulku CH, Uyar Y, Arbag H, Ozturk K. Ağız tabanında dermoid kist. *Türk Otolarengoloji Arşivi* 2002; 40: 137-41.
10. Agaimy A, Raab B, Bonkowsky V, Wünsch PH. Intestinal-type adenocarcinoma arising in a congenital sublingual teratoid cyst. *Virchows Archiv* 2007; 450: 479-81. [\[CrossRef\]](#)