

Evaluations of Paranasal Sinus Disease Using Multidetector Computed Tomography in Taif City, Saudi Arabia

Osama Alotaibi¹, Hamid Osman^{2*}, Yasser Hadi³, Yasser Alzamil⁴, Amjad Alyahyawi^{4,5}, Mamdouh S. Al-Enezi⁴, Feras Alafer⁶, Ahmad Abanomy⁷, Mayeen Uddin Khandaker^{8,9}, Meshari Almeshari⁴

¹King Abdulaziz Specialist Hospital-Taif, Taif, Saudi Arabia

²College of Applied Medical Science, Taif University, Taif, Saudi Arabia

³King Abdullah Medical City (KAMC), Makkah, Saudi Arabia

⁴Department of Diagnostic Radiology, College of Applied Medical Sciences, University of Ha'il, Ha'il, Saudi Arabia

⁵Centre for Nuclear and Radiation Physics, Department of Physics, University of Surrey, Guildford, UK

⁶College of Applied Medical Sciences, Jouf University, Sakaka, Saudi Arabia

⁷College of Applied Medical Sciences, King Saud University, Riyadh, Saudi Arabia

⁸Centre for Applied Physics and Radiation Technologies, School of Engineering and Technology, Sunway University, Selangor, Malaysia

⁹Daffodil International University, Dhaka, Bangladesh

Abstract

Background: This study aimed to evaluate paranasal sinusitis disease and determine if there is a relationship between the anatomical variation of sinusitis based on the age and gender of the patient and, if so, to identify the most affected demographic group.

Methods and Results: This study included 130 patients (76 men and 54 women with ages ranging from 18 years to 75 years) diagnosed with PNS disease and was conducted in the Radiology Department of King Abdulaziz Specialist Hospital and King Faisal Hospital (Taif city, Saudi Arabia) from January 1 2021 to January 31 2022. The evaluation of sinusitis was conducted using multidetector computed tomography (MDCT). The clinical symptoms included 70% cases of nasal obstruction, 53% cases of headache, 28.5% cases of nasal discharge, 17.7% cases of facial pain, and 3.1% cases of general malaise. The types of sinusitis included maxillary sinusitis (88.5%), sphenoid sinusitis (28.5%), ethmoid sinusitis (43.8%), and frontal sinusitis (23.5%). The study found no significant anatomical variation of sinuses based on age and gender ($P>0.05$).

Conclusion: An evaluation of paranasal sinusitis disease using an MDCT scan shows that there are no gender or age-related differences in the prevalence of the disease. Moreover, the study demonstrates that there is no significant anatomical variation of sinuses based on age and gender. (**International Journal of Biomedicine. 2022;12(4):575-579.**)

Keywords: paranasal sinus • sinusitis • multidetector computed tomography

For citation: Alotaibi O, Osman H, Hadi Y, Alzamil Y, Alyahyawi A, Al-Enezi MS, Alafer F, Abanomy A, Khandaker MU, Almeshari M. Evaluations of Paranasal Sinus Disease Using Multidetector Computed Tomography in Taif City, Saudi Arabia.. International Journal of Biomedicine. 2022;12(4):575-579. doi:10.21103/Article12(4)_OA9.

Abbreviations

CT, computed tomography; DNS, deviated nasal septum; MDCT, multidetector CT; PNS, paranasal sinus.

Introduction

Sinusitis is an inflammatory condition associated with bacterial, viral, or fungal infections of the cavities

around the nasal passages or allergic reactions affecting the paranasal sinuses.⁽¹⁾ Sinusitis affects approximately 15% of humans worldwide^(2,3) and is considered a major public health problem. The prevalence of sinusitis in the United States and

Europe was 12% and 10.9%, respectively.⁽⁴⁾ Paranasal sinus (PNS) disease is a chronic and life-threatening condition characterized by infection, growth, and inflammation of the sinuses.⁽⁵⁾ PNS disease is a prevalent disease in humans, and it impairs their quality of life.^(6,7) It is also considered the fifth most common cause of antibiotic prescription in the U.S., with medical costs of almost \$2.4 billion in addition to lost and diminished productivity.^(8,9)

The most widely used method for the assessment and diagnosis of PNS disease is the CT imaging modality.^(1,10) CT scans are considered reliable for diagnosing PNS disease due to their high accuracy and sensitivity in defining the extent and degree of sinusitis.⁽²⁾ While CT scans may not be reliable for detecting neoplasms in the paranasal sinuses, they can be used to distinguish between inflammatory diseases of the sinuses.⁽¹¹⁾ An improved form of a CT scan known as MDCT has been developed, which provides a quicker and more detailed analysis of body structures with higher spatial resolution and more coverage of the patient. MDCT can be a useful tool for assessing patients suspected of having and confirmed to have PNS disease.

Due to a lack of publication from our community regarding the efficacy of CT in diagnosing PNS, this study aims at characterizing and evaluating patients with PNS disease in Taif City, Saudi Arabia, using the MDCT technique. Preliminary research shows that sinusitis is prevalent in the Eastern Provinces, where it is associated with nasal polyposis, bronchial asthma, and analgesic intolerance.⁽¹²⁻¹⁴⁾ However, the prevalence rate of PNS disease in the Kingdom of Saudi Arabia is not known due to a paucity of studies on the disease prevalence and incidence.

This study aimed to evaluate paranasal sinusitis disease and determine if there is a relationship between the anatomical variation of sinusitis based on the age and gender of the patient and, if so, to identify the most affected demographic group.

Materials and Methods

Study population, sampling criteria, and study design

This study included 130 patients (males and females with ages ranging from 18 years to 75 years) diagnosed with PNS disease and was conducted in the Radiology Department of King Abdelaziz Specialist Hospital and King Faisal Hospital (Taif city, Saudi Arabia) from January 1 2021 to January 31 2022.

This retrospective study was performed to assess and characterize paranasal sinusitis using MDCT. The dependent variable was paranasal sinusitis disease with mucosal thickening, retention cysts, opacifications, fluid level, polyp, as well as septal deviation, and enlarged nasal conchae. The independent variables were age, gender, history of the disease, and patient complaint (clinical data).

Clinical assessments and guidelines

Patient data were obtained from the Picture Archiving and Communication System (PACS) of each hospital. The data are complete and do not require any special preparation. The data were captured with CT machines installed in the hospitals, including General Electric (GE) healthcare light

speed, Phillips Medical System, and Siemens, all with 128 slices each. The protocol followed during the assessment started with a patient in the supine position and supported under the knee for comfort. The lead apron was placed over the area to follow the concept of “as low as reasonably achievable” (ALARA) patient exposure to radiation.⁽¹⁵⁾ The study protocol was used for the assessment with a lateral scout, axial scan, coronal and sagittal scan plane, and a scan range from the bottom of the maxillary sinus to the endpoint of the frontal sinus.

Statistical analysis was performed using statistical software package SPSS version 23.0 (SPSS Inc, Armonk, NY: IBM Corp). Baseline characteristics were summarized as frequencies and percentages. Group comparisons with respect to categorical variables are performed using One-Sample Chi-Square test. A probability value of $P < 0.05$ was considered statistically significant.

Informed consent was obtained from patients before collecting the data. All identifiable information about patients was removed, and the data were coded to ensure anonymity.

Results

Analysis of the demographic characteristics of the study patients (76[59%] men and 54[41%] women) showed the age range from 18 to 65 years (21.63 ± 6.36 years) with the following age groups: the age group of 18-25 years – 24.6%, 26-35 years – 36.2%, 36-45 years – 18.5%, 46-55 years – 9.2%, and 56-65 years – 6.9% (Table 1).

Table 1.
Distribution of the study sample according to gender and age.

Variable		Frequency (n)	Percentage (%)
Gender	Males	76	58.5%
	Females	54	41.5%
Age range (years)	18-25	32	24.6%
	26-35	47	36.2%
	36-45	24	18.5%
	46-55	12	9.2%
	56-65	9	6.9%
	<65	6	4.6%

More than half of the study sample (60.8%) was aged between 18 and 35, with a mean age of 21.63. The clinical symptoms included 70% cases of nasal obstruction, 53% cases of headache, 28.5% cases of nasal discharge, 17.7% cases of facial pain, and 3.1% cases of general malaise (Table 2). The types of sinusitis included maxillary sinusitis (88.5%), sphenoid sinusitis (28.5%), ethmoid sinusitis (43.8%), and frontal sinusitis (23.5%) (Fig.1).

Characterization of sinusitis depending on the type of sinus opacification showed that 60.8% of the cases with maxillary sinusitis had bilateral opacification, 14.7% had right

sinus opacification, and 24.5% had left sinus opacification. Of the cases diagnosed with ethmoid sinusitis, 70.2% had bilateral sinus opacification, 8.8% had right sinus opacification, and 12.1% had left sinus opacification. Of the cases diagnosed with frontal sinus, 61.3% had bilateral sinus opacification, 12.9% had right sinus opacification, and 25.8% had left sinus opacification. Sphenoid sinus opacification was present in 27.5% of the cases (Table 3).

Table 2.
Distribution of the study sample according to clinical diagnosis.

Clinical symptoms	Frequency (n)	Percentage (%)
Nasal obstruction	91	70%
Headache	69	53.1%
Nasal discharge	37	28.5%
Facial pain	23	17.7%
General malaise	4	3.1%

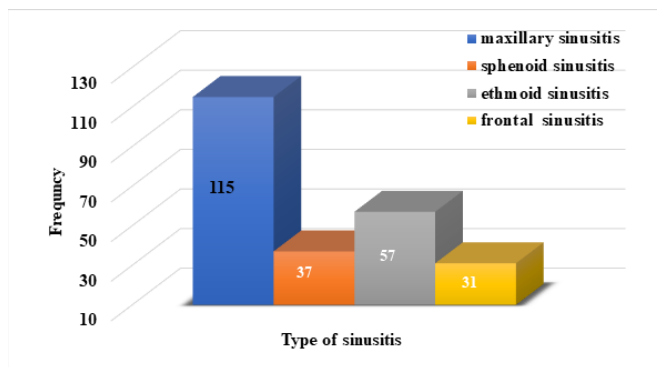


Fig. 1. Types of paranasal sinusitis.

Table 3.
The side of sinus opacification.

Sinus	The side of opacification		
	Right	Bilateral	Left
Maxillary sinus	17 (14.7%)	70 (60.8%)	28 (24.5%)
Ethmoid sinus	5 (8.8%)	40 (70.2%)	12 (12.1%)
Frontal sinus	4 (12.9%)	19 (61.3%)	8 (25.8%)
Sphenoid sinus	Present		Absent
	37 (28.5%)		93 (71.5%)

The most common CT findings in cross-sectional images were nasal septum deviation (72.3%), mucosal thickening (70.8%), nasal conchae enlargement (32.2%),

retention cyst(16.9%), and nasal polyps (7.7%) (Figure 2 and Table 4).

Table 4.
Distribution of the study sample according to CT findings.

CT finding	Side			
	Right	Bilateral	Left	
Presence of mucosal thickening	15 (16.3%)	62 (67.4%)	15 (16.3%)	
Presence of retention cyst	10 (45.4%)	4 (18.2%)	8 (36.4%)	
Presence of nasal polyps	2 (20%)	6 (60%)	2 (20%)	
Nasal conchae enlargement	Site	Right	Bilateral	Left
	Inferior	7 (16.7%)	6 (14.3%)	16 (38.1%)
	Middle	2 (4.7%)	4 (9.5%)	7 (16.7%)
	Superior	0	0	0
Nasal septum deviation	Right	Centralize	Left	
	56 (43.1%)	36 (27.7%)	38 (29.2%)	
Presence of air-fluid level	2 (1.5%)			

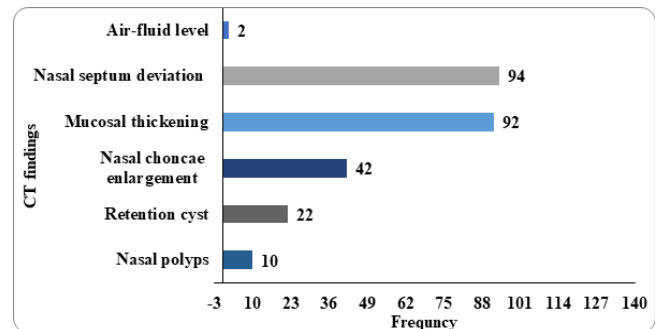


Fig. 2. Distribution of the study sample according to CT findings.

No gender differences in sinusitis prevalence were observed between male and female patients ($P=0.178$). An analysis of age differences in sinusitis showed no significant differences ($P=0.762$). We also did not find statistically significant anatomical variation among the age variables ($P>0.05$). No statistically significant differences in gender were noted in the anatomical variation of sinusitis ($P>0.05$).

Discussion

Sinusitis is a leading public health issue with significant cost implications. An extensive body of literature focuses on the evaluation of paranasal sinusitis using CT scans.^(7,12,16,17) The findings suggest that the age of the patient influences the

pattern of infection.⁽⁷⁾ Further research shows that the features of sinusitis vary widely among patients, including maxillary sinusitis, nasal septal deviation, enlarged nasal conchae, mucosal thickening, retention cysts, and polyps.

The samples used in this study included male and female samples of patients aged 18 years to 65 years old. The study sample indicated that more than half of the study patients (60.8%) who suffered from sinusitis were between 18 and 35 years old. Many studies have explored sinusitis prevalence among various age groups, including young children. Most of these studies have shown that sinusitis occurs among all age groups.^(14,20) Consistent with the evidence from the existing literature, this study's findings indicate no statistically significant difference between the age of the subjects and the severity of sinusitis ($P>0.05$).

Characterization of the study sample based on the type of sinusitis showed that most patients had maxillary sinusitis (88.5%), followed by ethmoid sinusitis (43%), sphenoid sinusitis (28%), and frontal sinusitis (23%).

According to this study, 58.5% of the cases were male while 41.5% were female, with a marginal preponderance for males, which corresponds with the existing research evidence.^(13,21,22) Sinusitis of the maxillary sinus was most common (88.5%), followed by ethmoid, sphenoid and frontal sinuses.^(13,23,24) The most frequent clinical presentations in the present study were nasal obstruction (70%) and headache (53%), which were like those found in the study by Almutairi et al.⁽²⁵⁾ In our study, the septal deviation, mucosal thickening, and enlarged nasal conchae were the most common findings in PNS pathologies, which agrees with data in the study by Alshammari et al.⁽¹²⁾

According to the current study, there was no statistically significant variation in sinusitis and anatomical variables between genders and ages. Most patients with PNS pathology were in their first and second decades, with male predominance. Nasal obstruction was the most common complaint among these patients, and the most common anatomical variant observed was deviated nasal septum, more to the right and with maxillary as commonly involved.

A range of research studies has shown that various mechanisms can damage the sinuses and cause them to become inflamed.⁽²⁶⁻³²⁾ The most common cause is an inflammation caused by a sinus infection that has not yet been identified. In this study, the differences in anatomical features between genders and between ages were not statistically significant. These findings are congruent with existing studies, which show that maxillary sinusitis is the most common type of sinusitis.⁽³³⁾

In conclusion, an evaluation of paranasal sinusitis disease using an MDCT scan shows that there are no gender or age-related differences in the prevalence of the disease. Moreover, the study demonstrates that there is no significant anatomical variation of sinuses based on age and gender. Further clinical studies are required to evaluate other anatomical variations, like concha bullosa, agger nasi cell, basal lamella pneumatization, and crista Galli. The study findings will help healthcare professionals, especially ENT physicians, to make early assessments and accurate diagnoses of PNS disease for effective treatment and management.

Acknowledgments

This research has been funded by Scientific Research Deanship at the University of Hail-Saudi Arabia through project number (GR-22094).

Competing Interests

The authors declare that they have no competing interests.

References

- Iwanaga J, Wilson C, Lachkar S, Tomaszewski KA, Walocha JA, Tubbs RS. Clinical anatomy of the maxillary sinus: application to sinus floor augmentation. *Anat Cell Biol*. 2019 Mar;52(1):17-24. doi: 10.5115/acb.2019.52.1.17.
- Choby G, Thamboo A, Won TB, Kim J, Shih LC, Hwang PH. Computed tomography analysis of frontal cell prevalence according to the International Frontal Sinus Anatomy Classification. *Int Forum Allergy Rhinol*. 2018 Jul;8(7):825-830. doi: 10.1002/alr.22105.
- Sobiesk JL, Munakomi S. Anatomy, Head and Neck, Nasal Cavity. National Library of Medicine. 2022, StatPearls Publishing LLC. <https://www.ncbi.nlm.nih.gov/books/NBK544232/>.
- Hastan D, Fokkens WJ, Bachert C, Newson RB, Bislimovska J, Bockelbrink A, Bousquet PJ, Brozek G, Bruno A, Dahlén SE, Forsberg B, Gunnbjörnsdóttir M, Kasper L, Krämer U, Kowalski ML, Lange B, Lundbäck B, Salagean E, Todo-Bom A, Tomassen P, Toskala E, van Drunen CM, Bousquet J, Zuberbier T, Jarvis D, Burney P. Chronic rhinosinusitis in Europe--an underestimated disease. A GA²LEN study. *Allergy*. 2011 Sep;66(9):1216-23. doi: 10.1111/j.1398-9995.2011.02646.x.
- Torpy JM, Lynn C, Golub RM. JAMA patient page. Chronic sinusitis. *JAMA*. 2011 Nov 9;306(18):2048. doi: 10.1001/jama.2011.1588.
- Papadopoulou AM, Chrysikos D, Samolis A, Tsakotos G, Troupis T. Anatomical Variations of the Nasal Cavities and Paranasal Sinuses: A Systematic Review. *Cureus*. 2021 Jan 15;13(1):e12727. doi: 10.7759/cureus.12727.
- Orman G, Kralik SF, Desai N, Meoded A, Vallejo JG, Huisman TAGM, Tran BH. Imaging of Paranasal Sinus Infections in Children: A Review. *J Neuroimaging*. 2020 Sep;30(5):572-586. doi: 10.1111/jon.12737.
- Centers for Disease Control and Prevention. Sinus Infection (Sinusitis). August 27, 2019. Available from: <https://www.cdc.gov/antibiotic-use/sinus-infection.html>
- Pereira JGD, Santos JBS, Sousa SP, Franco A, Silva RHA. Frontal sinuses as tools for human identification: a systematic review of imaging methods. *Dentomaxillofac Radiol*. 2021 Jul 1;50(5):20200599. doi: 10.1259/dmfr.20200599.
- Naqvi SFH, Arshad N, Naeem MA, Waseem N, Batool N, Ali A. Paranasal Sinuses in the Evaluation of Sinusitis using

**Corresponding author: Prof. Hamid Osman Hamid. Department of Radiology. College of Applied Medical Science, Taif University, Taif, Saudi Arabia. E-mail: ha.osman@tu.edu.sa*

Computed Tomography: Cross-Sectional Study. *Sch J App Med Sci.* 2021;9(4): 605-611.

11. Hussein AO, Ahmed BH, Omer MA, Manafal MF, Elhaj AB. Assessment of clinical, X-Ray and CT in the diagnosis of paranasal sinus diseases. *International Journal of Scientific Research.* 2014;3:7-11.

12. Alshammari QT, Malik BA, Salih M, Yousef M, Elnour E, Yousif E, Gameraddin M. Assessment of Paranasal Sinuses Diseases using Multi-Detector Computed Tomography Scanning in Hail city, Saudi Arabia. *Bioscience Research.* 2020;17:1308-1314.

13. Hamdi A, Mohtasib R, Mahmoud M. Role of Computed Tomography in Determining the Spectrum of Paranasal Sinuses Pathologies in Saudi patients. *Pakistan Journal of Biological Sciences.* 2020;23(3):339-344.

14. Alfarhood AA, Rayzah M, Alhassan MA, Alhassan AA, Alqahtani FA, Alanazi OH. Knowledge And Practice of Pilonidal Sinuses Among Adult Population in Zulfi City, Saudi Arabia, 2018-2019. *World Journal of Pharmaceutical Research.* 2018;7:270-275. doi: 10.20959/wjpr201818-13564.

15. Osman H. Evaluation of patient radiation dose in routine radiographic examinations in Saudi Arabia, *Radiat Phys and Chemi.* 2020;173:108883

16. Chang YS, Chen PL, Hung JH, Chen HY, Lai CC, Ou CY, Chang CM, Wang CK, Cheng HC, Tseng SH. Orbital complications of paranasal sinusitis in Taiwan, 1988 through 2015: Acute ophthalmological manifestations, diagnosis, and management. *PLoS One.* 2017 Oct 3;12(10):e0184477. doi: 10.1371/journal.pone.0184477.

17. Kaminsky J, Bienert-Zeit A, Hellige M, Rohn K, Ohnesorge B. Comparison of image quality and in vivo appearance of the normal equine nasal cavities and paranasal sinuses in computed tomography and high field (3.0 T) magnetic resonance imaging. *BMC Vet Res.* 2016 Jan 19;12:13. doi: 10.1186/s12917-016-0643-6.

18. Munhoz L, Abdala Júnior R, Abdala R, Asaumi J, Arita ES. Diffusion-Weighted Magnetic Resonance Imaging in Maxillary Sinuses Inflammatory Diseases: Report of Three Cases and Literature Review. *J Oral Maxillofac Res.* 2018 Jun 29;9(2):e4. doi: 10.5037/jomr.2018.9204.

19. Munhoz L, Abdala Júnior R, Arita ES. The value of the apparent diffusion coefficient calculated from diffusion-weighted magnetic resonance imaging scans in the differentiation of maxillary sinus inflammatory diseases. *Oral Surg Oral Med Oral Pathol Oral Radiol.* 2019 May;127(5):433-443. doi: 10.1016/j.oooo.2018.11.013.

20. Kakish KS, Mahafza T, Batiha A, Ekteish F, Daoud A. Clinical sinusitis in children attending primary care centers. *Pediatr Infect Dis J.* 2000 Nov;19(11):1071-4. doi: 10.1097/00006454-200011000-00008.

21. Verma J, Tyagi S, Srivastava M, Agarwal A. Computed tomography of paranasal sinuses for early and proper diagnosis of nasal and sinus pathology. *International Journal of Otorhinolaryngology and Head and Neck Surgery.* 2016;2(2):70-76.

22. Özer CM, Atalar K, Öz II, Toprak S, Barut Ç. Sphenoid Sinus in Relation to Age, Gender, and Cephalometric Indices. *J Craniofac Surg.* 2018 Nov;29(8):2319-2326. doi: 10.1097/SCS.0000000000004869.

23. Whyte A, Boeddinghaus R. The maxillary sinus: physiology, development and imaging anatomy. *Dentomaxillofac Radiol.* 2019 Dec;48(8):20190205. doi: 10.1259/dmfr.20190205.

24. Hui L, Hung KF, Yeung AWK, von Arx T, Leung YY, Bornstein MM. Anatomical variations of the ethmoid sinuses and their association with health or pathology of the ethmoid and maxillary sinuses in a Southern Chinese population: An analysis using cone-beam computed tomography. *Imaging Sci Dent.* 2022 Mar;52(1):109-115. doi: 10.5624/isd.20210277.

25. Almutairi AF, Shafi RW, Albalawi SA, Basyuni MA, Alzahrnai AA, Alghamdi AS, Alhaifi AA, Alshehri AA, Al-Gadouri MA. Acute and Chronic Sinusitis Causes and Management. *The Egyptian Journal of Hospital Medicine.* 2017;68(3):1513-1539. doi:10.12816/0039697.

26. Scangas GA, Gudis DA, Kennedy DW. The natural history and clinical characteristics of paranasal sinus mucocoeles: a clinical review. *Int Forum Allergy Rhinol.* 2013 Sep;3(9):712-7. doi: 10.1002/alr.21178.

27. Sataloff RT. Sinusitis. *Journal of Singing.* 2007;64(1):63-66.

28. Khasnavis S. Sinusitis. In *Handbook of Outpatient Medicine.* Springer, Cham. 2018:215-224.

29. Liu T, Sun Y, Bai W. The Role of Epigenetics in the Chronic Sinusitis with Nasal Polyp. *Curr Allergy Asthma Rep.* 2020 Nov 24;21(1):1. doi: 10.1007/s11882-020-00976-8.

30. Sumathy G. Chronic Sinusitis—A Review. *European Journal of Molecular & Clinical Medicine.* 2020;7(10):2020.

31. Abraham J. Imaging for head and neck cancer. *Surg Oncol Clin N Am.* 2015 Jul;24(3):455-71. doi: 10.1016/j.soc.2015.03.012.

32. Rosenfeld RM, Andes D, Bhattacharyya N, Cheung D, Eisenberg S, Ganiats TG, Gelzer A, Hamilos D, Haydon RC 3rd, Hudgins PA, Jones S, Krouse HJ, Lee LH, Mahoney MC, Marple BF, Mitchell CJ, Nathan R, Shiffman RN, Smith TL, Witsell DL. Clinical practice guideline: adult sinusitis. *Otolaryngol Head Neck Surg.* 2007 Sep;137(3 Suppl):S1-31. doi: 10.1016/j.otohns.2007.06.726.

33. Lewis ME, Roberts CA, Manchester K. Comparative study of the prevalence of maxillary sinusitis in later Medieval urban and rural populations in northern England. *Am J Phys Anthropol.* 1995 Dec;98(4):497-506.