

Delineating the Application of Ultrasound in Detecting Synovial Abnormalities of the Subtalar Joint in Juvenile Idiopathic Arthritis

STEFANO LANNI,¹ FRANCESCA BOVIS,¹ ANGELO RAVELLI,² STEFANIA VIOLA,¹
FRANCESCA MAGNAGUAGNO,¹ ANGELA PISTORIO,¹ GIAN MICHELE MAGNANO,¹
ALBERTO MARTINI,² AND CLARA MALATTIA²

Objective. To investigate the frequency of ultrasound (US)–detectable involvement of the subtalar joint (STJ), to compare clinical versus US assessment of the STJ, and to compare different scanning approaches to the STJ in juvenile idiopathic arthritis (JIA).

Methods. Clinical and US assessments were performed independently in 50 ankles with clinically active JIA. US abnormalities of the STJ were investigated using a lateral, medial, and posterior scanning approach and scored semi-quantitatively. Agreement was tested using kappa statistics. A control group of 10 healthy subjects was examined.

Results. Clinical and US evaluations detected synovitis in 24 of 50 (48.0%) and 27 of 50 (54.0%) of STJs, respectively. US detected synovitis in 10 of 26 STJs (38.5%) recorded as normal on clinical evaluation, but was negative in 7 of 24 STJs (29.2%) diagnosed as having involvement on clinical examination. Agreement between clinical and US assessments was fair ($\kappa = 0.32$). US abnormalities were more frequently detectable using the lateral scanning approach. All patients with US abnormalities in the medial and/or posterior side of the STJ had also US abnormalities on the lateral scanning approach, but the reverse was not true. Intra- and interobserver agreements for the lateral scanning approach were satisfactory for both detecting involvement and scoring US abnormalities. None of the 17 STJs of healthy controls showed US abnormalities.

Conclusion. US may increase the precision of the evaluation of the STJ in JIA. The observed high frequency of STJ involvement on US suggests to include this joint in US scanning protocols devised for children with JIA. Synovitis is more frequently detected using the lateral scanning approach.

INTRODUCTION

Juvenile idiopathic arthritis (JIA) is an exclusion diagnosis that gathers together all arthritides lasting for more than 6 weeks, with onset before 16 years of age, and of unknown etiology (1). The International League of Associations for Rheumatology (ILAR) has subclassified the condition into 7 distinct categories, based on articular and extraarticular manifestations (2); suggestions to improve the homogeneity of the various categories have been recently pro-

posed (3). Despite the heterogeneity, all subtypes of JIA are characterized by inflammation affecting the synovial membrane, which leads to the development of synovial hyperplasia (SH) and joint effusion (JE). Early identification and treatment of the articular inflammatory process are of foremost importance to prevent establishment of damage and related physical disability and to improve the quality of life of patients and their families (4,5).

The higher sensitivity of ultrasound (US) compared to physical evaluation in assessing joints of patients with chronic inflammatory arthritis has been shown in several studies (6–9). The advantage of US lies in its easy and ready availability, relatively low cost, patient well-acceptance and comfort, absence of ionizing radiation, and in its ability to allow real-time and multiplane imaging of several joints in a single scanning session (10–12).

In recent years, some reports have emphasized the ability of US to aid physicians to identify precisely the site of inflammation in the ankles of children with JIA (13–15). Clinical assessment of the ankle region is often challenging, especially in the very young, due to the multiplicity of joint recesses and surrounding tendons, the small size

¹Stefano Lanni, MD, Francesca Bovis, MSc, Stefania Viola, MD, Francesca Magnaguagno, MD, Angela Pistorio, MD, PhD, Gian Michele Magnano, MD: Istituto Giannina Gaslini, Genova, Italy; ²Angelo Ravelli, MD, Alberto Martini, MD, Clara Malattia, MD, PhD: Istituto Giannina Gaslini and Università degli Studi di Genova, Genova, Italy.

Address correspondence to Stefano Lanni, MD, Pediatria II, Istituto G. Gaslini, Largo G. Gaslini 5, 16147 Genova, Italy. E-mail: stefano.lanni@libero.it.

Submitted for publication March 26, 2015; accepted in revised form January 12, 2016.

Significance & Innovations

- Ultrasound (US) is a valuable imaging method to assess subtalar joint (STJ) in children with juvenile idiopathic arthritis.
- US may increase the precision of the evaluation of STJ.
- Synovitis of STJ is more frequently detected using the lateral scanning approach.

of articular compartments, and the abundant fat. These issues make it difficult, even for the expert physician, to identify the single anatomic components (10,11). Of the various structures that are part of the ankle region, the subtalar joint (STJ) is one of the most difficult to assess clinically (Figure 1). The STJ is located between the calcaneus and the talus and is typically divided into 3 articulating facets of the superior part of the calcaneus. The anterior facet articulates with the head of the talus and lies anterior and slightly lateral to the middle facet. The middle facet is supported by the sustentaculum tali on the medial aspect of the calcaneus. It has been described that the anterior and middle facets are frequently connected to each other. The posterior facet of the calcaneus is the largest and articulates with the inferior surface of the talar body. The posterior facet is separated from the anterior and middle facet by the calcaneal sulcus in the calcaneus, which forms with the equivalent sulcus tali in the talus the sinus tarsi (16–18). Many tendons lie close together to the STJ and inflammation of tendon sheaths may mimic STJ involvement. Furthermore, the STJ lies relatively deep to the skin, making assessment by palpation hard. These problems partially explain why involvement of the STJ, which is frequently affected throughout the course of JIA, often remains clinically unrecognized. The frequent lack of detection of arthritis in this joint has been documented in a previous study, in which 80% of STJs of children with JIA showing involvement on magnetic resonance (MR) were recorded as normal on clinical examination (19). Failure to properly diagnose STJ involvement may lead to persistence of joint inflammation, with consequent risk of development of structural

damage. Furthermore, correct location of joint inflammation in the STJ may guide the administration of intraarticular corticosteroid therapy in the appropriate area (20). Although the application of US represents a valuable option to improve the accuracy of the assessment of the STJ, to date there is little information about US assessment of this joint in children with JIA. In particular, to our knowledge, no guidelines or recommendations are available concerning the appropriate scanning approach to the STJ in children with chronic inflammatory arthritis.

The present study was aimed to gain insights into the potential utility of US in the assessment of STJ in children with JIA through the evaluation of the frequency of US-detectable involvement, the comparison of clinical versus US assessment, and the comparison of different scanning approaches.

PATIENTS AND METHODS

Patient selection. All consecutive patients who met the ILAR criteria for JIA (2), were seen between June and November 2013 at the rheumatology outpatient clinic of the Istituto G. Gaslini, Genova, Italy, and had clinically active ankle disease were enrolled. If both ankles were involved, only the one most clinically affected was selected. Informed consent was obtained from all children, parents, or guardians, as appropriate. The study protocol was approved by the local institutional review board.

Clinical and laboratory assessment. At study visit, the following data were recorded for each patient: sex, age at disease onset and study entry, disease duration, ILAR category, antinuclear antibody (ANA) status, and ongoing medications. Erythrocyte sedimentation rate (ESR) and C-reactive protein (CRP) levels were collected only if they were performed at the time of the visit. Clinical assessment for presence/absence of ankle disease was performed by 2 experienced pediatric rheumatologists (AR and SV). Clinically active ankle disease was defined as the presence of swelling or, if no swelling was present, of tenderness/pain on motion and restricted motion (21). Involvement of the STJ was defined as the presence of pain and restricted motion on the inversion or eversion of the foot.

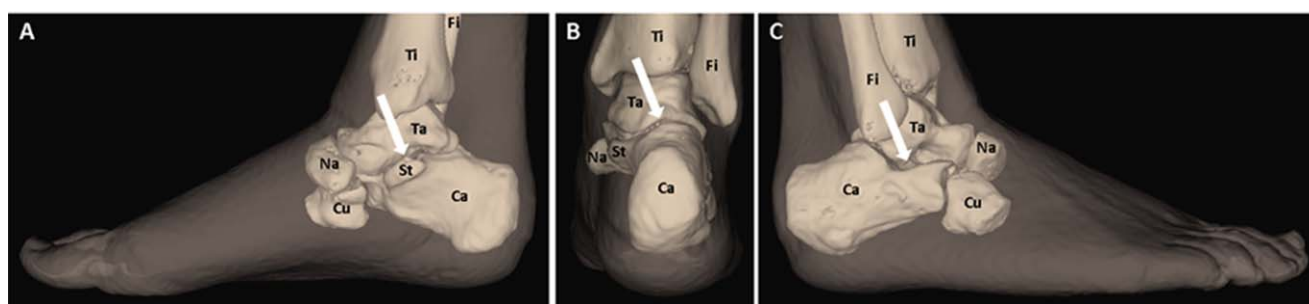

Figure 1. Anatomy of the ankle bones showing the medial (A), posterior (B), and lateral (C) viewpoints of the subtalar joint, respectively, as indicated by the arrows. The images have been obtained using Quanta Imaging Technology (Camelot Biomedical Systems Srl). Ca = calcaneus; Cu = cuboid; Fi = fibula; Na = navicular; St = sustentaculum tali; Ta = talus; Ti = tibia.

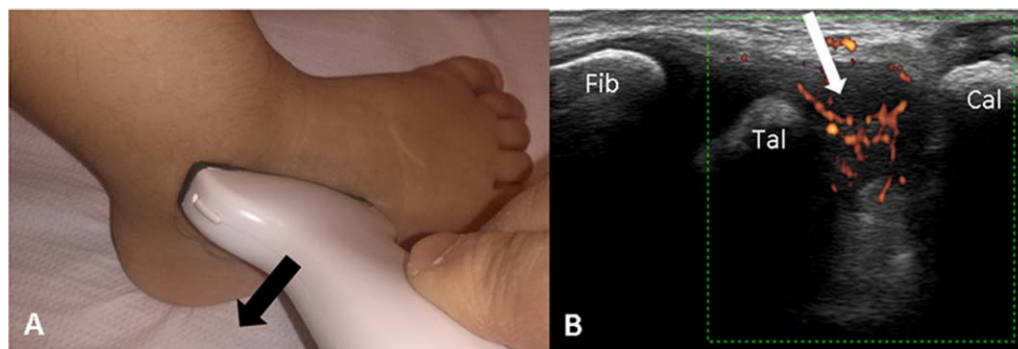


Figure 2. Position of the probe for the lateral scanning approach to the subtalar joint (A) and synovitis (white arrow) (B) exhibiting power Doppler signal through the lateral scanning approach in a 5-year-old girl with juvenile idiopathic arthritis. The black arrow (A) indicates the movement of the probe. Fib = fibula; Tal = talus; Cal = calcaneus.

US assessment. US assessments were performed and recorded immediately after the clinical evaluation by a pediatric rheumatologist (SL) experienced in US assessment of patients with JIA, blinded to clinical findings. Imaging was conducted using an Esaote MyLab Twice machine equipped with a multifrequency linear probe (3–13 MHz linear transducer). Images were collected using the following power Doppler (PD) settings: pulse repetition frequency (PRF) 750 Hz, low wall filter, and color gain just below the level that did not display color noise in the underlying bone. The STJ was evaluated using a lateral, medial, and posterior scanning approach. For the lateral approach, the probe was placed at the 4 o'clock position for the right ankle and at the 8 o'clock position for the left ankle, with its posterior edge over the lateral malleolus, and then was moved down in order to progressively explore the whole joint recess until the sinus tarsi (Figure 2). For the medial aspect of the STJ, the joint space was assessed between the talus and the sustentaculum tali of the calcaneus with the probe placed at the 4 o'clock position for the left ankle and at the 8 o'clock position for the right ankle, with its posterior edge over the medial malleolus (Figure 3). Both the medial and lateral approaches to the STJ were performed with children lying in a supine position with the knee in 45 degrees of flexion and the foot resting on the surface of the examination bed, resulting in

plantar flexion of tibiotalar joint, and with the forefoot oriented in a slightly eversion and inversion, for the medial and lateral assessment, respectively. For the posterior scanning approach to the STJ, the patients were asked to lie prone with the foot resting on the toes over the bed in order to maintain the foot perpendicular to the leg. The probe was then placed as to detect the Achilles tendon in a longitudinal plane and the posterior recess of the STJ was then visualized deeply between the inferior posterior facet of the talus and the superior posterior facet of the calcaneus (Figure 4). The tibiotalar joint, the midfoot region (talonavicular and navicular-first cuneiform joints), and the tendons of the anterior, medial, and lateral compartments of the ankle were also imaged according to published guidelines proposed for adults (22). All joints were investigated on gray-scale (GS) US and soon after on PD US.

US abnormalities were defined according to the Outcome Measures in Rheumatology Clinical Trials standardized definitions for US pathology (23). As per those definitions, SH was defined as an abnormal and poorly compressible hypoechoic joint space, whereas a JE was detected as the presence of an abnormal and compressible anechoic space within the joint. Tenosynovitis was defined as the presence of hypoechoic or anechoic thickened tissue with or without fluid within the tendon sheath, which was seen in 2 perpendicular planes and

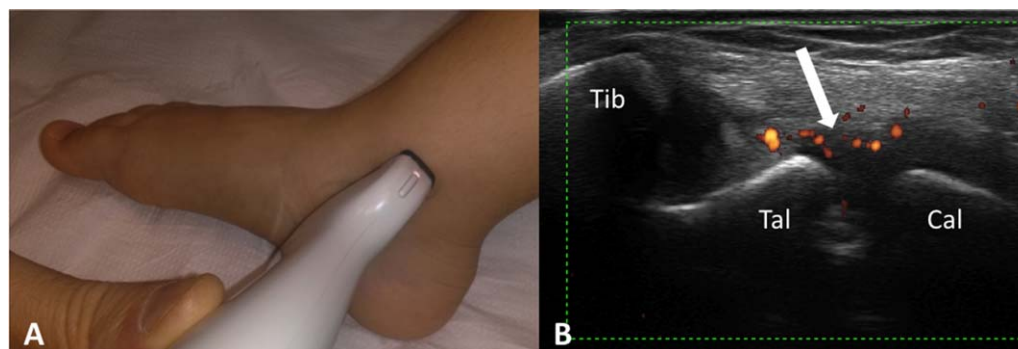


Figure 3. Position of the probe for the medial scanning approach to the subtalar joint (A) and synovitis (arrow) (B) exhibiting power Doppler signal through the medial scanning approach in a 13-year-old girl with juvenile idiopathic arthritis. Tib = tibia; Tal = talus; Cal = calcaneus.

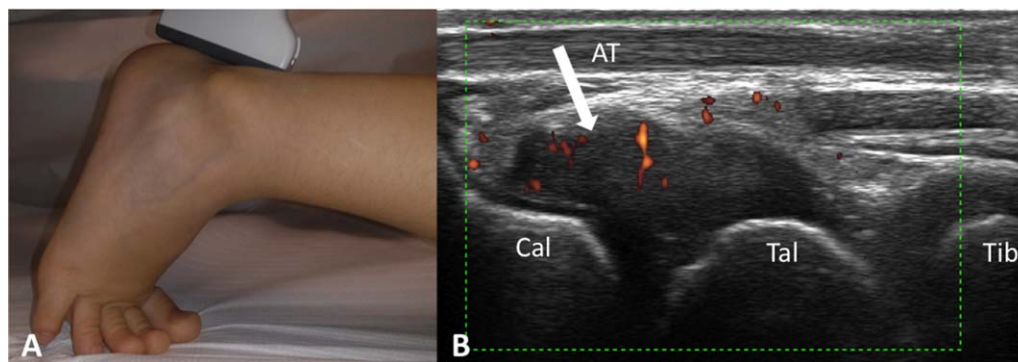


Figure 4. Position of the probe for the posterior scanning approach to the subtalar joint (A) and synovitis (arrow) (B) exhibiting power Doppler signal through the posterior scanning approach in a 4-year-old girl with juvenile idiopathic arthritis. Cal = calcaneus; AT = Achilles tendon; Tal = talus; Tib = tibia.

that could exhibit PD signal. PD signal was considered positive in the presence of vessel dots inside the SH. Joint involvement on US was defined as the presence of both or either JE and SH, which could exhibit PD signal. In particular, STJ involvement on US was defined as the presence in at least 1 of the scanning approaches of both or either JE and SH, which could exhibit PD signal. Only for the STJ, each of the US abnormalities was graded on a 4-point semiquantitative scale based on previous studies (6,24–26). JE and SH were scored as follows: 0 = absent, 1 = mild, 2 = moderate, and 3 = marked. PD signal was graded as follows: 0 = absent, 1 = mild, presence of single-vessel dots, 2 = moderate, presence of confluent vessel dots in less than half of the synovial area, and 3 = marked, presence of confluent vessel dots in more than half of the synovial area. An overall US severity score was calculated as the sum of the scores of JE, SH, and PD and determined for each of the STJ scanning approaches.

Reliability. In order to estimate the intraobserver reliability, stored scans of the different approaches to the STJ for each patient were reassessed and rescored by the same sonographer (SL) 6 months after the end of the study. To evaluate the interobserver reliability, a second pediatric rheumatologist (CM), experienced in US evaluation of children with chronic inflammatory arthritis, performed and scored independently the medial, lateral, and posterior scans of STJs in a randomly selected subgroup of 24 patients.

Healthy controls. Brothers and sisters of patients attending the study center for a visit and without history of musculoskeletal complaints were asked to participate in the study as healthy controls. All underwent a US assessment of at least 1 STJ, depending on their compliance. The US scanning protocol was the same used for JIA patients. The US examinations were performed by the same ultrasonographer (SL) who was aware that the subjects were healthy controls.

Statistical analysis. Descriptive statistics were reported in terms of medians and interquartile ranges (IQRs) for con-

tinuous variables and as absolute frequencies and percentages for categorical variables. Comparison of categorical data was performed by means of the chi-square test, or the Fisher's exact test in the case of expected frequencies <5.

Agreement was estimated by computing the percentage of the exact agreement and through the unweighted Cohen's kappa statistics (κ) with 95% confidence intervals (27). The strength of agreement was defined as follows: $\kappa \leq 0.20$ was considered poor, 0.21–0.40 fair, 0.41–0.60 moderate, 0.61–0.80 good, and >0.81 excellent (28).

SAS software, version 9.3, and Stata, version 10, were used for data analyses.

RESULTS

Study population. A total of 50 patients, 41 girls (82.0%) and 9 boys (18.0%), were enrolled in the study. At study entry, the median disease duration was 5.2 years (IQR 1.8–9.1 years), and the median age was 9.5 years (IQR 6.1–14.9 years). Twenty patients (40.0%) had persistent oligoarthritis, 21 (42.0%) had extended oligoarthritis, 5 (10.0%) had polyarthritis (4 rheumatoid factor [RF] negative and 1 RF positive), and 2 (4.0%) had systemic arthritis; both psoriatic and undifferentiated arthritis accounted for 1 patient (2.0%). ANAs were positive in 41 patients (82.0%): 18 patients with persistent oligoarthritis, 18 with extended oligoarthritis, 3 patients with RF-negative polyarthritis, 1 patient with undifferentiated arthritis, and 1 with systemic arthritis, respectively. Acute-phase reactants were assessed in 43 patients and resulted, on average, in a slight increase (median CRP level 0.5 mg/dl, IQR 0.5–0.9 mg/dl; median ESR 11.5 mm/hour, IQR 5.5–26.0 mm/hour). Thirty-eight patients (76.0%) were taking medications at study entry: 17 (44.8%) and 7 (18.4%) of them were given methotrexate or a biologic agent alone, respectively, whereas 4 patients (10.5%) were receiving methotrexate and a biologic agent. Only 10 patients (26.3%) were taking nonsteroidal antiinflammatory drugs in monotherapy. The control group comprised 10 subjects, 3 boys and 7 girls, ages 1.4–13.7 years (median age 10.2 years, IQR 6.2–12.6 years), for a total of 17 STJs examined.

Table 1. Frequency of US abnormalities for each STJ scanning approach*

US feature	Lateral, no. (%)	Medial, no. (%)	Posterior, no. (%)
Joint effusion			
Score 0	29 (58.0)	46 (92.0)	37 (74.0)
Score 1	9 (18.0)	2 (4.0)	11 (22.0)
Score 2	8 (16.0)	2 (4.0)	1 (2.0)
Score 3	4 (8.0)	0 (0.0)	1 (2.0)
Synovial hypertrophy			
Score 0	25 (50.0)	42 (84.0)	33 (66.0)
Score 1	7 (14.0)	7 (14.0)	3 (6.0)
Score 2	17 (34.0)	1 (2.0)	9 (18.0)
Score 3	1 (2.0)	0 (0.0)	5 (10.0)
Power Doppler			
Score 0	31 (62.0)	48 (96.0)	43 (86.0)
Score 1	3 (6.0)	1 (2.0)	4 (8.0)
Score 2	13 (26.0)	1 (2.0)	3 (6.0)
Score 3	3 (6.0)	0 (0.0)	0 (0.0)

* US = ultrasound; STJ = subtalar joint.

Comparison between clinical and US findings. Involvement of the STJ was detected on clinical examination in 24 of 50 patients (48.0%) and on US in 27 of 50 patients (54.0%). Concordance between clinical and US evaluation for presence and absence of STJ involvement was found in 17 of 50 patients (34.0%) and 16 of 50 patients (32.0%), respectively. US detected synovitis in 10 of 26 STJs (38.5%) that were recorded as normal on clinical evaluation. In 7 of 24 patients (29.2%) diagnosed as having STJ involvement on clinical examination, US was negative for synovitis of the STJ, but showed involvement of different anatomic sites of the ankle region. In particular, 2 patients displayed isolated tenosynovitis of at least 1 tendon com-

partment, 4 showed tibiotalar or talonavicular synovitis along with tendon involvement, and 1 had tibiotalar, talonavicular, and navicular-first cuneiform involvement and tenosynovitis of medial tendon compartment. Overall, agreement between clinical and US assessment for STJ involvement was fair ($\kappa = 0.32$).

US findings for STJ. All 27 ankles with US-detected STJ involvement showed synovitis on the lateral scanning approach. Twenty (74.1%) and 9 (33.3%) of them also showed synovitis on the posterior ($P < 0.0001$) and medial ($P = 0.0022$) scanning approaches to the STJ, respectively. Of the 20 STJs with posterior involvement, only 8 (40.0%) had evidence of STJ synovitis using the medial scanning approach ($P = 0.0016$). Detailed information about the frequency of specific US features in all STJ scanning approaches is reported in Table 1. Overall, JE, SH, and PD signal were recorded more frequently in the lateral aspect of the joint than in the posterior and medial. In all 3 scanning approaches, the most frequent US abnormality was SH, followed by JE and PD signal. Grade 2 for SH and PD signal and grade 1 for JE were the most frequent US abnormalities detected in the lateral aspect of the joint. Similar findings were observed also for the posterior side, except for PD signal, which was scored more commonly as 1. For the medial scanning approach, none of the US abnormalities were scored as 3 and no difference in the rate of score 1 and 2 for JE and PD signal was observed; score 1 was the most frequently registered for SH. In the 27 ankles with US-detected STJ involvement, the overall US severity score resulted as higher in the lateral side (median 4.0, IQR 3.0–6.0) compared to the medial (median 0.0, IQR 0.0–1.0) and posterior (median 2.0, IQR 0.0–4.0) sides. Considering the subgroup of 8 patients showing US abnormalities in all 3 aspects of STJ, the overall US severity score was higher for the lateral side of the STJ (median

Table 2. Intra- and interobserver agreement for US assessment of STJ*

Description	Intra-observer (%)†		Inter-observer (%)‡	
	Kappa	(95% CI)	Kappa	(95% CI)
STJ involvement (presence/absence)	98	0.96 (0.88–1.00)	96	0.92 (0.76–1.00)
STJ lateral involvement (presence/absence)	98	0.96 (0.88–1.00)	96	0.92 (0.76–1.00)
STJ medial involvement (presence/absence)	86	0.46 (0.12–0.79)	87	0.30 (0.00–0.91)
STJ posterior involvement (presence/absence)	98	0.96 (0.88–1.00)	87	0.73 (0.44–1.00)
STJ lateral				
JE score (range 0–3)	78	0.63 (0.46–0.81)	75	0.58 (0.33–0.83)
SH score (range 0–3)	84	0.74 (0.59–0.89)	87	0.79 (0.59–0.99)
PD score (range 0–3)	92	0.85 (0.72–0.98)	83	0.71 (0.47–0.94)
STJ medial				
JE score (range 0–3)	94	0.48 (0.00–0.68)	83	0.14 (0.00–0.44)
SH score (range 0–3)	86	0.44 (0.11–0.76)	92	0.31 (0.13–0.50)
PD score (range 0–3)	NA	NA	NA	NA
STJ posterior				
JE score (range 0–3)	84	0.60 (0.38–0.82)	67	0.22 (0.00–0.53)
SH score (range 0–3)	74	0.54 (0.37–0.71)	79	0.52 (0.21–0.82)
PD score (range 0–3)	96	0.85 (0.66–1.00)	100	1.00 (1.00–1.00)

* US = ultrasound; STJ = subtalar joint; 95% CI = 95% confidence interval; JE = joint effusion; SH = synovial hypertrophy; PD = power Doppler; NA = not assessable; the small number of positive cases for PD signal did not allow to calculate kappa assessment.

† Intraobserver agreement was assessed considering all 50 patients.

‡ Interobserver agreement was assessed considering data from a random subgroup of 24 patients.

5.5, IQR 3.5–6.5) than in the 2 other sides (medial median 1.0, IQR 1.0–3.0 and posterior median 4.0, IQR 3.5–6.0, respectively).

None of the 17 STJs of healthy controls showed US abnormalities. Ten of 27 ankles (37.0%) with STJ involvement on US did not show tenosynovitis in any of the 3 tendon compartments. Involvement of the medial or lateral tendon compartments was found in 11 of 23 ankles (47.8%) without US-detected synovitis of the STJ. Only in 1 case of our series did we find involvement on US of the anterior tendon compartment, and this finding was associated with the involvement of the medial tendon compartment and with the absence of synovitis of STJ on US.

Intraobserver and interobserver reliability. Results of intra- and interobserver agreement are reported in Table 2. Intraobserver agreement for the presence/absence of STJ involvement on US was high ($\kappa = 0.96$). Considering the different scanning approaches, the agreement was excellent for the lateral and posterior side of the STJ ($\kappa = 0.96$), but only moderate for the medial ($\kappa = 0.46$). For specific US features, the best agreement in scoring JE and SH was found for the lateral side of the STJ ($\kappa = 0.63$ and $\kappa = 0.74$, respectively), whereas for PD the lateral and posterior scanning approaches were comparable ($\kappa = 0.85$). Concerning interobserver reliability, the Cohen's kappa value for the presence/absence of STJ involvement on US was high ($\kappa = 0.92$). Regarding the different scanning approaches, the agreement ranged from fair to excellent, being best for the lateral ($\kappa = 0.92$) and worst for the medial ($\kappa = 0.30$). The best agreement in scoring JE and SH was found in the lateral side of the STJ ($\kappa = 0.58$ and $\kappa = 0.79$, respectively), whereas agreement was best for PD by using the posterior scanning approach ($\kappa = 1$).

DISCUSSION

Our study shows that a sizeable proportion of JIA patients with clinical ankle disease have US abnormalities in the STJ. In addition, we found that clinical assessment correlated poorly with US evaluation for the detection of STJ involvement. This finding highlights the difficulty of using physical examination alone to identify STJ synovitis in children with JIA and clinically established active disease in the ankle region.

To our knowledge, our study is the first to evaluate the agreement between clinical and US examination in assessing specifically STJ involvement in patients with JIA and clinically active disease of the ankle joint. A previous study evaluated the prevalence of US findings in ankles with active disease focusing only on the tibiotalar joint and medial and lateral tendons (13). In a subsequent investigation (14) the same group of authors found that only 39% of the STJs considered to be clinically involved showed signs of synovitis on US. However, this joint was not included in the evaluation of the level of agreement between clinical and US findings for the ankle, which was indeed very poor. This is in keeping with a more recent study (15) that showed a less than acceptable agreement for clinical versus US evaluation of the foot in JIA. How-

ever, although the STJ was one of the foot joints more frequently involved on US, the level of agreement between clinical and US assessment was not determined specifically for the STJ.

We found that a considerable proportion of STJs (38.5%) recorded as normal on clinical assessment had synovitis on US. Furthermore, in around one-third of patients who were judged as having STJ involvement on clinical examination, US detected the involvement of anatomic sites other than STJ. Altogether, our findings indicate that US may increase the precision of the assessment of STJ in patients with JIA. Notably, the accurate recognition of the truly inflamed anatomic structure is crucial to improve the outcome of a local treatment such as intra-articular steroid injections (20).

To obtain information useful to standardize image acquisition for the STJ in children with JIA, we compared different scanning approaches. We found that the lateral scanning approach was more advantageous than the medial and posterior approaches to assess the presence of US abnormalities of this joint. We found that JE, SH, and PD signal were more frequently detectable using the lateral scanning approach than the posterior and medial approaches. The overall US severity score, which reflects the amount of inflammation, resulted also as greater for the lateral approach. However, it should be mentioned that the major rate of positivity as well as the higher scores for PD signal found on the lateral scanning approach compared to the posterior may be explained by the fact that this US abnormality is more easily detectable where the synovial recess is more superficial. Furthermore, the predetermined standardized PD settings used for all scanning approaches to the STJ may have reduced the sensitivity of PD signal in certain areas of the joint, particularly in the posterior. This may be prevented in future studies by adjusting PRF, PD frequency and gain according to the selected scanning approach. Of note, all patients with US abnormalities in the medial and/or posterior side of the STJ were always found to have US abnormalities using the lateral scanning approach, but the reverse was not true. From a practical point of view, the ability to scan only the more comprehensive and representative aspect of a joint may help to shorten the length of the US session, which is important in daily clinical practice, especially when managing younger and poorly cooperative children. It is important to note that both levels of intra- and interreader agreement in scoring the lateral aspect of the joint were more than satisfactory for all US abnormalities, and were overall better than for the medial and posterior scanning approaches. Of the 3 US abnormalities, interobserver agreement on the lateral scanning approach was better for SH and PD signal than for JE. A certain degree of difficulty in reproducibility in scoring JE was anticipated, because the anechoic aspect of cartilage, which is well-represented in children, often hampers its clear distinction from joint fluid. Although the medial aspect of the ankle needs to be evaluated for the presence of tenosynovitis, the poor reproducibility of US abnormalities for the medial scanning approach found in our study suggests that this approach is less suited for use in clinical practice for the assessment of the STJ.

Our findings should be interpreted in the light of some potential limitations. Normative data have been so far proposed only for a limited set of joints in children (29), which does not include the STJ. We examined a small number of STJs from healthy controls and, indeed, none of them showed US abnormalities. However, we acknowledge the shortcoming that the ultrasonographer was aware that the subjects were healthy controls. Because pediatric definitions for US features are currently available only for healthy children (30), we used definitions for US pathology and grading systems for GS and PD changes developed for adults that may not be suitable for use in pediatric subjects (10). Finally, we acknowledge that we did not validate the presence of US abnormalities with other imaging modalities, particularly MR. However, previous studies comparing these imaging techniques have documented that both US and MR may provide valuable information on disease activity in patients with chronic inflammatory arthritis (31–34).

In summary, we found that US may increase the precision of the assessment of the STJ in patients with JIA. The observed high frequency of STJ involvement on US underscores the need to include the evaluation of this joint in future US scanning protocols devised for children with chronic inflammatory arthritis. Our study suggests that synovitis of the STJ is more frequently detected using the lateral scanning approach.

ACKNOWLEDGMENTS

The authors wish to thank ESAOTE Spa, Genoa, Italy for supplying the US equipment at the study center, and Camelot Biomedical Systems Srl, Genoa, Italy, for contributing to Figure 1.

AUTHOR CONTRIBUTIONS

All authors were involved in drafting the article or revising it critically for important intellectual content, and all authors approved the final version to be submitted for publication. Dr. Lanni had full access to all of the data in the study and takes responsibility for the integrity of the data and the accuracy of the data analysis.

Study conception and design. Lanni, Ravelli, Viola, Magnaguagno, Magnano, Martini, Malattia.

Acquisition of data. Lanni, Magnaguagno, Malattia.

Analysis and interpretation of data. Lanni, Bovis, Pistorio, Malattia.

REFERENCES

- Ravelli A, Martini A. Juvenile idiopathic arthritis. *Lancet* 2007;369:767–78.
- Petty RE, Southwood TR, Manners P, Baum J, Glass DN, Goldenberg J, et al. International League of Associations for Rheumatology classification of juvenile idiopathic arthritis: second revision, Edmonton, 2001. *J Rheumatol* 2004;31:390–2.
- Martini A. It is time to rethink juvenile idiopathic arthritis classification and nomenclature [editorial]. *Ann Rheum Dis* 2012;71:1437–9.
- Magnani A, Pistorio A, Magni-Manzoni S, Falcone A, Lombardini G, Bandeira M, et al. Achievement of a state of inactive disease at least once in the first 5 years predicts better outcome of patients with polyarticular juvenile idiopathic arthritis. *J Rheumatol* 2009;36:628–34.
- Consolaro A, Negro G, Lanni S, Solari N, Martini A, Ravelli A. Toward a treat-to-target approach in the management of juvenile idiopathic arthritis. *Clin Exp Rheumatol* 2012;30 Suppl:S157–62.
- Magni-Manzoni S, Epis O, Ravelli A, Klersy C, Visconti C, Lanni S, et al. Comparison of clinical versus ultrasound-determined synovitis in juvenile idiopathic arthritis. *Arthritis Rheum* 2009;61:1497–504.
- Haslam KE, McCann LJ, Wyatt S, Wakefield RJ. The detection of subclinical synovitis by ultrasound in oligoarticular juvenile idiopathic arthritis: a pilot study. *Rheumatology (Oxford)* 2010;49:123–7.
- Bretton S, Jousse-Joulin S, Cangemi C, de Parscau L, Colin D, Bressolette L, et al. Comparison of clinical and ultrasonographic evaluations for peripheral synovitis in juvenile idiopathic arthritis. *Semin Arthritis Rheum* 2011;41:272–8.
- Rebollo-Polo M, Koujok K, Weisser C, Jurencak R, Bruns A, Roth J. Ultrasound findings on patients with juvenile idiopathic arthritis in clinical remission. *Arthritis Care Res (Hoboken)* 2011;63:1013–9.
- Lanni S, Wood M, Ravelli A, Magni-Manzoni S, Emery P, Wakefield RJ. Towards a role of ultrasound in children with juvenile idiopathic arthritis. *Rheumatology (Oxford)* 2013;52:413–20.
- Lanni S, Martini A, Malattia C. Heading toward a modern imaging approach in juvenile idiopathic arthritis. *Curr Rheumatol Rep* 2014;16:416.
- Magni-Manzoni S, Malattia C, Lanni S, Ravelli A. Advances and challenges in imaging in juvenile idiopathic arthritis. *Nat Rev Rheumatol* 2012;8:329–36.
- Rooney ME, McAllister C, Burns JF. Ankle disease in juvenile idiopathic arthritis: ultrasound findings in clinically swollen ankles. *J Rheumatol* 2009;36:1725–9.
- Pascoli L, Wright S, McAllister C, Rooney M. Prospective evaluation of clinical and ultrasound findings in ankle disease in juvenile idiopathic arthritis: importance of ankle ultrasound. *J Rheumatol* 2010;37:2409–14.
- Hendry GJ, Gardner-Medwin J, Steultjens MP, Woodburn J, Sturrock RD, Turner DE. Frequent discordance between clinical and musculoskeletal ultrasound examinations of foot disease in juvenile idiopathic arthritis. *Arthritis Care Res (Hoboken)* 2012;64:441–7.
- Lopez-Ben R. Imaging of the subtalar joint. *Foot Ankle Clin* 2015;20:223–41.
- Jung MH, Choi BY, Lee JY, Han CS, Lee JS, Yang YC, et al. Types of subtalar joint facets. *Surg Radiol Anat* 2015;37:629–38.
- Maceira E, Monteagudo M. Subtalar anatomy and mechanics. *Foot Ankle Clin* 2015;20:195–221.
- Remedios D, Martin K, Kaplan G, Mitchell R, Woo P, Rooney M. Juvenile chronic arthritis: diagnosis and management of tibio-talar and sub-talar disease. *Br J Rheumatol* 1997;36:1214–7.
- Laurell L, Court-Payen M, Nielsen S, Zak M, Boesen M, Fasth A. Ultrasonography and color Doppler in juvenile idiopathic arthritis: diagnosis and follow-up of ultrasound-guided steroid injection in the ankle region. A descriptive interventional study. *Pediatr Rheumatol Online J* 2011;9:4.
- Ravelli A, Viola S, Ruperto N, Corsi B, Ballardini G, Martini A. Correlation between conventional disease activity measures in juvenile chronic arthritis. *Ann Rheum Dis* 1997;56:197–200.
- Backhaus M, Burmester GR, Gerber T, Grassi W, Machold KP, Swen WA, et al. Guidelines for musculoskeletal ultrasound in rheumatology. *Ann Rheum Dis* 2001;60:641–9.
- Wakefield RJ, Balint PV, Szkudlarek M, Filippucci E, Backhaus M, D'Agostino MA, et al. Musculoskeletal ultrasound including definitions for ultrasonographic pathology. *J Rheumatol* 2005;32:2485–7.
- Naredo E, Collado P, Cruz A, Palop MJ, Cabero F, Richi P, et al. Longitudinal power Doppler ultrasonographic assessment of joint inflammatory activity in early rheumatoid

- arthritis: predictive value in disease activity and radiologic progression. *Arthritis Rheum* 2007;57:116–24.
25. Naredo E, Rodríguez M, Campos C, Rodríguez-Heredia JM, Medina JA, Giner E, et al. Validity, reproducibility, and responsiveness of a twelve-joint simplified power Doppler ultrasonographic assessment of joint inflammation in rheumatoid arthritis. *Arthritis Rheum* 2008;59:515–22.
 26. Naredo E, Bonilla G, Gamero F, Uson J, Carmona L, Laffon A. Assessment of inflammatory activity in rheumatoid arthritis: a comparative study of clinical evaluation with grey scale and power Doppler ultrasonography. *Ann Rheum Dis* 2005;64:375–81.
 27. Cohen J. A coefficient of agreement for nominal scales. *Educ Psychol Meas* 1960;20:37–46.
 28. Landis JR, Koch GG. The measurement of observer agreement for categorical data. *Biometrics* 1977;33:159–74.
 29. Collado P, Naredo E, Calvo C, Crespo M. Assessment of the joint recesses and tendon sheaths in healthy children by high-resolution B-mode and power Doppler sonography. *Clin Exp Rheumatol* 2007;25:915–21.
 30. Roth J, Jousse-Joulin S, Magni-Manzoni S, Rodriguez A, Tzaribachev N, Iagnocco A, et al. Definitions for the sonographic features of joints in healthy children. *Arthritis Care Res (Hoboken)* 2015;67:136–42.
 31. Laurell L, Court-Payen M, Nielsen S, Zak M, Boesen M, Fasth A. Comparison of ultrasonography with Doppler and MRI for assessment of disease activity in juvenile idiopathic arthritis: a pilot study. *Pediatr Rheumatol Online J* 2012;10:23.
 32. Wakefield RJ, Freeston JE, O'Connor P, Reay N, Budgen A, Hensor EM, et al. The optimal assessment of the rheumatoid arthritis hindfoot: a comparative study of clinical examination, ultrasound and high field MRI. *Ann Rheum Dis* 2008;67:1678–82.
 33. Szkudlarek M, Klarlund M, Narvestad E, Court-Payen M, Strandberg C, Jensen KE, et al. Ultrasonography of the metacarpophalangeal and proximal interphalangeal joints in rheumatoid arthritis: a comparison with magnetic resonance imaging, conventional radiography and clinical examination. *Arthritis Res Ther* 2006;8:R52.
 34. Eich GF, Hallé F, Hodler J, Seger R, Willi UV. Juvenile chronic arthritis: imaging of the knees and hips before and after intraarticular steroid injection. *Pediatr Radiol* 1994;24:558–63.