

Penetrating trauma in rural areas – a public health disease: A report of 2 cases

M Tun,¹ MMed (Surg), FACS; M L Maroga,² FC Neurol (SA), MMed (Neurol); M Matlakala,¹ MB ChB; L O Orjiaka,³ FC Ortho (SA), MMed (Ortho); A Modiba,¹ MB ChB; L M Tormo Gainza,¹ MD

¹ Department of General Surgery, Limpopo Academic Complex and School of Medicine, University of Limpopo, Polokwane, South Africa

² Department of Neurosurgery, Limpopo Academic Complex and School of Medicine, University of Limpopo, Polokwane, South Africa

³ Department of Orthopaedic Surgery, Limpopo Academic Complex and School of Medicine, University of Limpopo, Polokwane, South Africa

Corresponding author: M Tun (drmyinttun@outlook.com)

It has been recommended that all penetrating trauma to the head, neck and torso, and to the extremities proximal to the elbow and knee, should be managed in specialised trauma centres. We present two cases of penetrating trauma that presented to Pietersburg Hospital, part of the Limpopo Academic Complex. Both of them were the result of interpersonal violence.

S Afr Med J 2022;112(11b):920-922. <https://doi.org/10.7196/SAMJ.2022.v112i11b.16826>

Limpopo Province, with 6.01 million inhabitants in 2021, is the fifth most populated province in South Africa (SA).^[1] The Limpopo Academic Complex, comprising Pietersburg Hospital and Mankweng Hospital, is the only referral centre for the public health sector in the province.

As a part of the Limpopo Academic Complex, Pietersburg Hospital renders its tertiary surgical services to the entire province and its emergency surgical services to the local community. Its emergency surgical team is headed by a surgical specialist and supported by other surgical subspecialty emergency teams, such as paediatric surgery, ear, nose and throat surgery, orthopaedic surgery, urology, plastic surgery and neurosurgery.

Case 1

A 34-year-old woman with penetrating trauma was referred from a district hospital on 5 June 2022. She had been stabbed with a panga, a broad, heavy knife similar to a machete, just below the chin. This incident was reportedly due to domestic violence. After receiving primary care at the district hospital, she was transferred to Pietersburg Hospital for further surgical management. Although the panga was still *in situ*, she was in a sufficiently stable condition for further investigations before emergency surgery. An urgent computed tomography (CT) scan with CT angiography (CTA) of the neck was requested to exclude possible major organ damage radiologically. However, the radiologist on call advised that this should not be performed because the panga, being a large metal object, could interfere with the radiological images. Emergency surgical exploration of the neck was therefore performed under general anaesthesia, and the panga was removed. Fortunately, no major organ damage was found (Fig. 1). The patient's postoperative recovery was uneventful.

Case 2

A 24-year-old man with penetrating trauma was referred from a district hospital on 14 July 2022. He had been stabbed in the back, reportedly in a homicide attempt. He also received primary care at a district hospital and was transferred to Pietersburg Hospital for further management. Similar to the first case, the assailant's knife was still embedded in the patient's back (Fig. 2). A lateral chest

radiograph showed the tip of the blade to be in close proximity to the descending thoracic aorta (Fig. 3). An urgent CT scan with CTA indicated that the knife had penetrated in close proximity to the vertebrae and thoracic aorta (Fig. 4). Remarkably, the patient's condition remained stable. Emergency surgery was performed under general anaesthesia. Because of the radiological findings, the surgical team was alerted to the potential for major organ damage due to this penetrating injury. An orthopaedic surgeon assisted with the operation, while the specialised neurosurgical and vascular

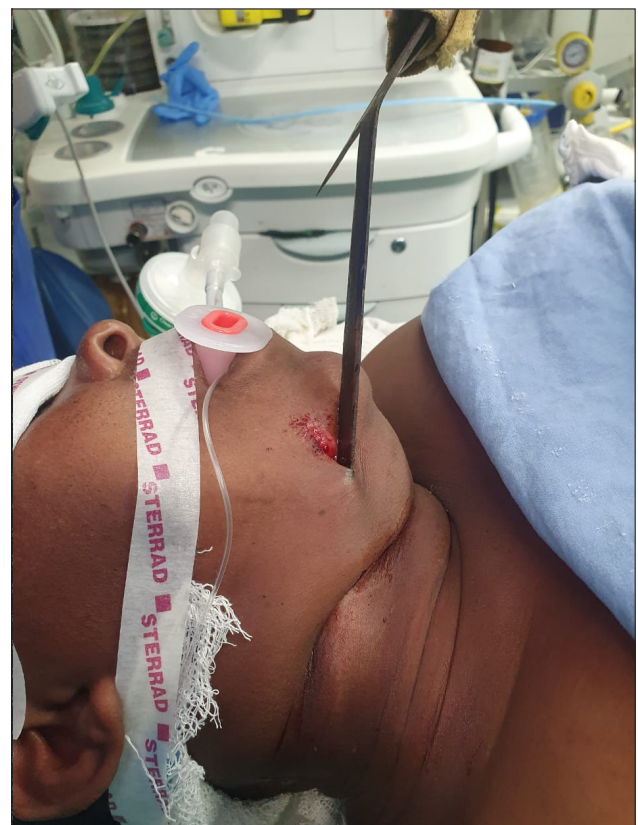

Fig. 1. Case 1. Penetrating neck trauma with a panga still in situ.

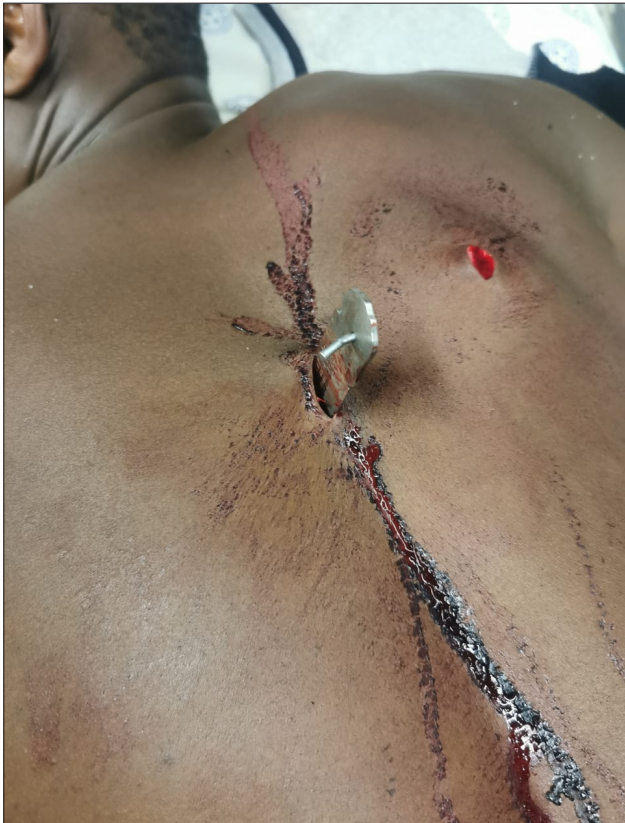

Fig. 2. Case 2. Penetrating back trauma with a knife blade still in situ.

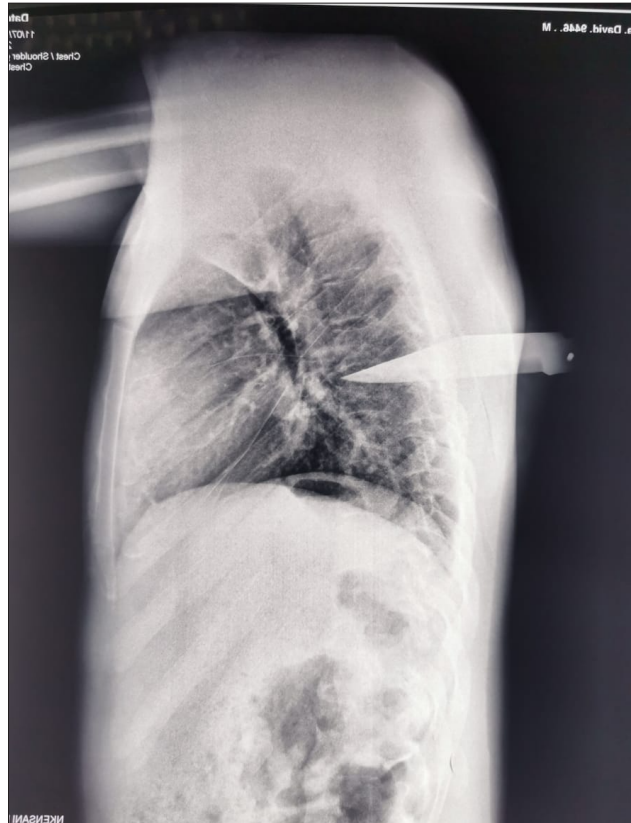


Fig. 3. Case 2. Chest radiograph, lateral view.

surgical teams were in attendance to provide immediate support if necessary. Fortunately, the knife was successfully removed without causing injury to any vital structures. The patient's postoperative recovery was uneventful.

Discussion

SA, a developing country, is in the midst of a health transition. This transition, characterised by epidemic infectious diseases and a rise in non-communicable diseases, has exposed the suboptimal performance of the health system, particularly at district level. Some particular challenges are: (i) a maturing and generalised HIV epidemic with a high prevalence of tuberculosis; (ii) high maternal and child mortality; (iii) non-communicable diseases such as cardiovascular disease, type 2 diabetes, cancer, chronic lung disease and depression; and (iv) last but not least, violence and injuries.^[2]

We have described two cases of penetrating trauma that were managed by the emergency surgical team at Pietersburg Hospital. Both of them were the result of violent assault and were attended by a single surgeon during a 6-week period while he was leader of the emergency surgical team.

The care of critically ill trauma patients with penetrating injuries begins before the time of injury. A properly set-up emergency medical team is essential for efficient medical care as well as the safety of medical staff. There are clear guidelines for management of trauma patients with penetrating injuries. All patients with penetrating injuries to the head, neck and torso, and to the extremities proximal to the elbow and knee, should be transferred to the highest-level trauma centre available. Patients who are physiologically unstable should be transported to the nearest centre that is able to provide appropriate trauma care.

Both our patients were transported to the highest-level trauma centre available. Pietersburg Hospital, although currently still without

its own established trauma unit, is relatively well equipped to deal with such major trauma cases. Both the patients received appropriate medical care from its emergency surgical team.

Operative management has been regarded as the gold standard for management of penetrating trauma. The physiological status of the victim dictates the need for urgent surgical intervention, with the goals of controlling active bleeding and controlling contamination from hollow viscus injuries. With the advent of newer-generation CT scanners, the appropriate use of CT imaging has become an integral part of the preoperative work-up in penetrating trauma patients who are haemodynamically stable.^[3]

In line with the existing literature,^[4] preoperative CT scans were requested in both our cases before emergency surgery. Both patients had an uneventful recovery postoperatively.

In 1997, Brandon Hamber and Sharon Lewis published the research report entitled 'An overview of the consequences of violence and trauma in South Africa'^[5] for the Centre for the Study of Violence and Reconciliation. In its introduction, South Africans were referred to as living in a 'culture of violence'; in a society that endorses and accepts violence as an acceptable and legitimate way to resolve problems and goals. It also reported that the majority of victims of violent crimes are likely to feel unsupported and hopeless, and understandably continue to lose faith in the effectiveness of the criminal justice system.

Children exposed to violence will more readily become perpetrators of violence themselves.^[5,6] Women who were beaten are at least twice as likely to beat their children compared with mothers who were not abused.^[5]

It is very difficult to estimate the exact prevalence of penetrating trauma due to violence in the local community served by Pietersburg Hospital's emergency surgical team. However, the two cases of penetrating trauma due to violence we report here presented to

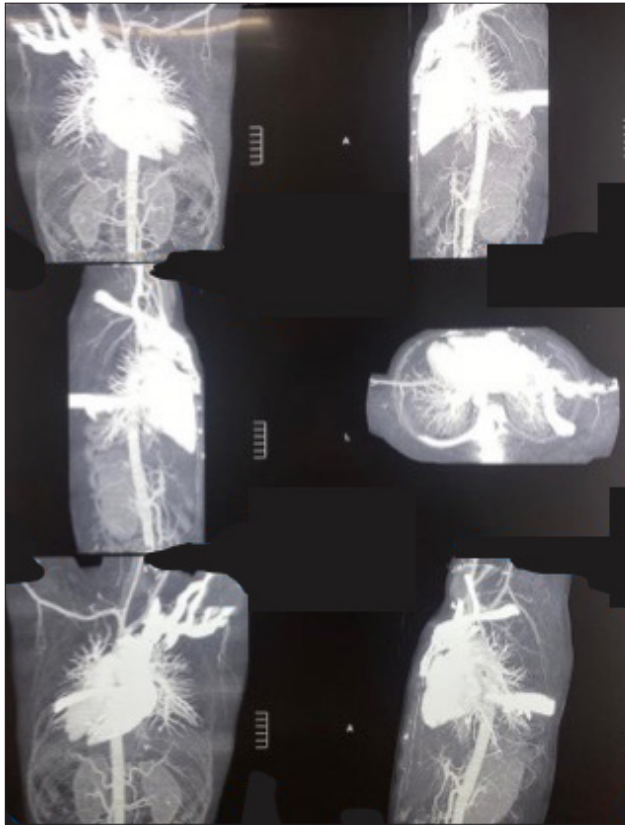


Fig. 4. Case 2. Preoperative computed tomography angiography imaging.

a single surgeon over a brief period of 6 weeks, reflecting a high prevalence of penetrating trauma and violence in our community.

It has been suggested in the literature that penetrating trauma and violence should be approached by using a variety of preventive techniques and preventive health programmes.^[7] It is possible to elucidate the causes of violence, and to suggest interventions to reduce its incidence. Multiple levels of prevention are necessary to combat violence and trauma. These include primary prevention

(e.g. education), secondary prevention initiatives (e.g. psychosocial and medical services), and finally tertiary preventive services (e.g. trauma counselling).^[5,8]

Conclusion

The two cases reported highlight the prevalence of violence in our community. Care of trauma patients should start before the time of injury. We strongly support community-based injury prevention programmes and are of the opinion that they should be part of the armamentarium of combating trauma and violence in rural areas.

Declaration. None.

Acknowledgements. We thank all staff of the Department of General Surgery, Limpopo Academic Complex, for their contributions to emergency surgical services. Without them, this article could not have been written. We also thank Mr C M Aung for his help formatting the figures.

Author contributions. Equal contributions.

Funding. None.

Conflicts of interest. None.

1. Statista. Total population of South Africa 2021, by province. 7 September 2022. <https://www.statista.com/statistics/1112169/total-population-of-south-africa-by-province/> (accessed 10 September 2022).
2. Still L. South Africa at a glance: Health indicators. In: Still L, ed. Health Care in South Africa 2014. Johannesburg: Profile Media, 2014:65-70.
3. Carlbom D, Bulger E. Prehospital care of penetrating trauma. In: Velmahos GC, Degiannis E, Doll D, eds. Penetrating Trauma: A Practical Guide on Operative Technique and Peri-operative Management. 2nd ed. Heidelberg: Springer, 2017:3-10.
4. Hamill ME. Computed tomography in the workup of patients with penetrating trauma. In: Velmahos GC, Degiannis E, Doll D, eds. Penetrating Trauma: A Practical Guide on Operative Technique and Peri-operative Management. 2nd ed. Heidelberg: Springer, 2017:115-124.
5. Hamber B, Lewis S. An overview of the consequences of violence and trauma in South Africa. Centre for the Study of Violence and Reconciliation, 1 June 1997. <https://www.csvr.org.za/an-overview-of-the-consequences-of-violence-and-trauma-in-south-africa/> (accessed 25 July 2015).
6. Dawes A. The Effects of Political Violence on Children: The Consideration of South African and Related Studies. Int J Psychol 1990;25(1):13-31. <https://doi.org/10.1080/00207599008246811>
7. Callahan DS, Plurad DS. Penetrating injury prevention. In: Velmahos GC, Degiannis E, Doll D, eds. Penetrating Trauma: A Practical Guide on Operative Technique and Peri-operative Management. 2nd ed. Heidelberg: Springer, 2017:605-608.
8. Foege WH, Rosenberg ML, Mercy JA. Public health and violence prevention. Curr Issues Public Health 1995;1:2-9.

Accepted 7 September 2022.