

Case Report

A case of disseminated BCG infection in a daughter of Italian immigrants in Switzerland

Claudia Colomba^{1,2}, Raffaella Rubino², Manlio Tolomeo², Davide Lo Porto¹, Silvia Bonura², Stefano Agrenzano¹, Antonio Cascio^{1,2}

¹ Department of Health Promotion, Mother and Child Care, Internal Medicine and Medical Specialties, University of Palermo, Italy

² Infectious and Tropical Disease Unit, AOU Policlinico "P. Giaccone", 90127 Palermo, Italy

Abstract

Bacillus Calmette-Guérin (BCG) is a vaccine against tuberculosis and contains a live, attenuated strain of *Mycobacterium bovis* as its essential constituent. Being a live, attenuated strain with potential pathogenicity, BCG can cause different complications, both near the inoculation site and through blood dissemination, especially in patients with immunodeficiency. IFN- γ R1 deficiency is an autosomal recessively inherited immunodeficiency characterized by predisposition to infections with intracellular pathogens, in particular mycobacteria.

We report a rare case of chronic osteomyelitis lasting 30 years due to BCG in a woman with IFN- γ R1 deficiency who had previous clinical history of multi-organ BCGitis. Diagnosis of chronic osteomyelitis was confirmed by an 18-fluorine fluorodeoxyglucose positron emission tomography combined with CT scan (18F-FDG PET/CT).

In children with a history of BCG vaccination and chronic unexplained infections, a clinical suspicion of BCG-related disease must arise, and a reason of immunodeficiency should be sought.

Key words: Disseminated BCG infection in IFN- γ R1 deficiency.

J Infect Dev Ctries 2022; 16(2):383-387. doi:10.3855/jidc.15388

(Received 27 May 2021 – Accepted 10 August 2021)

Copyright © 2022 Colomba *et al.* This is an open-access article distributed under the Creative Commons Attribution License, which permits unrestricted use, distribution, and reproduction in any medium, provided the original work is properly cited.

Introduction

Bacillus Calmette-Guérin (BCG) is a live, attenuated strain of *Mycobacterium bovis*, which is part of the *Mycobacterium tuberculosis* complex. The BCG vaccine strain was obtained from an isolate of *M. bovis* and it was used for the first time as a human vaccine in 1921. BCG vaccine continues to be the only licensed vaccine against tuberculosis (TB) [1]; it provides protection against severe forms of TB in infants and young children, but can cause different complications, both locally near the inoculation site and remotely through blood dissemination [2]. Today the World Health Organization (WHO) recommends a single dose of BCG vaccine as part of childhood immunization programs only in countries with a high prevalence of TB. In countries with low TB incidence rates, like Italy, it is now limited to neonates and infants in recognized high-risk groups. These groups include all tuberculin skin test (TST)-negative immunocompetent newborns and breastfeeding infants aged < 6 months, and all TST-negative children aged between 6 months and 5 years moving to highly epidemic areas or whose parents come

from highly endemic areas, or who have been in contact with a family member with active TB without contracting the disease themselves. The vaccine is also recommended for prisoners, health care workers and prison workers [1]. Change in the epidemiologic situation supports the choice of improving contact tracing, diagnosis and treatment [1,3-5]. Our report is about a rare case of chronic osteomyelitis due to BCG who was successfully treated with a multi-drug regimen. The report focuses on the pressing need to define diagnostic and therapeutic pathways for the management of complications resulting from the BCG vaccine. Indeed, to date there is no unanimous consensus on the regimen of drugs to be used and on the duration of such treatments [6,7].

Case Report

A 30-year-old woman with a family history without noteworthy pathologies, was admitted to the Infectious Diseases Unit of A.O.U.P. P. Giaccone of Palermo, Italy, on April 2017 with chronic osteomyelitis mostly involving the right wrist. Her medical history revealed

that she was vaccinated at birth with BCG intracutaneously in the left gluteal area because she was the daughter of Italian immigrants who were considered at high risk of tuberculosis infection at that time. After 48 hours a left inguinal abscess with lymphadenopathy with spontaneous perforation developed. Lymph node biopsy showed a granulomatous lymphadenitis with acid-fast bacilli, and the culture yielded a BCG strain. She was first treated with isoniazid alone, but she developed a right humerus fracture after one month, and radiological examination indicated osteolytic regions in the right ulna and clavicle, as well as in the lower limbs.

A diaphysectomy was required and, ethambutol and rifampicin were administered in addition to isoniazid. Treatment with antibiotics lasted four years.

Because of recurrent lung infection episodes and bronchoscopic signs of granulomatous tissue occluding the major left bronchus and carrying acid-fast bacilli, the patient had a left pneumonectomy when she was 8 years old. An impaired immune response was suspected and a partial innate interferon- γ (IFN) receptor R1 defect was detected by molecular analysis. At the age of 12, the patient developed right supraclavicular and left mammary masses and a lacrimal gland infiltration. Incision and drainage showed caseous degeneration and acid-fast bacilli in the specimen. Rifabutin 300 mg once a day and pain therapy were started and lasted for 18 years till she was admitted to our Unit. The patient received the therapy with excellent adherence and without side effects.

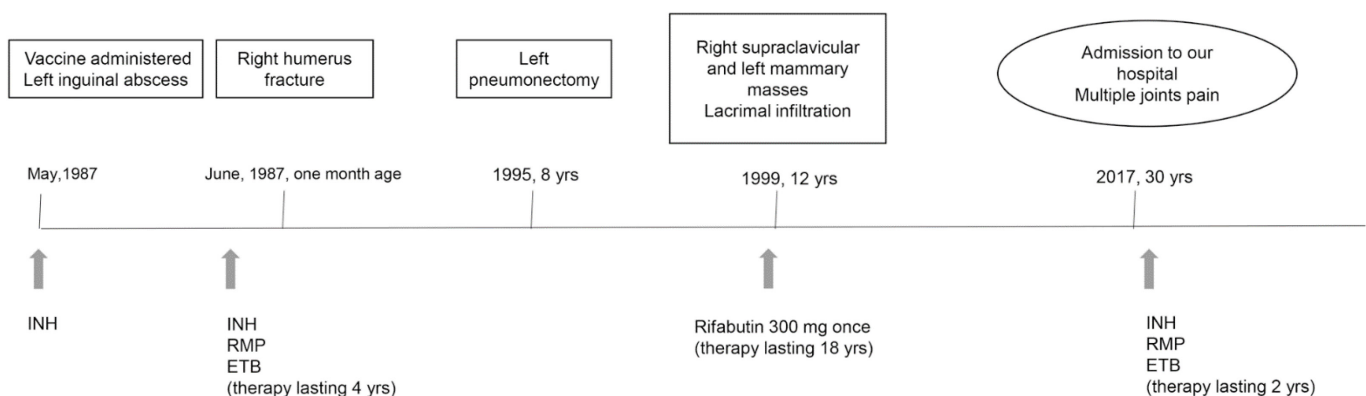
At the age of 30 when she was admitted to our Unit, the patient was afebrile and complained of pain in multiple joints. Magnetic resonance imaging (MRI) showed a bone marrow oedema, bone expansion, lytic areas and periosteal reaction of the right wrist. Computed tomography (CT) scan showed lytic bone

lesions, interesting right humerus distal epiphysis and carpus bilaterally. Quantiferon TB Gold was negative. There was no growth in three sputum samples and three urine cultures. An 8-fluorine fluorodeoxyglucose positron emission tomography combined with CT scan (18F-FDG PET/CT) confirmed a pattern of osteolytic lesions with high inflammatory activity. Treatment with isoniazid (300 mg once daily), rifampin (600 mg once daily) and ethambutol (1200 mg once daily) was started and continued for two months. Isoniazid and rifampin were continued for another two years. The patient improved, she didn't need pain therapy anymore, and a 18F-FDG PET/CT showed lower number of lesions of high intensity 18F-FDG uptake. However, because of her intricate history and the immune defect, the patient is still under observation at our outpatient clinic. Figure 1 shows a timeline of historical and current information from this case report.

Discussion

Inoculation with live BCG vaccine is harmless in most children although it occasionally leads to a benign regional adenitis [8]. The incidence of disseminated BCG infection is 0.5-2 cases per million vaccinated children [9]. Possible complications following BCG vaccination are more prevalent in the immunocompromised hosts [10-14]. IFN- γ R1 deficiency is an autosomal recessively inherited immunodeficiency characterized by predisposition to infections with intracellular pathogens, in particular mycobacteria [13-15]. BCG is also the gold-standard adjuvant treatment for urothelial cancer of the bladder. Immunotherapy with BCG is generally considered safe but post-instillation disease could occur and could be both localized and disseminated [16,17]. The prognosis appears to be worst after BCG vaccination, probably

Figure 1. Timeline of historical and current information from this case report.



INH: isoniazid; RMP: rifampin; ETB: ethambutol; yrs: years.

because of the higher virulence of BCG as compared with most atypical mycobacteria, the higher number of infecting BCG organisms, or the direct intradermal inoculation of BCG as opposed to natural routes of infection with atypical mycobacteria [18]. The association between susceptibility to infection and IFN- γ receptor defects was first described by Kamijo *et al.* [19] who inoculated IFN- γ receptor-deficient mice with BCG. They observed the inability of these mice to produce tumor necrosis factor α (TNF- α), IL-1 α , and IL-6 after the infection. In addition, these mice did not develop well-defined granulomas and were unable to kill mycobacteria [19].

Mycobacteria live and multiply within macrophages. When macrophages recognize mycobacterial pathogen-associated molecular patterns through their Toll-like receptors (TLRs), they trigger production of different cytokines. IL-12 secretion has a crucial role in host defense against mycobacteria. IL12 is produced by macrophages after endocytosis of mycobacteria and induces activation and differentiation of T cells into T-helper 1 subpopulations and CD8+, which, in turn, secrete IFN- γ . IFN- γ binds to subunit 1 (R1) of its receptor, and, after recruitment of subunit 2 (R2), starts the signaling via Jak/signal transducer and activator of transcription 1 (STAT1). STAT1 induces the production of reactive nitrogen intermediates (RNI) and tumor necrosis factor alpha (TNF- α), which are crucial for control of acute tuberculosis. Therefore, the absence of R1 in macrophage prevents the RNI and TNF- α production [20].

Jouanguy *et al.* reported a case of disseminated infection caused by the BCG strain. The analysis of the gene encoding IFN- γ R1 showed existence of a mutation, which resulted in the elimination of nucleotide 131 (C) in exon 2 and formation of a premature stop codon [18]. Two other mutations were subsequently described: a mutation which consists of a replacement of adenine for cytosine located at position 395 and causing a premature stop codon in the sequence of IFN- γ R1 [21] and a deletion of 4 nucleotides at 774 (774del4), resulting in generation of a premature stop codon [22]. The first mutation caused in 4 children from Malta a disseminated atypical mycobacterial infection; the second mutation was described in a Japanese girl who was vaccinated with BCG at 4 months of age. The patient developed regional lymph nodes inflammation two months after administration of the vaccine and a multifocal osteomyelitis at 12 years of age. Currently, twenty-seven unique mutations causing complete IFN- γ R1 deficiency have been identified. These are all small variations, and the largest deletion is only 22

nucleotides long. However, a large genomic deletion removing IFN- γ R1 entirely and causing complete IFN- γ R1 deficiency in three related patients has been recently described [21]. All but one patient developed mycobacterial infection [23].

BCG post-vaccination-disease in pediatric patient can onset weeks or months after the vaccination with various patterns classified in regional (persistent ulcer, abscess, fistula, or lymphadenopathy limited to the region of inoculation), extra-regional (osteitis or cutaneous abscess) and disseminated disease. Our patient presented only a localized form at the beginning but later developed a disseminated disease involving lungs and skeleton because she suffered from an innate defect of IFN- γ R1 with autosomal recessive inheritance. In our case, the dissemination of infection was evidenced by the isolation of BCG strain from different body parts. Complete IFN- γ R1 deficiency predispose individuals to overwhelming infection in early childhood, which may respond to antibiotics but relapse when antibiotics are discontinued [13].

So far, the multi-drug treatment has been successful, and the patient has reported no side effects two years after finishing treatment. Because complete recovery from disseminated BCG is improbable, the patient is currently being monitored at our outpatient clinic and may be referred for a hematological evaluation if symptoms return. The existence of different BCG strains has been described since the 1940s. Different BCG vaccine strains have evolved throughout time and differ from the first BCG introduced in 1921. These strains vary based on several laboratory properties, which may or may not translate into a discernible effect on vaccination, on safety, and more specifically on the rate of BCG dissemination. Unfortunately, we do not have information on the BCG strain administered to our patient, therefore we are not able to correlate the responsible strain to severity of clinical manifestations identified [24, 25]. In any case, rapid discrimination between complete IFN- γ R1 deficiency and other defects is an important diagnostic step for planning clinical management.

Underlying deficiencies and history of recurrent infections should be carefully evaluated and signs and symptoms must be sought before administering the vaccine. Neonatal BCG vaccine is included in many standard vaccination schedules around the world and we suggest that, depending on the epidemiological data in some clinical settings, postponing the BCG vaccination to a later time could help to avoid giving it to immunodeficient infants [26].

To summarize, in children with a history of BCG vaccination and chronic unexplained infections, a clinical suspicion of a BCG-related disease must arise, and a reason of immunodeficiency should be sought.

Conclusions

Several aspects related to cardiovascular risk factors were found to move in a negative direction during the lockdown period, including physical activity, changes in weight, and inadequate blood pressure control. A substantial portion of patients also failed to attend their follow-up visits and reported a worsening of cardiovascular symptoms. However, this study is a survey in only a single center. In the future, it is necessary to conduct surveys with larger number of patients with a larger scope in order to fully understand the effects of lockdown on patients with chronic underlying cardiovascular diseases in middle-income countries such as Vietnam.

Acknowledgements

The authors declare that they have not received substantial contributions from non-authors and from any sponsor. Patient gave her consent for her clinical information to be reported in the journal.

Authors' contributions

All the authors contributed equally towards this research and manuscript.

References

- World Health Organization (WHO) (2020) Global tuberculosis report. Available: <https://www.who.int/publications-detail-redirect/9789241565714>. Accessed: 15 January 2021.
- Colomba C, Rubino R, Mantia G, Guida Marascia F, Abbott M, Gizzi A, Anastasia A, Palermo G, Cascio A (2021) Clinical use of BCG and its complications: a case series. *Infez Med* 29: 123-129.
- Begun M, Newal AT, Marks GB, Wood JG (2013) Contact tracing of tuberculosis: a systematic review of transmission modelling studies. *PLoS ONE* 8: 72470.
- Kasaie P, Andrews JR, Kelton WD, Dowdy DW (2014) Timing of tuberculosis transmission and the impact of household contact tracing. An agent-based simulation model. *Am J Respir Crit Care Med* 189: 845-852.
- Fox GJ, Barry SE, Britton WJ, Marks GB (2013) Contact investigation for tuberculosis: a systematic review and meta-analysis. *Eur Respir J* 41: 140-156.
- Hassanzad M, Valinejadi A, Darougar S, Hashemitari SK, Velayati AA (2019) Disseminated bacille Calmette-Guérin infection at a glance: a mini review of the literature. *Adv Respir Med* 87: 239-242.
- Amanati A, Pouladfar G, Kadivar MR, Dashti AS, Jafarpour Z, Haghpanah S, Alborzi A (2017) A 25-year surveillance of disseminated bacillus Calmette-Guérin disease treatment in children in southern Iran. *Medicine* 96: 9035.
- Lotte A, Wasz-Höckert O, Poisson N, Dumitrescu N, Verron M, Couvet E (1984) BCG complications: estimates of the risks among vaccinated subjects and statistical analysis of their characteristics. *Adv Tuberc Res* 21: 107-193.
- Casanova JL, Blanche S, Emile JF, Jouanguy E, Lamhamedi S, Altare F, Stéphan JL, Bernaudin F, Bordigoni P, Turck D, Lachaux A, Albertini M, Bourrillon A, Dommergues JP, Pocard MA, Le Deist F, Gaillard JL, Griscelli C, Fischer A (1996) Idiopathic disseminated bacillus Calmette-Guérin infection: a French national retrospective study. *Pediatrics* 98: 774-778.
- Liberek A, Korzon M, Bernatowska E, Kurenko-Deptuch M, Rytlewski M (2006) Vaccination-related Mycobacterium bovis BCG infection. *Emerg Infect Dis* 12: 860-862.
- World Health Organization (WHO) (2018) BCG vaccine. Available: <http://www.who.int/biologicals/areas/vaccines/bcg/en/>. Accessed: 10 February 2021.
- Casanova JL, Jouanguy E, Lamhamedi S, Blanche S, Fischer A (1995) Immunological conditions of children with BCG disseminated infection. *Lancet* 346: 581.
- Remus N, Reichenbach J, Picard C, Rietschel C, Wood P, Lammas D, Kumararatne DS, Casanova JL (2001) Impaired interferon-gamma mediated immunity and susceptibility to mycobacterial infection in childhood. *Pediatr Res* 50: 8-13.
- Colomba C, Rubino R, Siracusa L, Lalicata F, Trizzino M, Titone L, Tolomeo M (2012) Disseminated tuberculosis in a patient treated with a JAK2 selective inhibitor: a case report. *BMC Res Notes* 5: 552.
- Ramirez-Alejo N, Santos-Argumedo L (2014) Innate defects of the IL12/IFN- γ axis in susceptibility to infections by Mycobacteria and Salmonella. *J Interferon Cytokine Res* 34: 307-317.
- Colomba C, Di Carlo P, Guadagnino G, Siracusa L, Trizzino M, Gioè C, Cascio A (2016) A case of epididymo-orchitis after intravesical bacille Calmette-Guérin therapy for superficial bladder carcinoma in a patient with latent tuberculosis infection. *Infect Agent Cancer* 11: 25.
- Liu Y, Lu J, Huang Yi, Ma L (2019) Clinical spectrum of complications induced by intravesical immunotherapy of bacillus Calmette-Guérin for bladder cancer. *J Oncol* 6230409.
- Jouanguy E, Altare F, Lamhamedi S, Revy P, Emile JF, Newport M, Levin M, Blanche S, Seboun E, Fischer A, Casanova JL (1996) Interferon-gamma-receptor deficiency in an infant with fatal bacille Calmette-Guérin infection. *N Engl J Med* 335: 1956-1961.
- Kamijo R, Le J, Shapiro D, Havell EA, Huang S, Aguet M, Bosland M, Vilcek J (1993) Mice that lack the interferon-gamma receptor have profoundly altered responses to infection with bacillus Calmette-Guérin and subsequent challenge with lipopolysaccharide. *J Exp Med* 178: 1435-1440.
- Flynn JL, Chan J (2001) Tuberculosis: latency and reactivation. *Infect Immun* 69: 4195-4201.
- Newport MJ, Huxley CM, Huston S, Hawrylowicz CM, Oostra BA, Williamson R, Levin M (1996) A mutation in the interferon-gamma-receptor gene and susceptibility to mycobacterial infection. *N Engl J Med* 335: 1941-1949.
- Okada S, Ishikawa N, Shirao K, Kawaguchi H, Tsumura M, Ohno Y, Yasunaga S, Ohtsubo M, Takihara Y, Kobayashi M (2007) The novel IFNGR1 mutation 774del4 produces a truncated form of interferon- γ receptor1 and has a dominant

- negative effect on interferon- γ signal transduction. *J Med Genet* 44: 485-491.
23. de Vor IC, van der Meulen PM, Bekker V, Verhard EM, Breuning MH, Harnisch E, van Tol MJD, Wieringa JW, van de Vosse E, Bredius RGM (2016) Deletion of the entire interferon- γ receptor 1 gene causing complete deficiency in three related patients. *J Clin Immunol* 36: 195–203.
 24. Behr MA (2002). BCG-different strains, different vaccines? *Lancet Infect Dis* 2: 86-92.
 25. Angelidou A, Conti M-G, Diray-Arce J, Benn CS, Shann F, Netea MG, Liu M, Potluri LP, Sanchez-Schmitz G, Husson R, Ozonoff A, Kampmann B, van Haren SD, Levy O (2020) Licensed Bacille Calmette-Guérin (BCG) formulations differ markedly in bacterial viability, RNA content and innate immune activation. *Vaccine* 38: 2229-2240.
 26. Alesa AA, Aljiffry HM, Alqurashi KA, Alghamdi KA, Batouk MA, Alesa AA (2018) Pediatric disseminated Bacillus Calmett-Guerin infection (BCGitis): a case report. *Egypt J Hosp Med* 70: 1149-1151.

Corresponding author

Raffaella Rubino, MD

Department of Health Promotion, Mother and Child Care, Internal Medicine and Medical Specialties, University of Palermo - AOUP P. Giaccone, via del Vespro 129 90127 Palermo, Italy

Phone: 3388049857, +390916554011

Fax: 0918773286

Email: raffaellarubino@libero.it

Conflict of interests: No conflict of interests is declared.