Brief Reports

Journal of Public Health Research

Journal of Public Health Research
2022, Vol. 11(4), 1–9

DOI: 10.1177/2279903622133234
journals.sagepub.com/home/phj
SAGE

The Great pretender: the first case of septic shock due to Capnocytophaga canimorsus in Sardinia. A Case report and review of the literature

Salvatore Sardo[1], Claudia Pes[1], Andrea Corona[2], Giulia Laconi[3], Claudia Crociani[4], Pietro Caddori[5], Maria Luisa Boi[5] and Gabriele Finco[1]

Abstract

Capnocytophaga canimorsus (C. canimorsus) is an emerging pathogen in critical care. C. canimorsus is a Gram-negative bacillus, commonly isolated as a commensal microorganism of the oral flora of healthy dogs and cats. A 63-year-old woman came to the emergency department with fever, chills, and malaise 2 days after a minor dog bite. After admission to the medicine ward, she developed respiratory failure and livedo reticularis. In the intensive care unit (ICU), she presented full-blown septic shock with thrombocytopenia, coagulopathy, severe acute kidney injury, and liver injury. We describe the first case of septic shock with Multiple Organ Dysfunction Syndrome related to Capnocytophaga canimorsus infection in Sardinia and its treatment in a tertiary hospital ICU. We also review recent literature on the relevance of C. canimorsus in human disease and critical illness.

Keywords

Capnocytophaga, septic shock, acute kidney injury, renal replacement therapy, Zoonosis, case report, ischemia

Date received: 12 June 2022; accepted: 29 September 2022

Introduction

In 1976 Bobo and Newton published a case report describing the isolation of a new Gram-negative bacillus in a cerebrospinal fluid sample from a man who developed meningitis and sepsis after bites of dogs.[1] A subsequent report of 17 cases confirmed the causative role of this Gram-negative rod in human disease.[2] Due to its slow growth, the United States Centers for Disease Control and Prevention (CDC) classified it in group DF-2 as a "dysgonic fermenter." In 1989 Brenner et al. proposed to reclassify the DF-2 group as a new species called *Capnocytophaga canimorsus*.[3] This suggestive name refers to the specific requirement of a carbon dioxide-enriched environment for growth and its main way of transmission in human disease, that is, dog bite.[3]

After these case reports, Capnocytophaga canimorsus has been recognized as an uncommon but increasingly significant pathogen associated with severe sepsis and septic shock.

We present the first case of septic shock related to Capnocytophaga canimorsus in Sardinia and its

[1]Department of Medical Sciences and Public Health, University of Cagliari, Monserrato, Italy
[2]Kantonsspital Graubünden, 7000 Chur, Department ANIR, Intensivmedizin, Switzerland
[3]Anesthesia and Intensive Care Service, Emergency Department, Azienda Ospedaliero Universitaria di Ferrara, Cona FE, Italy
[4]Azienda Ospedaliera Brotzu, San Michele Hospital, Microbiology, Piazzale Alessandro Ricchi, Cagliari, Italy
[5]Azienda Ospedaliera Brotzu, San Michele Hospital, Intensive Care Unit, Piazzale Alessandro Ricchi, Cagliari, Italy

Corresponding author:
Salvatore Sardo, Department of Medical Sciences and Public Health, University of Cagliari, S.S. 554 Km 4,500, Monserrato 09042, Italy.
Email: salvatore.sardo@unica.it

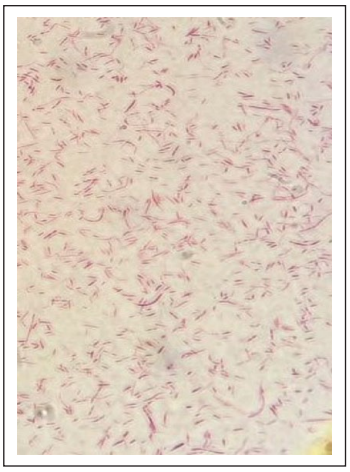

Figure 1. Direct Gram stain of blood culture. This picture shows the Gram-negative slender rods isolated from our patient culture bottle.

management in a tertiary hospital intensive care unit (ICU) and review the recent literature on the pathogenesis and critical illness caused by C. canimorsus.

Case report

A 63-year-old woman came to the emergency department with a chief complaint of acute onset fever (tympanic temperature 39.9°C) with chills and malaise. She was beclouded and tachypnoeic. Her history was notable for cigarette smoking and a previous breast cancer resection.

She suffered a recent dog hand bite 2 days before presentation. Laboratory values at arrival showed: creatinine 1.22 mg/dl, lactate dehydrogenase (LDH) 298, AST 115, ALT 54 U/l, hyponatremia 130 mmol/l, hyposmolality 265 mOsm/kg, PaO_2/FiO_2 ratio (P/F) 246 mmHg. Computerized tomography showed bilateral basal hyperdensities of the lungs. Two sets of peripheral blood were collected for microbiological diagnosis.

She was admitted to the medicine department with a diagnosis of pneumonia and began empirical antibiotic therapy with levofloxacin (Sequential Organ Failure Assessment Score, SOFA 5).

The following day, she developed thrombocytopenia, acute kidney injury (AKI), livedo reticularis, arterial hypotension, and acute hypoxemic respiratory failure with high serum procalcitonin (79.7 ng/ml). The Gram staining of the blood culture showed thin and slender Gram-negative rods, so she started an empirical course of meropenem (Figure 1). The patient was admitted to the ICU and intubated. Her condition rapidly worsened to full-blown septic shock (SOFA 21) with severe lactic acidosis (pH 6.7, lactate 17 mmol/l). She required high-dose inotropic support (norepinephrine 0.5–1 μg/kg/min) and continuous mandatory mechanical ventilation (P/F 90). She was also administered hydrocortisone 200 mg/die. Her AKI stage was 3 according to Kidney Disease: Improving Global Outcomes classification due to anuria and a serum creatinine of 3.91 mg/dl, so she underwent renal replacement therapy using continuous venovenous hemodialysis (CVVHD) with a high cutoff and high flux hemofilter (Ultraflux EMiC2, Fresenius, Germany) under citrate anticoagulation. After 72 h, this strategy improved hemodynamics, gas exchange, and level of consciousness.

On the fourth day of ICU stay, she developed rhabdomyolysis and liver injury (Figure 2). Severe thrombocytopenia (Figure 2) and coagulopathy required fresh frozen plasma and platelet transfusion under thromboelastographic guidance. Livedo reticularis worsened to a frank purpura, with ischemia of the limbs (Figure 3).

The microbiological diagnosis of this case began with the analysis of blood cultures using the automated BacT / ALERT system (bioMérieux, Marcy l'Etoile, France).

A sample of blood was then plated on blood agar and chocolate agar. After 1 week, the culture became positive. A sample from a direct smear of bacterial colonies was then analyzed by the MALDI Biotyper (Bruker, Germany). The MALDI biotyper provided a specific proteomic spectrum fingerprint for C. canimorsus. On the seventh day, she started ampicillin-sulbactam and ceftriaxone. After the resolution of the critical illness, we received the antibiogram. The isolated strain was sensitive to amoxicillin with clavulanic acid, ticarcillin with clavulanic acid, piperacillin, imipenem, cefoxitin, moxifloxacin, rifampin, chloramphenicol, while it was resistant to penicillin G, amoxicillin, clindamycin, vancomycin, metronidazole.

After 2 weeks of stay in the ICU, she was transferred to a facility near her hometown, where she underwent surgical amputation of her finger in the hand, ie, the site of the dog bite, and both inferior limbs below the knees. Eight months after her critical illness, she still required intermittent hemodialysis for end-stage renal disease.

The microbiological diagnosis of this case began with the analysis of blood cultures using the automated BacT/ ALERT system (bioMérieux, Marcy l'Etoile, France).

A sample of blood was then plated on blood agar and chocolate agar. After 1 week, the culture became positive. A sample from a direct smear of bacterial colonies was then analyzed by the MALDI Biotyper (Bruker, Germany). The MALDI Biotyper provided a specific proteomic spectrum fingerprint for C. canimorsus.

Review of the literature

We searched the MEDLINE® database using the medical subject headings term Capnocytophaga to retrieve pertinent studies on the microbiology, pathogenesis, and clinical manifestation of C. canimorsus in human patients. We did not enforce any language restriction. The genus Capnocytophaga was originally isolated from the human oral cavity and is made of Gram-negative, nonflagellated, fermentative, and capnophilic bacteria (5%–10% of carbon dioxide in growth medium) that exhibit glide motility.

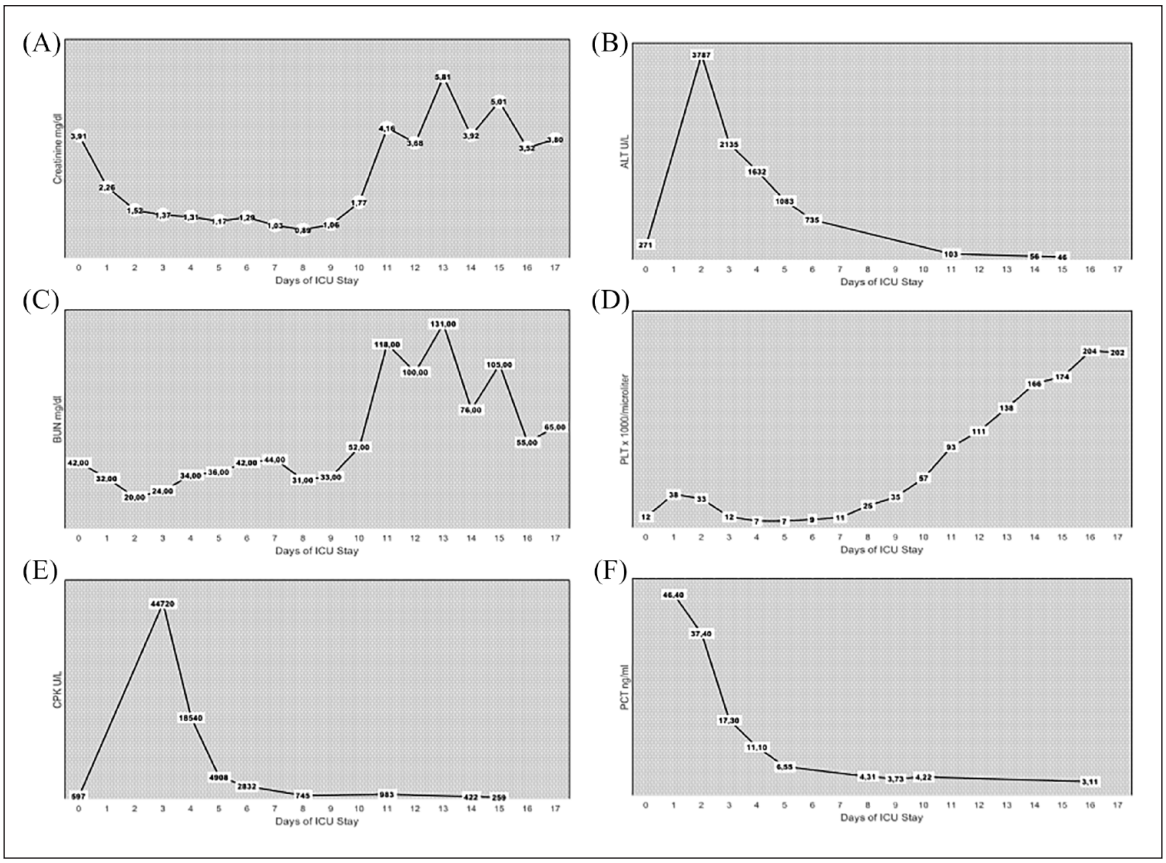

Figure 2. Main laboratory findings during ICU stay. This picture shows six plots that illustrate serum creatinine (panel A), serum alanine aminotransferase (panel B), blood urea nitrogen (panel C), platelets count (panel D), serum creatine phosphokinase (panel E), seru m procalcitonin (panel F) on the *y* axis and the day of ICU stay on the *x*-axis.
Abbreviations: ICU: Intensive Care Unit; mg: milligram; dl: deciliter; U: international units; L: liter; ng: nanograms.

C. canimorsus appear as long, thin, filamentous, spindle-shaped cells in blood Agar plates.[3]

It is a common commensal species of the oral flora of dogs and cats and can be isolated in 21%–73% of oropharyngeal swabs from dogs.[4,5]

C. canimorsus feeds on N-acetyl glucosamine and N-acetyl galactosamine from host cell glycoproteins (epithelial and macrophage cells), and the presence of macrophages increases bacterial growth.[6–8] The same surface N-glycan glycoprotein deglycosylation complex can also deglycosilate human immunoglobulin G (IgG) and modify the affinity of IgG for its Fc receptor.[8,9]

C. canimorsus can also prevent effective secretion of pro-inflammatory cytokines such as nitric oxide, IL-1 α, IL-6, or TNFα, maybe through active production of a factor capable of complete dephosphorylation of the p38 mitogen-activated protein kinase and a peculiar lipopolysaccharide structure.[8,10]

Evidence of resistance to phagocytic killing and feeding on macrophage glycoproteins may represent an essential factor not only for commensalism, but also for pathogenesis.[6,8]

Host factors can determine the vulnerability to C. canimorsus infection, such as asplenia, hyposplenism, alcohol abuse, and malignancy, supported by the disproportionately low incidence of C. canimorsus sepsis despite widespread exposure to dog or cat saliva in the general population.[11]

Butler's comprehensive review included all microbiologically confirmed cases of C. canimorsus infection and an estimated 484 clinical cases with a lethality rate of 26%.[11]

The same review listed 30 cases of septic shock and 18 cases of digital or limb gangrene in the period.[11]

In Supplemental Table and Figure 4 we summarized (1990–2022, up to April 25, 2022) case reports and case series describing C. canimorsus infection in human patients, with a focus on clinical course, outcome, organ failure, risk factors for C. canimorsus infection (i.e. bites, scratching, or close contacts with dogs or cats), immunosuppressed status (i.e. alcohol abuse, asplenia, corticosteroid therapy, methotrexate, immunosuppression malignancy).

In the period 1990–2022, 125 articles described 207 cases of C. canimorsus infection (Supplemental Table).[12–137]

Forty-seven studies described 73 cases of severe sepsis or septic shock, with 31% case fatality (see Supplemental Table). Despite the importance of risk factors for the development of severe C. canimorsus infection, 33 patients were not immunocompromised.

Treatment of organ failures was not always described in detail in case reports, probably for editorial reasons and

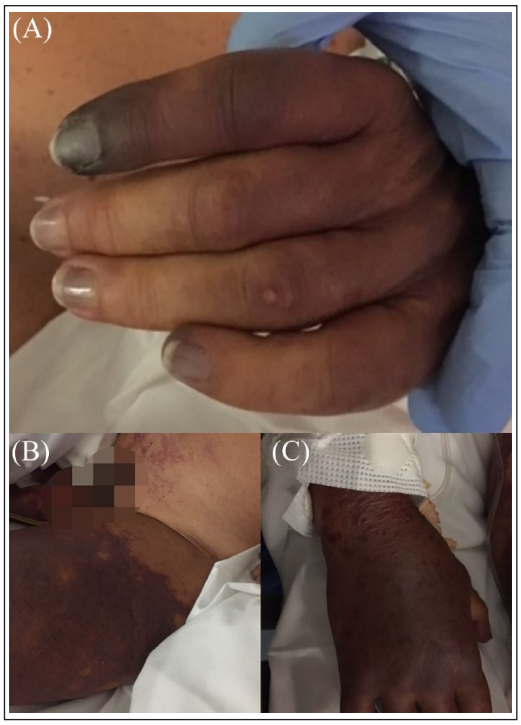

Figure 3. Physical findings. This picture shows the purpuric skin lesions in different anatomic locations: left hand (panel A), thighs (panel B), right hand (panel C).

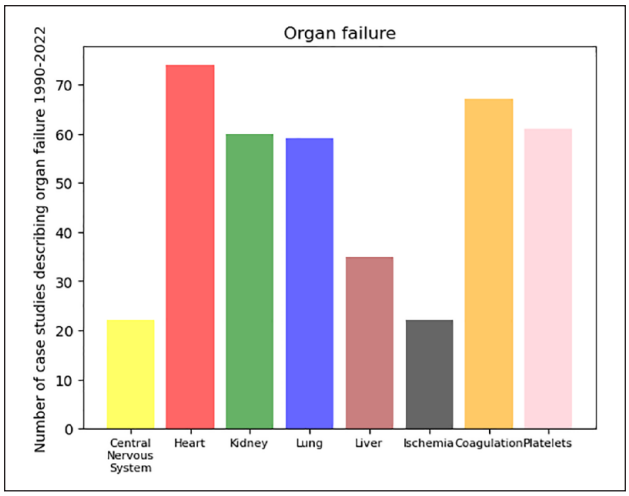

Figure 4. Bar chart of organ failures described in published case reports and series. This graph shows how many papers described each type of organ injury or failure.

also because some patients died briefly after the first clinical manifestations of infection.[57,63,78,90,91]

Furthermore, septic shock from C. canimorsus does not appear to require other specific treatments than those reported in current septic shock guidelines.

The most severe cases showed a high prevalence of acute kidney injury (60 reports). Renal replacement therapy was the most described therapy.[52,55,67,70,80,89]

Feige et al. reported the use of renal replacement therapy with regional anticoagulation, to manage the rapid development of severe AKI with significant metabolic derangement, hemodynamic instability, and coagulopathy.[89]

Coagulopathy is common in the setting of severe sepsis or septic shock of C. canimorsus (67 reports).

Furthermore, two case reports described the atypical hemolytic uremic syndrome and the Shwartzman reaction related to septic shock of C. canimorsus with their specific treatments, eculizumab (humanized monoclonal IgG anti-C5), and nebacumab (antilipid A IgG), respectively.[55,80]

Irreversible limb or digit ischemia was described in association with severe sepsis or septic shock (22 reports), suggesting significant microcirculation injury as one of the main pathophysiological mechanisms of systemic C. canimorsus infection.

We suppose that the published literature provided an underestimation of the relevance of this pathogen, due to its difficult microbiological diagnosis and fulminant course in the most severe cases, which can misleadingly suggest a more common etiologic agent, such as Neisseria meningitidis. The published literature offers some descriptions of purulent cases of meningitis caused by C. canimorsus, whose identification was possible by broad-range polymerase chain reaction (PCR) of cerebrospinal fluid (CSF) or 16S ribosomal RNA amplification from blood and CSF samples[72,128,138]

Capnocytophaga canimorsus is a rare cause of endocarditis and it is particularly rare in immunocompetent hosts.[85,92,122] These cases of endocarditis share a common factor: the difficult process of microorganism isolation that occurred after many blood cultures or after PCR analysis of valvular tissue.

C. canimorsus infection can cause direct macrovascular damage, including single or multiple mycotic aneurysms.[69,109,124,139] These aneurysms may present with rupture and hemodynamic instability or have a quite indolent course, resolving after surgical, and antibiotic treatment.

C. canimorsus infection may also display nonspecific skin changes, such as multiple erythematous macules, erythema annulare centrifugum, or urticaria.[111,127]

C. canimorsus has also been isolated in conjunction with Severe acute respiratory syndrome coronavirus 2 (SARS-CoV-2) infection.[110,126]

These case studies are important reminders to consider co-infection or super-infection by less common pathogens in patients with coronavirus disease 2019 (Covid-19). Furthermore, in the pandemic era, the diagnosis of SARS-CoV-2 infection is straightforward and has important consequences, such as that it may prompt significant changes in allocation and management, such as isolation wards and immunomodulatory therapies.

In this setting, the diagnosis of Covid-19 may overshadow rarer infections, including C. canimorsus.

As a confirmation of this, a case of C- canimorsus fulminant septic shock in a SARS-CoV-2 positive patient was diagnosed postmortem.[126]

Conclusions

The case we presented is the first description of a septic shock with multiple organ dysfunction syndrome in an immunocompetent patient caused by C. canimorsus in Sardinia.

According to the data presented, both healthy and immunosuppressed hosts can rapidly develop a severe septic syndrome characterized by a high incidence of AKI, coagulopathy, and cardiovascular instability. C. canimorsus infection should always be suspected in the differential diagnosis of Gram-negative sepsis, and risk factors, such as immunocompromised status and exposure to pets, should not be overlooked. Despite the absence of a specific therapy or the limited relevance of antibiotic resistance in C. canimorsus, the clinical suspect of this infection must induce to treat aggressively in the ICU due to its rapid course. According to our experience and the published literature, the most alarming signs, such as purpura, rapid worsening of respiratory and renal failure, should be interpreted as the clinical manifestation of systemic microvascular damage due to C. canimorsus.

No other case report described the use of a high cutoff filter in septic shock from C. canimorsus, but in our experience, it could be the best option to address AKI and the accumulation of myoglobin, cytokines, and interleukins.[140,141] Considering the frequent occurrence of severe coagulopathy, we suggest early placement of a large-bore hemodialysis catheter in a compressible site.

Furthermore, we believe that a more widespread adoption of antibiotic prophylaxis after high-risk bite injuries could contribute significantly to reducing the incidence of C. canimorsus infection.

Our case report and review of the literature confirm the role of Capnocytophaga canimorsus as an emerging cause of septic shock and multiorgan failure. Our article aims to add a little piece to the enormous amount of collective experience on this increasingly important pathogen and to raise awareness of this uncommon species among intensivists. Given the proteiform manifestations of Capnocytophaga canimorsus, as demonstrated by the published literature, this pathogen should be on the differential diagnosis list of every clinician, even during the SARS-CoV-2 pandemic. This experience was so important to our group that we correctly identified a second case the following year, which resulted in an early diagnosis (data are not presented because we did not obtain patient consent to add this case to our report). Our take-home messages for intensivists are always suspect C. canimorsus in rapidly evolving sepsis/septic shock, proactively investigate its presence, and consider early renal replacement therapy, especially in those patients who show clinical signs of microvascular damage.

Authors' contributions

SS, designed the study, collected and managed the review data, wrote the original draft, reviewed and edited; CP, collected the review data, wrote the original draft, reviewed and edited; AC, collected the review data, wrote the original draft, reviewed and edited; GL, collected the review data, reviewed and edited; CC, reviewed and edited; PC, reviewed and edited; MLB reviewed and edited; GF, reviewed and edited.

Declaration of conflicting interests

The author(s) declared no potential conflicts of interest with respect to the research, authorship, and/or publication of this article.

Funding

The author(s) received no financial support for the research, authorship, and/or publication of this article.

Ethical approval

The authors declare that approval from a Human Research Ethics Committee was not required for this study. The patient and her relatives gave their consent to the publication of this case report. The authors sent them the manuscript draft and images to receive explicit approval before submission.

Significance for public health section

Capnocytophaga canimorsus is a rare cause of rapidly progressive septic shock with a significant derangement of the function of the main organs and tissue ischemia due to microcirculation obstruction. As this microorganism eludes traditional microbiologic investigations, it is of paramount importance to include this species in the differential diagnosis of overwhelming septic shock and meningitis, especially in patients with close contact with dogs and cats. The presentation of C. canimorsus septic shock might be easily confused with meningococcal septic shock. The case described in this report served as an important reminder to accelerate the correct diagnosis in a subsequent case of C. canimorsus shock admitted the following year to the same intensive care unit (case not described because the patient did not give consent).

ORCID iD

Salvatore Sardo https://orcid.org/0000-0001-7664-8928

References

1. Bobo RA and Newton EJ. A previously undescribed gram-negative bacillus causing septicemia and meningitis. *Am J Clin Pathol* 1976; 65: 564–569.
2. Butler T, Weaver RE, Ramani TK, et al. Unidentified gram-negative rod infection. A new disease of man. *Ann Intern Med* 1977; 86(1): 1–5.
3. Brenner DJ, Hollis DG, Fanning GR, et al, . Capnocytophaga canimorsus sp. nov. (formerly CDC group DF-2), a cause of septicemia following dog bite, and C. cynodegmi sp. nov., A cause of localized wound infection following dog bite. *J Clin Microbiol* 1989; 27: 231–235.
4. Dilegge SK, Edgcomb VP and Leadbetter ER. Presence of the oral bacterium Capnocytophaga canimorsus in the tooth plaque of canines. *Vet Microbiol* 2011; 149: 437–445.
5. van Dam AP, van Weert A, Harmanus C, et al. Molecular characterization of Capnocytophaga canimorsus and other canine Capnocytophaga spp. and assessment by PCR of their frequencies in dogs. *J Clin Microbiol* 2009; 47: 3218–3225.

6. Mally M, Shin H, Paroz C, et al. Capnocytophaga canimorsus: a human pathogen feeding at the surface of epithelial cells and phagocytes. *PLoS Pathog* 2008; 4: e1000164.
7. Manfredi P, Renzi F, Mally M, et al. The genome and surface proteome of Capnocytophaga canimorsus reveal a key role of glycan foraging systems in host glycoproteins deglycosylation. *Mol Microbiol* 2011; 81: 1050–1060.
8. Shin H, Mally M, Kuhn M, et al. Escape from immune surveillance by Capnocytophaga canimorsus. *J Infect Dis* 2007; 195: 375–386.
9. Ittig S, Lindner B, Stenta M, et al. The lipopolysaccharide from capnocytophaga canimorsus reveals an unexpected role of the core-oligosaccharide in MD-2 binding. *PLoS Pathog* 2012; 8: e1002667.
10. Zähringer U, Ittig S, Lindner B, et al. NMR-based structural analysis of the complete rough-type lipopolysaccharide isolated from Capnocytophaga canimorsus. *J Biol Chem* 2015; 290: 25273.
11. Butler T. Capnocytophaga canimorsus: an emerging cause of sepsis, meningitis, and post-splenectomy infection after dog bites. *Eur J Clin Microbiol Infect Dis* 2015; 34: 1271–1280.
12. Hantson P, Gautier PE, Vekemans MC, et al. Fatal Capnocytophaga canimorsus septicemia in a previously healthy woman. *Ann Emerg Med* 1991; 20: 93–94.
13. Scarlett JD, Williamson HG, Dadson PJ, et al. A syndrome resembling thrombotic thrombocytopenic purpura associated with Capnocytophaga canimorsus septicemia. *Am J Med* 1991; 90: 127–128.
14. Howell JM and Woodward GR. Precipitous hypotension in the emergency department caused by Capnocytophaga canimorsus sp nov sepsis. *Am J Emerg Med* 1990; 8: 312–314.
15. Evans RJ. DF2 septicaemia. *J R Soc Med* 1991; 84: 749–750.
16. Bateman JM, Rainford DJ and Masterton RG. Capnocytophaga canimorus infection and acute renal failure. *J Infect* 1992; 25: 112–114.
17. Malnick H, Adhami ZN and Galloway A. Isolation and identification of Capnocytophaga canimorsus (DF-2) from blood culture. *Lancet Lond Engl* 1991; 338: 384.
18. Gallen IW and Ispahani P. Fulminant Capnocytophaga canimorsus (DF-2) septicaemia. *Lancet Lond Engl* 1991; 337: 308.
19. Kullberg BJ, Westendorp RG, van't Wout JW, et al. Purpura fulminans and symmetrical peripheral gangrene caused by Capnocytophaga canimorsus (formerly DF-2) septicemia—a complication of dog bite. *Medicine* 1991; 70: 287–292.
20. Ndon JA. Capnocytophaga canimorsus septicemia caused by a dog bite in a hairy cell leukemia patient. *J Clin Microbiol* 1992; 30: 211–213.
21. Pletschette M, Köhl J, Kuipers J, et al. Opportunistic Capnocytophaga canimorsus infection. *Lancet Lond Engl* 1992; 339: 308.
22. Decoster H, Snoeck J and Pattyn S. Capnocytophaga canimorsus endocarditis. *Eur Heart J* 1992; 13: 140–142.
23. Blanchard G, Boulet E, Martres P, et al. Infections à capnocytophaga canimorsus : à propos de trois cas. *Médecine Mal Infect* 1996; 26: 596–598.
24. Mirza I, Wolk J, Toth L, et al. Waterhouse-Friderichsen syndrome secondary to Capnocytophaga canimorsus septicemia and demonstration of bacteremia by peripheral blood smear. *Arch Pathol Lab Med* 2000; 124: 859–863.
25. Rintala E, Kauppila M, Seppälä OP, et al. Protein C substitution in sepsis-associated purpura fulminans. *Crit Care Med* 2000; 28: 2373–2378.
26. Yu RK, Shepherd LE and Rapson DA. Capnocytophaga canimorsus, a potential emerging microorganism in splenectomized patients. *Br J Haematol* 2000; 109: 679.
27. Mulder AH, Gerlag PG, Verhoef LH, et al. Hemolytic uremic syndrome after capnocytophaga canimorsus (DF-2) septicemia. *Clin Nephrol* 2001; 55: 167–170.
28. Chodosh J. Cat's tooth keratitis: human corneal infection with Capnocytophaga canimorsus. *Cornea* 2001; 20: 661–663.
29. Papadaki TG, Moussaoui RE, van Ketel RJ, et al. Capnocytophaga canimorsus endogenous endophthalmitis in an immunocompetent host. *Br J Ophthalmol* 2008; 92: 1566–1567.
30. Macrea MM, McNamee M and Martin TJ. Acute onset of fever, chills, and lethargy in a 36-year-old woman. *Chest* 2008; 133: 1505–1507.
31. Coutance G, Labombarda F, Pellissier A, et al. Capnocytophaga canimorsus endocarditis with root abscess in a patient with a bicuspid aortic valve. *Heart Int* 2009; 4: e5.
32. Hayani O, Higginson LA, Toye B, et al. Man's best friend? Infective endocarditis due to Capnocytophaga canimorsus. *Can J Cardiol* 2009; 25: e130–e132.
33. Rossi P, Oger A, Bagneres D, et al. Capnocytophaga canimorsus septicaemia in an asplenic patient with systemic lupus erythematosus. *BMJ Case Rep* 2009; 2009: bcr0520091840–bcr0520091840.
34. Handrick W, Schwede I and Steffens U. [Fatal sepsis due to capnocytophaga canimorsus after dog bite]. *Med Klin Munich Ger* 2010; 105: 739–741.
35. Eefting M and Paardenkooper T. Capnocytophaga canimorsus sepsis. *Blood* 2010; 116: 1396.
36. Stiegler D, Gilbert JD, Warner MS, et al. Fatal dog bite in the absence of significant trauma: Capnocytophaga canimorsus infection and unexpected death. *Am J Forensic Med Pathol* 2010; 31: 198–199.
37. Kourelis T, Kannan S and Foley RJ. An unusual case of septic shock in a geriatric patient. *Conn Med* 2010; 74: 133–137.
38. Joshi M, Reddy S, Ryan C, et al. Septicemia due to Capnocytophaga canimorsus following dog bite in an elderly male. *Indian J Pathol Microbiol* 2011; 54: 368–370.
39. O'Rourke GA and Rothwell R. Capnocytophaga canimorsis a cause of septicaemia following a dog bite: a case review. *Aust Crit Care* 2011; 24: 93–99.
40. Hawkins J, Wilson A and McWilliams E. 'Biting the hand that feeds': fever and altered sensorium following a dog bite. *BMJ Case Rep* 2011; 2011. DOI: 10.1136/bcr.08.2010.3265
41. Band RA, Gaieski DF, Goyal M, et al. A 52-year-old man with malaise and a petechial rash. *J Emerg Med* 2011; 41: 39–42.

42. Brichacek M, Blake P and Kao R. Capnocytophaga canimorsus infection presenting with complete splenic infarction and thrombotic thrombocytopenic purpura: a case report. *BMC Res Notes* 2012; 5: 695.
43. Ganguli I, Pierce C, Sharpe B, et al. The hand that feeds you. *J Hosp Med* 2012; 7: 590–594.
44. Christiansen CB, Berg RM, Plovsing RR, et al. Two cases of infectious purpura fulminans and septic shock caused by Capnocytophaga canimorsus transmitted from dogs. *Scand J Infect Dis* 2012; 44: 635–639.
45. Matulionytė R, Lisauskienė I, Kėkštas G, et al. Two dog-related infections leading to death: overwhelming Capnocytophaga canimorsus sepsis in a patient with cystic echinococcosis. *Med Kaunas Lith* 2012; 48: 11–115.
46. Sacks R and Kerr K. A 42-year-old woman with septic shock: an unexpected source. *J Emerg Med* 2012; 42: 275–278.
47. Popiel KY and Vinh DC. 'Bobo-Newton syndrome': an unwanted gift from man's best friend. *Can J Infect Dis Med Microbiol J Can Mal Infect Microbiol Medicale* 2013; 24: 209–214.
48. Rougemont M, Ratib O, Wintsch J, et al. Capnocytophaga canimorsus prosthetic aortitis in an HIV-positive woman. *J Clin Microbiol* 2013; 51: 2769–2771.
49. Yamamoto U, Kunita M and Mohri M. Shock following a cat scratch. *BMJ Case Rep* 2013. DOI: 10.1136/bcr-2012-007892
50. Ma A and Goetz MB. Capnocytophaga canimorsus sepsis with associated thrombotic thrombocytopenic purpura. *Am J Med Sci* 2013; 345: 78–80.
51. Fent GJ, Kamaruddin H, Garg P, et al. Hypertensive emergency and type 2 myocardial infarction resulting from pheochromocytoma and concurrent capnocytophaga canimorsus infection. *Open Cardiovasc Med J* 2014; 8: 43–47.
52. Hloch O, Mokra D, Masopust J, et al. Antibiotic treatment following a dog bite in an immunocompromized patient in order to prevent Capnocytophaga canimorsus infection: a case report. *BMC Res Notes* 2014; 7: 432.
53. Tuuminen T, Viiri H and Vuorinen S. The Capnocytophaga canimorsus isolate that caused sepsis in an immunosufficient man was transmitted by the large pine weevil Hylobius abietis. *J Clin Microbiol* 2014; 52: 2716–2717.
54. Shahani L and Khardori N. Overwhelming Capnocytophaga canimorsus infection in a patient with asplenia. *BMJ Case Rep* 2014; 2014: bcr2013202768. DOI: 10.1136/bcr-2013-202768
55. Tan V and Schwartz JC. Renal failure due to Capnocytophaga canimorsus generalized Shwartzman reaction from a dog bite (DF-2 nephropathy). *Proc Bayl Univ Med Cent* 2014; 27: 139–140.
56. Chiappa V, Chang CY, Sellas MI, et al. Case records of the Massachusetts General Hospital. Case 10-2014. A 45-year-old man with a rash. *New Engl J Med* 2014; 370: 1238–1248.
57. Bastida MT, Valverde M, Smithson A, et al. [Fulminant sepsis due to Capnocytophaga canimorsus: diagnosis by matrix-assisted laser desorption/ionization-time of flight mass spectrometry]. *Med Clin* 2014; 142: 230–231.
58. Ugai T, Sugihara H, Nishida Y, et al. Capnocytophaga canimorsus sepsis following BMT in a patient with AML: possible association with functional asplenia. *Bone Marrow Transplant* 2014; 49: 153–154.
59. Sotiriou A, Sventzouri S, Nepka M, et al. Acute generalized livedo racemosa caused by Capnocytophaga canimorsus identified by MALDI-TOF MS. *Int J Infect Dis IJID* 2015; 33: 196–198.
60. Cooper JD, Dorion RP and Smith JL. A rare case of Waterhouse-Friderichsen syndrome caused by Capnocytophaga canimorsus in an immunocompetent patient. *Infection* 2015; 43: 599–602.
61. Nishioka H, Kozuki T and Kamei H. Capnocytophaga canimorsus bacteremia presenting with acute cholecystitis after a dog bite. *J Infect Chemother* 2015; 21: 215–217.
62. Joswig H, Gers B, Dollenmaier G, et al. A case of Capnocytophaga canimorsus sacral abscess in an immunocompetent patient. *Infection* 2015; 43: 217–221.
63. Kovalev DV, Putintsev VA, Bogomolov DV, et al. [Postmortem forensic medical diagnostics of fulminant sepsis caused by Gram-negative bacterium (Capnocitophaga canimorsus) following a dog bite]. *Sud Med Ekspert* 2015; 58: 49–51.
64. Dobosz P, Martyna D, Stefaniuk E, et al. [Severe sepsis after dog bite caused by Capnocytophaga canimorsus]. *Pol Merkur Lek Organ Pol Tow Lek* 2015; 39: 219–222.
65. Wilson JP, Kafetz K and Fink D. Lick of death: Capnocytophaga canimorsus is an important cause of sepsis in the elderly. *BMJ Case Rep* 2016; 2016. DOI: 10.1136/bcr-2016-215450
66. Hästbacka J, Hynninen M and Kolho E. Capnocytophaga canimorsus bacteremia: clinical features and outcomes from a Helsinki ICU cohort. *Acta Anaesthesiol Scand* 2016; 60: 1437–1443.
67. Maezawa S, Kudo D, Asanuma K, et al. Severe sepsis caused by *Capnocytophaga canimorsus*complicated by thrombotic microangiopathy in an immunocompetent patient. *Acute Med Surg* 2017; 4: 97–100.
68. Jordan CS, Miniter U, Yarbrough K, et al. Urticarial exanthem associated with Capnocytophaga canimorsus bacteremia after a dog bite. *JAAD Case Rep* 2016; 2: 98–101.
69. Evans TJ, Lyons OT, Brown A, et al. Mycotic aneurysm following a dog bite: the value of the clinical history and Molecular Diagnostics. *Ann Vasc Surg* 2016; 32: 130.e5–130.e7.
70. Dedy NJ, Coghill S, Chandrashekar NKS, et al. Capnocytophaga canimorsus sepsis following a minor dog bite to the Finger: case report. *J Hand Surg* 2016; 41: 81–84.
71. van Samkar A, Brouwer MC, Schultsz C, et al. *Capnocytophaga canimorsus*Meningitis: three cases and a review of the literature. *Zoonoses Public Health* 2016; 63: 442–448.
72. Beernink TM, Wever PC, Hermans MH, et al. Capnocytophaga canimorsus meningitis diagnosed by 16S rRNA PCR. *Pract Neurol* 2016; 16: 136–138.
73. Thommen F, Opota O, Greub G, et al. Capnocytophaga canimorsus endophthalmitis after cataract surgery linked to salivary dog-to-human transmission. *Retin Cases Brief Rep* 2020; 14: 183–186. DOI: 10.1097/ICB.0000000000000637
74. Tamura S, Koyama A, Yamashita Y, et al. Capnocytophaga canimorsus sepsis in a methotrexate-treated patient with rheumatoid arthritis. *IDCases* 2017; 10: 18–21.
75. Morandi EM, Pauzenberger R, Tasch C, et al. A small 'lick' will sink a great ship: fulminant septicaemia after

dog saliva wound treatment in an asplenic patient. *Int Wound J* 2017; 14: 1025–1028.
76. Orth M, Orth P and Anagnostakos K. Capnocytophaga canimorsus – An underestimated cause of periprosthetic joint infection? *Knee* 2017; 24: 876–881.
77. Brunet J, Lhermitte D, Seguin A, et al. [Capnocytophaga canimorsus: A cause of multi-organ failure accompanied by livedo]. *Med Mal Infect* 2017; 47: 370–373.
78. Taquin H, Roussel C, Roudière L, et al. Fatal infection caused by Capnocytophaga canimorsus. *Lancet Infect Dis* 2017; 17: 236.
79. Beltramone M, Moreau N and Martinez-Almoyna L. Capnocytophaga canimorsus, a rare cause of bacterial meningitis. *Rev Neurol (Paris)* 2017; 173: 74–75.
80. Sokol KA, Veluswamy RR, Zimmerman BS, et al. Atypical hemolytic uremic syndrome associated with Capnocytophaga canimorsus. *Am J Hematol* 2017; 92: 322.
81. El-Battrawy I, Ansari U, Behnes M, et al. Dyspnoe und Hautausschlag bei einem 49-jährigen Patienten. *Internist* 2017; 58: 282–286.
82. Salvisberg C, Bartkowicki W, Imschweiler T, et al. Knieprotheseninfekt mit Capnocytophaga canimorsus: Prothesenerhalt oder -wechsel? *Praxis* 2017; 106: 483–485.
83. Marmo M, Villani R, Di Minno RM, et al. Cave canem: HBO2 therapy efficacy on Capnocytophaga canimorsus infections: a case series. *Undersea Hyperb Med J Undersea Hyperb Med Soc Inc* 2017; 44: 179–186.
84. Taki M, Shimojima Y, Nogami A, et al. Sepsis caused by newly identified *Capnocytophaga canis* following cat bites: *C. canis* is the third candidate along with *C. canimorsus* and *C. cynodegmi* causing zoonotic infection. *Intern Med Tokyo Jpn* 2018; 57: 273–277.
85. Barry M. Double native valve infective endocarditis due to Capnocytophaga canimorsus: first reported case caused by a Lion Bite. *Case Rep Infect Dis* 2018; 2018: 4821939.
86. Bertin N, Brosolo G, Pistola F, et al. Capnocytophaga canimorsus: an emerging pathogen in immunocompetent patients-experience from an emergency department. *J Emerg Med* 2018; 54: 871–875. DOI: 10.1016/j.jemermed.2018.01.042
87. Hettiarachchi I, Parker S and Singh S. 'barely a scratch': Capnocytophaga canimorsus causing prosthetic hip joint infection following a dog scratch. *BMJ Case Rep* 2018; 2018: bcr-2017–221185.
88. Abreu-Salinas F, Castelló-Abietar C, Ameijide Sanluis E, et al. [Capnocytophaga canimorsus as a cause of sepsis and meningitis in immunosuppressed patient]. *Rev Espanola Quimioter Publicacion* 2018; 31: 70–71.
89. Feige K, Hartmann P and Lutz JT. [Fulminant sepsis after Capnocytophaga canimorsus infection]. *Anaesthesist* 2018; 67: 34–37.
90. Piccinelli G, Caccuri F, De Peri E, et al. Fulminant septic shock caused by Capnocytophaga canimorsus in Italy: case report. *Int J Infect Dis* 2018; 72: 3–5.
91. Vignon G, Combeau P, Violette J, et al. [A fatal septic shock due to Capnocytophaga canimorsus and review of literature]. *Rev Med Interne* 2018; 39: 820–823. DOI: 10.1016/j.revmed.2018.03.384
92. Jalava-Karvinen P, Grönroos JO, Tuunanen H, et al. *Capnocytophaga canimorsus*: a rare case of conservatively treated prosthetic valve endocarditis. *APMIS Acta Pathol Microbiol Immunol Scand* 2018; 126: 453–456.
93. Elliott J and Donaldson E. Acute cholecystitis secondary to dog bite. *Int J Surg Case Rep* 2019; 55: 230–232.
94. Tsutsumi R, Yoshida Y, Suzuki M, et al. Image Gallery: annular erythema related to Capnocytophaga canimorsus bacteraemia after a dog bite. *Br J Dermatol* 2018; 179: e196.
95. Mantovani E, Busani S, Biagioni E, et al. Purpura fulminans and septic shock due to Capnocytophaga canimorsus after Dog Bite: a case report and review of the literature. *Case Rep Crit Care* 2018; 2018: 7090268.
96. Smeets NJL, Fijnheer R, Sebastian S, et al. Secondary thrombotic microangiopathy with severely reduced ADAMTS13 activity in a patient with *Capnocytophaga canimorsus* sepsis: a case report. *Transfusion* 2018; 58: 2426–2429.
97. Cabrol M, Le Bars H, Bailly P, et al. [Capnocytophaga canimorsus bacterial meningitis]. *Med Mal Infect* 2018; 48: 419–421.
98. Cardoso RM, Rodrigues J, Garcia D, et al. Tricuspid valve endocarditis due to Capnocytophaga canimorsus. *BMJ Case Rep* 2019; 12: e233721.
99. Hopkins AM, Desravines N, Stringer EM, et al. Capnocytophaga bacteremia precipitating severe thrombocytopenia and preterm labor in an asplenic host. *Infect Dis Rep* 2019; 11: 8272.
100. Mader N, Lührs F, Herget-Rosenthal S, et al. Being Licked by a dog can Be fatal: capnocytophaga canimorsus sepsis with Purpura Fulminans in an immunocompetent man. *Eur J Case Rep Intern Med* 2019; 6: 1.
101. Sakai J, Imanaka K, Kodana M, et al. Infective endocarditis caused by Capnocytophaga canimorsus; a case report. *BMC Infect Dis* 2019; 19: 927.
102. Sabia L, Marchesini D, Pignataro G, et al. Beware of the dog – capnocytophga canimorsus septic shock: a case report. *Eur Rev Med Pharmacol Sci* 2019; 23: 7517–7518.
103. Bialasiewicz S, Duarte TPS, Nguyen SH, et al. Rapid diagnosis of Capnocytophaga canimorsus septic shock in an immunocompetent individual using real-time nanopore sequencing: a case report. *BMC Infect Dis* 2019; 19: 660.
104. Tani N, Nakamura K, Sumida K, et al. An immunocompetent case of *Capnocytophaga canimorsus* infection complicated by secondary thrombotic microangiopathy and disseminated intravascular coagulation. *Intern Med Tokyo Jpn* 2019; 58: 3479–3482.
105. Hundertmark M, Williams T, Vogel A, et al. Capnocytophaga canimorsus as cause of Fatal sepsis. *Case Rep Infect Dis* 2019; 2019: 3537507.
106. Tanabe K, Okamoto S, Hiramatsu Asano S, et al. Capnocytophaga canimorsus peritonitis diagnosed by mass spectrometry in a diabetic patient undergoing peritoneal dialysis: a case report. *BMC Nephrol* 2019; 20: 219.
107. Kelly BC, Constantinescu DS and Foster W. Capnocytophaga canimorsus periprosthetic joint infection in an immunocompetent patient: a case report. *Geriatr Orthop Surg Rehabil* 2019; 10: 2151459318825199.
108. Ahmad S, Yousaf A, Inayat F, et al. Capnocytophaga canimorsus-associated sepsis presenting as acute abdomen: do we need to think outside the box? *BMJ Case Rep* 2019; 12: e228167.

109. Barry I, Sieunarine K and Bond R. Ruptured mycotic common iliac aneurysm due to Capnocytophaga canimorsus, acquired from dog saliva: a case report. *Int J Surg Case Rep* 2021; 78: 12–15.
110. Wendt R, Schauff C and Lübbert C. An asplenic with life-threatening Capnocytophaga canimorsus sepsis. *IDCases* 2020; 21: e00828.
111. Klein C, Mahé A, Goussot R, et al. [Multiple erythema annulare centrif ugum associated with knee monoarthritis revealing capnocytophagacanimorsus infection]. *Ann Dermatol Venereol* 2020; 147: 373–376.
112. Prasil P, Ryskova L, Plisek S, et al. A rare case of purulent meningitis caused by Capnocytophaga canimorsus in the Czech Republic – case report and review of the literature. *BMC Infect Dis* 2020; 20: 100.
113. Ashley PA, Moreno DA and Yamashita SK. Capnocytophaga canimorsus aortitis in an immunocompetent host. *Hawaii J Health Soc Welf* 2020; 79: 324–325.
114. Knabl L, Mango M, Stögermüller B, et al. Cluedo – source identification in a case of septicemia fatality caused by Capnocytophaga canimorsus. *Eur Rev Med Pharmacol Sci* 2020; 24: 7151–7154.
115. Mori J, Oshima K and Tanimoto T. Cat rearing: A potential risk of fulminant sepsis caused by Capnocytophaga canimorsus in a hemodialysis patient. *Case Rep Nephrol Dial* 2020; 10: 51–56.
116. Woźniak P, Szymczak R and Piotrowska A. A case of fulminant sepsis caused by Capnocytophaga canimorsus after a dog bite. *IDCases* 2020; 21: e00798.
117. Bering J, Hartmann C, Asbury K, et al. Unexpected pathogen presenting with purulent meningitis. *BMJ Case Rep* 2020; 13: e231825.
118. Squire G and Hetherington S. First reported case of lead-related infective endocarditis secondary to Capnocytophaga canimorsus: 'Dog Scratch' endocarditis. *BMJ Case Rep* 2020; 13: e233783.
119. Igeta R, Hsu H-C, Suzuki M, et al. Compartment syndrome due to Capnocytophaga canimorsus infection: a case report. *Acute Med Surg* 2020; 7: e474.
120. Liapis K and Delimpasis S. Worth a careful look at the blood film. *Eur J Intern Med* 2020; 73: 94–95.
121. Sri A, Droscher E and De Palma R. Capnocytophaga canimorsus and infective endocarditis-making a dog's dinner of the aortic valve: a case report. *Eur Heart J Case Rep* 2021; 5: ytab278.
122. McNicol M, Yew P, Beattie G, et al. A case of Capnocytophaga canimorsus endocarditis in a non-immunosuppressed host: the value of 16S PCR for diagnosis. *Access Microbiol* 2021; 3: 000235.
123. Lindén S, Gilje P, Tham J, et al. Capnocytophaga canimorsus tricuspid valve endocarditis. *IDCases* 2021; 24: e01083.
124. Westenfield K, Glogoza M, Tierney D, et al. Mycotic aortic aneurysm due to Capnocytophaga species infection treated non-surgically. *IDCases* 2021; 25: e01235.
125. Ducours M, Leitao J, Puges M, et al. An infected arterial aneurysm and a dog bite: Think at Capnocytophaga canimorsus! *Infect Drug Resist* 2021; 14: 2397–2401.
126. Meyer EC, Alt-Epping S, Moerer O, et al. Fatal septic shock due to Capnocytophaga canimorsus bacteremia masquerading as COVID-19 pneumonia – a case report. *BMC Infect Dis* 2021; 21: 736.
127. Goetzinger JC, LaGrow AL, Shibib DR, et al. Capnocytophaga canimorsus bloodstream infection associated with an urticarial exanthem. *Case Rep Infect Dis* 2021; 2021: 9932170.
128. O'Riordan F, Ronayne A and Jackson A. Capnocytophaga canimorsus meningitis and bacteraemia without a dog bite in an immunocompetent individual. *BMJ Case Rep* 2021; 14: e242432.
129. Tsunoda H, Nomi H, Okada K, et al. Clinical course of Capnocytophaga canimorsus bacteremia from acute onset to life crisis. *Clin Case Rep* 2021; 9: 266–268.
130. Rizk M-A, Abourizk N, Gadhiya KP, et al. A bite so bad: septic shock due to Capnocytophaga canimorsus following a dog bite. *Cureus* 2021; 13: e14668.
131. Oliveira P, Figueiredo M, Paes de, Faria V, et al. Septic shock due to Capnocytophaga canimorsus infection in a splenectomized patient. *Cureus* 2021; 13: e13815.
132. Amacher SA, Søgaard KK, Nkoulou C, et al. Bilateral acute renal cortical necrosis after a dog bite: case report. *BMC Infect Dis* 2021; 21: 231.
133. Bjørkto MH, Barratt-Due A, Nordøy I, et al. The use of eculizumab in Capnocytophaga canimorsus associated thrombotic microangiopathy: a case report. *BMC Infect Dis* 2021; 21: 137.
134. Nakayama R, Miyamoto S, Tawara T, et al. *Capnocytophaga canimorsus* infection led to progressively fatal septic shock in an immunocompetent patient. *Acute Med Surg* 2022; 9: e738.
135. Nisi F, Dipasquale A, Costantini E, et al. Surviving Capnocytophaga canimorsus septic shock: intertwining a challenging diagnosis with prompt treatment. *Diagn Basel Switz* 2022; 12: 260.
136. Harrigan A, Murnaghan K and Robbins M. Double valve infective endocarditis due to Capnocytophaga canimorsus. *IDCases* 2022; 27: e01448.
137. El-Battrawy I, Ansari U, Behnes M, et al. [Dyspnea and skin rash in a 49-year-old male patient]. *Internist* 2017; 58: 282–286.
138. Gottwein J, Zbinden R, Maibach RC, et al. Etiologic diagnosis of Capnocytophaga canimorsus meningitis by broad-range PCR. *Eur J Clin Microbiol Infect Dis* 2006; 25: 132–134.
139. Tierney DM, Strauss LP and Sanchez JL. Capnocytophaga canimorsus mycotic abdominal aortic aneurysm: why the mailman is afraid of dogs. *J Clin Microbiol* 2006; 44: 649–651.
140. Haase M, Bellomo R, Morgera S, et al. High cut-off point membranes in septic acute renal failure: a systematic review. *Int J Artif Organs* 2007; 30: 1031–1041.
141. Naka T, Haase M and Bellomo R. 'Super high-flux' or 'high cut-off' hemofiltration and hemodialysis. *Contrib Nephrol* 2010; 166: 181–189.