

Endovascular and thoracoscopic treatment for post-lobectomy hemothorax

William Grossi, Pio Maniscalco*, Francesco Quarantotto and Giorgio Cavallesco

Department of General and Thoracic Surgery, Sant'Anna Hospital Ferrara, Ferrara, Italy

* Corresponding author. Istituto di Chirurgia Generale e Toracica, C.so Giovecca No. 203, via Ariano No. 51, 44100 Ferrara, Italy.
Tel: +39-0532-236256; fax: +39-0532-209819. e-mail: pioman@libero.it (P. Maniscalco).

Received 21 March 2011; received in revised form 23 March 2011; accepted 25 May 2011

Keywords: Embolization • Hemothorax • Lung cancer • Lobectomy • Debridement

A male patient underwent lobectomy and partial pleurectomy for non-small-cell lung cancer (NSCLC). After 30 days, chest computed tomography discovered a hemothorax secondary to

an intercostal artery leakage (Fig. 1). A thoracic aorta angiography revealed an intercostal pseudo-aneurysm treated successfully with embolization (Fig. 2(A) and (B)). We performed a successful thoracoscopic debridement.

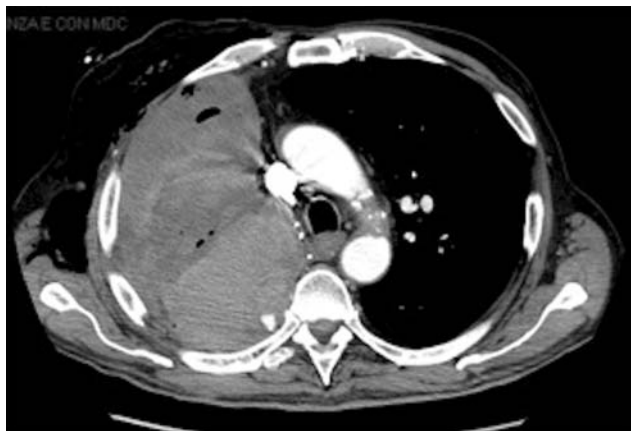

Figure 1: Chest CT performed for weakness, dyspnea and hemoglobin loss, shows the hemothorax due to the intercostal artery leakage. At discharge the thorax X-ray and the lab test did not show any acute bleeding sign.

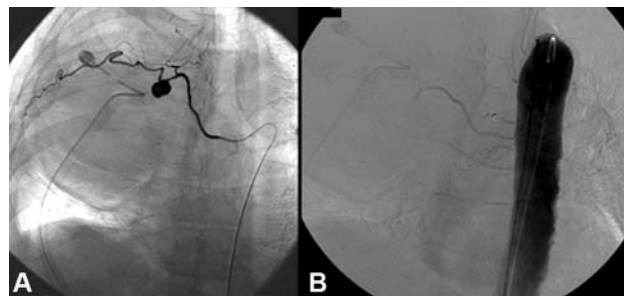


Figure 2. (A) Aortography shows the intercostal artery pseudo-aneurysm. (B) Intercostal artery pseudo-aneurysm superselective embolization with platinum coils (2.2 F).