

Quiz

A nose for trouble

A 63-year-old Caucasian non-smoker presented with purplish, firm, slowly growing plaques on the nose, of 20 years duration. The bigger one involved the upper part of the nose in its entirety [Figure 1], while there were smaller ones on the left and right cheek. All the plaques were asymptomatic and did not worsen after sunlight exposure. His past medical history was unremarkable. Hematological and biochemical parameters were within normal limits. Histological

examination revealed a diffuse mid-dermal cellular infiltrate composed of neutrophils, eosinophils, plasma cells, and lymphocytes. A narrow Grenz zone was present. In the lower part of the reticular dermis, the mixed infiltrate was intermingled with a massive deposition of fascicled pattern collagen fibers and spindle cells [Figures 2 and 3].

WHAT IS YOUR DIAGNOSIS?

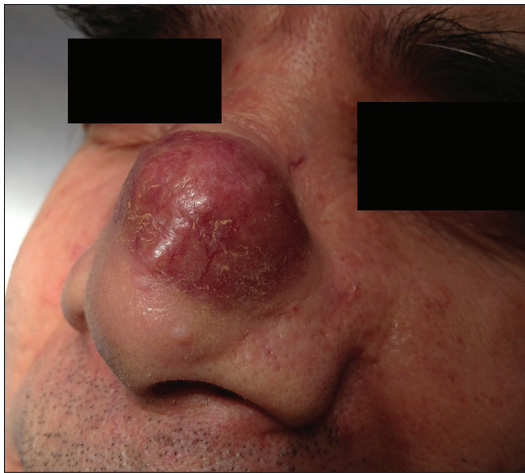


Figure 1: Erythematous indurated plaque of the upper nose

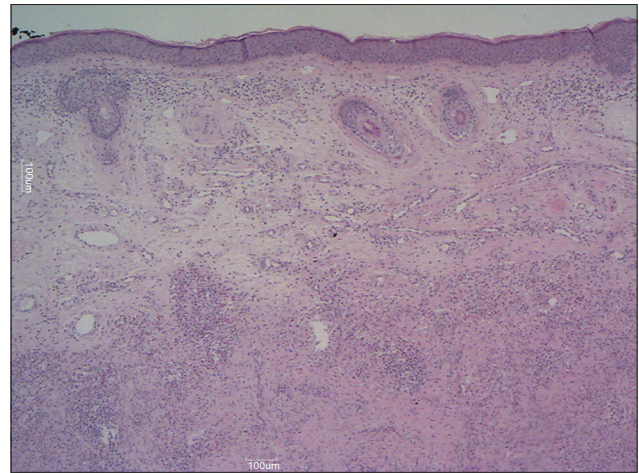


Figure 2: A narrow Grenz zone and superficial and deep infiltrates are noted. (H and E, x4)

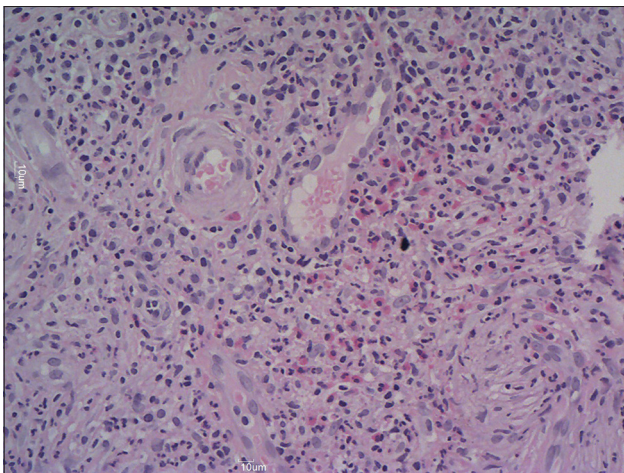


Figure 3: The infiltrate shows many eosinophils along with neutrophils, lymphocytes and plasma cells. Fascicles of spindle cells are also seen. (H and E, x40)

How to cite this article: Fumo G, Patta F, Milo C, Pilloni L, Atzori L. A nose for trouble. *Indian J Dermatol Venereol Leprol* 2015;81:93-4.

Received: January, 2014. **Accepted:** September, 2014. **Source of Support:** Nil. **Conflict of Interest:** None declared.

ANSWER

Diagnosis

Granuloma faciale

DISCUSSION

Granuloma faciale is an uncommon, benign, chronic inflammatory skin disease. It is characterized by recurrent erythematous papules, which evolve to nodules and/or plaques.^[1] Over 90% of the cases occur in middle-aged Caucasians, with the face being typically the site of onset. Multiple lesions develop in up to a third of patients, while extrafacial involvement occasionally occurs, usually several months to years after the onset.^[2]

The aetiology is unknown, although different predisposing factors have been postulated, including radiation, trauma, and allergy.^[1] The histopathology is diagnostic and shows a dense mid-dermal cellular infiltrate rich in eosinophils, with a sub-epidermal Grenz zone, leukocytoclastic vasculitis, and fibrosis.^[3] The name of the disease was proposed by Pinkus, although it was first described by Lever and Leeper in 1950.^[1] Histologically, there is no granulomatous inflammation, thus the term is actually a misnomer. The differential diagnosis includes discoid lupus erythematosus, deep mycotic infections, sarcoidosis, lymphoma, and fixed drug eruption.^[4]

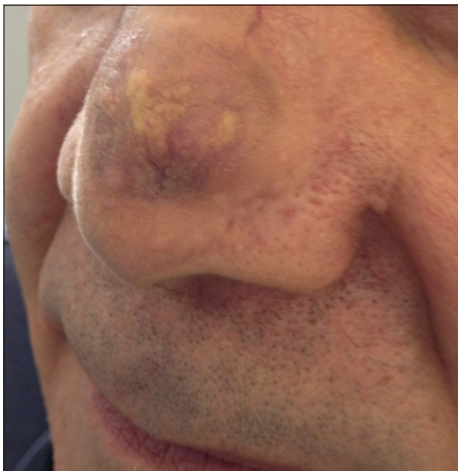

Figure 4: After the treatment with intralesional corticosteroid therapy

Numerous therapies have been tried for granuloma faciale, such as dapsone, several immunosuppressive drugs, topical calcineurin inhibitors, dye lasers, surgical excision,^[4] topical psoralen and UVA,^[5] and intralesional corticosteroid injection, alone or combined with cryotherapy.^[6] However, granuloma faciale is notoriously resistant to therapy and has a high rate of relapse. In our patient, therapy with dapsone, 100 mg a day for 6 months, and tacrolimus ointment 0.1%, twice daily for 2 months, had failed. Intralesional steroid injection of betamethasone at a dosage of 6 mg every 2 weeks for 2 months caused the lesion to regress with acceptable cosmetic improvement and without significant side effects [Figure 4]. No relapses occurred during a follow-up period of 2 years.

**Giuseppe Fumo, Federico Patta, Carla Milo,
Luca Pilloni, Laura Atzori**

Department of Dermatology, University of Cagliari, Italy

Address for correspondence: Dr. Federico Patta,
S. Giovanni Hospital, Via Ospedale, 46, I-09100 Cagliari, Italy
E-mail: federicopatta@yahoo.it

REFERENCES

1. Thiyanaratnam J, Doherty SD, Krishnan B, Hsu S. Granuloma faciale: Case report and review. *Dermatol Online J* 2009;15:3.
2. De D, Kanwar AJ, Radotra BD, Gupta S. Extrafacial granuloma faciale: Report of a case. *J Eur Acad Dermatol Venereol* 2007;21:1284-6.
3. Tojo G, Fujimura T, Kambayashi Y, Kikuchi K, Aiba S. Successful treatment of granuloma faciale with topical tacrolimus: A case report and immunohistochemical study. *Case Rep Dermatol* 2012;4:158-62.
4. Gupta L, Naik H, Kumar NM, Kar HK. Granuloma faciale with extrafacial involvement and response to tacrolimus. *J Cutan Aesthet Surg* 2012;5:150-2.
5. Hruza GJ, Ammirati CT. Granuloma faciale treated with 595-nm pulsed dye laser. *Dermatol Surg* 2011;37:1060-1.
6. Dowlati B, Firooz A, Dowlati Y. Granuloma faciale: Successful treatment of nine cases with a combination of cryotherapy and intralesional corticosteroid injection. *Int J Dermatol* 1997;36:548-51.

Access this article online	
Quick Response Code:	Website: www.ijdv1.com
	DOI: 10.4103/0378-6323.148604

Copyright of Indian Journal of Dermatology, Venereology & Leprology is the property of Medknow Publications & Media Pvt. Ltd. and its content may not be copied or emailed to multiple sites or posted to a listserv without the copyright holder's express written permission. However, users may print, download, or email articles for individual use.