

Risk Stratification of Neck Lesions Detected Sonographically During the Follow-Up of Differentiated Thyroid Cancer

Livia Lamartina, Giorgio Grani, Marco Biffoni, Laura Giacomelli, Giuseppe Costante, Stefania Lupo, Marianna Maranghi, Katia Plasmati, Marialuisa Sponziello, Fabiana Trulli, Antonella Verrienti, Sebastiano Filetti, and Cosimo Durante

Dipartimento di Medicina Interna e Specialità Mediche (L.L., G.G., S.L., M.M., K.P., M.S., F.T., A.V., S.F., C.D.), Dipartimento di Scienze Chirurgiche (M.B., L.G.), Università di Roma "Sapienza," 00161 Roma, Italy; and Department of Internal Medicine (G.C.), Institut Jules Bordet Comprehensive Cancer Center, 1000 Brussels, Belgium

Context: The European Thyroid Association (ETA) has classified posttreatment cervical ultrasound findings in thyroid cancer patients based on their association with disease persistence/recurrence.

Objective: The objective of the study was to assess this classification's ability to predict the growth and persistence of such lesions during active posttreatment surveillance of patients with differentiated thyroid cancer (DTC).

Design: This was a retrospective, observational study.

Setting: The study was conducted at a thyroid cancer center in a large Italian teaching hospital.

Patients: Center referrals (2005–2014) were reviewed and patients selected with pathologically confirmed DTC; total thyroidectomy, with or without neck dissection and/or radioiodine remnant ablation; abnormal findings on two or more consecutive posttreatment neck sonograms; and subsequent follow-up consisting of active surveillance. Baseline ultrasound abnormalities (thyroid bed masses, lymph nodes) were classified according to the ETA system. Patients were divided into group S (those with one or more lesions classified as suspicious) and group I (indeterminate lesions only). We recorded baseline and follow-up clinical data through June 30, 2015.

Main Outcomes: The main outcomes were patients with growth (>3 mm, largest diameter) of one or more lesions during follow-up and patients with one or more persistent lesions at the final visit.

Results: The cohort included 58 of the 637 DTC cases screened (9%). A total of 113 lesions were followed up (18 thyroid bed masses, 95 lymph nodes). During surveillance (median 3.7 y), group I had significantly lower rates than group S of lesion growth (8% vs 36%, $P = .01$) and persistence (64% vs 97%, $P = .014$). The median time to scan normalization was 2.9 years.

Conclusions: The ETA's evidence-based classification of sonographically detected neck abnormalities can help identify papillary thyroid cancer patients eligible for more relaxed follow-up. (*J Clin Endocrinol Metab* 101: 3036–3044, 2016)

Diagnoses of differentiated thyroid cancer (DTC) have increased nearly 3-fold since 1975 (1). Most cases involve papillary thyroid cancers (PTC) with indolent be-

haviors. However, locoregional disease is found in 7%–28% of PTC patients during follow-up, depending on the baseline risk class and response to initial therapy (2–5).

ISSN Print 0021-972X ISSN Online 1945-7197
Printed in USA

Copyright © 2016 by the Endocrine Society

Received February 21, 2016. Accepted May 10, 2016.

First Published Online May 17, 2016

Abbreviations: AJCC, American Joint Committee on Cancer; ATA, American Thyroid Association; DTC, differentiated thyroid cancer; ETA, European Thyroid Association; FNAB, fine-needle aspiration biopsy; PTC, papillary thyroid cancer; RRA, radioiodine remnant ablation; Tg, thyroglobulin; US, ultrasonography.

Almost all of this disease is discovered with cervical ultrasonography (US), the most sensitive tool for exploring the thyroid bed and cervical lymph node compartments (6) and the internationally acknowledged cornerstone of the postoperative surveillance program (5, 7).

Debate continues, however, on the management of sonographically detected abnormalities, in particular when these lesions should be subjected to fine-needle aspiration biopsy (FNAB). Confirmation of locoregional metastatic involvement often leads to further treatment, but if this course of action has already been excluded by an analysis of costs and benefits, FNAB serves little purpose and can even be an unnecessary source of stress for the patient. According to the American Thyroid Association (ATA) practice guidelines, surgery is the preferred treatment for locoregional disease (5), and in expert hands, neck dissections are acceptably safe procedures. But they are by no means risk free, particularly when they involve areas already subjected to surgery (8–10). Moreover, not all dissections are carried out by experts, and even those that are can be associated with considerable morbidity. These considerations become increasingly important in light of the efficacy rates of these procedures, as low as 40%–50% in some series (11–13), and the fact that in up to 9% of cases the resected tissues prove to be benign (11, 13, 14). Even when neck lesions are cytologically confirmed to be malignant, their progression is usually extremely slow (15, 16) and their impact on clinical outcomes far from clear (17–22).

Support is thus growing for the use of more cautious, conservative strategies for managing sonographically detected neck lesions in DTC patients. The 2015 ATA Guidelines allow for active surveillance of suspicious, nonthreatening lymph nodes whose smallest diameters are less than 8–10 mm. Biopsy should be reserved for lesions that exceed this limit and/or display active growth, and it should be used only when management of the case is likely to be modified if positive findings emerge (5). Specific recommendations are lacking, however, on the management of small masses detected in the postoperative thyroid bed. Although some of these lesions are indeed malignant, many prove to be foci of postoperative fibrosis or suture granulomas.

In this scenario, the sonographic features of neck lesions acquire increasing importance in decisions regarding the posttreatment management of DTC. Several authors have described the sonographic characteristics of abnormal lymph nodes and thyroid bed nodules (23–26). Some features are highly specific in identifying persistence/recurrence; others are sensitive markers of disease but low on specificity (23). To aid clinicians in exploiting the diagnostic value of these markers, the European Thyroid

Association (ETA) has published a set of criteria for estimating the malignancy risk of sonographically identified neck masses and lymph nodes based on the assessment of a series of US characteristics classified as normal, indeterminate, and suspicious (27). This study was conducted to assess the value of this classification in clinical decision making regarding the use or deferral of FNAB. Our primary objective was to determine how well this classification predicts the evolution of sonographically detected neck lesions, in terms of persistence and/or growth, during the posttreatment surveillance of DTC patients. As secondary end points, we also assessed rates of complications and the occurrence of new lesions.

Materials and Methods

Study design

We conducted a retrospective observational study in the thyroid cancer follow-up center of a large teaching hospital in Italy. The study protocol was approved by the institutional review board. Written informed consent was obtained from all patients whose data were analyzed.

The center's DTC follow-up protocol

Patients with DTC are initially seen 6–12 months after primary treatment and at least once a year thereafter. Each visit includes serum thyroglobulin (Tg) assays (DYNO test Tg-plus, Brahms Diagnostics GmbH; functional sensitivity 0.2 ng/mL), radioimmunoassays of circulating Tg antibodies (Architect System Anti-Tg; Abbott Laboratories; functional sensitivity 0.31 IU/mL), and high-resolution gray-scale and color Doppler US of the thyroid bed and cervical lymph node compartments. The US examinations are performed by an endocrinologist with specific training and expertise in sonographic examination of the neck. The characteristics of the examiner and the standard examination protocol are both in conformity with ETA recommendations (27). Additional imaging studies and/or FNAB for cytology are ordered at the examiner's discretion in accordance with evidence-based guidelines (5, 28).

Study cohort selection and division into subgroups

We reviewed the center's case database and identified patients diagnosed with DTC and referred for follow-up between January 1, 2005, and December 31, 2014. Those who met the following criteria were included in the study cohort: 1) surgical pathology report confirming diagnosis of DTC (ie, papillary, follicular, or poorly differentiated thyroid cancer); 2) primary treatment consisting of total or near-total thyroidectomy, with or without central and/or lateral neck dissection and radioiodine remnant ablation (RRA); 3) abnormal findings on at least two consecutive neck sonograms performed in our center; and 4) subsequent follow-up consisting solely of active surveillance.

Static images from the baseline US examination (ie, the first showing abnormalities) were reexamined by an independent reviewer. Each thyroid bed or lymph node lesion was recorded and classified in accordance with the schema shown in Table 1. The lesion features considered were those that were routinely eval-

Table 1. Classification of Lesions Noted on Neck Ultrasound

ETA Classification (n = 27)	Thyroid Bed Lesions (n = 24–26)	Lymph Nodes (n = 23)
Suspicious	Increased vascularization Microcalcifications Cystic areas Irregular borders Taller than wide in transverse plane	Peripheral vascularization Microcalcifications Cystic areas Solid thyroid-like tissue
Indeterminate	Hypoechoogenicity	Round shape Hilum absent

uated by our staff during the study period. Each was retrospectively designated suspicious or indeterminate in accordance with the ETA guidelines (27). When the reviewer's and original examiner's judgments were discordant, both operators reexamined the images and reached a consensus judgment.

The cohort itself was then divided into two groups: group S comprising patients with at least one lesion classified as suspicious and group I comprising those whose lesions were all considered indeterminate. Medical records were reviewed and demographic and clinical characteristics recorded for each patient at the time of thyroid cancer diagnosis, at study baseline, and at all subsequent visits through June 30, 2015 (data lock).

Analysis of follow-up data

Clinical findings, US images and reports, and laboratory data relative to each postbaseline follow-up visit were reviewed. We recorded the results of serum Tg, Tg antibodies, and TSH assays as well as the location, dimensions, and sonographic features of each lesion observed (including those appearing after baseline, provided they were observed on at least two consecutive scans). The primary end points were growth of one or more lesions at any time during follow-up and persistence of one or more neck lesions at the end of follow-up. Growth was defined as an increase of greater than 3 mm in the largest diameter relative to that observed at initial detection. Persistent lesions were those still visualized sonographically at the final visit (ie, the most recent visit for patients who were still undergoing active surveillance at data lock or the last visit in our center before the patient was referred for treatment, died or was lost to follow-up). We also recorded the number of lesions that were detected after baseline (provided they were seen on at least two consecutive scans) and the number of patients who had clinical evidence of complications related to lesion growth (dyspnea, dysphagia, bleeding, skin ulceration).

Statistical analysis

Differences between categorical variables (expressed as numbers and percentages) were evaluated with the χ^2 test or the Fischer exact test for small samples; differences between continuous variables (reported as medians and ranges) were assessed with the Mann-Whitney test. Values of $P < .05$ were considered statistically significant. StatView 5.0.1 software (SAS Institute, Inc) was used for statistical analyses.

Results

Cohort profile at baseline

Six hundred thirty-seven patients with pathologically confirmed DTC were referred to our follow-up center

between January 31, 2005, and December 31, 2014 (Supplemental Figure 1). In 117 cases (18%), neck US performed by our staff had revealed one or more abnormalities. In 18 of these cases, subsequent US findings were unavailable (contact interrupted because the patient was referred directly for treatment or lost to follow-up shortly after lesion detection or because the next visit was scheduled after data lock). In 41 others, none of the lesions observed at baseline were seen on the subsequent US scan. The remaining 58 DTC patients constituted the study cohort: they had a total of 94 neck lesions, each visualized on at least two consecutive scans. In all 58 cases, treatment and/or FNAB were deferred (based on decisions made jointly by patients and physicians) and the patients placed under active surveillance.

Their characteristics are summarized in Table 2. All 58 had PTC. The median age at diagnosis was 46 years, almost two-thirds were women, and in 71% of the cases, the ATA risk level was intermediate or high. All had initially been treated with total thyroidectomy; 25 (43%) had also undergone some form of neck dissection (central in 13, lateral in two, both in 10), and over 80% had had RRA. Postoperatively, all received levothyroxine at doses that kept serum TSH levels in the low to normal range. At baseline (ie, at study entry), 10 of the 58 patients (17%) had already undergone revision neck dissections and were being followed up for second neck recurrences. Nine (16%) had distant metastases.

At baseline, 33 of the 58 patients (57%) had one or more suspicious lesions and were therefore assigned to group S. Their profile at the time of initial treatment resembled that of the 25 patients whose neck lesions were all classified as indeterminate (43%) (group I). Group S patients had significantly larger primary tumors, their initial treatment was more likely to include RRA, and they had a higher rate of postoperative whole-body scan showing neck uptake outside the thyroid bed. There were no significant differences in American Joint Committee on Cancer (AJCC) stages or the initial ATA risk classification. At study entry, however, the differences between the two groups were more marked, involving disease stage, presence of distant metastases, and a history of revision surgery (Table 2).

Table 2. Characteristics of the Study Cohort and Subcohorts

Characteristics ^a	Whole Cohort	Group I	Group S	P Value
Patients, n	58	25	33	
Females	36 (62%)	19 (76%)	17 (52%)	.06
At initial treatment				
Age, y, median (range)	46 (15–78)	46 (21–73)	45 (15–78)	.41
Total thyroidectomy with neck dissection				
With central neck dissection	13 (22%)	6 (24%)	7 (21%)	.45
With lateral neck dissection	2 (3%)		2 (6%)	
With central and lateral neck dissection	10 (17%)	2 (8%)	8 (24%)	
Radioiodine remnant ablation	47 (81%)	16 (64%)	31 (94%)	.004
RAI activity, mCi, median (range)	105 (30–300)	120 (42–300)	100 (30–155)	.61
RxWBS (n = 41) ^b				
No uptake or uptake in thyroid bed	34 (83%)	15 (100%)	19 (73%)	.03
Uptake outside the thyroid bed ^c	7 (17%)		7 (27%)	
Histology subtype				
PTC, classic	31 (54%)	13 (52%)	18 (55%)	.60
PTC, follicular variant	20 (34%)	10 (40%)	10 (30%)	
PTC, aggressive variant ^d	7 (12%)	2 (8%)	5 (15%)	
Largest tumor diameter, mm	11	10	12	.02
Median (range) (n = 53) ^b	(1.1–45)	(1.1–35)	(4–45)	
Tumor foci (n = 57) ^b				
Unifocal	32 (56%)	17 (68%)	15 (47%)	.19
Multifocal	25 (44%)	8 (32%)	17 (53%)	
Extrathyroidal extension	19 (33%)	4 (16%)	15 (45%)	.055
Microscopic (T3)	18 (31%)	4 (16%)	14 (42%)	
Macroscopic (T4)	1 (2%)		1 (3%)	
AJCC stage				
I	39 (67%)	19 (76%)	20 (61%)	.09
II	2 (3%)		2 (6%)	
III	8 (14%)	5 (20%)	3 (9%)	
IV	9 (16%)	1 (4%)	8 (24%)	
Distant metastases	4 (7%)	0	4 (12%)	.14
ATA risk class				
Low	17 (29%)	10 (40%)	7 (21%)	.06
Intermediate	32 (55%)	14 (56%)	18 (55%)	
High	9 (16%)	1 (4%)	8 (24%)	
At study entry (baseline)				
Age, y, median (range)	50.7 (16–82)	51.7 (22–77)	49 (16–82)	.52
AJCC stage				
I	37 (64%)	19 (76%)	18 (55%)	.01
II	3 (5%)		3 (9%)	
III	7 (12%)	5 (20%)	2 (6%)	
IV	11 (19%)	1 (4%)	10 (30%)	
Distant metastases	9 (16%)	0	9 (27%)	.007
Previous revision neck surgery	10 (17%)	1 (4%)	9 (27%)	.03
TSH, μ U/L, median (range)	0.29 (0.01–18.7)	0.31 (0.02–6.5)	0.28 (0.02–18.7)	.75
Serum Tg, ng/mL, median (range)	0.2 (0.002–195.9)	0.17 (0.002–1)	0.25 (0.01–195.9)	.28
TgAb status (n = 54) ^b				
Negative	41 (76%)	21 (84%)	20 (69%)	.08
Positive	13 (24%)	4 (16%)	9 (31%)	
Years from initial surgery, median (range)	1.2 (0.1–26)	0.5 (0.1–16)	1.9 (0.1–26)	.11

Abbreviations: NA, not available; RAI, radioactive iodine; RxWBS, posttreatment whole-body scan; TgAb, anti-Tg antibodies.

^a Unless otherwise stated, results are expressed as numbers (percentages).

^b Number of patients with available data.

^c Cervical and in two cases at distant sites.

^d Two oxyphilic in group I; two tall cell, one sclerosing, one trabecular, and one poorly differentiated in group S.

Table 3 summarizes the characteristics of the 94 neck lesions visualized by our staff at baseline, which included 16 thyroid bed masses and 78 lymph nodes. The 49 suspicious lesions (52%) were significantly larger than those classified as indeterminate. Ten thyroid bed lesions (63%)

were hypoechoic nodules with no other abnormal features. Almost all the 78 abnormal lymph nodes were round with no detectable hilum; 43 also presented one or more suspicious features (the most common combination being solid aspect with cystic areas and microcalcifications).

Table 3. Characteristics of the 94 Neck Lesions Present at Baseline

Characteristics	Total	Indeterminate	Suspicious	P Value
Number of lesions, %	94 (100%)	45 (48%)	49 (52%)	
Largest diameter, mm, median (range)	9.1 (3.9–36.4)	8.2 (3.9–36.4)	9.8 (5.7–26)	.01
Location relative to primary tumor				
Ipsilateral	68 (72%)	30 (67%)	38 (78%)	.23
Contralateral	26 (28%)	15 (33%)	11 (22%)	
Location				
Level II	16 (17%)	6 (13%)	10 (21%)	.29
Level III	20 (21%)	9 (20%)	11 (22%)	
Level IV	26 (28%)	12 (27%)	14 (29%)	
Level V	3 (3%)		3 (6%)	
Level VI	11 (12%)	6 (13%)	5 (10%)	
Level VII	2 (2%)	2 (4%)		
Thyroid bed	16 (17%)	10 (23%)	6 (12%)	
Ultrasound features				
Thyroid bed nodules				<.001
Hypoechoogenicity	10 (11%)	10 (22%)		
Irregular margins	2 (2%)		2 (4%)	
Solid with microcalcifications and cystic areas	2 (2%)		2 (4%)	
Increased vascularization	2 (2%)		2 (4%)	
Lymph nodes				
Round with absent hilum	35 (37%)	35 (78%)		
Round, absent hilum, and the following				
Cystic changes	6 (7%)		6 (13%)	
Microcalcifications	6 (7%)		6 (13%)	
Cystic changes and microcalcifications	2 (2%)		2 (4%)	
Solid	3 (3%)		3 (6%)	
Solid with microcalcifications	5 (5%)		5 (10%)	
Solid with microcalcifications and cystic areas	10 (11%)		10 (20%)	
Solid with microcalcifications and cystic areas and peripheral vascularization	1 (1%)		1 (2%)	
Solid with microcalcifications and peripheral vascularization	5 (5%)		5 (10%)	
Peripheral vascularization	3 (3%)		3 (6%)	
Absent hilum and peripheral vascularization	2 (2%)		2 (4%)	

Follow-up

Ten patients (17%) (7 from group S) developed one or more new neck lesions after baseline. The 19 new lesions were almost all lymph nodes ($n = 17$: six in level IV, five in level III, four in level VI, and one each in levels II and VII), and 10 (53%) (all observed in group S patients) were considered suspicious. The total number of lesions followed up in the study was thus 113 (Figure 1). At first appearance, greater than half the 95 lymph node lesions were classified as suspicious, whereas most of the 18 thyroid bed lesions were considered indeterminate. Only two thyroid bed lesions displayed growth during follow-up, but all 18 were still visualized at the final visit (median 3.7 y after baseline US, range 0.2–10.5). Growth was slightly more common in lymph node lesions, regardless of whether they were indeterminate or suspicious. At the final visit, however, 17 of the abnormal lymph nodes had disappeared, including one indeterminate lesion that had formerly displayed growth. Lesion resolution was significantly more common among indeterminate nodal lesions ($P < .001$ vs those considered suspicious). The two suspicious nodes that disappeared had both been detected in

the same patient and were both characterized by undetectable hila and peripheral vascularization.

Figure 2 shows patient-level outcomes recorded in groups I and S. Growth of one or more lesions during follow-up was significantly more common in group S (36% vs 8%, $P = .01$). In both groups, however, most patients experienced no structural progression, and none developed complications related to lesion growth. The final neck US findings were completely negative in nine of the 25 patients in group I (36%). This finding was significantly less common in group S (5%, $P = .014$ vs group I). The median time to normalization (from baseline to first negative US) in these cases was 2.9 years (0.9–4.0 y), and the median duration of the postnormalization follow-up was 0.5 years (range 0–4.1 y).

As shown in Table 4, in all of the patients whose lesions ultimately disappeared, the basal serum Tg levels measured at the time of the last US examination were undetectable (ie, <0.2 ng/mL) or indeterminate (ie, ≤ 1 ng/mL with no evidence of Tg antibodies or with declining Tg antibodies). The nine patients with evidence of distant metastases (all in group S) were the same ones with distant

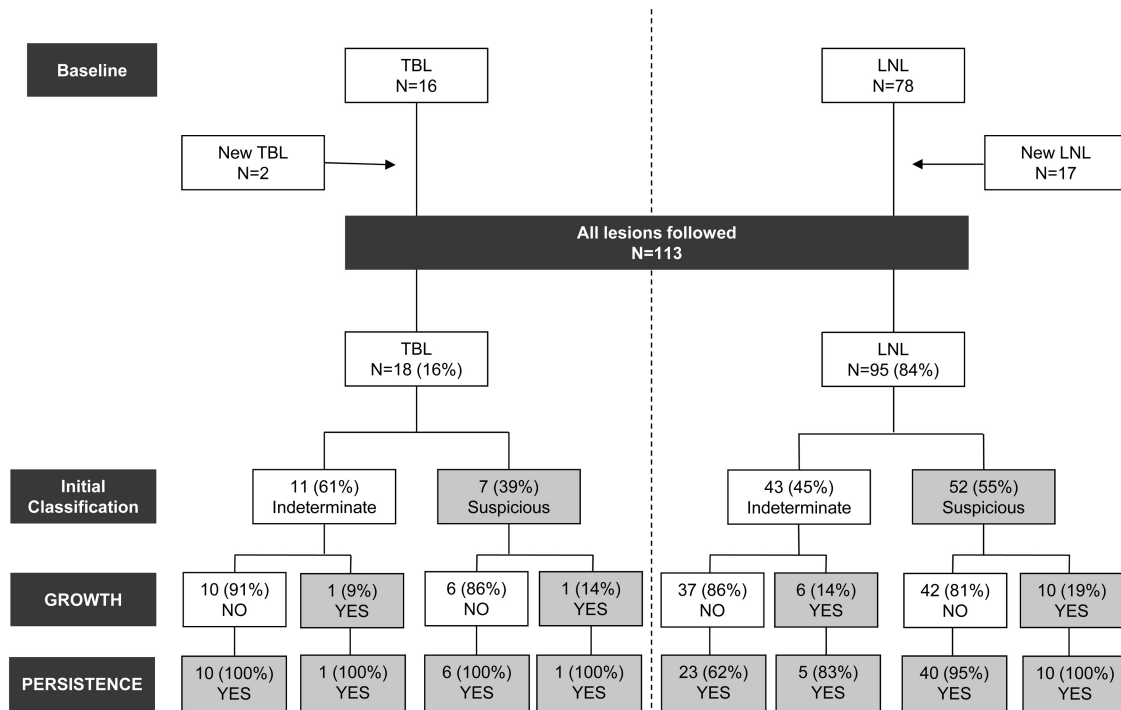


Figure 1. Appearance, classification, and outcomes of the neck lesions followed up during the study period. Criteria for lesion classification as suspicious or indeterminate are shown in Table 1. Like the lesions present at baseline, new lesions that developed during follow-up were considered only when visualized on two or more consecutive ultrasound scans. Growth was defined as an increase in largest diameter of greater than 3 mm compared with that at initial detection. LNL, lymph node lesions; TBL, thyroid bed lesions.

metastases at baseline. Based on the data shown in the table, the clinical judgment of the medical staff, and the preferences of the patients, 8 of the 32 group S patients with persistent neck lesions were referred for treatment, and five others (three from group S, two from group I) underwent FNAB for cytological assessment. In all 13 cases, pathology findings confirmed the presence of recurrent neck disease.

Discussion

We retrospectively analyzed the sonographic features of neck lesions detected in 58 PTC patients treated with near-total thyroidectomy, with or without RRA, to determine whether they could provide guidance for surveillance management decisions in the absence of FNAB. Using the ETA's recently published classification of cervical US findings, we divided our patient cohort

into two subgroups: those with at least one lesion classified as suspicious (group S) and those whose abnormalities all fell within the indeterminate category (group I) (27). All of the patients were managed with active surveillance based mainly on serial US studies and serum Tg assays.

In the cohort as a whole, structural progression rates during follow-up (median 3.7 y) were low: fewer than 20% of the patients developed new neck lesions, only 24% experienced lesion growth, and none experienced lesion-related complications. Most important, at the final follow-up visit, 17% of the patients had no abnormalities whatsoever on




Figure 2. Patients in groups I and S with persistent lesions at the final follow-up visit. In the 10 patients whose neck US findings normalized (17% of the cohort), the median time from baseline to the first negative US examination was 2.9 years (range 0.9–4.0 y), and follow-up after US normalization ranged from 0 to 4.1 years (median 0.5 y).

Table 4. Patient-Level Outcomes in Groups I and S at the Final Visit

Findings at Last Visit ^a	Group I		Group S	
	Patients With Persistent Lesions (n = 16)	Patients With No Lesions (n = 9)	Patients With No Lesions (n = 1)	Patients With Persistent Lesions (n = 32)
Basal serum Tg ^b				
Undetectable levels	7 (44%)	6 (67%)		10 (31%)
Detectable levels	7 (44%)	2 (22%) ^c		20 (63%)
Uninterpretable	2 (12%)	1 (11%) ^d	1 (100%) ^d	2 (6%)
Serum TSH, μ IU/L, median (range)	0.5 (0.09–12.6)	0.22 (0.06–1.4)	5.3	0.31 (0–3.2)
Presence of distant metastases				9 (28%)
Follow-up, y, median (range) (baseline US to last US)	2.8 (0.2–7.7)	1.6 (0.2–3)	2.1	2.5 (0.2–10.5)

Abbreviation: TgAb, anti-Tg antibodies.

^a Expressed as number (percentage) of patients unless otherwise stated.

^b Basal Tg levels were classified as follows: undetectable, less than 0.2 ng/mL and negative TgAb status; detectable, greater than 0.2 ng/mL and negative TgAb status; and uninterpretable, any Tg level and positive or unknown TgAb status.

^c Tg levels less than 1 ng/mL.

^d Declining TgAb levels.

the US examination. However, the two subgroups were characterized by significantly different disease behaviors and outcomes. In group I, lesion growth was observed in only 8% of the patients, and in 36% all lesions resolved spontaneously over time. Lesion growth and persistence were both much more common when one or more of the patient's lesions presented suspicious features: in 36% of the group S patients, at least one lesion increased in size during follow-up, and in 97%, abnormalities were still detectable at the final visit. These findings suggest that, in the presence of sonographically detected neck lesions, the fact that the abnormalities are all indeterminate rather than frankly suspicious adds support to a decision to defer FNAB and/or additional treatment.

This is important because abnormal neck US findings are common during the follow-up of DTC patients, particularly those with PTCs. Our cohort was selected from a background population of more than 600 consecutive DTC patients followed up in our center since 2005 with one or more neck US examinations per year. As shown in [Supplemental Figure 1](#), almost 20% of these individuals had at least one scan showing abnormalities, but the percentage decreased by approximately half when we considered only those whose lesions were still present at the next visit. Ninety-five percent of the lesions that disappeared between the first and second scans were cervical lymph nodes, and 83% of these displayed only indeterminate features. The same pattern emerged in the study cohort itself (Figure 1). Resolution appears to be much less common among thyroid bed nodules, which often repre-

sent foci of postoperative fibrosis or suture granulomas (15, 29, 30).

Disappearance of nodes with suspicious features has been reported (16). In our cohort, only two suspicious nodes, both documented in the same patient on two consecutive scans, resolved completely. The lesions were located ipsilaterally to the primary tumor (one in level IV, the other in level VI), and both had presented with absent hila and evidence of peripheral vascularization. Although the latter feature is regarded as a sensitive and also relatively specific predictor of malignancy, it is also observed in up to 18% of reactive nodes (23). Size increases are also compatible with reactive phenomena, and this is a plausible explanation for the single lesion in group I that disappeared after exhibiting growth of 7 mm.

It is important to note that the US-based risk class defined at the first sign of neck lesions may require periodic revision owing to the appearance of new abnormalities and/or changes in the appearance of those originally present. Neither of these situations occurred within our study. As for the 19 new lesions, only 10 were classified as suspicious, and all 10 developed in patients already assigned to group S. Aside from size changes, the sonographic characteristics of the baseline lesions in our cohort did not vary appreciably during follow-up. As expected, the US-based risk classification showed concordance with other clinical predictors of recurrent thyroid cancer. For example, group S patients also tended to have higher-stage tumors and were more likely to have undergone revision neck surgery

for persistent/recurrent PTC prior to study entry (Table 2); they also had higher Tg levels at the final assessment.

Previous studies (15, 16) have already shown that neck lesions detected sonographically during the postoperative follow-up of DTC patients frequently follow an indolent course and that noninvasive surveillance is usually a safe, cost-effective strategy for managing cases of this type. The outcomes observed in our study suggest that postponing invasive procedures such as FNA or further treatments is a safe course of action, even in population with higher-risk profiles, particularly when the neck lesions are characterized by exclusively indeterminate features.

The main limits of this study were the retrospective nature of our analyses and the small size of the study cohort. It is also important to stress that the present study was conducted in a single center, and all the US examinations were performed by a single physician with extensive training and experience. These factors may well have enhanced the uniformity of the examinations themselves and the descriptions of findings. However, they might also reduce the applicability of our study findings to other settings. The main shortcoming of cervical US is its operator dependence. The impact of this problem can be attenuated to some extent by the use of standardized examination and reporting protocols, such as those proposed by the ETA (27). Greater uniformity would not only improve communication between clinicians, but also it would also facilitate comparison of the findings from different studies, an essential step for identifying high-quality, cost-effective management strategies (31).

In conclusion, previous studies (15, 16) have shown that neck lesions detected sonographically during the postoperative follow-up of DTC patients frequently follow an indolent course and that noninvasive surveillance is usually a safe, cost-effective strategy for managing cases of this type. Our study expands these findings. The outcomes we observed suggest that watchful waiting can be a safe course of action, even in population with higher-risk profiles, particularly when the neck lesions are characterized by exclusively indeterminate sonographic features. Risk estimates based on the ETA's evidence-based classification of sonographically detected neck abnormalities can be a useful aid for identifying PTC patients for whom a more relaxed follow-up protocol can be proposed. Invasive procedures and additional imaging studies can then be reserved for cases in which the neck lesions are most likely to pose an actual threat.

Acknowledgments

We thank all the members of the Italian Thyroid Cancer Observatory Foundation.

Address all correspondence and requests for reprints to: Cosimo Durante, MD, Dipartimento di Medicina Interna e Specialità Mediche, Università di Roma "Sapienza," Viale del Policlinico 155, 00161 Roma, Italy. E-mail: cosimo.durante@uniroma1.it.

Writing support was provided by Marian Everett Kent, BSN. L.L. and G.G. contributed to this paper as recipients of the PhD program of Biotechnologies and Clinical Medicine of the University of Rome, Sapienza.

This work was supported by The Umberto Di Mario Foundation and the Banca d'Italia.

Disclosure Summary: The authors have nothing to disclose.

References

- Davies L, Welch HG. Current thyroid cancer trends in the United States. *JAMA Otolaryngol Head Neck Surg*. 2014;140:317–322.
- Tuttle RM, Tala H, Shah J, et al. Estimating risk of recurrence in differentiated thyroid cancer after total thyroidectomy and radioactive iodine remnant ablation: using response to therapy variables to modify the initial risk estimates predicted by the new American Thyroid Association staging system. *Thyroid*. 2010;20:1341–1349.
- Castagna MG, Maino F, Cipri C, et al. Delayed risk stratification, to include the response to initial treatment (surgery and radioiodine ablation), has better outcome predictivity in differentiated thyroid cancer patients. *Eur J Endocrinol*. 2011;165:441–446.
- Durante C, Montesano T, Torlontano M, et al. Papillary thyroid cancer: time course of recurrences during postsurgery surveillance. *J Clin Endocrinol Metab*. 2013;98:636–642.
- Haugen BR, Alexander EK, Bible KC, et al. 2015 American Thyroid Association management guidelines for adult patients with thyroid nodules and differentiated thyroid cancer. *Thyroid*. 2016;26:1–133.
- Durante C, Filetti S. Management of papillary thyroid cancer patients in absence of postoperative radioiodine remnant ablation: tailoring follow-up by neck sonography. *J Clin Endocrinol Metab*. 2011;96:3059–3061.
- Perros P, Boelaert K, Colley S, et al. Guidelines for the management of thyroid cancer. British Thyroid Association. *Clin Endocrinol (Oxf)*. 2014;81:1–122.
- Roh JL, Kim JM, Park CI. Central compartment reoperation for recurrent/persistent differentiated thyroid cancer: patterns of recurrence, morbidity, and prediction of postoperative hypocalcemia. *Ann Surg Oncol*. 2011;18:1312–1318.
- Lang BH, Lee GC, Ng CP, Wong KP, Wan KY, Lo CY. Evaluating the morbidity and efficacy of reoperative surgery in the central compartment for persistent/recurrent papillary thyroid carcinoma. *World J Surg*. 2013;37:2853–2859.
- Onkendi EO, McKenzie TJ, Richards ML, et al. Reoperative experience with papillary thyroid cancer. *World J Surg*. 2014;38:645–652.
- Schuff KG, Weber SM, Givi B, Samuels MH, Andersen PE, Cohen JI. Efficacy of nodal dissection for treatment of persistent/recurrent papillary thyroid cancer. *Laryngoscope*. 2008;118:768–775.
- Yim JH, Kim WB, Kim EY, et al. The outcomes of first reoperation for locoregionally recurrent/persistent papillary thyroid carcinoma in patients who initially underwent total thyroidectomy and remnant ablation. *J Clin Endocrinol Metab*. 2011;96:2049–2056.
- Shah MD, Harris LD, Nassif RG, Kim D, Eski S, Freeman JL. Efficacy and safety of central compartment neck dissection for recurrent thyroid carcinoma. *Arch Otolaryngol Head Neck Surg*. 2012;138:33–37.
- Al-Saif O, Farrar WB, Bloomston M, Porter K, Ringel MD, Kloos RT. Long-term efficacy of lymph node reoperation for persistent papillary thyroid cancer. *J Clin Endocrinol Metab*. 2010;95:2187–2194.

15. Rondeau G, Fish S, Hann LE, Fagin JA, Tuttle RM. Ultrasonographically detected small thyroid bed nodules identified after total thyroidectomy for differentiated thyroid cancer seldom show clinically significant structural progression. *Thyroid*. 2011;21:845–853.
16. Robenshtok E, Fish S, Bach A, Domínguez JM, Shaha A, Tuttle RM. Suspicious cervical lymph nodes detected after thyroidectomy for papillary thyroid cancer usually remain stable over years in properly selected patients. *J Clin Endocrinol Metab*. 2012;97:2706–2713.
17. Tubiana M, Schlumberger M, Rougier P, et al. Long-term results and prognostic factors in patients with differentiated thyroid carcinoma. *Cancer*. 1985;55:794–804.
18. Hay ID, Bergstralh EJ, Goellner JR, Ebersold JR, Grant CS. Predicting outcome in papillary thyroid carcinoma: development of a reliable prognostic scoring system in a cohort of 1779 patients surgically treated at one institution during 1940 through 1989. *Surgery*. 1993;114:1050–1058.
19. Mazzaferri EL, Kloos RT. Clinical review 128: current approaches to primary therapy for papillary and follicular thyroid cancer. *J Clin Endocrinol Metab*. 2001;86:1447–1463.
20. Podnos YD, Smith D, Wagman LD, Ellenhorn JD. The implication of lymph node metastasis on survival in patients with well-differentiated thyroid cancer. *Am Surg*. 2005;71:731–734.
21. Kandil E, Friedlander P, Noureldine S, Islam T, Tufano RP. Impact of extensive neck dissection on survival from papillary thyroid cancer. *ORL J Otorhinolaryngol Relat Spec*. 2011;73:330–335.
22. Gulcelik MA, Ozdemir Y, Kadri Colakoglu M, Camlibel M, Alagol H. Prognostic factors determining survival in patients with node positive differentiated thyroid cancer: a retrospective cross-sectional study. *Clin Otolaryngol*. 2012;37:460–467.
23. Leboulleux S, Girard E, Rose M, et al. Ultrasound criteria of malignancy for cervical lymph nodes in patients followed up for differentiated thyroid cancer. *J Clin Endocrinol Metab*. 2007;92:3590–3594.
24. Shin JH, Han BK, Ko EY, Kang SS. Sonographic findings in the surgical bed after thyroidectomy: comparison of recurrent tumors and nonrecurrent lesions. *J Ultrasound Med*. 2007;26:1359–1366.
25. Lee JH, Lee HK, Lee DH, et al. Ultrasonographic findings of a newly detected nodule on the thyroid bed in postoperative patients for thyroid carcinoma: correlation with the results of ultrasonography-guided fine-needle aspiration biopsy. *Clin Imaging*. 2007;31:109–113.
26. Kamaya A, Gross M, Akatsu H, Jeffrey RB. Recurrence in the thyroidectomy bed: sonographic findings. *AJR Am J Roentgenol*. 2011;196:66–70.
27. Leenhardt L, Erdogan MF, Hegedus L, et al. European Thyroid Association guidelines for cervical ultrasound scan and ultrasound-guided techniques in the postoperative management of patients with thyroid cancer. *Eur Thyroid J*. 2013;2:147–159.
28. Tufano RP, Clayman G, Heller KS, et al. Management of recurrent/persistent nodal disease in patients with differentiated thyroid cancer: a critical review of the risks and benefits of surgical intervention versus active surveillance. *Thyroid*. 2015;25:15–27.
29. Langer JE, Luster E, Horii SC, Mandel SJ, Baloch ZW, Coleman BG. Chronic granulomatous lesions after thyroidectomy: imaging findings. *AJR Am J Roentgenol*. 2005;185:1350–1354.
30. Kim JH, Lee JH, Shong YK, et al. Ultrasound features of suture granulomas in the thyroid bed after thyroidectomy for papillary thyroid carcinoma with an emphasis on their differentiation from locally recurrent thyroid carcinomas. *Ultrasound Med Biol*. 2009;35:1452–1457.
31. Porter ME, Larsson S, Lee TH. Standardizing patient outcomes measurement. *N Engl J Med*. 2016;374:504–506.