

Early Diagnosis of Congenital Uterine Anomalies: Is the Three Dimensional Ultrasound Approach the Suitable Choice? 3D in Uterine Anomalies

Riganelli L*, Savone D, Salerno L, Carrone A, Casorelli A, Faiano P, De Medici C, Raad Besharat A, Benedetti Panici P and Grazia Piccioni M

Department of Obstetrics and Gynecology, "Sapienza" University, Umberto I Policlinico of Rome, Italy

Abstract

Purposes: Congenital uterine anomalies (CUA) are benign conditions associated with relatively serious complications affecting the reproductive life. Due to their infrequency CUA are often misdiagnosed, exposing the patient to possible future complications.

Case description: We report the cases of three women affected by an unknown CUA, which underwent three different diagnostic and surgical approaches.

Conclusions: A correct and early diagnosis of CUA is mandatory to allow a correct clinical and therapeutic management. In our opinion we might avoid the use of MRI considered as the second line technique after 2D-US, keeping in mind that in CUA the diagnostic value of 3D-US has the same accuracy as MRI.

Keywords: Congenital uterine anomalies; 3D-ultrasound; MRI; Diagnosis

Introduction

Congenital uterine anomalies (CUA), a rather common benign condition with a prevalence of 4-7% [1], result from the abnormal formation, fusion or resorption of Mullerian ducts during fetal life [2]. Depending on the type and degree of anatomical alteration, CUA are associated with relatively serious complications affecting the reproductive life. The prevalence is higher in women with a history of infertility and recurrent pregnancy loss (15-27%) [3]. The last classification system of female genital tract anomalies has been proposed by the ESHRE/ESGE (European Society of Human Reproduction and Embryology/European Society of Gynecological Endoscopy) [4]. According to this system, anomalies are classified into 7 main classes, each one including anatomical deviations with the same embryological origin: U0, normal uterus; U1, dysmorphic uterus; U2, septate uterus; U3, bicorporeal uterus; U4, hemi-uterus; U5, aplastic uterus; U6, still unclassified cases.

In adult women, when CUA is suspected, 2D transvaginal ultrasound (TV-US) is the first line diagnostic approach but since it characterizes the type of CUA in only 59.1% of cases [5-7], a second line examination is still under current investigation. Trans abdominal ultrasound (TA-US) is the first modality approach in non-sexually active patients due to the high compliance in these women but due to its low diagnostic accuracy TA-US is poorly utilized [8]. Currently, pelvic magnetic resonance imaging (MRI) is the second-line exam for further noninvasive CUA evaluation in non-sexually-active patients with an accuracy near to 100% [5,9,10]. Nevertheless, MRI is more expensive and less available than ultrasound. In sexually active patients, the gold standard technique to evaluate CUA is laparoscopy followed by hysteroscopy which both represent invasive approaches, less feasible and more expensive than other diagnostic procedures [11].

Recently, three dimensional ultrasound (3D-US) has been proposed as a non-invasive procedure for CUA assessment in infertile patient. Indeed, while 2D resolution provide direct views in only transverse and sagittal planes, the 3D imaging added the coronal plane, with a reported accuracy near to 100% in detecting CUA [12,13]. Herein, we report the cases of three women presented to our department from June 2012 to

May 2015, affected by an unknown CUA, submitted to three different diagnostic and surgical approaches.

Case Reports

The first case is a 30 year-old woman with pelvic pain, fever and vomiting 10 days after a voluntary abortion performed in another hospital. Since menarche, which occurred at the age of 12, she referred frequent fevers following periods and primary dysmenorrhea, never investigated before. Vaginal examination showed a severe tenderness to the lateral motion of cervix accompanied by high uterine pain. 2D TV-US showed the presence of two cavities, the left one empty and the right one with endometrial decidualization. On this new evidence she was submitted to MRI with diagnosis of Bicorporeal Uterus. After several hours of continuous oxytocin infusion, the woman had vaginal blood loss and pain relief. 2D TV-US reevaluation showed both endometrial cavities empty and the patient was discharged. At two weeks later follow up 3D ultrasound confirmed MRI diagnosis of U3 CUA (Figure 1).

The second case is a 30 year-old primigravida admitted with the diagnosis of extra uterine left tubaric pregnancy. She was at 7+1 weeks of amenorrhea. Her levels of beta- HCG blood dosage consecutively increased from 962-9494, reaching 9892 mUI/mL. She complained a high pain in the left adnexal fossa. Her blood pressure and cardiac frequency were stable. She referred a history of primary dysmenorrhea. Abdominal examination showed a slight tenderness in left iliac fossa. The bimanual vaginal examination revealed the

*Corresponding author: Riganelli Lucia, Department of Gynecology and Obstetrics, "Sapienza" University of Rome, Umberto I Policlinico, Rome, Italy, Tel: +393928994062; Fax: +390649973128; E-mail: lu.riganelli@gmail.com

Received January 02, 2016; Accepted March 22, 2016; Published March 27, 2016

Citation: Riganelli L, Savone D, Salerno L, Carrone A, Casorelli A, et al. (2016) Early Diagnosis of Congenital Uterine Anomalies: Is the Three Dimensional Ultrasound Approach the Suitable Choice? 3D in Uterine Anomalies. J Clin Case Rep 6: 752. doi:10.4172/2165-7920.1000752

Copyright: © 2016 Riganelli L, et al. This is an open-access article distributed under the terms of the Creative Commons Attribution License, which permits unrestricted use, distribution, and reproduction in any medium, provided the original author and source are credited.

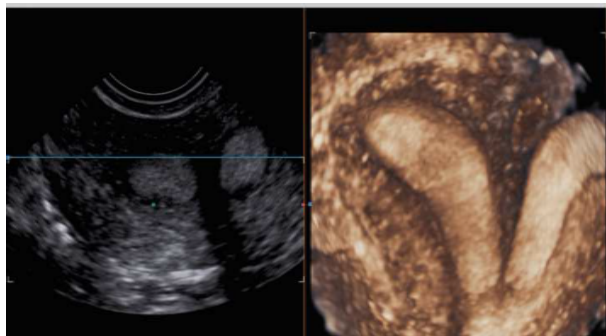


Figure 1: 3D reconstruction of Bicorniporeal Uterus U3 (Eshre, Congenital Uterine Anomalies classification).

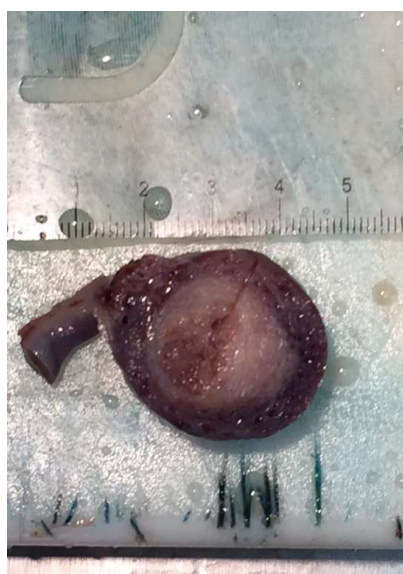


Figure 2: Macroscopic coronal sections of the horn pregnancy, directly communicating with fallopian tube.

absence of pathological discharge and no cervical motion tenderness. Haemoglobin preoperative level was 12.9 mg/dL. 2D TV-US revealed a lesion including a gestational sac containing an embryo of 4 mm CRL with cardiac activity and fluid in the pouch of Douglas. This lesion was localized close to the normal uterus and left ovary in the adnexal region. Her beta-HCG dosage was 21872 mUI/mL. She underwent operative laparoscopy with removal of the left ectopic pregnancy. No intra and post-operative complications occurred and the patient was discharged on the first post-operative day. Histology revealed an interstitial pregnancy located into a rudimentary uterine horn (Figure 2 and 3).

The third case is a 12 years-old girl presented with primary dysmenorrhea after recent menarche, not responding to the normal anti-inflammatory drugs. She was submitted to 3D pelvic TA-US examination with diagnosis of U4. In particular she had a bicorniporeal uterus with a rudimentary left horn and hematocolpos. The patient, after a period of contraceptive use, was submitted to operative laparoscopy with removal of the left horn. At follow up she restored her normal physiology.

Discussion

In spite of the presence of numerous imaging modalities, in a suspect of CUA by clinical findings as primary dysmenorrhea, pelvic pain, recurrent miscarriage and infertility, the first line diagnostic tool still remains 2D TV-US. However, its diagnostic accuracy is limited in recognizing CUA [14]. In non-sexually active patients, 2D TA-US is the first choice but it has limited resolution with consequent very low accuracy. For these reasons a second line diagnostic exam is required. MRI has been growing in popularity as the ideal imaging modality, by virtue of its non-invasiveness, lack of ionizing radiations, capability for multiplanar imaging and soft tissue characterization, enabling clear demonstration of the external uterine fundal contour [15,16]. Although it is an ideal technique it has high costs effectiveness and requires a specialistic care centre.

3D is becoming an increasingly feasible way of evaluating the assessment of Mullerian uterine anomalies, and it has been considered a helpful tool in association to 2D imaging for CUA evaluation [17]. Particularly, 3D procedure allows easier visualization with a detailed reconstruction of any pelvic structure plane. Furthermore, 3D imaging can produce these images faster than MRI in outpatient setting. In literature [12,13] the accuracy of 3D-US is reported to be near to 100% when compared to hysteroscopy and laparoscopy in CUA diagnosis. Regarding cost-effectiveness, 3D-US can provide extensive information with lower costs compared to the previously mentioned diagnostic modalities [18]. 3D is feasible, reproducible and less expensive technique. It seems to be accurate as well as the common invasive procedure known as the gold standard strategy and MRI to identify CUA. In our case series, the first woman underwent a surgical approach without an accurate preoperative evaluation with consequent misdiagnosis. In the second case a correct diagnosis could have prevented the complication of cornual pregnancy. The third case is explicative in term of correct management in CUA: the 3D-US with diagnosis of U4 allowed the surgical repair.

The rarity and unusual presentation may contribute to a diagnostic delay, resulting frequently in an emergency intervention. If accurately diagnosed, the use of hormonal therapy followed by laparoscopic approach are the elective procedure to remove the rudimentary horn [19]. Based on this evidence, early identification of this condition decreases the long-term morbidity in terms of gynecologic and obstetric complications (i.e. primary dysmenorrhea, dyspareunia,

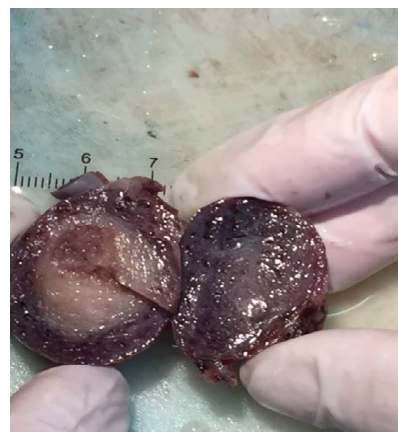

Figure 3: Macroscopic coronal sections of the horn pregnancy, directly communicating with fallopian tube.

secondary infertility, endometriosis, spontaneous abortion, preterm labor, ectopic rudimentary horn, uterine rupture) [20]. Further studies are needed to assess which imaging method is the suitable choice in CUAs diagnose. Although we report few cases, we encourage the use of 3D-US as first diagnostic tool for its rapidity of execution, non-invasiveness and acceptable costs. In our opinion we might avoid MRI use, considered as the second line technique after 2-US, keeping in mind that in CUAs, the diagnostic accuracy of 3D-US is the same of MRI. In symptomatic patients with suspicious of CUA, is mandatory to diagnose earlier this condition in a safe, non-invasive and less expensive way, in order to manage properly the possible surgical approach and to prevent misdiagnosis and future complications.

References

1. Chan YY, Jayaprakasan K, Zamora J, Thornton JG, Raine-Fenning N, et al. (2011) The prevalence of congenital uterine anomalies in unselected and high-risk populations: a systematic review. *Hum Reprod Update* 17: 761-771.
2. Moore KL, Persaud TVN, Torchia MG (2008) The urogenital system. In: *Before We Are Born: Essentials of Embryology and Birth Defects*. Philadelphia, U.S.A.
3. Alborzi S, Dehbashi S, Parsanezhad M (2002) Differential diagnosis of septate and bicornuate uterus by sonohysterography eliminates the need for laparoscopy. *Fertil Steril* 78:176-178
4. Grimbizis GF, Gordts S, Di Spiezio Sardo A, Brucker S, et al. (2013) The ESHRE/ESGE consensus on the classification of female genital tract congenital anomalies. *Hum Reprod*; 28: 2032-2044.
5. Pellerito JS, McCarthy SM, Doyle MB, Glickman MG, et al. (1992) Diagnosis of uterine anomalies: relative accuracy of MR imaging, endovaginal ultrasound, and hysterosalpingography. *Radiology* 183: 795-800.
6. Nicolini U, Bellotti M, Bonazzi B, Zamberletti D, Candiani GB (1987) Can ultrasound be used to screen uterine malformations? *Fertil Steril* 47: 89-93.
7. Fedele L, Ferrazzi E, Dorta M, Vercellini P, Candiani GB (1988) Ultrasonography in the differential diagnosis of "double" uteri. *Fertil Steril* 50: 361-364.
8. Spence J, Gervaise P, Jain S (2003) Uterovaginal anomalies: diagnosis and current management in teens. *Curr Womens Health Rep* 3: 445-450.
9. Troiano RN, McCarthy SM (2004) Mullerian duct anomalies: imaging and clinical issues. *Radiology* 233: 19-34.
10. Mueller GC, Hussain HK, Smith YR, Quint EH, Carlos RC, et al. (2007) Müllerian duct anomalies: comparison of MRI diagnosis and clinical diagnosis. *AJR Am J Roentgenol* 189: 1294-1302.
11. Luciano DE, Exacoustos C, Luciano AA (2014) Contrast ultrasonography for tubal patency. *J Minim Invasive Gynecol* 21:994-8.
12. Ghi T, Casadio P, Kuleva M, Perrone AM, Savelli L, et al. (2009) Accuracy of three-dimensional ultrasound in diagnosis and classification of congenital uterine anomalies. *Fertil Steril* 92: 808-813.
13. Raga F, Bonilla-Musoles F, Blanes J, Osborne NG (1996) Congenital Mullerian anomalies: diagnostic accuracy of three-dimensional ultrasound. *Fertil Steril* 65: 523-528.
14. Lang IM, Babyn P, Oliver GD (1999) MR imaging of paediatric uterovaginal anomalies. *Pediatr Radiol* 29: 163-170.
15. Behr SC, Courtier JL, Qayyum A (2012) Imaging of Mullerian duct anomalies. *Radiographics* 32: 233-250.
16. Haimovici JBA, Tempany CMC (1997) MR of the female pelvis: Benign disease. *Applied Radiology* 26: 7-22.
17. Acién P, Acién M, Sánchez-Ferrer ML (2009) Müllerian anomalies "without a classification": from the didelphys-unicollis uterus to the bicervical uterus with or without septate vagina. *Fertil Steril* 91:2369-2375.
18. Moini A, Mohammadi S, Hosseini R, Eslami B, Ahmadi F (2013) Accuracy of 3-dimensional sonography for diagnosis and classification of congenital uterine anomalies. *J Ultrasound Med* 32: 923-927.
19. Jayasinghe Y, Rane A, Stalewski H, Grover S (2005) The presentation and early diagnosis of the rudimentary uterine horn. *Obstet Gynecol* 105: 1456-1467.
20. Heinonen PK (1997) Unicornuate uterus and rudimentary horn. *Fertil Steril* 68: 224-230.

Citation: Riganelli L, Savone D, Salerno L, Carrone A, Casorelli A, et al. (2016) Early Diagnosis of Congenital Uterine Anomalies: Is the Three Dimensional Ultrasound Approach the Suitable Choice? 3D in Uterine Anomalies. *J Clin Case Rep* 6: 752. doi:[10.4172/2165-7920.1000752](https://doi.org/10.4172/2165-7920.1000752)

OMICS International: Publication Benefits & Features

Unique features:

- Increased global visibility of articles through worldwide distribution and indexing
- Showcasing recent research output in a timely and updated manner
- Special issues on the current trends of scientific research

Special features:

- 700+ Open Access Journals
- 50,000+ editorial team
- Indexing at major indexing services
- Rapid review process
- Quality and quick editorial, review and publication processing
- Indexing at major indexing services
- Sharing Option: Social Networking Enabled
- Authors, Reviewers and Editors rewarded with online Scientific Credits
- Better discount for your subsequent articles

Submit your manuscript at: <http://www.omicsonline.org/submission/>