



Ropivacaine vs tetracaine in topical anesthesia for intravitreal injection

Fernanda Pacella¹, Saul Collini², Paolo Turchetti³, Gianpaolo Smaldone¹, Fabiana Troisi⁴, Mauro Salducci¹, *Elena Pacella¹

¹Department of Sense Organs, Faculty of Medicine and Dentistry Sapienza University of Rome, Italy.

²Department of Medical-Surgical Sciences and Translational Medicine, University Sapienza of Rome, Italy.

³National Institute for Health, Migration and Poverty (INMP/NIHMP), Rome, Italy.

⁴Anesthesia and Intensive Care Sant'Andrea Hospital, Rome, Italy.

***Corresponding author** Elena Pacella, Department of Sense Organs, Faculty of Medicine and Dentistry "Sapienza" University of Rome, viale del Policlinico - Clinica Oculistica, 00161 Rome (ITALY) Tel: +39 0649975303 - +39 336783409; e-mail: elena.pacella@uniroma1.it

Article history

Received: December 2, 2015

Accepted: December 28, 2015

Published: December 31, 2015

Abstract

Aim: The object of the study was to evaluate the long term efficacy and safety of ropivacaine 0,5% vs tetracaine 0,5% for topical anesthesia in intravitreal injection

of dexamethasone in patients with diabetic macular edema (DME) and anti-vascular endothelial growth factor (VEGF) therapy.

Methods: Thirty-seven patients were enrolled in the study. Intravitreal anti-vascular endothelial growth factor (VEGF) and Dexamethasone were placed in DME patients.

Intravitreal administration determines appropriate and long-lasting drug's concentration without systemic side effects. Topical anesthesia under ropivacaine 0,5% vs tetracaine 0,5% was performed.

Results: Intravitreal injection without any supplemental anesthesia and sedation was realized. Patients reported mild pain (recorded by a 0 to 10 scale) during the procedure with optimal operative result.

Conclusions: Topical anesthesia with ropivacaine and tetracaine is safe and effective in intravitreal injection. The long-lasting anesthesia secured low pain during this limited but unpleasant procedure.

Keywords: ropivacaine vs tetracaine; anesthesia topical; intravitreal injection

Introduction

Intravitreal drugs administration determines appropriate and long-lasting pharmacological concentration with reduced systemic side effects [1]. Intravitreal injection obtain effective drug's concentration in limited time [1,2]. Frequently, intravitreal procedures are considered for retinopathy treatment of age related Macular Degeneration, wet variant (ARMD) [3], in Diabetic Proliferant and in related Macular Edema [4], in

uveitis [5-8], in retinal occlusion [1], in high myopia[9]. In these pathologies, therapeutic protocols refer to drugs with different pharmaceutical characteristics, at rates ranging from 4 to 6 weeks for 1-2 years, injected in the bulbar space. This strategy prevent angiogenesis, reduce retinal edema, improves the best visual acuity (BVA)[10]. The injection technique requires antiseptic maneuvers in the operating room and local anesthetics utilization [11]. The procedures of topical anesthesia consist in: instillation of eye drops or gel, placing of a cotton swab

soaked in anesthetic below the upper eyelid, subconjunctival injection of lidocaine solutions or peribulbar block [12-14].

In the meantime, to secure more comfortable procedures, new and more effective topical anesthetic agents were tested in ocular surgery [15], in particular in phacoemulsification procedures for cataract surgery: Oxibuprocaina, Bupivacaine, Lidocaine 1%, Ropivacaine 0,5 % and 1% [16-20].

At present there are no studies that emphasize the methods of administration and the best local anesthetic agents for patient's analgesia [21], nor standardized anesthesia's protocols of intravitreal injections for the control of patient's discomfort [22]. The subconjunctival and peribulbar anesthesia, while causing better analgesia, also involving the iris and ciliary body, compared with the drop's instillation, often result to be painful and less tolerated [23]. Thus, the purpose of the present study was to evaluate the efficacy and safety of Ropivacaine 0,5% solutions vs Tetracaine 0.5 % eyedrops and cotton swab soaked with cocaine 4% in patients receiving intravitreal therapy.

Ropivacaine is a long-lasting anesthetic agent with reduced systemic effects; we evaluated the efficacy of ropivacaine for topical anesthesia in intravitreal injection.

Materials and Methods

Patients

In this clinical randomized trial 48 patients, from March 2015 to November 2015, divided in two groups each, 24 to A group and 24 to B group, respectively medicated with Ropivacaine 0,5% solution and Tetracaine 0.5% eyedrops with cocaine 4% cotton swab. Demographic data of the patients are reported in **Table 1**.

Table 1. Demographic of subjects included in the study.

Demographic and clinical features	
Age	66.34 ± 9.35
Gender	32M/16F

Data are expressed as mean±standard deviation M: male; F: female

This study received the approval of the Institutional Review Board of the Sapienza University of Rome and was in agreement with the Helsinki Declaration. All patients received full informations and a written informed consent was obtained from each patient.

Treatment

All injections were performed under sterile conditions, after Ropivacaine 0,5% solution (Naropine®,

AstraZeneca, UK) to patients of A group and Tetracaine 0.5% eyedrops in group B, one drop every 5 minutes for five times were administered, before positioning of blepharostat and surgery [24].

No preoperative or intraoperative sedative was administered. All operations were performed by two surgeons with the same standardized technique.

Inclusion criteria

Inclusion criteria were: age ≥ 18 and patients requiring intravitreal injection therapy.

Exclusion criteria were previous allergic reaction to local anesthetics, psychiatric diseases, pregnancy, anxiety, deafness, and languages barriers. Our patients had a complete ophthalmologic examination before the surgery, including in particular best-corrected visual acuity and slit-lamp biomicroscopy of the anterior segment.

Evaluations

At the end of the procedure, patients were asked to answer about the pain experienced during the administration of the Ropivacaine 0,5% solution in group A patients and Tetracaine 0.5% eyedrops in B group patients, during the intravitreal injection, and the immediate postoperative period.

The pain level perceived by the patients was classified with two scales: the VAS (visual analogue scale) pain score from 0 (no pain) to 10 (the worst pain) according to Functional Oksuz et al [25], and the WB (Wong-Baker) FACES pain score [26, 27].

The latter one was evaluated by the assistant surgeon, based on the expression of the patient's face during injection (**Fig. 1**). Such scales have already been used in ophthalmic trials of pain [28] and analgesia [29].

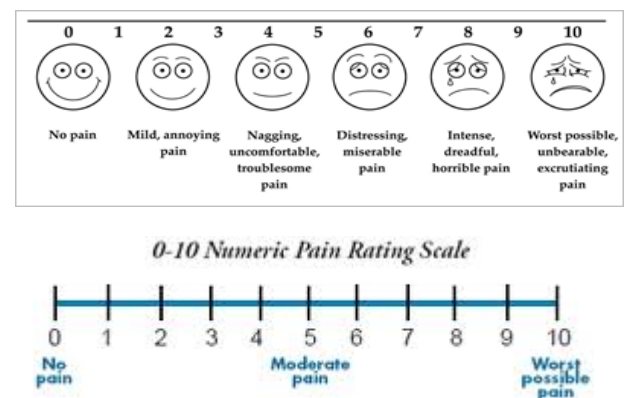


Fig. 1 VAS (Visual Analogue Scale) for pain (above) e WB (Wong-Baker) FACES pain rating scale (under), for intravitreal pain test.

Efficacy criteria

Primary outcome included the efficacy of Ropivacaine 0,5% solution versus Tetracaine 0.5% eyedrops with cocaine 4% cotton swab, for topical anesthesia in intravitreal injection. Secondary outcome considered the safety and tolerance of the anesthetic agents during the procedure.

Statistical analysis

We used the Student's t test to evaluate the result's statistical significance in the two groups. The **Tables 2** highlights the average value of each group with respect to both scales, while **Table 3** evidences the result of Student T test, setting the VAS pain score to $p = 0.80$ and WB faces pain score to $p = 0.56$. The differences between the scores are not statistically significant, thus the analgesic effect of two anesthetic agents can be considered analogue.

Table. 2 Visual Analog Scale (VAS) and Wong - Baker Faces Score (WB FACES pain score) average value

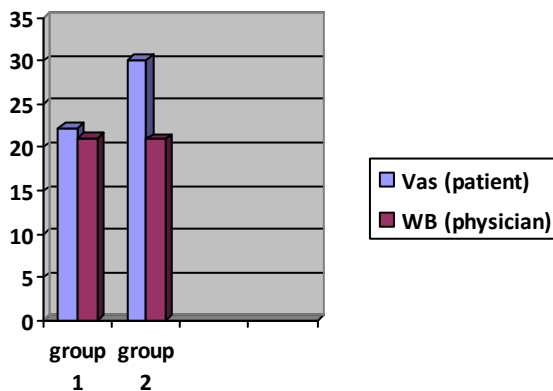


Table. 3 Student T test ($p < 0.05$)

GROUPS	VAS	WB
Group 1	22.24±4.01	3.12±1.80
Group 2	21.12±4.76	2.92±1.60
<i>P value</i>	0.80	0.56

Results

The average procedure time was 11 minutes. During intravitreal injection, the average pain score was 22.24 ± 4.01 in group A e 21.12 ± 4.76 in group B. None local or systemic adverse events resulted from the topical Ropivacaine and Tetracaine administration; all the procedures were fulfilled without any supplemental anesthesia or sedative drugs administration.

Complications

One patient suffered for a subconjunctival hemorrhage, dependent on intravitreal injection, spontaneously receded after ten days.

None of the patients evidenced ophthalmic or systemic noteworthy side effect in the immediate postoperative period.

The control visit after seven days excluded corneal endothelium damages or any other problem depending on local anesthetics administration.

Discussion

The intravitreal injection procedures represent the reference therapeutic methodology for the management of retinal pathologies². Subconjunctival infiltration of anesthetic agents and peribulbar block can be an unpleasant experience for patients scheduled for intravitreal procedure. Our interest was to make the intravitreal treatment more comfortable for those patients who are opposed to the procedure under topical anesthesia [28].

We tested the effectiveness of Ropivacaine 0,50% solution versus Tetracaine 0.5% eyedrops with cocaine 4% cotton swab, for topical anesthesia. These anesthetic agents proved adequate analgesia for cataract surgery and high safety level with limited systemic adverse events. [16,18,20].

The literature is unanimous in recognizing the lack of standardized guidelines about the reference anesthetic technique for intravitreal injection. The subconjunctival local anesthetics and peribulbar block are both painful and often not well tolerated by the patient [11, 12,14, 20]

Cintra [22] compares topical anesthesia with subconjunctival infiltration and peribulbar block, evidencing similar results between subconjunctival and topical technique. Peribulbar block is higher but definitely more invasive and painful of eyedrops. Kaderli et al [12] compared topical anesthesia with subconjunctival lidocaine 4% ; the latter obtained greater analgesia, resulting more painful and associated with increased risk of subconjunctival hemorrhage.

Kozak et al [12] and Friedman et al. [14] confirmed that topical anesthesia with 2% lidocaine gel and the subconjunctival infiltration are likewise analgesics. A randomized trial, comparing the analgesic efficacy of Proparacaine, Tetracaine, Lidocaine swab and subconjunctival injection of Lidocaine, excluded significant differences [23]. A further study compared the effectiveness of Levobupivacaine vs Bupivacaine in peribulbar anesthesia observed that Levobupivacaine is safe and useful even in elderly patients compared to general anesthesia [20].

We employed low dosage Ropivacaine 0.5% to limit corneal toxicity; only 0.01% ropivacaine in vitro was considered non-toxic, in the absence of anesthetic effect [30]. Our choice was free of any corneal damage after seven days.

The results emerging from our study did not show a statistically significant difference in pain perception in both groups of patients considered. The pain level, evaluated both with VAS score or with the assistant one's (WB faces pain score), it is similar with both anesthetic agents.

Anyway, topical anesthesia was less invasive and side effects free of subconjunctival and peribulbar techniques. The pain resulting from the puncture, the risk of chemosis and subconjunctival hemorrhage, together with higher skills needed and, not least, higher costs, limited the loco-regional techniques to patients with subjective problems.

The inability to avoid eye's movement, the low pain threshold and the anxiety condition are the major contraindication to topical anesthesia for intravitreal procedures.

Therefore, the outcomes were maintained: topical anesthesia with Ropivacaine, and Tetracaine were effective because they provided adequate analgesia, or mild pain; the anesthetic technique was minimally invasive and no apparent toxicity or systemic side effects occurred.

Conflict of Interest

The Authors declare that there are no conflicts of interest.

References

1. Pacella, E.; Pacella, F.; La Torre, G.; et al. Testing the effectiveness of intravitreal Ranibizumab during 12 months of follow-up in venous occlusion treatment *Clinica terapeutica*. 163, 6 Supplement: S, E413-E422.
2. Aiello LP, Brucker AJ, Chang S. et al. Evolving guidelines for intravitreal injections. *Retina*. 2004 Oct;24(5 Suppl):S3-19
3. Balaratnasingam C, Dhrami-Gavazi E, McCann JT, Ghadiali Q, Freund KB. Aflibercept: a review of its use in the treatment of choroidal neovascularization due to age-related macular degeneration. *Clin Ophthalmol*. 2015
4. Pacella, E.; La Torre, G.; Impallara, D.; et al.
5. Zhang R, He R, Qian J, Guo J, Xue K, Yuan YF. Treatment of experimental autoimmune uveoretinitis with intravitreal injection of tacrolimus (FK506) encapsulated in liposomes. *Invest Ophthalmol Vis Sci*. 2010 Jul;51(7):3575-82. doi: 10.1167/iovs.09-4373. Epub 2010 Feb 17.
6. Bianchi E, Scarinci F, Ripandelli G, Feher J, Pacella E, Magliulo G, Gabrieli CB, Plateroti R, Plateroti P, Mignini F, Artico M. Retinal pigment epithelium, age-related macular degeneration and neurotrophic keratouveitis. *International Journal of molecular Medicine*, 2013, 1: 232-242.
7. Multicenter Uveitis Steroid Treatment (MUST) Trial Follow-up Study Research Group. Quality of Life and Risks Associated with Systemic Anti-inflammatory Therapy versus Fluocinolone Acetonide Intraocular Implant for Intermediate Uveitis, Posterior Uveitis, or Panuveitis: Fifty-four-Month Results of the Multicenter Uveitis Steroid Treatment Trial and Follow-up Study. *Ophthalmology*. 2015 Oct;122(10):1976-86.
8. Pacella F., Smaldone G., Albanese G., et all. Treatment chronic macular edema in Vogt-Koyanagi Harada syndrome with dexamethasone intravitreal implant: Description of Three Case. *Senses Sci* 2015; 2 (1):57 -63 doi: 10.14616/sands-2015-1-57 63.
9. Zhang Y, Han Q, Ru Y, Bo Q, Wei RH. Anti-VEGF treatment for myopic choroid neovascularization: from molecular characterization to update on clinical application. *Drug Des Devel Ther*. 2015 Jul 2;9:3413-21.
10. Girmens JF, Glacet-Bernard A, Kodjikian L, Nghiêm-Buffet S, Massé H, Fourmaux E, Wolff B, Roquet W, Gaucher D, Baillif S, Tadayoni R. Management of macular edema secondary to retinal vein occlusion]. *J Fr Ophtalmol*. 2015 Mar;38(3):253-63.
11. Kaderli B, Avci R. Comparison of topical and subconjunctival anesthesia in intravitreal injection administrations. *Eur J Ophthalmol*. 2006 Sep-Oct;16(5):718-21
12. Kozak I, Cheng L, Freeman WR. Lidocaine gel anesthesia for intravitreal drug administration. *Retina*. 2005 Dec;25(8):994-8
13. Pacella E., Collini S., Pacella F. et al. Levobupivacaine vs. racemic bupivacaine in peribulbar anaesthesia: a randomized double blind study in ophthalmic surgery. *Eur Rev Med Pharmacol Sci* 2010; 14 (6) : 539-544
14. Friedman SM, Margo CE. Topical gel vs subconjunctival lidocaine for intravitreal injection: a randomized clinical trial. *Am J Ophthalmol*. 2006 Nov;142(5):887-8
15. Pacella, E; Abdolrahimzadeh, S; Gabrieli, CB. Excimer laser photorefractive keratectomy for hyperopia. *Ophthalmic Surgery and Laser*. 32.,: 1; 30-34
16. Borazan M, Karalezli A, Akova YA, et al. Comparative clinical trial of topical anaesthetic

- agents for cataract surgery with phacoemulsification: lidocaine 2% drops, levobupivacaine 0.75% drops, and ropivacaine 1% drops. *Eye*. 2008;22:425–429.
17. Lorusso V., Moramarco A, Pacella E; et al. Intraocular lens complications. 1990. *Ann. Ophthalmol.*, 22: 377-381
 18. Pacella E; Abdolrahimzadeh B; Brauneis, S et al. Efficacy of preoperative systemic clonidine for intraocular pressure reduction in ophthalmic surgery. *Annals of Ophthalmol*: 2001;33: 2: 116-118.
 19. Martini E, Cavallini GM, Campi L, et al. Lidocaine versus ropivacaine for topical anesthesia in cataract surgery. *J Cataract Refract Surg*. 2002;28:1018–1022.
 20. Pacella E, Pacella F, Troisi F, Dell'edera D, Turchetti P, Lenzi T, Collini S. Efficacy and safety of 0.5% levobupivacaine versus 0.5% bupivacaine for peribulbar anesthesia. *Clin Ophthalmol*. 2013;7:927-32.
 21. Yau G.L., Jackman C.S., Hooper P.L. et al. Intravitreal injection anesthesia-comparison of different topical agents: a prospective randomized controlled trial. *Am J Ophthalmol* 2011 Feb;151(2):333-7.e2.
 22. Cintra LP, Lucena LR, Da Silva JA et al. Comparative study of analgesic effectiveness using three different anesthetic techniques for intravitreal injection of bevacizumab. *Ophthalmic Surg Lasers Imaging*. 2009 Jan-Feb;40(1):13-8
 23. Blaha GR, Tilton EP, Barouch FC et al. Randomized trial of anesthetic methods for intravitreal injections. *Retina* 2011 - Mar;31(3): 535-9
 24. Pacella E, Vestri AR, Muscella R, Carbotti MR, Castellucci M, Coi L, Turchetti P, Pacella F. Preliminary results of an intravitreal dexamethasone implant (Ozurdex®) in patients with persistent diabetic macular edema. *Clin Ophthalmol*. 2013;7:1423-8.
 25. Karakayali F, Oksuz E, Turk E et al. Effectiveness of multiple neurectomies to prevent chronic groin pain after tension-free hernia repair. *Int Surg*. 2010 Jan-Mar;95(1):40-8.
 26. Wilson GA, Doyle E. Validation of three pediatric pain scores for use by parents. *Anaesthesia*. 1996 Nov;51(11):1005-7
 27. Chambers CT, Giesbrecht K, Craig KD et al. A comparison of faces scales for the measurement of pediatric pain: children's and parents' ratings. *Pain*. 1999 Oct;83(1):25-35
 28. Morris B, Watts P, Zatman T et al. Pain relief for strabismus surgery in children: a randomised controlled study of the use of preoperative sub-Tenon levobupivacaine. *Br J Ophthalmol*. 2009 Mar;93(3):329-32. Epub 2008 Dec 3
 29. Haas P, Falkner-Radler C, Wimpfissinger B, et al. Needle size in intravitreal injections - pain evaluation of a randomized clinical trial. *Acta Ophthalmol*. 2015 Nov 2.
 30. Soker S1, Cakmak S, Olmez G, Buyukbayram H, Nergiz Y. Investigation of the toxic effects of ropivacaine corneal endothelium by the impression cytological method. *Saudi Med J*. 2007 Jul;28(7):1018-20.