

## Case Report

# Accessory belly of piriformis, as a cause of superior gluteal neurovascular entrapment

Rimple Bansal<sup>1\*</sup>, Subhash Kaushal<sup>2</sup>, Usha Chhabra<sup>3</sup>

<sup>1</sup>Assistant Professor, Department of Anatomy, MMIMSR, Mullana (Ambala), Haryana, India

<sup>2</sup>Professor and Head, Department of Anatomy, MMIMSR, Mullana (Ambala), Haryana, India

<sup>3</sup>Professor, Department of Anatomy, GMC, Patiala, India

**Received:** 17 May 2013

**Accepted:** 30 May 2013

**\*Correspondence:**

Dr. Rimple Bansal,

E-mail: rimpledr79@gmail.com

© 2013 Bansal R et al. This is an open-access article distributed under the terms of the Creative Commons Attribution Non-Commercial License, which permits unrestricted non-commercial use, distribution, and reproduction in any medium, provided the original work is properly cited.

### ABSTRACT

During routine dissection on 50 years old male cadaver, an accessory belly of piriformis was observed. This accessory belly was superior and parallel to the main piriformis muscle. This was associated with emergence of superior gluteal nerve and superior gluteal artery between the two bellies. Piriformis muscle and its relation to sciatic nerve has been suggested as a cause of piriformis syndrome. But interestingly in the present case, superior gluteal nerve was interposed between two bellies that may help the clinicians to establish a rare yet important cause of piriformis syndrome and a rare cause of undiagnosed chronic pain in gluteal region. As superior gluteal artery was also interposed, so this rare variation holds interest to surgeons especially in isolated buttock claudication despite otherwise normal vascular investigations.

**Keywords:** Anatomical muscle variation, Accessory piriformis muscle, Isolated buttock claudication, Piriformis syndrome, Superior gluteal nerve entrapment

### INTRODUCTION

The piriformis is the uppermost of the small muscles of the gluteal region and the key to the arrangement of nerves and vessels in the buttock. The vessels and nerves typically emerge above and below the piriformis. Thus, any anatomical variation of this muscle may be of clinical importance. It originates from the pelvic surface of sacrum by three digitations, gluteal surface of ilium near posterior inferior iliac spine and capsule of adjacent sacroiliac joint and passes out of the pelvis through greater sciatic foramen, which it substantially fills and gets inserted into the medial side of upper border of greater trochanter of femur via a rounded tendon. It is innervated by the first and second sacral nerves.<sup>1</sup>

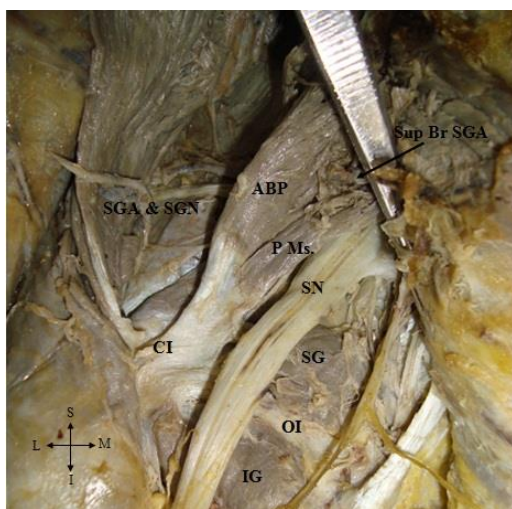
The morphology of the piriformis may be evaluated reliably via MRI scans, and the presence of an accessory belly of piriformis may be detected timely.<sup>2</sup> Therefore, variations of piriformis should be listed in clinical anatomy and radiology textbooks.

Here, we report an important variation of piriformis muscle especially for the benefit of clinicians and radiologists.

### CASE REPORT

Following routine dissection of left gluteal region of 50 years old male cadaver, an accessory belly of piriformis was observed (Figure 1), originating from dorsal aspect of hip bone close to the margin of greater sciatic notch.

This accessory belly was superior and parallel to the main piriformis muscle. The accessory belly was larger and thicker than the main piriformis muscle. The tendon of accessory belly merged with main piriformis before its insertion and had a common insertion with gemellus superior, obturator internus and gemellus inferior on the greater trochanter of the femur. The innervation of accessory belly was derived from first and second sacral nerves. It was further observed that superior gluteal nerve and artery emerged between the two bellies. Out of which superior gluteal nerve and deep branch of superior gluteal artery coursed deep to the accessory belly and ended by supplying gluteus medius, gluteus minimus and tensor fascia lata, whereas superficial branch of superior gluteal artery was found entering the gluteus maximus by passing between accessory belly and piriformis muscle.



**Figure 1: Dissected left gluteal region (SGA: Superior gluteal artery, SGN: Superior gluteal nerve, Sup Br SGA: Superficial branch of superior gluteal artery, ABP: Accessory belly of piriformis, PMs: Main piriformis muscle, SN: Sciatic nerve, SG: Superior Gemellus, OI: Obturator internus, IG: Inferior gemellus, CI: Common insertion).**

## DISCUSSION

It is not rare for the piriformis to be penetrated by some structures which are supposed to pass through greater sciatic foramen in the normal anatomical position. This is usually associated with high division of sciatic nerve with the peroneal portion of sciatic nerve emerging between the two heads. The muscle is rarely divided by the tibial division of sciatic nerve or by the entire sciatic nerve. The cleavage generally affects only the muscle belly, although it may involve the entire muscle.<sup>3</sup> But the surprising observations in the present study were interposition of superior gluteal nerve and superior gluteal artery between accessory belly and piriformis muscle. This is an extremely rare finding, which can be rare cause of undiagnosed chronic pain in the gluteal region.

The superior gluteal nerve and vessels passing between the two bellies may become compressed if the muscle hypertrophies. Diop et al have reported a case of superior gluteal nerve entrapment in the suprapiriformis foramen.<sup>4</sup>

Compression of superior gluteal nerve as in this case could result in functional impairment; especially of gluteus medius, gluteus minimus and tensor fascia lata and may influence the stability of hip joint. Additionally ipsilateral muscle weakness may accompany the above symptomatology.<sup>5</sup>

The superior gluteal artery is the largest branch of internal iliac artery and leaves the pelvis by the greater sciatic foramen above the piriformis and divides into superficial and deep branches. The superficial branch supplies the gluteus maximus and deep branch supplies the gluteus medius, gluteus minimus and tensor fascia lata.<sup>6</sup>

Although, ischemic buttock claudication is due to lesions of common iliac or internal iliac vessels but it can also be caused by isolated stenosis of the superior gluteal artery in the absence of atheromatous involvement of other arteries.<sup>7</sup> The observation of superior gluteal artery stenosis in the absence of atheromatous disease suggests the existence of an anatomic cause as seen in present case.

## CONCLUSION

In conclusion, to our knowledge, not many cases of accessory piriformis with interposition of superior gluteal nerve and superior gluteal artery between accessory belly and piriformis muscle have been reported previously. Neuronal and ischemic changes may be observed due to contracture of piriformis in such a case which may go undiagnosed. Hence present report of rare morphological variations holds interest not only to anatomists but also to surgeons as well as radiologists, as a rare cause of undiagnosed chronic pain in gluteal region and in isolated buttock claudication despite otherwise normal vascular investigations.

*Funding: None*

*Conflict of interest: None declared*

*Ethical approval: Not required*

## REFERENCES

1. Williams A, Newell RLM. Pelvic girdle, gluteal region and hip joint. In: Standring S. Gray's Anatomy. The anatomical basis of clinical practice, Elsevier Churchill Livingstone, 39<sup>th</sup> Edition;2004:1419.
2. Russell JM, Krausderl MJ, Bancraft LW, Peterson JJ, Berquist TH, Bridges MD. Magnetic resonance imaging of the sacral plexus and piriformis muscles. Skeletal Radiol 2008;37:709-13.

3. Anson BJ, Mcvay CB. *Surgical Anatomy*, WB Saunders Company/ Philadelphia London Toronto, 5<sup>th</sup> Edition;1971:1087-8.
4. Diop M, Parratte B, Tatu L, Vuillier F, Faure A, Monnier G. Anatomical bases of superior gluteal nerve entrapment syndrome in the suprapiriformis foramen. *Surg Radiol Anat* 2002;24:155-9.
5. Yadav Y, Mehta V, Roy S, Suri S, Rath G. Superior gluteal nerve entrapment between two bellies of piriformis muscle. *IJAV* 2010;3:203-4.
6. Moore KL, Dalley AF. Lower limb. In *clinical oriented anatomy*, Lippincott Williams & Wilkins, 5<sup>th</sup> Edition; 2006:624.
7. Batt M, Desjardin T, Rogupoulos A, Hassen-Khodja, Le Bas. Buttock claudication from isolated stenosis of gluteal artery. *J Vasc Surg* 1997;25:584-6.

DOI: 10.5455/2320-6012.ijrms20130830

**Cite this article as:** Bansal R, Kaushal S, Chhabra U. Accessory belly of piriformis, as a cause of superior gluteal neurovascular entrapment. *Int J Res Med Sci* 2013;1:296-8.