

DOI: <http://dx.doi.org/10.18203/2320-1770.ijrcog20163024>

Case Report

Primary ovarian pregnancy: early diagnosis still a myth

Suman Lata Mendiratta^{1*}, Smriti Anand¹, Rajni Mittal¹, Farheen Khan¹, Namrata Nargotra²

¹North DMC Medical College and Hindurao Hospital, Delhi, India

²Department of Pathology, North DMC Medical College and Hindurao Hospital, Delhi, India

Received: 15 July 2016

Accepted: 10 August 2016

*Correspondence:

Dr. Suman Lata Mendiratta,

E-mail: sumanmendi@yahoo.co.in

Copyright: © the author(s), publisher and licensee Medip Academy. This is an open-access article distributed under the terms of the Creative Commons Attribution Non-Commercial License, which permits unrestricted non-commercial use, distribution, and reproduction in any medium, provided the original work is properly cited.

ABSTRACT

Primary ovarian pregnancy occurs quite rarely accounting for 1 to 3%. And that too usually in young highly fertile multiparous women using intra uterine device and is associated with rupture very early in the gestation. We present a case where a young primigravida presented with abdominal pain and was diagnosed as ectopic pregnancy and was confirmed intra-operatively and histopathologically as primary ovarian pregnancy, managed with partial ovariectomy.

Keywords: Laparotomy, Ovarian pregnancy, Ectopic, Corpus luteum cyst

INTRODUCTION

Ectopic pregnancy is an important health problem and accounts for 10% of all maternal mortality.¹ Primary ovarian pregnancy is even rarer accounting for 0.15-3% of all ectopic gestations.² The diagnosis of which continues to challenge the practicing clinicians. Since the first case reported by St. Maurice in 1689, many cases have been reported in the literature. Heartig estimated that ovarian pregnancy occurs in one in 25,000 - 40,000 pregnancies.³ Its frequency is 0.3 - 3.0 of all ectopic gestation.⁴ In contrast to tubal pregnancy, ovarian pregnancy occurs as a single event in an otherwise healthy woman. There is no specific clinical, laboratory test or ultrasonography signs for differentiating ovarian from tubal pregnancy. At laparoscopy, it frequently suggests hemorrhage from the corpus luteum or a rupture of ovarian cyst. Histology is the only means of establishing the diagnosis. Pelvic pain, amenorrhea and vaginal bleeding are the foremost classical symptoms found in these cases. Abdominal pain is the most common presenting complaint, but the severity and nature of the pain varies widely. Ovarian pregnancies could be misdiagnosed because they are mostly and easily confused with a ruptured corpus luteum cyst.

Here we report an interesting case of primary ruptured ovarian pregnancy, a 23 years old married lady who presented to the emergency ward with only pain abdomen and with no preceding amenorrhoea and bleeding, diagnosed as primary ovarian pregnancy after laprotomy is being reported.

CASE REPORT

A 23 years old female married for 4 years G2P1L1A0 unbooked patient came to our emergency ward, referred from department of surgery with complaints of pain abdomen mainly on left side and vomiting for 1 day with no preceding amenorrhoea and bleeding. She had normal menstruation earlier; her LMP was 28 days back. There was history of fainting attack 1 day back. There was no history of any trauma, bladder or bowel complaints. She was a regular user of combined oral contraceptive since 2 years. No risk factor for extra uterine pregnancy was illustrated in her gynaecological history. Her previous pregnancy was uneventful 3 years back. No significant past medical/surgical history was there. On her usg there was no sac seen in uterus and uterus size was normal. There was a left adnexal bulky mass suggestive of gestational sac like structure. On examination, her vitals

were stable with mild tachycardia having pulse rate of 104/min, blood pressure 100/60 mm Hg with moderate pallor was there. On per abdomen examination there was marked tenderness present on left iliac fossa. On per vaginum examination uterus was anteverted, normal size, left adnexal tenderness and boggy was present. There was fullness in right adnexa also cervical motion tenderness was also present. Urine pregnancy test was positive. In view of above clinical findings a disturbed ectopic pregnancy was suspected.

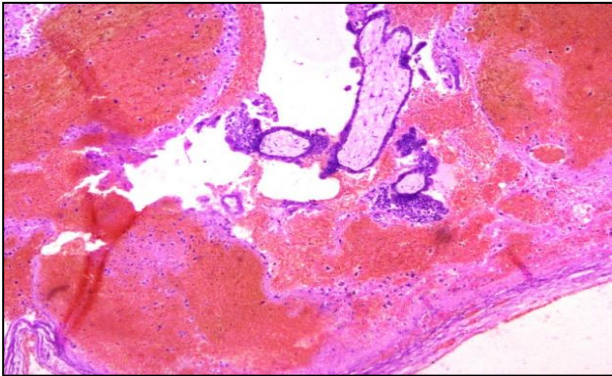


Figure 1: Microphotograph low power (4x); view, products of conception in ovarian tissue.

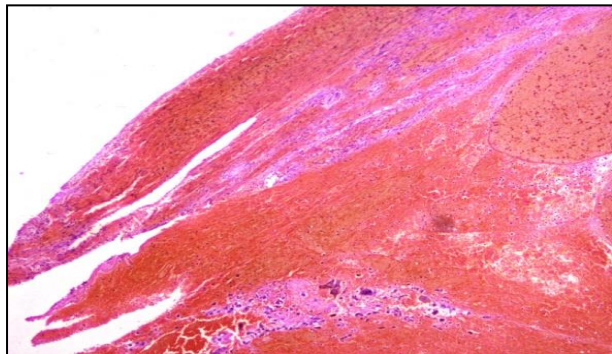


Figure 2: Microphotograph low power (4x); view showing ovarian stroma and trophoblastic tissue below.

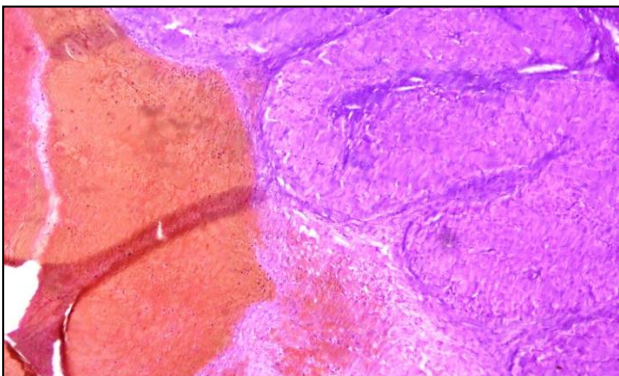


Figure 3: Low power (4x) view; showing corpus luteum on the right side of the image.

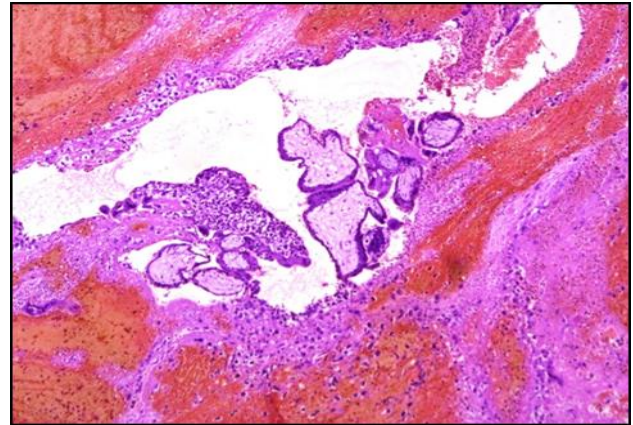


Figure 4: Low power (4x); showing chorionic villi embedded in the ovarian stroma which confirms ectopic pregnancy.

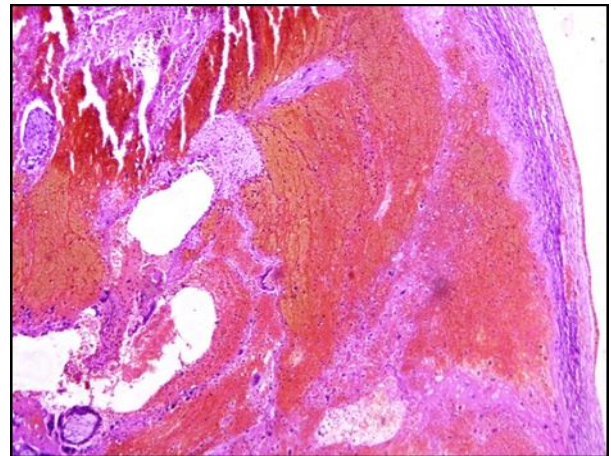


Figure 5: Low power (4x) view showing chorionic villi small part seen towards left lower side and membrane (part of the ovary) seen towards right.

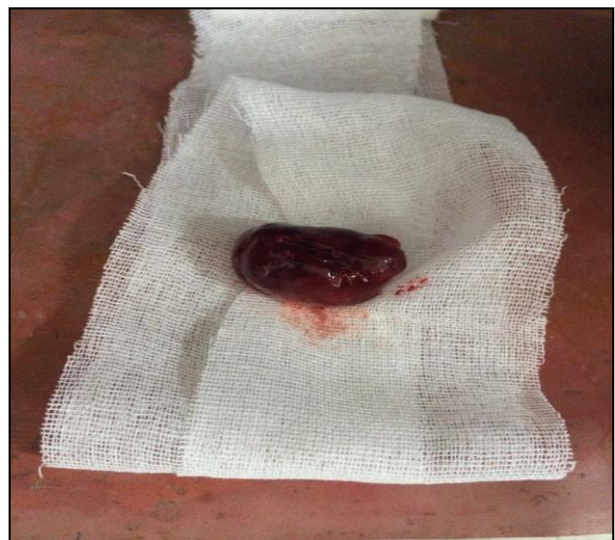

Figure 6: Specimen of partial ovariectomy showing rent in its upper surface where organised blood clot is present.

Consequently, an emergency exploratory laprotomy was done in view of rupture ectopic pregnancy after arranging adequate blood. On laprotomy there was approximately 1000 ml of hemoperitoneum was present, uterus was normal in size, both tubes were normal and intact. Left ovary was enlarged with a bluish red mass of around 3x4 cm with a rent on its surface. There was organised blood present around the mass and slight oozing present through the rent. There was a cyst of around 3x 3 cm in left side suggestive of corpus leuteum cyst. Her left sided partial ovariectomy with removal of cyst was done and tissue was sent for histopathological examination. Her postoperative period was uneventful. Histopathological report was consistent with ruptured ectopic ovarian pregnancy.

DISCUSSION

Ovarian pregnancy is an uncommon presentation of ectopic gestation being 0.5-1.0% of all ectopic pregnancies.⁵ In 1950s the incidence of primary ovarian pregnancy was one in 40,000 pregnancies and increased further with an incidence of one in 7,000 pregnancies for the year 1983.⁶ Ovarian pregnancy usually ends in rupture during the first trimester in 91% cases, 5.3% in the second trimester and 3.7% in the third trimester. It is important to distinguish primary ovarian pregnancy from tubal pregnancy and hemorrhagic ovarian cyst, because they have same symptoms. It has been reported that ovarian pregnancy is diagnosed as a hemorrhagic corpus luteum in two-thirds of cases.^{7,8} Ovarian pregnancies can be diagnosed by the following criteria of Spiegelberg.⁹

- The fallopian tube on the affected side must be intact
- The fetal sac must occupy the position of ovary
- The ovary must be connected to the uterus by the ovarian ligament
- Ovarian tissue must be located in the sac wall.

Primary ovarian pregnancy may occur without any classical antecedent risk factors. Some of the cases are associated with predisposing factors such as the use of intrauterine contraceptive device assisted reproductive technology, endometriosis and pelvic inflammatory disease.^{10,11} Our patient did not have any of these risk factors, and the present pregnancy had occurred in a spontaneous cycle.

Several theories have been suggested to explain ovarian implantation such as reflux of the conceptus following a normal fertilization from the fallopian tube along with blood from the uterus or fertilization occurs within the follicle following defective ovum release at ovulation.^{12,13} The entity, empty follicle syndrome, where no oocytes are retrieved from the mature ovarian follicles with apparently normal follicular development and estradiol levels, after controlled ovarian hyper stimulation for an assisted reproductive technology cycle, despite repeated aspiration and flushing, can also be a cause for primary ovarian pregnancy.¹⁴ The signs and symptoms of

ovarian pregnancy are similar to disturbed tubal pregnancy, conditions most commonly confused with ruptured hemorrhagic corpus luteum and chocolate cyst or tubal ectopic pregnancy. Rupture in the first trimester is the usual rule in an ovarian ectopic, but the pregnancy may advance to full term.¹⁵

Ultrasonography can be a useful adjunct to clinical presentation and physical examination in allowing the preoperative diagnosis of ovarian gestation.¹⁶ In the present case, the urine pregnancy test was positive, and the USG also suggested an ectopic pregnancy although not exactly as of ovarian origin. Intraoperatively, a presumptive diagnosis of ruptured ovarian pregnancy was made in our case but only on histopathology was it confirmed. With a few exceptions, the initial diagnosis is made on the operating table and the final diagnosis only on histopathology on the basis of the four Spiegelberg criteria.¹⁶

Bouyer et al reported that unlike tubal gestation, ovarian pregnancy is neither associated with pelvic inflammatory disease nor infertility.¹⁷ The only risk factor associated with the development of ovarian pregnancy is the current use of intrauterine device. Intrauterine device is effective in preventing intrauterine and tubal pregnancies in 99.5% and 95% respectively. However it has little effect on the prevention of an ovarian pregnancy. The rate of intrauterine device use in reported ovarian pregnancies is 17 to 25%. Grimes and Matseoane noted prior history of pelvic inflammatory disease in 42% and 46% of ectopic pregnancies, respectively.¹⁸ The classic management of ruptured ovarian pregnancy is surgical, like any other ruptured ectopic pregnancy. The extent of surgery varies according to the amount of tissue destruction that has occurred. Patients with an ovarian pregnancy have a good prognosis. Fertility after ovarian pregnancy remained unmodified.

CONCLUSION

Primary ovarian ectopic pregnancy is still a diagnostic challenge for clinician may occur without the presence of any of the classical risk factors or symptoms/signs, and should be entertained as one of the important differential diagnoses in a female of reproductive age group with or without a history of amenorrhea or bleeding. In conclusion, ovarian ectopic pregnancy is rare and expected to rise as more patients opt for fertility therapy. Despite modern diagnostic modalities, these patients continue to present in circulatory collapse. The necessity to maintain a high index of suspicion is required to ensure an efficient mode of treatment, appropriate prognosis, and patient counselling.

Funding: No funding sources

Conflict of interest: None declared

Ethical approval: Not required

REFERENCES

1. Das S, Kalyani R, Lakshmi M. Ovarian Pregnancy. *Indian J Path Microbiol.* 2008;51(1):37-8.
2. Nwanodi O, Khulpateea N. Primary Ovarian Pregnancy. *Journal Of The National Medical Association.* 2006;98(5):797.
3. Hertig AT. Discussion of Gerin-Lojoie L. Ovarian pregnancy. *Am J Obstet and Gynecol.* 1951;62:920.
4. Salas Valien JS, Reyero Alvarez MP, Gonzalez Moran MA, Garcia Merayo M, Nieves Diez C. Ectopic ovarian pregnancy. *An Med Intern.* 1995;12:192-4.
5. Sharma B, Preston J, Olibo N. Ovarian pregnancy: An unusual presentation of an uncommon condition. *J Obset Gynecol.* 2002;5:565-6.
6. Gaudoin MR, Coulter KL, Robins AM, Verghese A, Harretty KP. Is the incidence of ovarian ectopic pregnancy increasing? *Eur J Obstet Gynecol Reprod Biol.* 1996;70:141.
7. Hallat JG. Primary ovarian pregnancy: a report of twenty -five cases. *Am J Obstet Gynecol.* 1982;143:55-60.
8. Varras M, Polizos D, Kalamara Ch, Antypa E, Tsikini A, Tsouroulas M, Antoniou S, Paissios P. Primary ruptured ovarian pregnancy in a spontaneous conception cycle: a case report and review of the literature. *Clin Exp Obstet Gynecol.* 2002;29:143-7.
9. Lehfeldt H, Tietle C, Gorstein F. Ovarian pregnancy and the intrauterine device. *Am J Obstet Gynecol.* 1970;108:1005-8.
10. Mehmood SA, Thomas JA. Primary ectopic ovarian pregnancy(report of three cases). *J Postgrad Med.* 1985;31:219-22.
11. DeSeta F, Baraggino E, Strazzanti C, DeSanto D, Tracanzan G, Gunschino S. Ovarian pregnancy: a case report. *Acta Obstet Gynecol Scand.* 2001;80:661-5.
12. Grimes HG, Nosal RA, Gallagher JC. Ovarian pregnancy: a series of 24 cases. *Obstet Gynecol* 1983;61:174-6.
13. Raziell A, Golan A, Pansky M, Ronel R, Bukovsky J, Caspi E. Ovarian pregnancy : a report of twenty cases in one institution. *Am J Obstet Gynecol:* 1990;163:1182-5.
14. Mehmood SA, Thomas JA. Primary ectopic ovarian pregnancy, report of three cases. *J Postgrad Med.* 1985;31:219.
15. Darbar RD, Reddy CC, Despande NR, Nagalotimath SJ. Primary Ovarian Pregnancy (a case report). *J Obstet Gynecol India.*1976;28:310.
16. Spiegelberg O. Zur casuistik der ovarialschwangerschaft. *Arch Gynaekol.* 1878;13:73-5.
17. Bouyer J, Coste J, Fernandez H, Pouly JL, Job-Spira N. Sites of ectopic pregnancy: a 10 year population-based study of 1800 cases. *Hum Reprod.* 2002;12:3224-6.
18. Matseoane SL. Ectopic pregnancy: an 11 year old study. *Am J Diag Gynecol Obstet.* 1979;1:331-4.

Cite this article as: Mendiratta SL, Anand S, Mittal R, Khan F, Nargotra N. Primary ovarian pregnancy: early diagnosis still a myth. *Int J Reprod Contracept Obstet Gynecol* 2016;5:3238-41.