

DOI: <http://dx.doi.org/10.18203/2320-1770.ijrcog20201266>

Case Report

## Surgical management of caesarean scar pregnancy: a case report

Savita Singh Gautam<sup>1\*</sup>, Manmeet Kaur<sup>2</sup>

<sup>1</sup>Department of Obstetrics and Gynecology, Sunshine Hospital Bilaspur, Chhattisgarh, India

<sup>2</sup>Department of Obstetrics and Gynecology, Lady Hardinge, Delhi, India

**Received:** 06 February 2020

**Accepted:** 02 March 2020

**\*Correspondence:**

Dr. Savita Singh Gautam,

E-mail: [drsavita\\_gwl@yahoo.co.in](mailto:drsavita_gwl@yahoo.co.in)

**Copyright:** © the author(s), publisher and licensee Medip Academy. This is an open-access article distributed under the terms of the Creative Commons Attribution Non-Commercial License, which permits unrestricted non-commercial use, distribution, and reproduction in any medium, provided the original work is properly cited.

### ABSTRACT

Caesarean scar ectopic is one of the rarest of all ectopic pregnancies. The incidence of caesarean scar pregnancy (CSP), which was extremely rare till recent times, has been rising steadily. Case have more of such cases being published in medical literature now. It is defined as when a blastocyst implants on a previous caesarean scar. The incidence of caesarean scar ectopic has increased due to increase in number of caesarean deliveries. Early diagnosis of this can be done by using ultrasound. It is very important because a delay can lead to increased maternal morbidity and mortality. Early diagnosis leads to prompt management and improves the outcome by allowing preservation of future fertility. Magnetic resonance imaging (MRI) has important role when sonography is equivocal or inconclusive before therapy or intervention. Case are reporting a rare case of G2P111 with previous one caesarean delivery, diagnosed as caesarean scar ectopic pregnancy with the help of sonography. Patient underwent laparotomy and on histopathological examination caesarean scar pregnancy was confirmed. Due to the rarity of this condition, there are no specific guidelines available for its management.

**Keywords:** Caesarean scar pregnancy, Ectopic pregnancy, Laparotomy

### INTRODUCTION

Caesarean scar pregnancy (CSP) is a rare entity and can cause serious complications.<sup>1</sup> There is a rising trend in the number of cases being reported possibly due to the increasing prevalence of caesarean sections. Increasing the use of imaging studies such as ultrasonography and magnetic resonance imaging (MRI) helps in detecting these cases. Early diagnosis would help avoid complications such as scar rupture and excessive hemorrhage, which may require a hysterectomy. This can endanger the woman's life and also affect future fertility.<sup>2</sup>

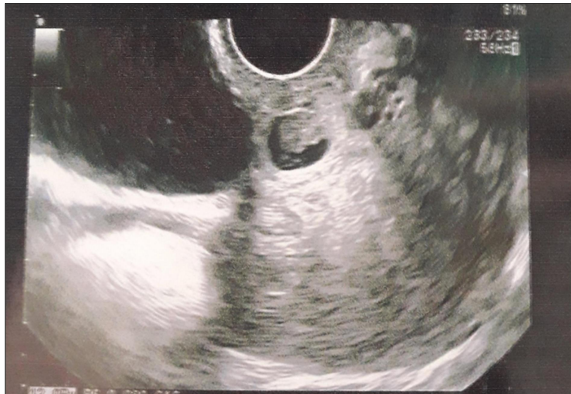Patients who are vitally stable have more treatment options including conservative management. Hence, obstetricians/gynaecologists and radiologists must be highly vigilant of this potentially fatal complication.<sup>3</sup>

### CASE REPORT

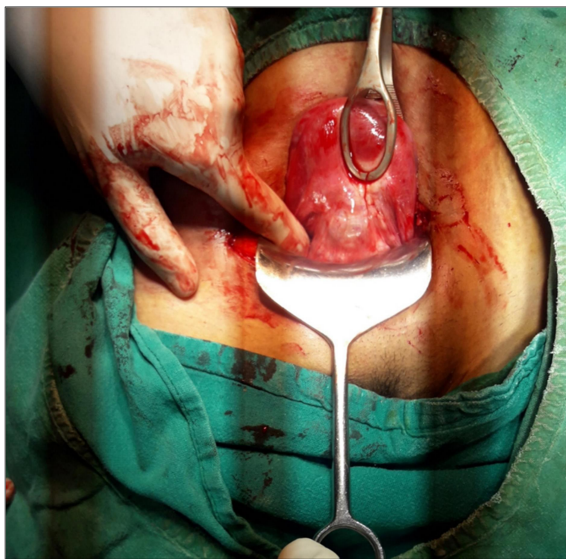
A 25-year-old female presented to outpatient department of gynecology with chief complaint of two-month amenorrhea with bleeding per vaginum on and off since 10-12 days with severe pain in lower abdomen since 2 days. She had history of dilation and curettage in present pregnancy in view of incomplete abortion.

In obstetric history, she was G2P111 with previous one caesarean delivery. Her first Caesarean section was due to fetal distress and was done 13 months ago. General physical examination was normal. On per speculum, cervix was normal, no discharge or bleeding per vaginum was seen. On bimanual examination, cervix was tightly closed, uterus was bulky, anteverted, tender and bilateral fornices were free with no tenderness.

On investigation, routine blood and urine investigations were normal. Her urine pregnancy test was positive. Trans vaginal ultrasound revealed single well-defined gestational sac in uterus at the site of caesarean scar with poor choriodecidual reaction. Myometrial thickness between the sac and urinary bladder is 1.6 mm with possible adhesion between uterus and urinary bladder. Mild vascularity seen around gestational sac. Single embryo of 6 weeks 5 days seen, cardiac activity was not seen, adenexa normal Figure 1. A diagnosis of caesarean scar pregnancy was considered. Patient was given option for medical management with methotrexate or surgical management with laparotomy, she has undergone for laparotomy. Intraoperative findings were soft and vascular mass seen at the site of previous scar Figure 2. Incision was given over bulge and products of conception were gently removed. It was communicating with uterine cavity, edges of scar tissue were excised and freshened, gentle uterine curettage was done. Tissue was sent for histopathological examination and diagnosis of caesarean scar ectopic pregnancy was confirmed.



**Figure 1: Ultrasound of caesarean scar pregnancy.**



**Figure 2: Intra-op of caesarean scar pregnancy.**

## DISCUSSION

The exact cause of CSP is still not clear. There is an early invasion of the myometrium and it is presumed that this occurs through a microscopic tract in the cesarean section scar tissue.<sup>4</sup> The incidence has been reported to be 1:1 800 to 1:2 200 pregnancies.<sup>4</sup> In CSP, the gestational sac gets embedded within the fibrous tissue of the previous cesarean section scar. The gestational age at diagnosis ranged from five to 12.4 weeks (mean 7.5±2.5 weeks) and the time interval between the last cesarean and the CSP was six months to 12 years.<sup>5</sup> There are many risk factors implicated in the development of CSP. These include the number of cesarean sections, the time interval between the previous cesarean section and the subsequent pregnancy, and the indications for the previous cesarean section, but it is not clear whether these factors are directly related to CSP.<sup>5</sup> On review of the various case reports, it was noted that CSP were incidental ultrasonography finding in an asymptomatic woman while some present with mild painless vaginal bleeding. In a lesser percentage of patients, it was accompanied with mild to moderate abdominal pain. The uterus may be tender during examination if the CSP is in the process of rupture. A patient with a ruptured CSP may present in a state of collapse or hemodynamically unstable.<sup>5</sup> To reduce morbidity and fatal complications, it is important to diagnose a scar pregnancy as early and as accurately as possible. The diagnosis may be late till uterine rupture occurs or the woman goes into hypovolemic shock, and it may be difficult to differentiate between a miscarriage and a scar pregnancy due to similarities in presentation and examination findings. Transvaginal sonography remains to be an important tool in diagnosing CSP and could soon be the gold standard for the diagnosis of scar implantation.<sup>4</sup>

### *Diagnostic criteria are as follows*

- An empty uterine cavity and an empty cervical canal
- A gestational sac in the anterior part of the uterine isthmus
- An absence of healthy myometrium between the bladder and gestational sac.<sup>4</sup>

As it is a rare condition, there are no specific guidelines available for the management of CSP. The main aim of treatment of CSP is to prevent massive blood loss and conserve the uterus to maintain future fertility, women's health, and quality of life.<sup>6</sup> Management may be either medical or surgical. Various treatment options include dilatation and curettage and excision of trophoblastic tissues using laparotomy or laparoscopy, local and/or systemic MTX administration, bilateral hypogastric artery ligation, associated with dilatation and evacuation under laparoscopic guidance, and selective uterine artery embolization (UAE) in combination with curettage and/or MTX injections.<sup>1</sup>

In a case of CSP, management was done by injecting potassium chloride into the gestational sac and a combination of local and systemic methotrexate administration. The patient was followed-up by monitoring the beta human chorionic gonadotropin level until it reached non pregnant level and followed-up with scan and MRI until complete resolution of the pregnancy sac.<sup>7</sup> In cases with a viable fetus, local injection of potassium chloride and hyperosmolar glucose or crystalline trichosanthin will act as an embryocide.<sup>3</sup>

Jurkovic et al, recommended surgical repair of the scar either as a primary treatment or as a secondary operation after the initial treatment in women who desire further pregnancies.<sup>3</sup> This could decrease the risk of recurrence of CSP. Once the gestational mass is surgically excised, it has been noted that hCG returns to normal much more quickly within one to two weeks. Various case reports of patients with caesarean scar ectopic pregnancy even in the absence of bleeding, supports of management as the surgical option.<sup>8</sup> This includes elective laparotomy and excision of the gestational mass. The benefit of surgery is less recurrence because of the resection of the old scar, with a new uterine closure. Other is a shorter follow-up period.<sup>4</sup> In another study with Caesarean scar pregnancy cases, surgical excision of scar is considered as a key management and helpful to prevent recurrence.<sup>9</sup> Uterine artery embolization (UAE) followed by dilatation and curettage to reduce bleeding is used in some cases. UAE requires less follow up as compare to methotrexate.<sup>10</sup> High intensity focused ultrasound combined with suction curettage under hysteroscopic guidance was recently reported to be a safe and effective modality of treatment when the gestational period is more than eight weeks.<sup>11</sup>

## CONCLUSION

Caesarean scar ectopic pregnancies can have very fatal and poor outcomes, including uterine rupture, massive haemorrhage and maternal death. Thus, it is important that early and accurate diagnosis of caesarean scar pregnancy is obtained in order to avoid complications and preserve fertility. Its incidence is rising due to the increasing incidence of caesarean sections. The liberal use of transvaginal ultrasound to assess early pregnancies helps early diagnosis and planning of the management. If the condition is not diagnosed, a simple gynaecological procedure such as a dilatation and curettage may end up with massive hemorrhage and unexpected complications. Every pregnant woman with a past history of a caesarean section should have a careful ultrasonographic assessment of the previous scar. As there are no evidence-based recommendations available, clinicians will have to depend on the available case reports and counsel the women accordingly on the various treatment

options available to make an informed choice. Consultants should be involved in patient counselling and planning the further management of such cases.

*Funding: No funding sources*

*Conflict of interest: None declared*

*Ethical approval: Not required*

## REFERENCES

1. Tulpin L, Morel O, Malartic C, Barranger E. Conservative management of a caesarean scar ectopic pregnancy: a case report. *Cases J.* 2009;2(8):7794.
2. Al-Nazer A, Omar L, Wahba M, Abbas T, Abdulkarim M. Ectopic intramural pregnancy developing at the site of a cesarean section scar: a case report. *Cases J.* 2009;2(11):9404.
3. Muraji M, Mabuchi S, Hisamoto K, Muranishi M, Kanagawa T, Nishio Y, et al. Caesarean scar pregnancies successfully treated with methotrexate. *Acta Obstet Gynecol Scand.* 2009;88(6):720-3.
4. Jurkovic D, Hillaby K, Woelfer B, Lawrence A, Salim R, Elson CJ. First-trimester diagnosis and management of pregnancies implanted into the lower uterine segment caesarean section scar. *Ultrasound Obstet Gynecol.* 2003;21(3):220-7.
5. Ash A, Smith A, Maxwell D. Caesarean scar pregnancy. *BJOG.* 2007;114(3):253-63.
6. Litwicka K, Greco E. Caesarean scar pregnancy: a review of management options. *Current Opin Obstet Gynecol.* 2011;23(6):415-21.
7. Roy MM, Radfar F. Management of viable caesarean scar pregnancy a case report. *Oman Med J.* 2017;32(2):161-6.
8. Aich R, Solanki N, Kakadiya K, Bansal A, Joshi M, Nawale A. Ectopic pregnancy in caesarean section scar: a case report. *Radiol Case Reports.* 2015;10(4):68-71.
9. Fylstra DL. Ectopic pregnancy not within the (distal) fallopian tube: aetiology, diagnosis, and treatment. *Am J Obstet Gynaecol.* 2012;206(4):289-99.
10. Zhuang Y, Huang L. Uterine artery embolization compared with methotrexate for the management of pregnancy implanted within a cesarean scar. *Am J Obstet Gynecol.* 2009;201(2):152.e1-152.e3.
11. Zhu X, Deng X, Wan Y, Xiao S, Huang J, Zhang L, et al. High intensity focused ultrasound combined with suction curettage for the treatment of caesarean scar pregnancy. *Med. (Baltimore).* 2015;94(18):e854.

**Cite this article as:** Gautam SS, Kaur M. Surgical management of caesarean scar pregnancy: a case report. *Int J Reprod Contracept Obstet Gynecol* 2020;9:1769-71.