

DOI: <https://dx.doi.org/10.18203/2320-1770.ijrcog20213496>

Case Report

Case report of spontaneous bilateral ovarian pregnancy in a multiparous female

Priya Gupta^{1*}, Sandip Maheshwari²

¹Department of Obstetrics and Gynaecology, Baptist Christian Hospital, Tezpur, Assam, India

²Department of Radiodiagnosis, Base Hospital, Tezpur, Assam, India

Received: 25 July 2021

Accepted: 17 August 2021

***Correspondence:**

Dr. Priya Gupta,

E-mail: Sandip_7001@yahoo.co.in

Copyright: © the author(s), publisher and licensee Medip Academy. This is an open-access article distributed under the terms of the Creative Commons Attribution Non-Commercial License, which permits unrestricted non-commercial

ABSTRACT

Non-tubal ectopic pregnancies, especially bilateral ovarian ones, are very rare. In this case report, we present a case of spontaneous bilateral ovarian pregnancy in a 30-year-old multiparous lady who presented with a seven-day history of lower abdominal pain associated with fever. The urine pregnancy test was positive. The transvaginal ultrasound findings along with the β -chorionic gonadotropin level were indicative of a bilateral ovarian ectopic pregnancy, and the surgical treatment of the patient was decided. Following the patient's consent, intraoperatively the presence of an ovarian ectopic pregnancy was detected by the gynecologist and bilateral salpingo-oophorectomy was done. On histopathology, the findings revealed trophoblastic tissue and chorionic villi along with products of conception in both ovaries, confirming the diagnosis of bilateral spontaneous ectopic pregnancy. The patient was discharged from our clinic on the fifth post-operative day, with instructions for regular follow-up of the β -chorionic gonadotropin level until it returns to normal values. An early diagnosis leads to a significant reduction in morbidity and mortality with such cases and helps to improve their overall prognosis.

Keywords: Multiparous, β -chorionic gonadotropin, Salpingo-oophorectomy

INTRODUCTION

Ectopic pregnancy is defined as implantation of the trophoblastic tissue outside the endometrium of the uterus.¹ It has an estimated incidence of 1.5% to 2.5% in all pregnancies.² The vast majority of these ectopic pregnancies occur in the fallopian tubes, especially in the ampulla part of the fallopian tube, with the remaining one being non-tubal in origin. An ovarian pregnancy is one of the common type of non-tubal ectopic pregnancy with an approximate incidence of only 1/7000-1/30,000 live births and 0.5-2.5% of all ectopic gestations.^{3,4} Primary bilateral ovarian ectopic pregnancy is a condition in which there are at least two simultaneously spontaneous pregnancies occur in the same patient, located in each of these ovaries.² Bledsoe in 1918 published the first case of ovarian ectopic pregnancy. The incidence of ovarian ectopic pregnancies is high in the case of assisted reproductive techniques

(ART), which includes ovulation induction, intrauterine insemination, in vitro fertilization, embryo transfer (IVF-ET), and intracytoplasmic sperm injections (ICSI).² No case reports exist for the recurrence of an ovarian pregnancy in a lady so far, which indicates that a previous ovarian pregnancy is unlikely to be a risk factor for its recurrence.⁶ The most common symptom of ovarian pregnancy is pain in the lower abdomen. Other differentials include a ruptured corpus luteal cyst, seen in 75% of such cases. On per vaginal examination, an adnexal mass is sometimes palpable.³ Some pre-operative criteria include combining biochemical and ultrasonography findings, which includes the following: a serum β hCG level ≥ 1000 IU/L, absence of a uterine gestational sac on transvaginal ultrasound, surgical confirmation of the involvement of ovaries, association with bleeding, visualization of chorionic villi, presence of an atypical cyst on the ovary, intact tubes.^{5,6} The diagnosis of

ovarian pregnancy is confirmed only after histological confirmation post-operatively. Despite this, a correct diagnosis during surgery is only possible in 28% of cases due to difficulty in differentiating an ovarian pregnancy from hemorrhagic corpus luteum. Spielberg criteria are used for the diagnosis of ovarian ectopic pregnancy, which depends on the following histopathological findings: the gestational sac is located in the region of the ovary, the ectopic pregnancy is attached by the ovarian ligament to the uterus, presence of ovarian tissue in the wall of the gestational sac is proven on histological examination, and the tube on the involved side is intact. This case report enlightens the importance of having a bilateral ovarian pregnancy as a differential diagnosis in a multiparous lady because of its clinical urgency and its association with high maternal mortality.

CASE REPORT

A 30-year-old multiparous G4P2L2A1 Indian female presented to the emergency department with a seven-day history of lower abdominal pain. The pain was acute in onset and gradually progressive in severity. It was non-radiating and dull aching. These symptoms were associated with nausea, high-grade fever, and five episodes of vomiting in one day. All deliveries were full-term normal vaginal delivery, with the last delivery 3 years back with no post vaginal complications. The patient had no previous past comorbidities. Her last menstrual period was on 24/05/2021, a urine pregnancy test was done on 30/06/2021, which was positive for pregnancy. She has taken abortive pills on 02/07/2021, for which she got vaginal bleeding for three days with blood clots in her pads similar to her regular menstrual period. Her expected date of delivery was documented as 03/03/2022; therefore, on presentation, she was estimated to be at 9 weeks of gestation age. Upon examination: (i) General look: the patient was conscious; alert; oriented to time, place, and person; febrile, tachycardia with 120 beats per minute, (ii) Abdominal examination: Mild tenderness over the suprapubic region with a pain score graded as seven out of ten on the pain scale, (iii) Reflexes: Rigidity of the abdomen was present with positive rebound tenderness and (iv) Vaginal examination was done which revealed mild bleeding and cervical tenderness.

Laboratory investigations revealed a β hCG level of 10500 mIU/mL and a positive urine pregnancy test. The radiologist performed an ultrasound of the pelvis in the emergency room, which revealed that the uterus was normal in size with no intrauterine gestation sac seen (Figure 1, arrow marked by A). Both ovaries are enlarged, the right ovary measuring 51x30 mm and the left ovary measuring 50x47 mm. A cystic lesion with internal soft tissue components and showing internal vascularity is seen in the right ovary measuring 29x17 mm. A similar morphology lesion measuring 32x18 mm is seen in the left ovary with internal vascularity (Figure 1, arrow marked by B and Figures 2, 3). Mild free fluid was present in the pelvis.

After counseling the patient regarding her condition and an urgent need for surgical intervention, the couple agreed for an exploratory laparotomy under general anesthesia with the potential to convert to salpingectomy or oophorectomy if indicated. In operating theatre, the laparotomy findings confirmed distention of both ovaries with an ectopic pregnancy seen in each of them (Figure 4) and hemoperitoneum of approx. 300 ml. Bilateral salpingo-oophorectomy was done. The tissue samples were then sent for analysis by histopathological analysis (Figure 5). An approximately blood loss of 800 mL had taken during surgery. Histopathological analysis revealed the presence of ovarian tissues with fragments of cysts lined by luteinized cells along with a focal area showing trophoblastic tissue and chorionic villi, thus making the diagnosis consistent with a bilateral ovarian ectopic pregnancy (Figures 6). The post-operative period was uneventful and the patient was discharged in stable condition with follow up on regular basis.

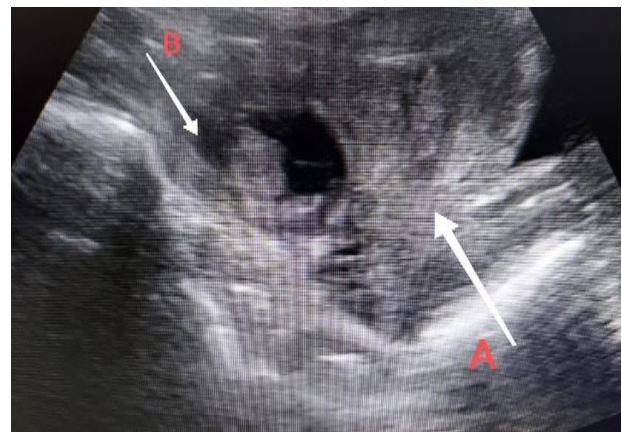


Figure 1: Arrow marked by A-The uterus was normal in size with no intrauterine gestation sac seen. Arrow marked by B.

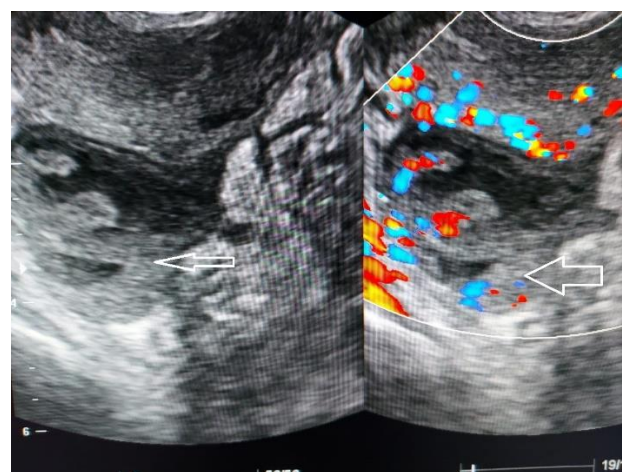


Figure 2: The right ovary measured 51x30 mm. A cystic lesion with internal soft tissue components and showing internal vascularity is seen in the right ovary measuring 29x17 mm.

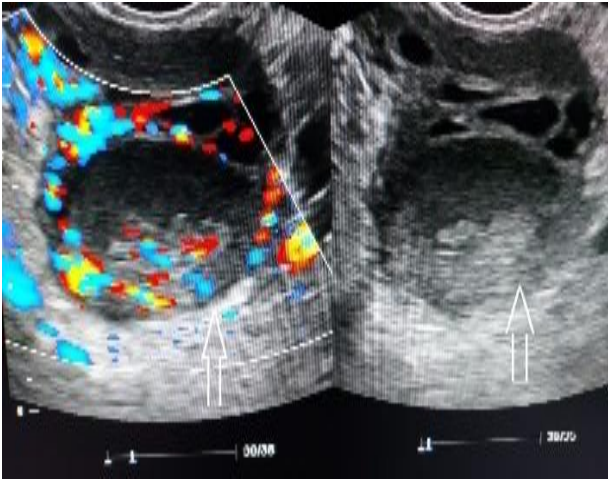


Figure 3: The left ovary measured 50x47 mm. A cystic lesion with internal soft tissue components and showing internal vascularity is seen in the left ovary measuring 32x18 mm.

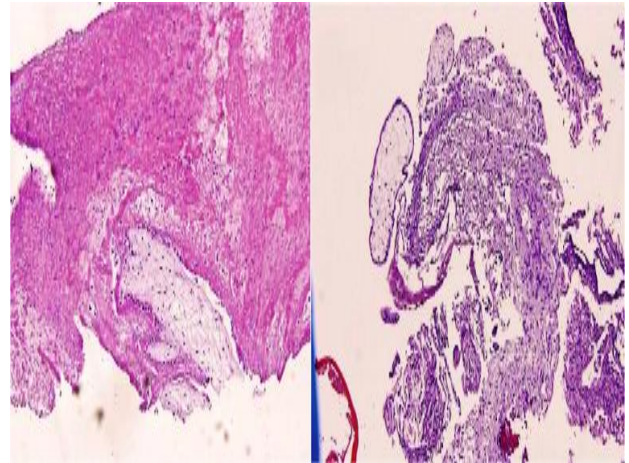


Figure 6: Histopathological analysis revealed the presence of ovarian tissues with fragments of cysts lined by luteinized cells along with a focal area showing trophoblastic tissue and chorionic villi.

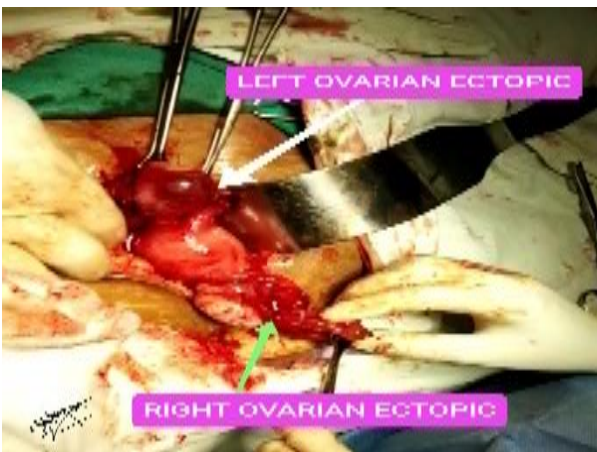


Figure 4: The laparotomy findings confirmed distention of both ovaries with an ectopic pregnancy seen in each of them.

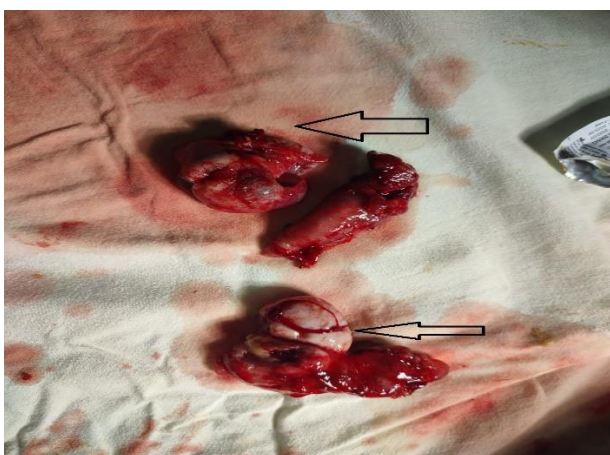


Figure 5: Bilateral salpingo-oophorectomy was done. The tissue samples were then sent for analysis by histopathological analysis.

DISCUSSION

An early diagnosis and immediate intervention are required for the prognosis of primary ovarian ectopic pregnancy, which guides in reducing the incidence of maternal mortality and morbidity. Its early diagnosis is challenging among other types of non-tubal pregnancies and crucial for the management of the individuals.⁸ Misinterpretation of ultrasonography findings remains the primary cause of missed early diagnosis.^{6,7} However, with an improvement of ultrasonogram sensitivity, earlier identification of the ovarian ectopic pregnancy has become possible, which helps the gynecologist for early management for such individuals.⁹ In the present case scenario, we suspected a bilateral ovarian ectopic pregnancy preoperatively based on the patient's positive urine pregnancy test, high β hCG level, and correlated with the ultrasonography findings. Intra-operatively, we found that ectopic pregnancy seen in both the ovaries with fallopian tubes normal. Both the ovaries and fallopian tubes were excised, and tissue samples were sent to the histopathology department for further analysis. Along with the products of conception, trophoblastic tissue and chorionic villi were present in both ovarian tissues; hence, confirming the diagnosis of bilateral ovarian ectopic pregnancy. The previous case reports have agreed that the primary ovarian ectopic pregnancy is rare and there is great difficulty in diagnosis pre-operatively.^{1,5,6,8} Management of primary ovarian ectopic pregnancies vary among cases. Management options include being managed by exploratory laparotomy, medical treatment, or laparoscopy.^{8,10}

CONCLUSION

The present case report is an example of bilateral ovarian ectopic pregnancy in a multiparous female, whose diagnosis was confirmed after the histopathological report.

Bilateral ovarian ectopic pregnancy is quite rare. It may present without the classical symptoms of ectopic pregnancy and hemorrhage. This is a life-threatening emergency and if missed, this is considered to be a leading cause of maternal mortality especially in the first trimester accounting from 4% to 9% of all pregnancy-related deaths. When there is suspicion of an ectopic pregnancy, ovarian locations should also be taken into account as early detection helps for timely management in such patients, which in turn reduced mortality and morbidity. Hence, the clinical perception of gynecologists and radiologists is important for an early detection and management. No data exists so far between a history of infertility or recurrent extra-uterine pregnancy with ovarian pregnancy.

Funding: No funding sources

Conflict of interest: None declared

Ethical approval: Not required

REFERENCES

1. Kadau JVVV. Sonographic detection of ovarian ectopic pregnancy. J Diagnostic Med Sonography. 2016;32(5):299-303.
2. José F, Castañeda JD. Bilateral ectopic pregnancy. J Minimally Invasive Gynaecol. 2007;14(4):419-27.
3. Samiee-Rad F, Ziaee-Ardestani M. Primary ovarian ectopic pregnancy: a case report. Biotechnol Health Sci. 2017;4(1):45-8.
4. Goyal LD, Tondon R, Goel P. Ovarian ectopic pregnancy: a 10-year experience and review of literature. Iranian J Reproductive Med. 2014;12(12):825-30.
5. Lothian N, Talaei BA, Rahmani BM, Daiemi M, Rahmani BR. An ovarian ectopic pregnancy: a rare case report. Sci Database. 2017;21(11):1142-8.
6. Sergent F, Mauger-Tinlot F, Gravier A, Verspyck E. Ovarian pregnancies: reevaluation of diagnostic criteria. J gynecol obstetr biol la reproduct. 2002;31(8):741-6.
7. Manjula NV, Sundar G, Shetty S, Sujani BK. A case of a ruptured ovarian pregnancy. Proceedings in Obstet Gynaecol. 2010;1(2):1-5.
8. Raine-Fenning N, Sur S, Horne AW, Wilkinson H. Pregnancy of unknown viability. J Family Planning Reproduct Health Care. 2012;38(1):7-10.
9. Alleyassin A, Khademi A, Aghahosseini M, Safdarian L. Comparison of success rates in the medical management of ectopic pregnancy with single-dose and multiple-dose administration of methotrexate: a prospective, randomized clinical trial. Fertility sterility. 2006;85(6):1661-6.
10. Tulandi T. Ectopic pregnancy: epidemiology, risk factors, and anatomical sites. 2020.
11. Alalade AO, Smith FJ, Kendall CE, Odejinmi F. Management of non-tubal ectopic pregnancies. J Obstetr Gynaecol. 2017;37(8):982-91.

Cite this article as: Gupta P, Maheshwari S. Case report of spontaneous bilateral ovarian pregnancy in a multiparous female. Int J Reprod Contracept Obstet Gynecol 2021;10:3610-3.