

## Original Research Article

# Diagnostic accuracy of transabdominal ultrasound in respect to transvaginal ultrasound in diagnosing ectopic pregnancy in a tertiary care hospital of Kolkata taking histopathology as gold standard: a prospective study

Prasun Das<sup>1</sup>, Raj Saha<sup>1</sup>, Srijak Bhattacharyya<sup>1</sup>, Swadha Priya Basu<sup>1\*</sup>, Debopriyo Das<sup>2</sup>

<sup>1</sup>Department of Radiodiagnosis, <sup>2</sup>Department of Pathology, Nil Ratan Sircar Medical College and Hospital, Kolkata, West Bengal, India

**Received:** 19 May 2021

**Revised:** 17 June 2021

**Accepted:** 18 June 2021

### \*Correspondence:

Dr. Swadha Priya Basu,

E-mail: drswadhapriyabasu@gmail.com

**Copyright:** © the author(s), publisher and licensee Medip Academy. This is an open-access article distributed under the terms of the Creative Commons Attribution Non-Commercial License, which permits unrestricted non-commercial use, distribution, and reproduction in any medium, provided the original work is properly cited.

## ABSTRACT

**Background:** Ectopic pregnancy (EP) represents an important cause of acute pelvic pain in women of reproductive age. Initial evaluation consists of appropriate history and clinical examination followed by pelvic ultrasonography (US) and hormonal assays. Objective of the study was to measure diagnostic accuracy of TAS in respect to TVS in detecting ectopic pregnancy.

**Methods:** This prospective cross sectional study was done for 1 year duration in Nilratan Sircar Medical College and Hospital, Kolkata. 50 patients with suspected ectopic pregnancy were transferred from Gynae emergency ward and trans-abdominal, transvaginal ultrasound were subsequently performed on each. The results were corroborated with histopathology reports..

**Results:** Diagnostic parameters of TAS in respect to HPE:sensitivity 75.5, specificity-80,PPV-97.1, NPV-26.6 (all in percentages). Diagnostic parameters of TVS in respect to HPE:sensitivity 86.6, specificity-80, PPV-97.5, NPV-40 (all in percentages).

**Conclusions:** Sonography by transvaginal route stood way ahead of trans abdominal scan in terms of all diagnostic parameters to correctly evaluate ectopic pregnancy.

**Keywords:** Ectopic pregnancy, Transabdominal ultrasound, Transvaginal ultrasound

## INTRODUCTION

Ectopic pregnancy (EP) occurs when the developing blastocyst becomes implanted at a site other than the endometrium of the uterine cavity. In the general population, the average prevalence of EP is 1-2 percent and 2-5 percent for patients who have used assisted reproductive technology (ART).<sup>1</sup> Worldwide, in women of childbearing age, EP is a major cause of morbidity and death, especially in countries or areas with inadequate

prenatal care. In recent years, the mortality rate from EP has decreased, possibly largely due to technical advances in ultrasound imaging, earlier sonographic imaging and diagnosis, more responsive hCG tests, and improved laparoscopy and methotrexate (MTX) therapy, as well as increased diagnostic knowledge among clinicians and patients. Normally, fertilization of an ovum takes place in the fallopian tube. Then, about 6 days after fertilization, the fertilized egg moves down the fallopian tube to implant within the endometrial cavity. Ectopic

implantation may result in any delay or obstruction of transit inside the fallopian tube. The vast majority, 95% to 99%, of EPs are located within the fallopian tube.<sup>2</sup> Major risk factors are tubal disease, pelvic inflammatory disease salpingitis previous ectopic pregnancy salpingitis nodosa isthmica, tubal sterilization and reconstructive tubal surgery, in utero exposure to Dethystilbesterol (DES), Assisted reproductive technologies (ART), Intrauterine devices (IUD). Minor risk factors are endometriosis, early age at first intercourse (<18 years), older maternal age at first pregnancy (>35 years), cigarette smoking, previous pelvic/abdominal surgery, no known risk factors (50% of cases).<sup>3</sup> Most patients who have an ectopic pregnancy present with a 5-9 week history of amenorrhea, mild pelvic pain, and vaginal spotting. These symptoms should trigger an evaluation for an ectopic pregnancy.<sup>4</sup> The differential diagnosis for pelvic pain in early pregnancy includes early pregnancy failure, normal intrauterine pregnancy, salpingitis, torsion or rupture of the ovarian cyst, bleeding corpus luteum, endometriosis, appendicitis, gastroenteritis, diverticulitis, diseases affecting urinary tract.

Laparoscopy is the approved gold standard for tubal ectopic pregnancy diagnosis.<sup>5</sup> The diagnosis is confirmed by the visualization of a tubal pregnancy during laparoscopy and the subsequent histological confirmation of chorionic villi following surgery. Laparoscopy is an invasive procedure that requires general anaesthetic having many risk factors. For the diagnosis of tubal ectopic pregnancy, laparoscopy does not confer 100 percent sensitivity.<sup>6</sup> Some tubal ectopic pregnancies may be overlooked during laparoscopy. This can occur when the laparoscopy detection of the ectopic pregnancy is too small or when the ectopic pregnancy spontaneously fails. A major role of US in evaluating a patient with clinical suspicion for EP is to establish the presence of an IUP because 70% to 90% of patients presenting with pelvic pain and/or vaginal bleeding in the first trimester will ultimately be diagnosed as having an IUP. Therefore early and reliable diagnosis of ectopic pregnancy is major challenge for clinician and is essential to avoid life-threatening bleeding or consequent infertility. Any clinical suspicion for a ruptured ectopic pregnancy in a patient in an unstable condition warrants emergent surgical intervention.<sup>7</sup> On ultrasound the uterine findings of EP are as follows fluid collection is central in uterine cavity with "pointy" edges due to blood accumulation with absence of an intrauterine gestational sac (Figure 6A). On ultrasound the adnexal findings are as follows: Visualization of an extrauterine gestational sac containing a yolk sac (Figure 6B) or an embryo with or without a heartbeat is diagnostic of an EP with sugar doughnut sign. On doppler study, ring of fire sign noted which should be differentiated with corpus luteum which is the closest differential of EP (Figure 5). In interstitial EP there is eccentric location of the gestational sac within the myometrium and clear separation from the endometrial cavity. Cervical EP shows eccentric gestational sac embedded in the wall of the cervix as the trophoblastic

tissue invades through the cervical mucosa, usually through a defect in the lining. The G sac in caesarean scar EP lies at the site of the cesarean incision scar just above the internal cervical os. posthysterectomy EPs are the rarest of the unusual EPs. After hysteroscopic guided biopsy, we found ectopic pregnancy to be seen grossly as distension of tube with thin or ruptured wall, dusky red serosa and hematosalpinx, possibly with fetal parts identified. On microscopy, we see the following histological features: intraluminal chorionic villi and extravillous trophoblast (possibly degenerated); foetal sections vary (Figure 7), decidual alteration in the lamina propria in one-third of the cases; reactive mesothelial proliferation with papillary development and psammoma bodies. In uterus gestational hyperplasia with Arias-Stella reaction, absence of swollen, hyalinized spiral arteries, and absence of fibrinoid matrix. Justification for performing TVS prior to obtaining the serum hCG results includes reports that up to 50% of ruptured EPs have extremely low hCG levels (<1000 mIU/mL) and that hCG levels do not necessarily correlate with risk of rupture.<sup>8</sup> Although TVS is much more sensitive than transabdominal sonography, most experts recommend that scanning begin with transabdominal pelvic ultrasound, albeit without intentional filling of the bladder.<sup>9</sup> Transabdominal sonography should still be the initial sonographic technique for routine evaluation of female pelvis followed by transvaginal sonography.<sup>10</sup>

The main objectives were to show that transabdominal ultrasonography is superior to transvaginal ultrasonography by comparing the findings of the two imaging techniques and correlate of imaging findings with those of histopathology findings and thus finding out the sensitivity, specificity and accuracy of transvaginal ultrasonography and transabdominal ultrasonography.

## METHODS

This hospital based prospective cross sectional study was done in Nil Ratan Sircar Medical College and Hospital from February 2020 to January 2021 with 50 patients referred from gynaecology emergency with suspected ectopic pregnancy. Institutional review board approval for conducting this study was obtained and informed consent of all those 50 patients were taken.

### *Inclusion criteria*

Clinically suspected ectopic pregnancy and patients having pelvic or lower abdominal pain, vaginal bleeding, positive pregnancy test and raised serum beta HCG level were included in the study.

### *Exclusion criteria*

Exclusion criterias were post-menopausal women, Girls who has not achieved menarche, known gynecological malignancy, known urogenital anomalies, inability to

perform both TAS, TVS and patient requiring urgent surgical intervention.

Institutional review board approval for conducting this study was obtained and informed consent of all those 50 patients were taken. After recording patients' obstetrical history, clinical examination, and relevant investigations including pregnancy test, we briefly told the participants about the procedure of TAS and TVS. Transabdominal scanning was done with distended bladder by using real time scanners with low frequency probe (3.5 MHz). High-frequency endovaginal probe (7.5 MHz) (Philips HD 7 machine) was used after the patient was asked to void urine. Scanning was done in both coronal and sagittal planes.<sup>11</sup> A systematic approach was used for both TVS and TAS. First the uterus was scanned, then the adnexa, and finally the Cul-de Sac and hepatorenal pouch. The uterine cavity was first located and examined to exclude the presence of an intrauterine gestation. The ovaries were then identified and described after which the remainder of the adnexa were then carefully surveyed in an effort to locate any adnexal mass (Figure 4). A diagnosis of adnexal mass consistent with an ectopic pregnancy was made only if the ovary on the ipsilateral side was identified to exclude confusion with an ovarian cyst. The criteria for diagnosis of ectopic pregnancy included an extrauterine gestational sac containing a foetus or a foetal pole or an empty extrauterine sac. Solid or complex adnexal mass, peritoneal collection, pseudogestational sacs were considered suggestive and correlated with pregnancy test (hCG in urine and serum). All patients underwent surgery and peroperative findings were collected. Surgical diagnosis of ectopic pregnancy was made by visualization of foetal parts, gestational sac, haemoperitoneum, tubal status and in doubtful cases specimen was sent for histopathological examination. We noted all findings from sonographic analysis and corroborated with histopathology reports. Data were entered into a Microsoft excel spreadsheet and then analyzed by SPSS (version 24.0; SPSS Inc., Chicago, IL, USA and Graph Pad Prism version 5). Paired t-tests were a form of blocking and had greater power than unpaired tests. Unpaired proportions were compared by chi-square test or Fischer's exact test, as appropriate. Correlation was calculated by Pearson correlation analysis. The p-value was considered for statistically significant when less than 0.05 was considered significant. Finally we got diagnostic accuracy parameters of TAS and TVS.

**RESULTS**

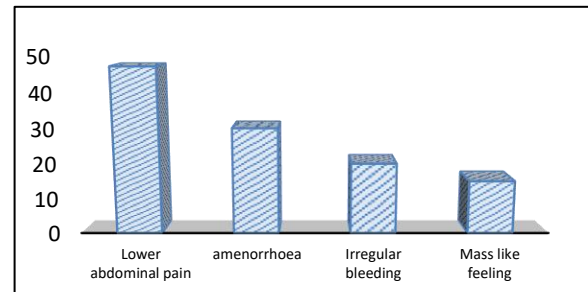
Major age group affected in suspected ectopic pregnancy was 20-25 years (40 out of 50). We found only 10 out of 50 patients were from low socio economic status. Most participants were nulliparous (25 of 50). We found that most common presenting symptom was lower abdominal pain (47 out of 50) followed by amenorrhoea (30 out of 50), irregular bleeding (20 out of 50). Mass like feeling noted in lower abdomen in 15 out of 50 patients (Figure 1).

**Table 1: Corroboration of findings of ectopic in TAS in respect to histopathology.**

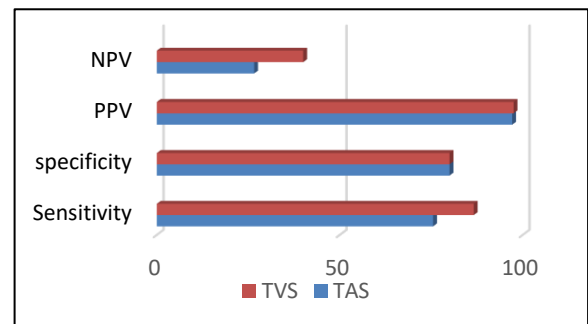
Detection by TAS	Confirmed by histopathology	Not confirmed by histopathology	Total
<b>Positive</b>	34	1	35
<b>Negative</b>	11	4	15
<b>Total</b>	45	5	50

**Table 2: Corroboration of findings of ectopic in TVS in respect to histopathology.**

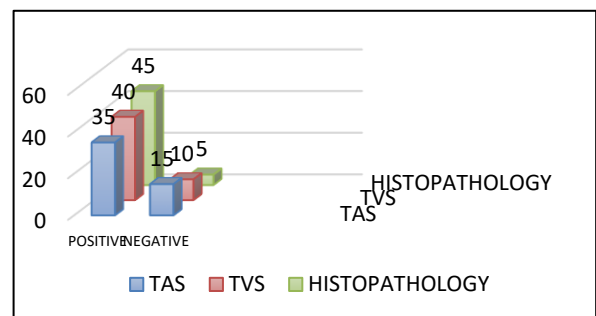
Detection by TVS	Confirmed by histopathology	Not confirmed by histopathology	Total
<b>Positive</b>	39	1	40
<b>Negative</b>	6	4	10
<b>Total</b>	45	5	50



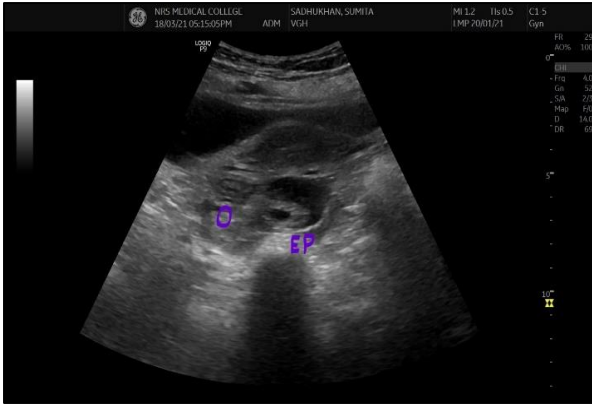
**Figure 1: Distribution of presenting symptoms in suspected ectopic pregnancy.**



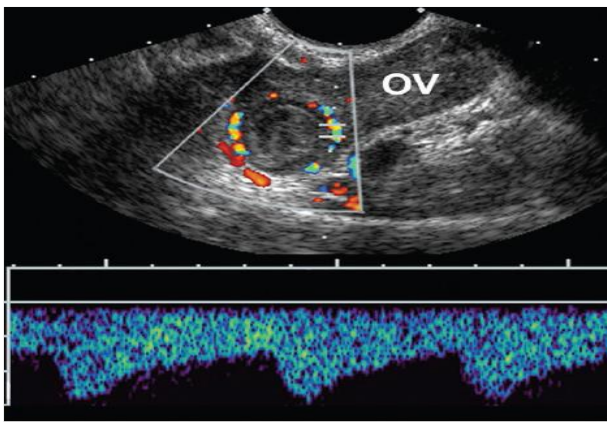
**Figure 2: Diagnostic accuracy parameters of TAS in respect to TVS (%).**



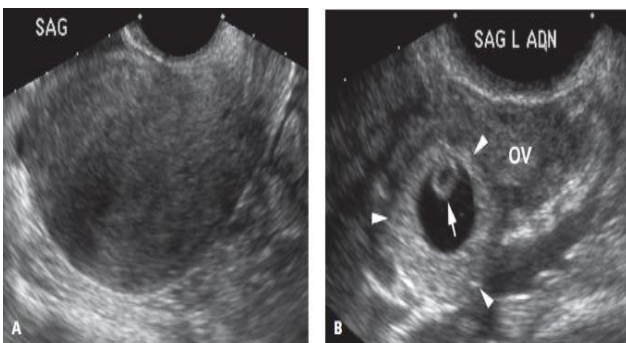
**Figure 3: Detection rate of ectopic pregnancy of TAS and TVS in respect to histopathology.**



**Figure 4: Transabdominal ultrasonography of pelvic region showing a complex cystic lesion in right adnexa completely separable from right ovary.**



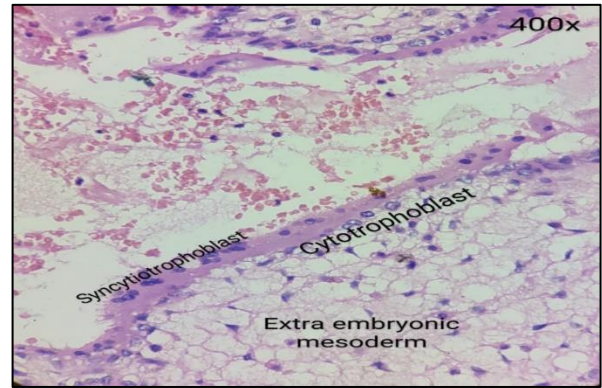
**Figure 5: Transvaginal ultrasound showing solid appearing lesion in left adnexa with ring of fire sign having low resistance flow in colour Doppler.**



**Figure no 6 shows TVS view revealing empty uterine cavity(6A) with yolk sac(arrowhead) containing G sac near the ovary(6B)**

We found that most common risk factor identified was history of pelvic inflammatory disease (40 out of 50) followed by previous history of ectopic (35 out of 50). In all 50 cases we got positive results recorded in pregnancy test and no intrauterine G sac was demonstrated in any modes of ultrasound. TAS detected 35 cases to be ectopic (Table 1); whereas TVS detected 40 cases to be ectopic

(Table 2), and in histopathology 45 cases were confirmed to be ectopic prospectively (Figure 3). Diagnostic parameters of TAS in respect to HPE:sensitivity 75.5, specificity-80, PPV-97.1, NPV-26.6 (all in percentages). Diagnostic parameters of TVS in respect to HPE:sensitivity 86.6, specificity-80, PPV-97.5, NPV-40 (all in percentages) (Figure 2).



**Figure 7: Histopathological findings in ectopic.**

## DISCUSSION

Ectopic pregnancies are estimated to occur in 1.4% of all pregnancies and account for 15% of pregnancy-related deaths.<sup>12</sup> The incidence of ectopic pregnancy (EP) is increasing as a result of an increase in the number of patients with risk factors as well as an increase in diagnosis due to earlier presentation and detection. But Mortality rate from EP is decreasing because of improved diagnostic techniques and heightened awareness among clinicians and patients. The classical triad of abdominal or pelvic pain, vaginal bleeding, and an adnexal mass was seen in our study in only 20 out of 50 cases (40%); as comparable in the study of Alsuleiman et al where they found the triad in 50% cases.<sup>13</sup> Major age group affected in our study was 20-25 years (80%), Akram et al showed in ectopic pregnancy. Majority of the patients 61 (50.83%) belonged to 20-25 years. 83.33% of the patients were  $\leq 30$  year.<sup>14</sup> We found only 20% of participants were from low socio economic status; contrary to the study shown by Kharat et al where most of the patients (88.1%) cases were belonging to low socioeconomic status.<sup>15</sup> In our study, 50% were nulliparous; similar finding as shown in study documented by Arup et al. where ectopic pregnancy was most commonly noted in 44.23% cases.<sup>16</sup> Most frequent complain presented by participants was lower abdominal pain in our study (94%) followed by amenorrhoea (60%), irregular bleeding (56%); contrary to the finding in study done by Pal et al in 1996 where they showed pain was the commonest symptom (91.7%) followed by bleeding per vagina (71.7%) and amenorrhoea (41.4%).<sup>17</sup> Most commonly identified risk factor was found to be PID; similarly shown in study by Bohm et al.<sup>18</sup> The diagnostic parameters of TAS in respect to HPE were found to be having sensitivity 75.5, specificity-80, PPV-97.1, NPV-

26.6 (all in percentages); in contrary to the findings of the study done by Kim et al where they found transabdominal ultrasonography was 95.9% sensitive, 73.9% specific and positive predictive value was 73.9% in detecting Ectopic.<sup>19</sup> The diagnostic accuracy parameters of TVS in respect to HPE were found to be having 86.6% sensitivity, 80% specificity, 97.5% PPV and 40% NPV; which corroborates with the study done by Shalev and colleagues where they found that the use of TVS in the diagnosis of an ectopic pregnancy has a sensitivity of 87%, specificity of 94%, and positive predictive value of 92.5%.<sup>20</sup> The limitations of our study may be due to small sample size and 1 year duration.

## CONCLUSION

Transabdominal ultrasound is a good modality to diagnose ectopic. But it cannot catch Transvaginal ultrasound in terms of diagnostic accuracy parameters. We should use both modalities of ultrasound sequentially (TAS to be in first preferably) so that we will not miss any cases of ectopic preferably as early diagnosis can be very valuable in lessening morbidity and mortality. Diagnosis before tubal rupture can prevent life-threatening hemorrhage and increase the probability that the patient may be managed medically or via tube-conserving surgery.

*Funding: No funding sources*

*Conflict of interest: None declared*

*Ethical approval: The study was approved by the Institutional Ethics Committee*

## REFERENCES

- Practice Committee of the American Society for Reproductive Medicine. Medical treatment of ectopic pregnancy: a committee opinion. *Fertil Steril*. 2013;100:638-44.
- Gurel S, Sarikaya B, Gurel K. Role of Sonography in the diagnosis of ectopic pregnancy. *J Clin Ultrasound*. 2007;35:509-17.
- Marye N, Leslie S, Vickie F. Callen's ultrasonography in obstetrics and gynecology. 6<sup>th</sup> Edition. 2017:967.
- Lipscomb GH, Stovall TG, Ling FW. Nonsurgical treatment of ectopic pregnancy. *N Engl J Med*. 2000;343:1325-9.
- Ankum WM, Veen F, Hamerlynck JV, Lammes FB. Laparoscopy: a dispensable tool in the diagnosis of ectopic pregnancy? *Hum Reprod*. 1993;3:1301-6.
- Condous G, Okaro E, Khalid A. A prospective evaluation of a single-visit strategy to manage pregnancies of unknown location. *Hum Reprod*. 2005;20:1398-403.
- Attar E. Endocrinology of ectopic pregnancy. *Obstet Gynecol Clin North Am*. 2004;31:779-94.
- Saxon D, Falcone T, Mascha EJ. A study of ruptured tubal ectopic pregnancy. *Obstet Gynecol*. 1997;90:46-9.
- Benacerraf BR. Filling of the bladder for pelvic sonograms: an ancient form of torture. *J Ultrasound Med*. 2003;22:239-41.
- Gruzinskas JG. Miscarriage, ectopic pregnancy and trophoblastic disease. In: Edmonds DK, editor. *Dewhurst's textbook of obstetrics and gynecology for postgraduate*. 6th ed. London: Blackwell sci. 1999;61-75.
- Tritsch IE, Farine D, Rosen MG. A close look at early embryonic development with the high-frequency transvaginal transducer. *Am J Obstet Gynecol*. 1988;159(3):676-81.
- Levi CS, Lyons EA. The first trimester. In: Rumack CM, Wilson SR, Charboneau JW, Levine D, eds. *Diagnostic Ultrasound (4<sup>th</sup> edition)*. Philadelphia: Elsevier; 2011:1099-1110.
- Alsuleiman SA, Grimes EM. Ectopic pregnancy: a review of 147 cases. *J Reprod Med*. 1982;27(2):101-6.
- Akram S. A clinic-demographic study of incidence of ectopic pregnancy and its management. *Int J Health Clin Res*. 2020;3(9):233-8.
- Kharat D, Giri PG, Fonseca M. A study of epidemiology of ectopic pregnancies in a tertiary care hospital of Mumbai, India. *Int J Reprod Contracept Obstet Gynecol*. 2017;6(9):3942-6.
- Arup KM, Niloptal R, Kakali SK, Pradip KB. Ectopic pregnancy- an analysis of 180 cases. *J Indian Med Assoc*. 2007;105:308-14.
- Pal A, Gupta KB, Sarin R. A study of ectopic pregnancy and high risk factors in Himachal Pradesh. *J Indian Med Assoc*. 1996;94(5):172-3.
- Velez BM, Mendelson EB, Freimanis MG: Transvaginal sonography in evaluating ectopic pregnancy. *Semin Ultrasound*. 1990;11(1):44-58.
- Kim DS, Chung SR, Park MI, Kim YP. Comparative review of diagnostic accuracy in tubal pregnancy: a 14-year survey of 1040 cases. *Obstet Gynaecol*. 1987;70(4):547-54.
- Shalev E, Yarom I, Bustan M, Weiner E, Shlomo I. Transvaginal sonography as the ultimate diagnostic tool for the management of ectopic pregnancy: experience with 840 cases. *Fertil Steril*. 1998;69:62-5.

**Cite this article as:** Das P, Saha R, Bhattacharyya S, Basu SP, Das D. Diagnostic accuracy of transabdominal ultrasound in respect to transvaginal ultrasound in diagnosing ectopic pregnancy in a tertiary care hospital of Kolkata taking histopathology as gold standard: a prospective study. *Int J Res Med Sci* 2021;9:1965-9.