

## Case Report

# Importance of magnetic resonance imaging brain in metronidazole-induced cerebellar ataxia- a case report

Munish Kumar<sup>1\*</sup>, Chitra Priyadarshini<sup>2</sup>

<sup>1</sup>Department of Neurology, Patna Medical College, Patna, Bihar, India

<sup>2</sup>Department of Medicine, Patna Medical College, Patna, Bihar, India

**Received:** 25 January 2021

**Accepted:** 03 March 2021

### \*Correspondence:

Dr. Munish Kumar,

E-mail: munishpmch@gmail.com

**Copyright:** © the author(s), publisher and licensee Medip Academy. This is an open-access article distributed under the terms of the Creative Commons Attribution Non-Commercial License, which permits unrestricted non-commercial use, distribution, and reproduction in any medium, provided the original work is properly cited.

## ABSTRACT

Metronidazole is an antibiotic and an antiprotozoal drug, is cost effective treatment of choice in amoebic liver abscess. Cerebellar toxicity is quite rare and serious side effect of metronidazole, which is reversible. The importance of MRI brain in this condition is the typical finding of abnormal T2 as well as FLAIR hyperintensities in dentate nuclei and splenium of corpus callosum. We present a case of liver abscess on prolong metronidazole treatment presented with acute onset cerebellar ataxia.

**Keywords:** Metronidazole toxicity, Cerebellar ataxia, Liver abscess

## INTRODUCTION

Metronidazole is a synthetic 5-nitroimidazole, an antibiotic and anti-protozoal drug. It is considered to be cost-effective drug of choice for treatment of amoebic liver abscess. Common side effects are headache, nausea, dry mouth, and metallic taste. Sometimes vomiting, diarrhea and abdominal pain occurs. Dizziness, vertigo, and very rarely encephalopathy, convulsions and ataxia are neurotoxic effects that need drug discontinuation.<sup>1</sup> Neurological features usually manifest when the drug is used in a dose exceeding 2 gm/day for prolonged periods.<sup>1</sup> Cerebellar ataxia due to Metronidazole, the dosage usually ranges from 25 to 1080 gm and therapeutic duration ranging from 5 to 730 days, with classic findings on magnetic resonance imaging (MRI).<sup>2,3</sup> Most CNS adverse effects usually resolve over a period of 2-8 weeks. We present a case of liver abscess presented with metronidazole induced cerebellar ataxia.

## CASE REPORT

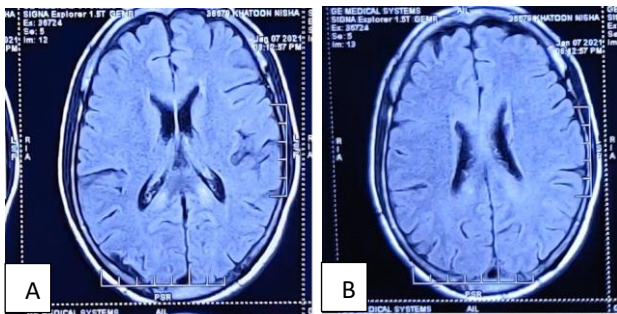
A 50-year-old female admitted in medicine department in Patna medical college, Patna, on 13<sup>th</sup> November 2020

with complaints of fever and abdominal pain, diagnosed as a case of liver abscesses (volume-758 ml) with right pleural effusion and was managed initially by intravenous metronidazole 500 mg three times a day for 7 days along with drainage of abscess. She improved and was discharged on oral metronidazole 800 mg thrice a day for 14 days. Fifteen days after discharge, On 2<sup>nd</sup> December 2020 she presented again with pain abdomen and vomiting. Repeat USG showed large liver abscess (volume-805 ml), for which repeat drainage done along with intravenous metronidazole 500 mg thrice a day for 7 days and discharged on oral metronidazole 800 mg thrice a day for 7 days, but she continued the drug. On 5<sup>th</sup> January 2021 i.e., 54 days after initial presentation she reported with 2 days history of slurring of speech, incoordination, progressive unsteadiness of gait and inability to walk. This was not associated with headache, tremors, seizures, any limb weakness, fever, loss of bowel or bladder control, dysphagia, nasal regurgitation, dysphonia, numbness or tingling sensation. On neurologic examination, she was conscious and oriented to person, place, and time. Had slurring of speech. Cranial nerve examination revealed horizontal nystagmus without vertical nystagmus. Pupils were bilaterally

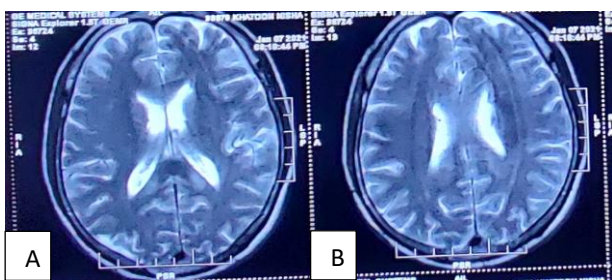
normal in size equally reactive to light. There was truncal as well as appendicular ataxia. The muscle power was 5/5 with hypotonia in all four limbs. Deep tendon reflexes were normally present and equal. Had wide-based gait; she felt unsteady and was unable to walk without support. Her sensory examination was normal. The Romberg's sign could not be tested properly because of imbalance. MRI Brain revealed abnormal T2 as well as FLAIR hyperintensities in dentate nuclei and splenium of corpus callosum, no mass, hemorrhage or herniation was seen (Figure 1-3).

**Table 1: Biochemical parameters.**

Parameters	13-11-2020	2-12-2020	5-1-2021	12-1-2021
Hb % (gm/dl)	9.9	9.1	10.0	
Random blood sugar (mg/dl)	83	94	94	
Blood urea (mg/dl)	34	24	21	
S. creatinine (mg/dl)	1.0	1.3	0.8	
S. sodium (mmol/L)	132	133	140	
S. Potassium (mmol/L)	3.9	4.2	3.7	
S. Bilirubin (mg/dl)	0.8	0.7	0.6	
SGPT (IU/L)	25	31	25	
SGOT (IU/L)	28	24	30	
S. vitamin B12 (pg/ml)				1828

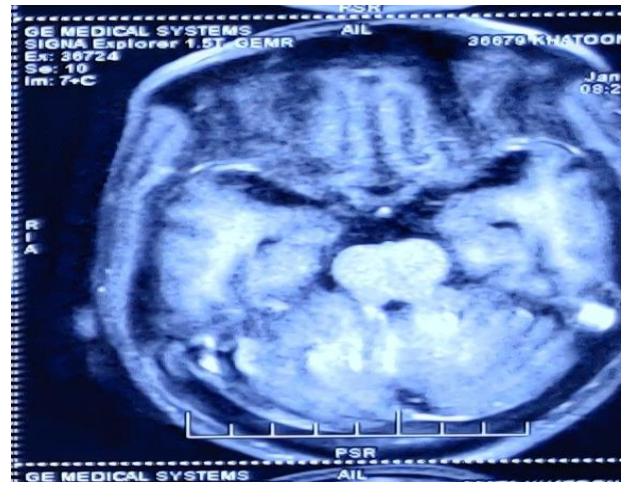


**Figure 1: Flair hyperintensity of corpus callosum.**



**Figure 2: T2 hyperintensity in splenium of corpus callosum.**

Complete hemogram, liver function tests, kidney function tests were all within normal limits (Table 1). Hepatitis B and C with HIV serology were negative. Serum electrolytes were normal. Cerebrospinal fluid examination was normal. USG abdomen done on 6<sup>th</sup> January 2021, showed small abscess (volume-50 ml). Repeat X-ray chest showed resolution of right plural effusion.



**Figure 3: Flair hyperintensity in dentate nucleus of cerebellum.**

**DISCUSSION**

Liver abscesses are caused by bacterial, protozoal, or fungal infection.<sup>4</sup> Out of this amoebic liver abscess is more common and metronidazole is the mainstay of treatment. Ninety five per cent of uncomplicated amoebic abscesses resolve with metronidazole alone.<sup>4</sup> Use of metronidazole in excessive doses can give rise to neurological problems such as cerebellar ataxia, seizures, peripheral neuropathies, and encephalopathy.<sup>1</sup> Cerebellar toxicity is a very unusual manifestation of metronidazole therapy, the dosage usually ranges from 25 to 1080 gm and therapeutic duration ranging from 5 to 730 days.<sup>2</sup> The imaging findings of metronidazole toxicity were first described by Ahmed et al., as symmetric abnormal signal within supratentorial white matter, including the corpus callosum, and within the cerebellum, including the cerebellar deep gray matter nuclei.<sup>5</sup> It has been proposed that axonal swelling with increased water content causes the MRI changes due to T2 prolongation, hence the MRI changes are reversible after stopping of the drug.<sup>5</sup> Metronidazole binds to RNA, DNA and inhibitory neurotransmitters, as well as induces both vasogenic and cytotoxic edema that causes neurotoxicity.<sup>6</sup> The exact mechanism by which metronidazole causes reversible cerebellar ataxia and dentate nuclei changes is unclear. High doses of metronidazole in rats have also been shown to induce lesions in the cerebellum.<sup>7</sup> The differential diagnosis of bilateral symmetric T2 hyperintense lesions in dentate nuclei is methyl bromide intoxication, maple syrup urine disease and enteroviral encephalomyelitis.<sup>8</sup> In our patient the diagnosis of

metronidazole induced cerebellar ataxia is made by MRI findings in conjunction with clinical findings, normal CSF examination and treatment history of patient. The total cumulative dose of metronidazole was high in this case. As it is a reversible condition and patient improves after stopping the offending drug, physicians should be aware of the entity. So, metronidazole induced ataxia should be suspected in any patient on metronidazole treatment after ruling out other possible causes by relevant investigation along with typical changes on MRI brain.

## CONCLUSION

Patients on high dose metronidazole therapy for prolong time should be monitored for neurotoxicity. MRI findings of bilateral increased T2/FLAIR signal of the dentate nuclei are a very characteristic feature of metronidazole-induced neurotoxicity. Metronidazole should be immediately discontinued. Complete reversal of symptoms and imaging findings is seen in most of the cases. Follow-up imaging is usually unnecessary once the clinical signs and symptoms have resolved.

*Funding: No funding sources*

*Conflict of interest: None declared*

*Ethical approval: Not required*

## REFERENCES

1. Neki NS, Joshi N, Rana D, Singh GD, Shergil, Singh G et al. Metronidazole toxicity presenting with cerebellar ataxia. Int J Curr Res Med Sci. 2017;3:10-3.
2. Patel K, Hopkins G. cerebellar ataxia following prolonged use of Metronidazole: case report and a literature review. Int J infectious dis. 2008;12:e111-4.
3. Woodruff BK, Wijdicks EF, Marshall WF. Reversible metronidazole-induced lesions of the cerebellar dentate nuclei. N Engl J Med. 2002;346:68-9.
4. Krige JEJ, Beckingham IJ. Liver abscesses and hydatid disease. BMJ. 2001;322(7285):537-40.
5. Ahmed A, Loes DJ, Bressler EL. Reversible magnetic resonance imaging findings in metronidazole-induced encephalopathy. Neurology. 1995;45:588-9.
6. Iqbal A, Tripathi K, Rai M, Dwivedi AN. Clinical and imaging perspective and unanswered questions in a case of metronidazole induced encephalopathy. Ann Indian Acad Neurol. 2013;16(4):569-71.
7. Ojha P, Chourasiya M, Shah H, Pandey V. Metronidazole induced Reversible Cerebellar Ataxia in a patient of multiple liver abscesses: a case report. Int J Biomed Adv Res. 2014;5:643-4.
8. Kalia V, Vibhuti, Saggarr K. Case report: MRI of the brain in metronidazole toxicity. Indian J Radiol Imaging. 2010;20(3):195-7.

**Cite this article as:** Kumar M, Priyadarshini C. Importance of magnetic resonance imaging brain in metronidazole-induced cerebellar ataxia- a case report. Int J Res Med Sci 2021;9:1222-4.