

## Case Report

# Neural, renal and retinal hamartomas with cutis vertis gyrata a rare presentation in tuberous sclerosis complex

Nita U. Shanbhag<sup>1</sup>, Nupur Vijay Bhatt<sup>1\*</sup>, Sharmila Patil<sup>2</sup>, Priyadarshini Cholera<sup>1</sup>

<sup>1</sup>Department of Ophthalmology, <sup>2</sup>Department of Dermatology, D. Y. Patil Hospital and Research centre, Navi Mumbai, Maharashtra, India

**Received:** 18 August 2015

**Revised:** 22 September 2015

**Accepted:** 05 October 2015

### \*Correspondence:

Dr. Nupur Vijay Bhatt,

E-mail: [nupur.bhatt.24@gmail.com](mailto:nupur.bhatt.24@gmail.com)

**Copyright:** © the author(s), publisher and licensee Medip Academy. This is an open-access article distributed under the terms of the Creative Commons Attribution Non-Commercial License, which permits unrestricted non-commercial use, distribution, and reproduction in any medium, provided the original work is properly cited.

## ABSTRACT

Tuberous sclerosis complex characterised by multiple benign tumours, is caused by mutation in the genes TSC1 and TSC2 coding for Hamartin and Tuberin respectively. We report a case of a 17 year old female patient who presented with classical Vogt's triad characterized by seizures, mental retardation and adenoma sebaceous. She presented with Cutis Vertis Gyrata in addition to multiple retinal astrocytic hamartomas in her right eye with retinal pigment epithelium changes in both eyes and a normal anterior segment examination. Magnetic resonance imaging (MRI) of the brain showed subependymal giant cell astrocytomas and cortical tubers. Ultrasound of the abdomen showed bilateral renal angiomyoliposis. We are presenting this case as retinal hamartomas with five Major criteria are seen along with secondary Cutis Vertis Gyrata which is an extremely rare presentation of Tuberous sclerosis. Absence of most of the Minor criteria is not to be excluded.

**Keywords:** Tuberous sclerosis, Astrocytic retinal hamartomas, Cutis Vertis Gyrata, Subependymal giant cell astrocytoma, Renal angiomyolipomas

## INTRODUCTION

Tuberous sclerosis was first described by Von Recklinghausen in 1862. Desire-Magloire Bourneville (a French physician) coined the term sclerosetubereuse, from which the disease derives its name.<sup>1</sup> Tuberous Sclerosis Complex (TSC) is a genetic disorder characterized by the growth of numerous benign tumours in various parts of the body, such as the brain, heart, lungs, eyes, kidneys, skin and other organs, leading to significant health problems like seizures, intellectual disability, or developmental delay. Definite TSC is diagnosed when there is presence of either 2 major features (out of a total of 11) or one major feature with 2 minor features (out of a total of 9) (Table 1).<sup>1-3</sup> The major ophthalmic manifestations associated with tuberous sclerosis are retinal astrocytic hamartomas and eyelid angiofibromas.<sup>4</sup> Cutis Vertis Gyrata is hypertrophy and

folding of the skin of scalp giving it a cerebriform appearance. It is very rarely associated with tuberous sclerosis.<sup>5,6</sup> Ophthalmic features associated with TSC can be divided into retinal and non-retinal. The retinal associations of TSC were first noted by Van der Hoeve in 1921.<sup>7</sup> These lesions initially called phakomas (derived from the Greek word phakos-meaning spot) and concept of phakomatosis was introduced by him. These retinal lesions are now known to be "astrocytic hamartomas". Three basic morphological types of retinal hamartomas have been described in literature 4: (i) the relatively flat, smooth, non-calcified, grey, translucent lesion; (ii) the elevated, multinodular, calcified, opaque lesion resembling mulberries; and (iii) a transitional lesion which has morphological features of both the above. Other retinal findings seen include retinal pigmentary disturbance which range from hyperpigmented areas to "punched out" hypopigmented areas at the posterior pole

or midperiphery. Non-retinal findings include angiofibromas of the eyelids, coloboma of the iris, lens and choroid, strabismus, poliosis of eyelashes, papilledema, and sector iris depigmentation.<sup>8</sup>

**CASE REPORT**

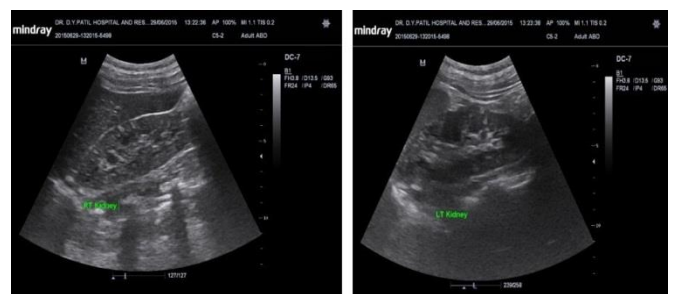
A 17 year old girl known case of seizure disorder for 10 years was referred to our outpatient department for ophthalmic evaluation. The patient was admitted in the medicine ward where she was being treated for her seizure disorder. There was no history of any ocular complaints. On external examination the patient was well built but seemed to be of subnormal intelligence. There was no positive birth history. Parents were normal, and younger sibling had just angiofibromas of the face showing 100% gene penetration. On examination the skin of the face forehead and eyelids showed multiple papules of sebaceous adenoma in the butterfly area of the face (Figure 1). Thick leathery area of the skin that dimpled like an orange peel 7 cm x 4 cm was seen on temporal aspect of the left forehead suggestive of a shagreen patch (Figure 1). Non pigmented hypertrophy and folding of the skin of scalp in both the parietal-occipital region largest measuring (15cm x 7cm) with circumvolutions and deep grooves that imitate the cerebral surface giving a cerebriform appearance suggestive of Cutis Vertis Gyrate (Figure 2) .On ocular examination the visual acuity was 6/6 in both eyes. Multiple Angiofibromas were seen on the eye lids. There was a pigmented angiofibroma (Figure 1) 2 cm x 1 cm on left lower lid.

**Table 1: Diagnostic criteria for tuberous sclerosis complex (TSC).**

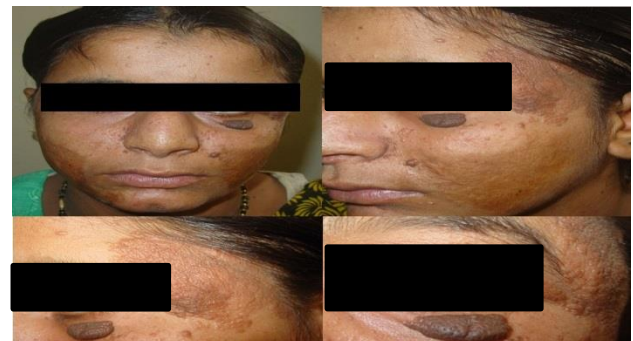Major features	Minor features
Facial angiofibromas or forehead plaques	Multiple randomly distribute pits in dental enamel
Nontraumatic ungual or periungual fibroma	Hamartomatous rectal polyps
Hypomelanotic macules (>3)	Bone cysts
Shagreen patch	Cerebral white matter migration tracts
Cortical tuber	Gingival fibromas
Subependymal nodule	Nonrenal hamartoma
Subependymal giant cell astrocytoma	Retinal achromic patch
Multiple retinal nodular hamartomas	Confetti skin lesions
Cardiac rhabdomyoma, single or multiple	Multiple renal cysts
Lymphangiomyomatosis	
Renal angiomyolipoma	

Café au lait spots were absent. Anterior segment examination was within normal limits. (Figure 3). Fundus examination of the right eye showed presence of two well defined circular white dense in the centre, opaque lesions one measuring 1/2 disc diameter (DD) at the superior

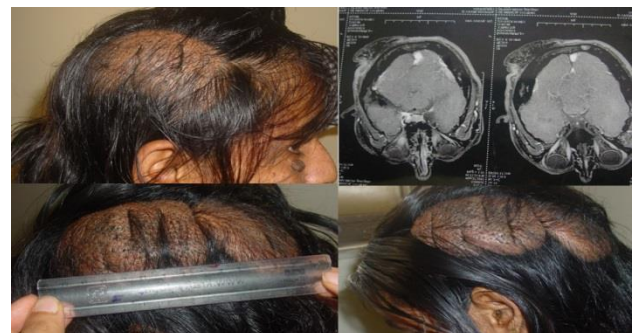arcade 2 DD from the optic disc and another 1/3rd DD about 2 DD from the macula at the edge of the superior arcade, obscuring the underlying blood vessels and retinal nerve fibre layer, suggestive of retinal astrocytic hamartomas. The left eye showed presence of retinal pigment epithelium changes (Figure 4). MRI brain showed the presence of subependymal lesions in the right caudo- thalamic groove with calcific foci suggestive of subependymal giant cell astrocytomas and focal nonenhancing cortical thickening and gyral flattening in bilateral frontal, occipital and left temporal lobes suggestive of cortical tubers (Figure5). An ultrasonography of the abdomen showed multiple echogenic lesions in the cortex of both kidneys suggestive of bilateral renal angiomyoliposis (Figure 6). X- Ray chest and echocardiography were normal.



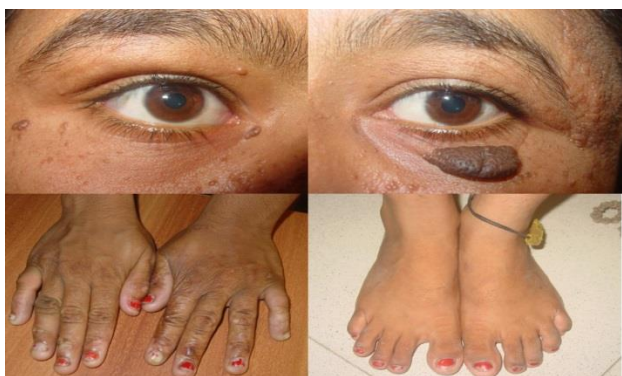**Figure 1: Angiofibromas in the butterfly area of the face with pigmented fibroma of the lower lid with shagreen patch.**



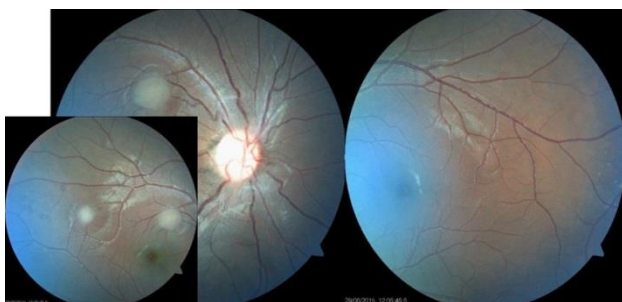**Figure 2: Cutis Vertis gyrate 15cm x 7 cm - extradural intradermal cerebriform lesion on both parieto-occipital region.**



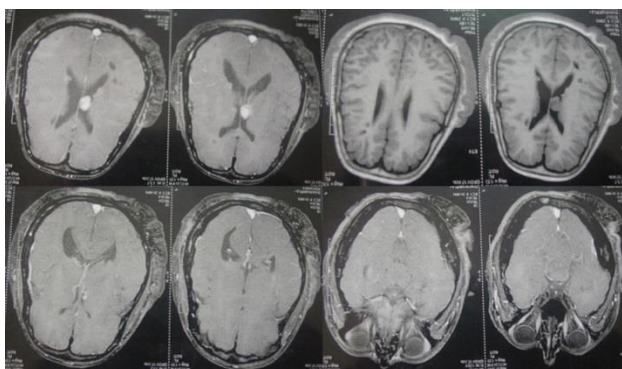
**Figure 3: Normal anterior segment with absence of Koenen's tumours.**



**Figure 4: Retinal hamartoma within papillo-macular bundle.**



**Figure 5: MRI brain showing subependymal giant cell astrocytomas, subependymal nodules and cortical tubers.**



**Figure 6: USG abdomen showing bilateral renal angiomyoliposis.**

## DISCUSSION

Tuberous sclerosis complex has varied clinical manifestations. Seizures the most common neurological manifestations of TSC occur in around 92 % of the patients.<sup>9</sup> Mental retardation and angiofibromas are reported in 70% of all cases.<sup>1</sup> Our case reported with all these three features.

Neurocutaneous manifestations associated with TSC make careful skin examination mandatory. As revealed in earlier studies the prevalence of facial angiofibromas, forehead or scalp plaques and shagreen patches were respectively 75%, 48%, 19%.<sup>10</sup> Our patient presented

with all three features. Our patient also presented with the rare Cutis Vertis Gyrata, which is classified into primary and secondary types. The secondary type is associated with systemic diseases such as acromegaly and tuberous sclerosis, inflammatory skin conditions such as plexiform neurofibroma, hamartomas. It has been previously reported with melanocytic naevi, connective tissue naevi or neurofibromatosis but only once in case of TSC.<sup>5-6</sup> There is a potential risk of developing melanomas in 4.5% of these lesions hence a regular follow up is necessary.

Retinal astrocytic hamartomas are seen in around 50% of the patients. They can manifest as a small, sessile, noncalcified lesions in the nerve fibre layer, as multinodular yellow white calcified lesions, or as a combination of the two.<sup>4,8</sup> Our case showed the multinodular white calcified lesion. It has been seen that astrocytic hamartomas are fairly stationary lesions with little or no tendency to grow.<sup>11</sup> Disturbances in the retinal pigment epithelium also referred to as punched out lesions have only recently been reported as a clear marker for TSC.<sup>12</sup>

Angiomyolipomas and renal cysts are the common types of renal associations of tuberous sclerosis.<sup>13</sup> Our patient presented with angiomyolipomas of both the kidneys. Rakowski reported an incidence of 85.4% in patients with tuberous sclerosis.<sup>14</sup> Our patient presented with 6 major features of the diagnostic criteria of TSC with almost nil minor criteria's.

An estimated that one million people are known to suffer from tuberous sclerosis .The prognosis of the disease depends upon the number of organs involved and severity of the disease. There is no specific cure for tuberous sclerosis. Our patient was symptomatically treated for her seizure disorder. As the retinal astrocytomas did not hamper the visual acuity and are unlikely to progress the patient was not prescribed any treatment. However she was counselled for a regular follow up every 6 months for Neural, Renal and retinal hamartomal growth in the rare event of progression or any other manifestation.

## CONCLUSION

To our knowledge this is a rare case report showing 6 major diagnostic features of tuberous sclerosis. An extremely rare presentation of hypertrophy and folding of the skin of scalp giving a cerebriform appearance suggestive of Cutis Vertis Gyrata presenting with classical Vogt triad of TSC. For an Ophthalmologist presence of retinal hamartomas especially in children with seizure disorders in the absence of many other features is a good marker for tuberous sclerosis.

*Funding: None*

*Conflict of interest: None declared*

*Ethical approval: Not required*

## REFERENCES

1. Shobha Bijjargi, Ashwini Rani SR, Veerendra S Patil, Sunil Bapure. Tuberous Sclerosis Complex Syndrome A Rare Case Report. *Journal of Medical Education & Research.* 2013;3:57-63.
2. Hung CC, SuYN, ChienSC, LiouHH, ChenCC, ChenPC, et al. Molecular and clinical analyses of 84 patients with tuberous sclerosis complex. *BMC Med Genet.* 2006;7:72.
3. TS Cheng. Tuberous sclerosis complex: an update Review Article Hong Kong J. *Dermatol. Venereol.* 2012; 20:61-67.
4. Rowley SA, O'Callaghan FJ, Osborne JP. Ophthalmic manifestations of tuberous sclerosis: a population based study. *Br J Ophthalmol.* 2001;85:420-3.
5. Tony Burns, Staphen Breathnach, Neil Cox, ChristopherGriffiths Rook's Textbook of Dermatology. 8th Edition Volume 4. Wiley Blackwell. Pages 66.58
6. León-Muñíos E, Monteagudo B. ¿Cutis verticis gyrata secundaria en un paciente con esclerosis tuberosa? *Cir Esp.* 2014; 92:699–700.
7. Kinder RSL. The ocular pathology of tuberous sclerosis. *J Paediatr Ophthalmol.* 1972; 9:106-107.
8. Robertson DM. Ophthalmic manifestations of tuberous sclerosis. *Ann NY Acad Sci.* 1991; 615:17-25.
9. Gupta S, Bhowate R, Degwekar SS. Clinical and radiological findings related to tuberous sclerosis complex: a case report. *J Contemp Dent Pract.* 2008; 9:85-91.
10. Jozwiak S, Schwartz RA, Janniger CK, Michalowicz R, Chmielik J. Skin lesions in children with tuberous sclerosis complex: their prevalence, natural course, and diagnostic significance. *Int J Dermatol.* 1998;37:911-7.
11. Zimmer-Galler IE, Robertson DM. Long term observation of retinal lesions in tuberous sclerosis. *Am J Ophthalmol.* 1995;119:318-24.
12. Shields CL, Reichstein DA, Bianciotto C, Shields JA. Retinal pigmented epithelium depigmented lesions associated with tuberous sclerosis complex. *Arch Ophthalmol.* 2012; 130:387-390.
13. Gupta S, Bhowate R, Degwekar SS. Clinical and radiological findings related to tuberous sclerosis complex: a case report. *J Contemp Dent Pract.* 2008; 9:85-91.
14. Rawboski SK, Winterkorn EB, Paul E, Steller DJ, et al. Renal manifestations of tuberous sclerosis complex: Incidence, prognosis, and predictive factors. *Kideny* 2006;70:1777-82.

**Cite this article as:** Shanbhag NU, Bhatt NU, Patil S, Cholera P. Neural, renal and retinal hamartomas with cutis vertis gyrata a rare presentation in tuberous sclerosis complex. *Int J Res Med Sci* 2015;3:3412-5.