

## Research Article

# A study of variations in the branching pattern of facial nerve in the face

Karey Venkata Naga Geetha Devi\*, Sarada Toleti

Department of Anatomy, Rangaraya Medical College, Dr. NTR University of Health Sciences, Vijayawada, AP, India

**Received:** 30 December 2014

**Accepted:** 15 January 2015

**\*Correspondence:**

Dr. Karey Venkata Naga Geetha Devi,

E-mail: geethadevi297@gmail.com

**Copyright:** © the author(s), publisher and licensee Medip Academy. This is an open-access article distributed under the terms of the Creative Commons Attribution Non-Commercial License, which permits unrestricted non-commercial use, distribution, and reproduction in any medium, provided the original work is properly cited.

### ABSTRACT

**Background:** Purpose of current study was to describe the variations in the complex network of terminal branches of facial nerve in the face. The facial nerve passes through the substance of parotid gland in the plane between superficial and deep lobes. The knowledge of variation in the branching pattern of terminal branches is very important for surgeons to prevent the injuries which may lead to facial palsy.

**Methods:** The present study includes fifty foetal parotid glands in 25 fetuses and 8 adult parotid glands of 4 cadavers. The glands exposed in fixed fetuses and adult cadavers, capsules removed. The superficial lobe of the gland reflected laterally and the trunk of facial nerve in the substance was observed. The divisions and terminal branches were traced. The variations in the divisions and terminal branches, loops between branches were observed and noted.

**Results:** In the foetal specimens the facial nerve divides into 2 main divisions in 88% of glands. The remaining 12% foetal specimens the facial nerve divides directly into 5 terminal branches. 56% foetal specimens show straight branching pattern, 12% specimens show looping between zygomatic and buccal branch. In 32% specimens the loop between upper buccal and lower buccal branches present. Multiple communications or complex pattern between two main divisions not found in this study.

**Conclusion:** The variations noted are: In the foetal specimens the facial nerve divides into two main divisions in 88% and in all adult specimens. In 12% of foetal specimens direct five terminal branches are given.

**Keywords:** Facial nerve, Parotid gland, Temporo-facial division, Cervico-facial division, Terminal branches

### INTRODUCTION

The complex network of terminal branches of the facial nerve, the seventh cranial nerve passes through the substance of parotid salivary gland to supply muscles of the facial expression. The anatomical structural scenario of the parotid gland is intimately related to the facial nerve along with vascular structures make the gland complex structure. The facial nerve injured during the surgical interventions for parotid diseases like parotid abscess, parotid fistulas, parotid duct stones (sialoliths); benign tumors and malignant growths. The nerve lies in a plane between superficial and deep lobes of the gland and the surgeons warranted for the surgical care for the

prevention of the injuries to the branches or the trunk of facial nerve which leads to facial palsy.

#### *Description*

The facial nerve emerges from stylomastoid foramen, passes downwards and forward 2.5 cm, deep to middle of anterior border of mastoid process about one cm before the nerve pierces the postero-medial surface of the parotid gland. In the gland the nerve runs forwards for another 1 cm superficial to retromandibular vein and external carotid artery. Before piercing the gland the nerve gives three branches: 1) Posterior auricular nerve 2) Nerve to posterior belly of digastrics 3) Nerve to stylohyoid muscle. In the gland the facial nerve trunk divides into

two divisions: 1) Temparofacial division 2) Cervicofacial division. The temparofacial division gives two branches: a) Temporal branch b) Zygomatic branch; the cervicofacial division gives three branches a.buccal branch b.marginal mandibular branch c) Cervical branch. The arrangement of terminal branches in face is known as pes anserinus because all the branches distributed widely like a foot of a goose on the side of the face and they are interconnected. The temporal branch supplies auricularis anterior, auricularis superior, upper part of orbicularis oculi, frontalis and corrugator supercilli. The zygomatic branch supplies the lower part of orbicularis oculi. The buccal branch divides into superficial branch and deep branch. The superficial branch supplies the procerus and the deep branch divides into upper and lower buccal branch. The upper branch supplies zygomaticus major, zygomaticus minor, levator anguli oris, levator labii superioris, levator labii alaeque nasi and muscles of nose. The lower buccal branch supplies buccinators and orbicularis oris. The marginal mandibular nerve supplies risorius, depressor anguli oris, depressor labii inferioris and mentalis. The cervical branch supplies the platysma muscle.

**METHODS**

**Materials**

The present work consists of 50 foetal parotid glands from 25 dead fetuses (15 male+10 female) and 8 glands from 4 adult cadavers (3 males+1 female). The fetuses are fixed in embalming solution after obtaining consent from the HOD’s of department of gynaecology and department of anatomy. They are labeled from 1 to 25 numbers sex, crown rump length of the fetuses recorded. The adults’ bodies were obtained from the routine dissection for first MBBS students.

The study was approved by the ethical committee.

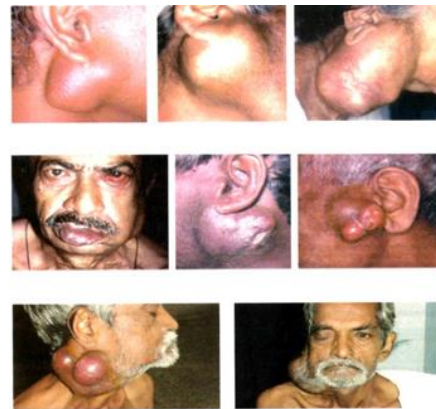**Dissection procedure**

A midline incision given from the hairline of the scalp to the symphysis menti and the skin flap reflected laterally to the auricle, the anterior layer of the capsule removed and the gland exposed. The superficial lobe separated and reflected laterally to expose the branches and the trunk of the facial nerve. The branching pattern of the specimens were observed, variations are noted and recorded, photographs taken for study.

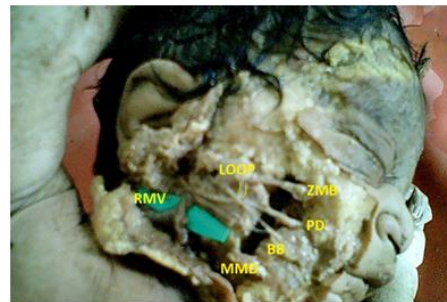
**RESULTS**

In the present study of 50 foetal parotid glands the facial nerves of 44 specimens show 2 main divisions and are 88%. The temparofacial division given 2 branches and cervicofacial division given 3 branches. In adult parotid glands the facial nerve given 2 divisions and it is 100%. It is observed in all foetal and adult facial nerves the buccal branch given 2 branches above and below the parotid

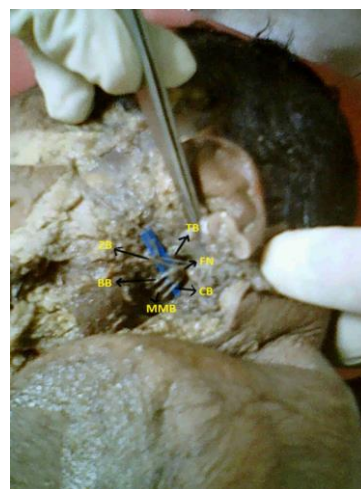duct. It is noted that in 8 foetal glands (3, 7, 8 and 15) the facial nerve directly given 5 terminal branches from the trunk without divisions. In the study 56% foetal specimens show straight branching pattern without loops, the 12% specimens are having loops between zygomatic and buccal branches on both sides. 32% of foetal specimens are having loops between the upper and lower buccal branches whereas 100% of adult facial nerve showing loop between upper buccal and lower buccal branches.



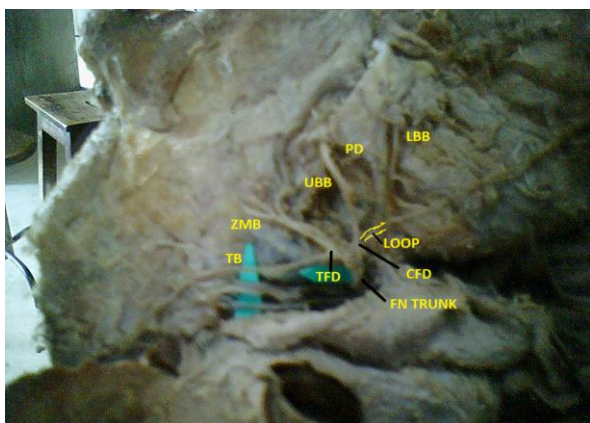
**Figure 1: Parotid tumour in patient with facial palsy.**



**Figure 2: Foetal specimen showing loop between zygomatic and buccal branch.**



**Figure 3: Foetal specimaen showing five terminal branches from the trunk.**



**Figure 4: Adult specimen showing loop between upper buccal and lower buccal branches.**

TFD: Temporofacial division; CFD: Cervicofacial division; TB: Temporal branch; ZMB: Zygomatic branch; UBB: Upper buccal branch; LBB: Lower buccal branch; PD: Parotid duct; MMB: Marginal mandibular branch; RMV: Retro mandibular vein

## DISCUSSION

Ketz and Catalano 1987 described the terminal branch arrangements and variations sub-divided into 5 groups:

A) 24% shows - straight branching pattern.

The present study showing 56%.

B) 14% shows - loop communication between zygomatic and buccal branches.

The present study giving 12%.

C) 44% involving loops between upper buccal and lower buccal branches.

The study showing - 32% in foetal specimens.

100% in adult specimens.

D) 14% had multiple communications between the divisions and trunk or complex pattern.

The present study observed no multiple communications between divisions and branches or complex pattern - 0%.

E) 3% had connections between the two main divisions.

The present study-not showing any communication between the divisions i.e., 0%.

## CONCLUSIONS

The study varied with the statement of Ketz and Catalano. The study shows a wide range of variations. In

foetal specimens the facial nerve divides into two main divisions in 88% of glands and all adult specimens the facial nerve divided into two main divisions. In foetal specimens 12% cases the facial nerve directly given 5 terminal branches.

*Funding: No funding sources*

*Conflict of interest: None declared*

*Ethical approval: The study was approved by the institutional ethics committee*

## REFERENCES

1. Luschka H. The study of parotid gland, emphasis on topographic anatomy of parotid area and the manner of facial nerve in the substance, 1862. In: Richard A. Davis, Rarry R.J. Anson, John M. Budinger, Leroy L.E. Kurth, eds. Human Anatomy in Consideration of the Needs of Practical Medicine. 1st ed. Germany: Hubert von Luschka en science; 1956: 183-185.
2. Schaefer EA, Symington J, Bryce TH. The course of facial nerve and the course in the gland, 1867. In: Richard A. Davis, Rarry R.J. Anson, John M. Budinger and Leroy L.E. Kurth, Quain's Anatomie, eds. 11th ed. London: Longmans, Green, and Co.; 1956.
3. McWhorter. The isthmus situated centrally, being embedded above and below by two primary divisions of facial nerve. In: 1917: 149, Available at: <http://scans.library.utoronto.ca/pdf/5/30/anatomicalrecord12bard/anatomicalrecord12bard.pdf>.
4. Piersol. The two primary sub-divisions of facial nerve were referred to as giving of innumerable branches which are sub-divided in the gland, 1930. In: Richard A. Davis, Rarry R.J. Anson, John M. Budinger, Leroy L.E. Kurth, eds. Applied anatomy. 1st ed. US: Education Nest; 1956.
5. Nico Tortorella Archives. The character of ramification of peripheral branches of facial nerve the plexiform arrangement of tempero facial branches formed by dichotic and anastomotic divisions, but the cervicofacial branch was never plexiform in character, Tortella, 1930. Available at: [www.slashfilm.com](http://www.slashfilm.com).
6. Nico Tortorella Archives. The variations of formation of plexes of facial nerve, Tortella, 1947. Available at: [www.slashfilm.com](http://www.slashfilm.com).
7. Bobin VV. Distribution of facial nerve and its relation to the gland were found asymmetrical in 20% cases. This frequency increases with age, 1964. Available at: [www.mag-inc.com](http://www.mag-inc.com).
8. Gasser. The intimate relation of various branches of facial nerve to the gland, 1970. Available at: [site.hmc.org.qa/.../10-14\\_Facial\\_Nerve\\_Disorders\\_and\\_Surgery.pdf](http://site.hmc.org.qa/.../10-14_Facial_Nerve_Disorders_and_Surgery.pdf).
9. Nergos Procter. The branches form a plexus known as parotid plexus which distributes facial

musculature, 1982. Available at:  
[www.medicinafacial.com](http://www.medicinafacial.com).

10. Katz and Catalano. The facial nerve arrangement, variations have been divided into 5 groups. As discussed in the text, 1987. Available at:  
[https://www.jstage.jst.go.jp/article/ofaj1936/70/6/70\\_295/\\_pdf](https://www.jstage.jst.go.jp/article/ofaj1936/70/6/70_295/_pdf).

DOI: 10.5455/2320-6012.ijrms20150216

**Cite this article as:** Geetha Devi KVN, Toleti S. A study of variations in the branching pattern of facial nerve in the face. *Int J Res Med Sci* 2015;3:466-9.