

DOI: <http://dx.doi.org/10.18203/2320-1770.ijrcog20181474>

Case Report

Spontaneous umbilical cord hematoma causing still birth: a case report in Madagascar

Lyn Z. A. Rabetsimamanga¹, Hary F. Rabarikoto^{2*},
Eddie B. Rekoronirina¹, Hery R. Andrianampanalinarivo³

¹Department of Obstetrics and Gynecology, Pavillon Sainte Fleur, University Hospital Center JRA, Antananarivo, Madagascar

²Department of Obstetrics and Gynecology, Military Hospital Antsiranana, Madagascar

³Department of Obstetrics and Gynecology, University Hospital Center GOB, Antananarivo, Madagascar

Received: 03 April 2018

Accepted: 07 April 2018

***Correspondence:**

Dr. Hary F. Rabarikoto,

E-mail: hbararikoto@yahoo.com

Copyright: © the author(s), publisher and licensee Medip Academy. This is an open-access article distributed under the terms of the Creative Commons Attribution Non-Commercial License, which permits unrestricted non-commercial use, distribution, and reproduction in any medium, provided the original work is properly cited.

ABSTRACT

Spontaneous umbilical cord hematoma is uncommon complication during delivery. It is responsible for severe fetal distress or death. We report a case of a 28 year-old primigravida Malagasy woman at the 37th weeks of gestation. She was admitted in the delivery room for beat oscillating on the fetal heart monitoring at the beginning of labour. Cesarean section was indicated for acute fetal distress in monitoring at dilation 5cm of the cervix traduced by some decelerations. But she gives birth to a still born female fetus by vaginal way short time after. A 5,5 cm hematoma was discovered on umbilical cord. This still birth may be due to anoxia during acute compression of the umbilical vessels by the hematoma. So, placental and cord examinations in cases of unexplained fetal hypoxia and stillbirth are very important.

Keywords: Madagascar, Umbilical cord, Spontaneous hematoma, Still birth

INTRODUCTION

Spontaneous umbilical cord hematoma is a rare complication during delivery. It is occurred around 1 per 5500 to 1 per 11000 births.¹⁻³

It is also an unpreventable event that an obstetrician may have to manage. It is responsible for death or severe fetal distress.^{1,4} Still births is an important cause for major concern for both the obstetrician and expectant mother. We must systematically seek an etiology even if in vast majority of cases, the cause of the still birth is unexplained. Spontaneous umbilical cord hematoma is one of this cause and it may be diagnosed on examination of placenta and cord after birth. We aimed to report the

first case of umbilical cord hematoma causing still birth in our practice.

CASE REPORT

A 28 year-old primigravida Malagasy woman was admitted to delivery room for surveillance of the fetal heart rate at 37 th gestational week at the beginning of labour and for.

On admission, the fetal heart monitoring beat was oscillating, and was reactive a few indeed (Figure 1). She had regular antenatal check-ups. Her pregnancy did not have any particular incident and fetal movements were always normal. There was no history of any invasive fetal

procedure, nor trauma during pregnancy. There was no fever during the labour, nor other pathology.

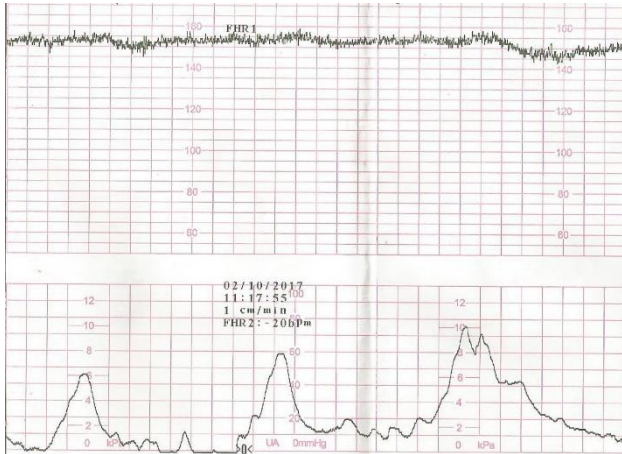


Figure 1: Beat oscillating on fetal heart monitoring.

Moreover, there was normalization of cardiocograph after repositioning of the patient and any abnormalities was observed during 6 hours.

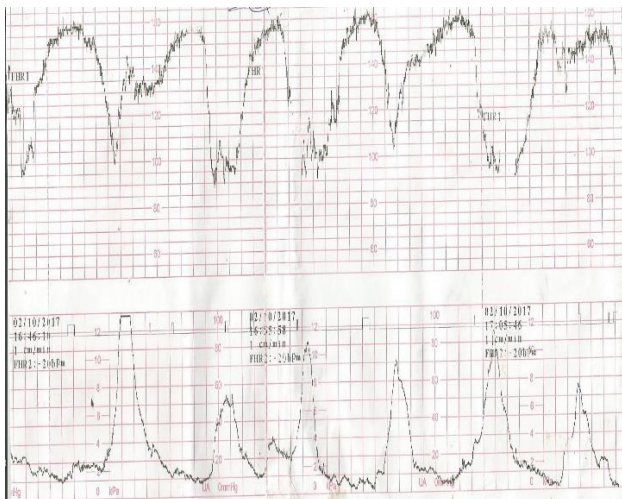

Figure 2: Decelerations on fetal monitoring.

At cervical dilation at 5 cm and vertex engaged, there were a number of decelerations on fetal monitoring (Figure 2). Cesarean section was indicated for acute fetal distress. But vaginal birth with suction cup obstetrical was performed in cesarean room few minutes after this indication. This is because that the patient had an imperious need to push and complete the dilation before incision. A still born female fetus weighing 2660g with no visible external anomalies was delivered. In the investigation of this still birth, examination of the placenta and cord has been emphasized. Placenta was in healthy appearances, with central cord insertion. The placenta weighed 580g and cord measured 52cm. The umbilical cord was in aubergine color in 5.5 cm (Figure 3). A fetal autopsy and histology exams were advised but not performed as family refused.

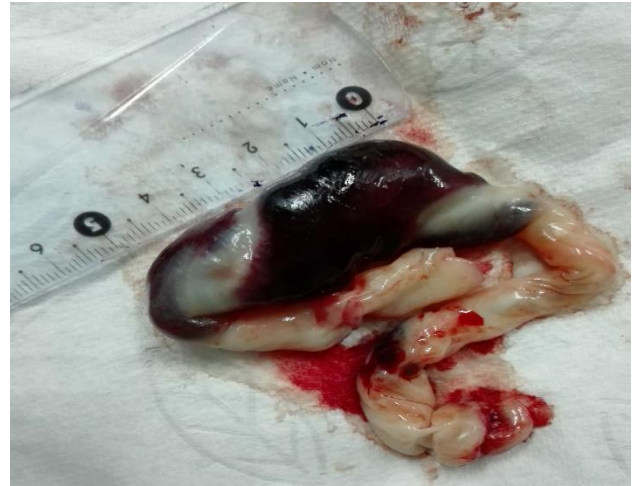

Figure 3: Aspect of umbilical cord hematoma in 5.5 cm immediately after birth.

DISCUSSION

In many cases of spontaneous umbilical hematoma the causes remain unknown. Often, it is due to rupture of the umbilical vein and rarely of the umbilical arteries.^{1,5,6} In the literature, many risk factors were identified: infections, post-maturity, morphologic anomalies, alterations of the vessel walls, prolapses, shortness or twisting and traction of the cord, intravascular fetal blood transfusions and fetal diagnostic procedure.^{3,6-8} There were no risk factor found in the case that we report. Without histology, alteration or not of vessel walls was not proved.

In this case, umbilical hematoma was probably developed in the beginning of the labour when the fetal monitoring tracing detected a micro-oscillating rhythm. This heart fetal rate did not seem worrying; as he had normalized after changing the position of the patient. But after a bibliography inspired by this still birth, the monitoring could have pointed us to an acute pathology of umbilical cord. A fetal monitoring alterations can make possible to anticipate the deterioration of the fetal condition indeed. Abnormalities of heart fetal rate, non-discernable oscillation and loss of beat to beat variation may point to an umbilical cord hematoma.^{6,9} Towers CV et al reported in three cases a decreased variability with an absence of accelerations.² Little variability in fetal heart rate may indicate immediate delivery to prevent intrauterine death. The scalp lactate dosage could have helped us make a caesarean decision early, but it is not available in delivery room in our condition of work.

Usually an ultrasound exam is not performed systematically in the labour room for abnormalities of heart fetal rate; except in case of suspicion of placental abruption or for a presentation check. Ultrasound using or not color Doppler imaging makes antenatal diagnosis possible.^{5,10}

Even if emergency Caesarean section is performed, the outcome of umbilical cord hematomas is poor in half of the cases. Many newborn developed hypoxic ischemic encephalopathy and died in the neonatal period.^{6,7} In the case that we report, still birth may be due to anoxia during acute compression of the umbilical vessels by the hematoma.

CONCLUSION

Still birth is one of the many challenges that an obstetrician has to face. Spontaneous umbilical cord hematoma is one of the uncommon etiology of this. So, placental and cord examinations in cases of unexplained fetal hypoxia and stillbirth are very important.

Funding: No funding sources

Conflict of interest: None declared

Ethical approval: Not required

REFERENCES

1. Sizun J, Soupre D, Broussine L, Girou JD, Piriou P, Ventrillon E al. Spontaneous umbilical cord hematoma, a rare cause of acute fetal distress. *Arch Pediatr.* 1995;2(12):1182-3.
2. Towers CV, Juratsch CE, Garite TJ. The fetal heart monitor tracing in pregnancies complicated by a spontaneous umbilical cord hematoma. *J Perinatol* 2009;29(7):517-20.
3. Arora PK, Mohandas S, Mc Andrew S, Karody V. Spontaneous Umbilical Cord Hematoma. *J Pediatr.* 2017;184:233.
4. Tonni G, Bonasoni MP, De Felice C, Rossi A, Tonni S. Histopathological findings in spontaneous hematoma of the umbilical cord: severe hypoxic-ischemic encephalopathy in a term survived newborn. *Am J Forensic Med Pathol* 2015;36(4):254-6.
5. Feng D, He W. Spontaneous umbilical artery haematoma diagnosed in the third trimester: a case report. *J Obstet Gynaecol.* 2018;31:1-2.
6. Abraham A, Rathore S, Gupta M, Benjamin SJ. Umbilical Cord Haematoma Causing Still Birth- A Case Report. *J Clin Diagn Res.* 2015;9(12):QD01-2.
7. Gualandri G, Rivasi F, Santunione AL, Silingardi E. Spontaneous umbilical cord hematoma: an unusual cause of fetal mortality: a report of 3 cases and review of the literature. *Am J Forensic Med Pathol.* 2008;29(2):185-90.
8. Keckstein G, Tschürtz S, Schneider V, Hütter W, Terinde R, Jonatha WD. Umbilical cord haematoma as a complication of intrauterine intravascular blood transfusion. *Prenat Diagn.* 1990;10(1):59-65.
9. S. Ballas, S. Gitstein and J. Kharasch. Fetal heart rate variation with umbilical haematoma. *Postgraduate Med J.* 1985;61:753-5.
10. Sutro WH, Tuck SM, Loesevitz A, Novotny PL, Archbald F, Irwin GAL. Prenatal Observation of Umbilical Cord Hematoma. *AJR.* 1984;142:801-2.

Cite this article as: Rabetsimamanga LZA, Rabarikoto HF, Rekoronirina EB, Andrianampanalinarivo HR. Spontaneous umbilical cord hematoma causing still birth: a case report in Madagascar. *Int J Reprod Contracept Obstet Gynecol* 2018;7:2031-3.