

Case Report

Situs inversus

Shilpa Ramling*, K. R. Dakshayani

Department of of Anatomy, Mysore Medical College & Research Institute, Mysore, Karnataka, India

Received: 20 October 2014

Accepted: 26 October 2014

***Correspondence:**

Dr. Shilpa Ramling,

E-mail: shilpa_ramling@yahoo.co.in

Copyright: © the author(s), publisher and licensee Medip Academy. This is an open-access article distributed under the terms of the Creative Commons Attribution Non-Commercial License, which permits unrestricted non-commercial use, distribution, and reproduction in any medium, provided the original work is properly cited.

ABSTRACT

Situs inversus is a rare condition with a genetic predisposition, where in organs are transposed from their normal location to the opposite side of the body with an incidence of 1 in 10000 live births. If Situs Inversus is associated with other congenital anomalies the survival rate is low. So prenatal diagnosis is essential to detect any associated anomalies. During routine fetal autopsies conducted in the department of anatomy, Mysore medical college, Mysore, a rare interesting case of still born baby with gestational age of 20 weeks was observed. Autopsy findings of external examination revealed kyphosis in thoracic region. Thoracotomy revealed heart on the right side (dextrocardia). Laparotomy revealed that the left lobe of liver was bigger than the right. The gall bladder was present on the visceral surface of the left lobe of liver, stomach was on right side, duodenum on left side, pancreas and spleen were on the right side. There was agenesis of right kidney, right ureter and both suprarenal glands. All the above findings correlate with the condition situs inversus. Situs inversus is a rare condition with a genetic predisposition, it's etiology lies in the mutation of chromosome no 12, which is critical for recognition of right sidedness.^{1,2} Even though there is transposition of organs in situs inversus, the survival rate is good but if situs inversus is associated with other congenital anomalies the survival rate is low. So prenatal diagnosis is essential to detect any associated anomalies to bring down mortality rate.

Keywords: Situs inversus, Fetal autopsy, Dextrocardia, Agenesis, Anomalies

INTRODUCTION

Situs inversus is a rare condition with a genetic predisposition, it's etiology lies in the mutation of chromosome no 12, which is critical for recognition of right sidedness. It's incidence being 1 in 10000 live births.¹ Developmentally defect lies in the nodal movement of cilia present on the primitive node of the developing notochord.

CASE REPORT

A 23 year old multigravida delivered preterm female anomalous baby (20 weeks) with placenta and membranes weighing 800 gm by induction at Cheluvamba Hospital, Mysore Medical College, Mysore.

There was no history of consanguinous marriage, exposure to teratogens during pregnancy and anomalous baby in the family. Autopsy was conducted in the department of anatomy, Mysore medical college and research institute, Mysore which revealed following findings:

External examination revealed kyphosis in thoracic region, low set ears, receding chin, umbilical cord showing single umbilical artery, clubbed hand & foot External genitalia that of female, Imperforate anus.

Thoracotomy

On autopsy of thoracic cavity, it revealed dextrocardia (apex of heart on the right side), as shown in the Figure 1,

right lung pushed posteriorly and thoraco-abdominal diaphragm was complete.

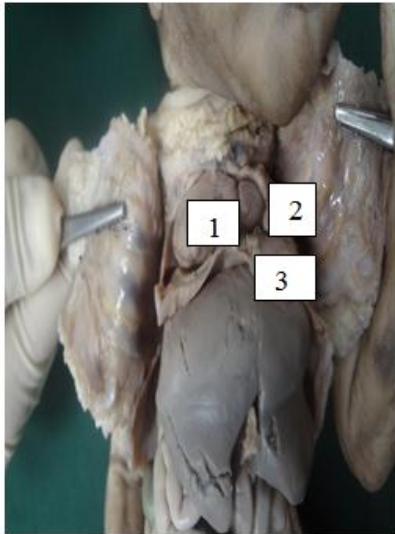


Figure 1: Thoracotomy: 1) Dextrocardia 2) Left lung 3) Thoracoabdominal diaphragm.

Laparotomy

Stomach was present in the right hypochondriac region, duodenum on left side, liver was covering right and left hypochondriac region completely, wherein the left lobe was larger than the right. Spleen and pancreas were seen on the right side under the cover of liver. Coils of small intestine were in the midline, colon, caecum and appendix were seen in the normal anatomical position.

There was agenesis of right kidney, ureter and both the suprarenal glands, left kidney was lobulated with normal ureter, uterus, fallopian tube and both ovaries were in normal anatomical position. Figure 2, 3, and 4 show above features.

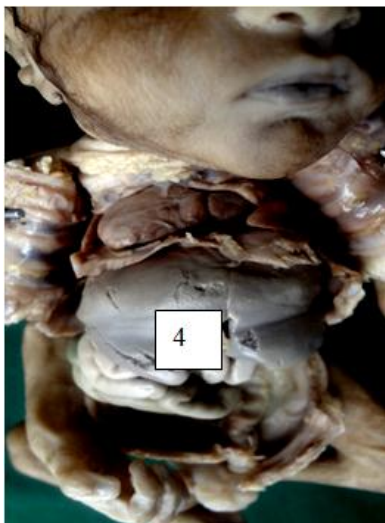

Figure 2: Laparotomy: 4) Liver.

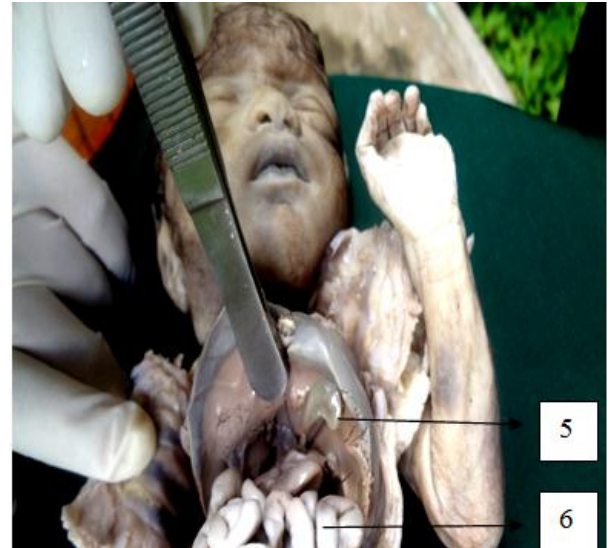

Figure 3: Laparotomy: 5) Gall bladder 6) Coils of intestine.

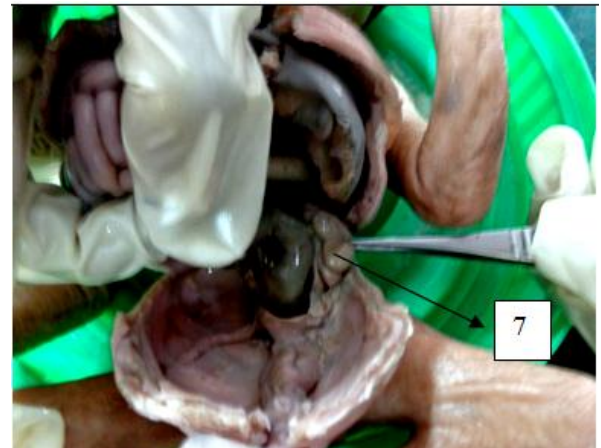

Figure 4: Laparotomy: 7) Lobulated kidney on left side.

DISCUSSION

Situs inversus is a short form of Latin phrase “situs inversus viscerum” which means transposition of internal organs from its normal anatomical position.^{1,3} The normal anatomical position of internal organs is termed as Situs solitus¹.

In 1643, Marco Severino was first to describe situs inversus.¹⁻³ It is the mirror image of situs solitus. If situs (position) cannot be determined then it is known as situs ambiguous.³

Classification¹

- 1) Situs inversus: a) Situs inversus with dextrocardia, b) Situs inversus with levocardia.
- 2) Situs ambiguous: a) Asplenic syndrome/right isomerism, b) Polysplenic Syndrome/left isomerism.

Associated syndromes:^{3,4,6}

- 1) Polysplenia
- 2) Asplenia
- 3) Renal agenesis
- 4) Pancreatic fibrosis
- 5) Kartgeners syndrome

Akimou Yosini et al. in 1962 reported in his autopsy case, bilateral agenesis of kidney with situs inversus.⁴

In 2000 Huang SC, et al. observed varying spectrum of renal dysplasia and pancreatic fibrosis with situs inversus.⁶

In 2012 Sharada Sharma et al., in her case, observed reversal of all the organs with superior vena cava on left side but normal in formation.

Embryological cause

Primitive streak, which appears during 3rd week of gestation decides right-left axis of embryo. Primitive node appears on the cranial part of streak, which induces nodal expression lefty-2, this beats the cilia present on node towards left of embryonic disc upto lateral plate mesoderm. In the floor of neural tube on the left side, a gene by name lefty-1 acts as barrier preventing the ciliary movement towards right.⁵

CONCLUSION

Even though situs inversus is a rare condition, 1:10000 live births, awareness of it is necessary before and after birth.^{1,3}

Before birth situs may be associated with other congenital anomalies. In the present case situs inversus is associated with renal agenesis which may result in still birth, so prenatal diagnosis using latest radiological intervention may prevent unwanted morbidity and mortality of baby.^{4,5}

After birth surgeons and radiologists should be aware of situs inversus to avoid surgical mishaps. Situs inversus individuals may come with atypical history like, acute cholecystitis, patient may complaint pain in left hypochondriac region instead of right, in such cases

surgeon must approach surgically on the left hypochondriac region.⁶

Situs inversus may complicate organ transplantation, like in heart transplantation of situs inversus patients, usually donors will be of normal donors (situs solitus). In this case along with heart, great vessels should also be reattached to the already existing vessels because orientation of the structures is difficult in situs inversus patients.⁷

ACKNOWLEDGEMENTS

We are thankful to the teaching & non-teaching staff of department of anatomy & forensic medicine, Mysore Medical College & Research Institute, Mysore.

Funding: No funding sources

Conflict of interest: None declared

Ethical approval: Not required

REFERENCES

1. Annamaria Wilhelm et al. Situs inversus imaging, 2013. Available at: <http://emedicine.medscape.com/article/413679-overview>. Accessed 7 October 2013.
2. Yokoyama T, Copeland NG, Jenkins NA, Montgomery CA, Elder FF, Overbeek PA. Reversal of left-right asymmetry: a situs inversus mutation. *Science*. 1993;260(5108):679-82.
3. Sharada Sharma, Chaitanya KK, Suseelamma D. Situs inversus: an anatomical study. *Anat Physiol*. 2012 Dec;2(5):2-3.
4. Akimou Yosini, Sensaku Yosikawa, Susumu Tkrai. An autopsy case of B/L renal agenesis with situs inversus viscerum. *Pathol Int*. 1962;12(4):419-24.
5. Datta AK. Situs inversus. In: Datta AK, eds. *Essentials of Human Embryology-Human Genetics*. 2nd ed. India. Current Distributors; 1991: 93.
6. Huang SC, Chen WJ. Renal dysplasia & situs inversus totalis: an autopsy report. *Chang Gung Med J*. 2000 Jan;23(1):43-7.
7. Marta MJ, Falcão LM, Saavedra JA, Ravara L. A case of complete situs inversus (language lateralisation). *Rev Port Cardiol*. 2003 Jan;22(1):91-104.

DOI: 10.5455/2320-6012.ijrms20150156

Cite this article as: Ramling S, Dakshayani KR. Situs inversus. *Int J Res Med Sci* 2015;3:307-9.