

DOI: <http://dx.doi.org/10.18203/2320-1770.ijrcog20163466>

Case Report

A novel treatment option in management of tubal ectopic pregnancy after in vitro fertilization with embryo transfer by trans-vaginal aspiration of gestational sac: a case report

Vineet Mishra*, Priyankur Roy, Sumesh Choudhary, Rohina Aggarwal,
Khushali Gandhi, Suwa Ram Saini

Department of Obstetrics and Gynaecology, Institute of Kidney Disease and Research Centre, Civil Hospital Campus, Ahmedabad, Gujarat, India

Received: 22 August 2016

Accepted: 17 September 2016

*Correspondence:

Dr. Vineet Mishra,

E-mail: vineet.mishra.ikdrc@gmail.com

Copyright: © the author(s), publisher and licensee Medip Academy. This is an open-access article distributed under the terms of the Creative Commons Attribution Non-Commercial License, which permits unrestricted non-commercial use, distribution, and reproduction in any medium, provided the original work is properly cited.

ABSTRACT

Majority of the reports suggest that the frequency of ectopic pregnancies have grown in the last 30 years, especially in patients conceived through artificial reproductive techniques (ART). Ectopic pregnancy occurs mostly in the fallopian tubes (90%), and the most common region is the ampula. Its prompt diagnosis and appropriate management is important in preventing severe morbidity and mortality. In a select patient population, most of the unruptured, live ectopic pregnancies can be successfully managed without surgical intervention using trans-vaginal ultrasound guided aspiration and instillation of local injection KCl or administration of systemic injection Methotrexate. We report a case of tubal ectopic pregnancy in a patient who underwent IVF-ET and was successfully treated conservatively by ectopic aspiration and instillation of injection KCl locally in the ectopic site.

Keywords: ART, IVF-ET, Ectopic pregnancy

INTRODUCTION

The implantation of a trophoblast outside the uterine cavity occurs in 1.5% to 2% of all pregnancies. In vitro fertilization (IVF) with embryo transfer (ET) has been reported to result in a higher rate of ectopic pregnancies than spontaneous pregnancies. Approximately 2.1-8.6% of all clinical pregnancies after IVF-ET have been reported to be ectopic compared with an ectopic pregnancy rate of 2% after natural conception.¹⁻³ Several hypotheses have been advocated to explain this difference, including different hormonal milieu, technical aspects of IVF procedures, and the estimated embryo implantation potential.²

Nonetheless, several studies have assessed the risk factors for ectopic pregnancy after IVF-ET with a view of

improving IVF-ET outcomes and reducing ectopic pregnancy rates.

Theoretically, blastocyst ET, which is more similar to the natural cycle than cleavage-stage ET, has a higher implantation potential.⁴ Previous studies have shown that decreased uterine contractility during the later luteal phase and the larger sizes of blastocysts would prevent the retrograde passage of embryos, which imply that blastocyst ET reduces the rate of ectopic pregnancy compared with cleavage-stage ET.^{5,6} These results support Chang and Suh's observation that transfer of three or more embryos with higher estimated embryo implantation potential was reported to be associated with an increased risk of ectopic pregnancy.² Moreover, two studies suggested that the rate of ectopic pregnancy was not reduced after blastocyst ET compared with cleavage-stage ET.⁷

We report a case of tubal ectopic pregnancy that occurred after IVF-ET in a woman with no predisposing factors for ectopic implantation. This case is unique because of its novel mode of management. The patient was managed by Ovarian Ectopic Aspiration and instillation of Inj. KCl. She is now on follow-up with non-pregnant β -HCG levels.

CASE REPORT

A 35 year old nulligravid woman presented to our fertility centre (Institute of kidney diseases and research, Ahmedabad) for evaluation of primary infertility. She was married for 16 years and led an active married life. The patient had undergone ovulation induction (OI) with clomiphene citrate and intrauterine insemination (IUI) several times previously.

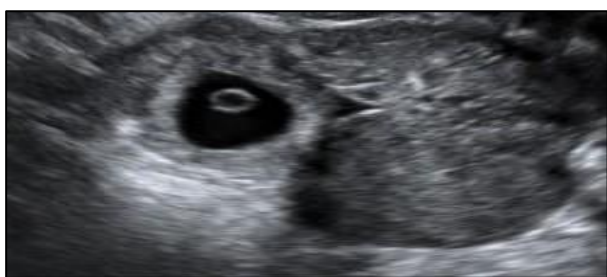

Figure 1: USG image showing the foetus inside the right fallopian tube.

She was investigated for her infertility status. She underwent hormonal analysis which was found to be normal. She also underwent office hysteroscopy which revealed that the uterine cavity and bilateral ostia were normal. Her husband's semen analysis revealed normal sperm count with normal motility and morphology. She was advised IVF in view of previous failed IUI attempts.

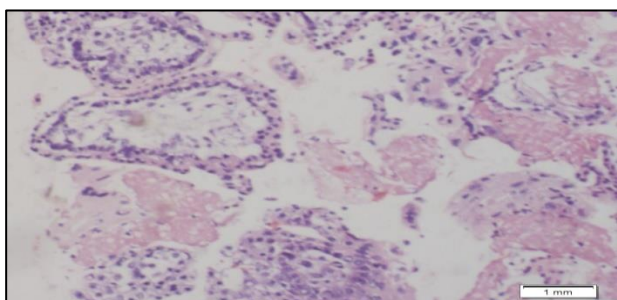


Figure 2: HPE showing immature chorionic villi – s/o ectopic pregnancy.

The patient underwent antagonist protocol. Recombinant Follicle Stimulating Hormone was given (total units 3000 IU). Antagonist protocol based on ultrasonographic findings (14 mm sized follicles) - 0.25 mg of Inj. Cetrorelix was given for 4 days. Trigger was given with recombinant human chorionic gonadotropin (HCG) 500 mcg on day 11. Oocyte retrieval was done under short

general anaesthesia on day 13 of cycle. Six oocytes were retrieved.

Out of the six oocytes, all six fertilized into grade - a embryos. Day 3 embryo transfer (ET) post ovum-pickup was done (day 16 of cycle). Embryos were placed 1 cm away from fundus under ultrasound guidance with embryo transfer catheter. Micronized progesterone and estradiol were initiated following the transfer.

Serum β -HCG on day 14 after ET was 135 mIU/ml followed by 304 mIU/ml on day 18. She was considered to be a case of failed ET and advised to come on the 2nd day of her next cycle. Her trans-vaginal sonography (TVS) on the 2nd day of the next cycle revealed bilateral stimulated ovary with endometrial thickness of 12 mm and minimal free fluid in the POD. She continued to bleed for the next 10 days and a repeat trans-vaginal sonography (TVS) was performed; which revealed a 2.4 x 2.4 cm left adnexal ectopic with foetal pole and CRL measuring 6 weeks and 6 days; cardiac activity was present. There was no free fluid in the pelvis. Repeat serum β -HCG on the same day was raised to 11093.96 mIU/ml. The patient was diagnosed as a case of unruptured right tubal pregnancy.

Thorough counseling of the couple regarding different treatment options was done. The couple opted for conservative management. She was admitted and further planned for Ectopic Aspiration. She underwent Ectopic Aspiration and instillation of injection KCl into the ectopic site under USG guidance and the tissue obtained was sent for histopathological examination. The HPE report obtained was in favor of ectopic pregnancy. She was discharged from the hospital with advice to follow-up with weekly β -HCG values till non-pregnant levels.

On post-aspiration day 6, her repeat β -HCG levels dropped to 4490 mIU/ml. Repeat serum β -HCG level on day 13 after ovarian ectopic aspiration was found to be 3564 mIU/ml. Her repeat β -HCG levels on post-aspiration Day 20 further dropped to 2112 mIU/ml. A decreasing trend in the values were noted and was asked to come on regular follow-up with serum β -HCG levels repeated every 15 days. Her repeat serum β -HCG levels 15 days later was 113 mIU/ml and at present it is in non-pregnant level.

DISCUSSION

The first pregnancy obtained with IVF by Steptoe et al. was ectopic, in a patient with history of tubal factor infertility.⁸ Theories regarding the genesis of spontaneous ectopic pregnancy are well known. Damage to the endosalpinx produced by sexually transmitted infections, distortion of pelvic anatomy caused by disease like endometriosis or by adhesions after previous surgical interventions, surgery performed in the fallopian tubes, mullerian malformations, hormone concentration imbalance during the menstrual cycle, late ovulation,

history of a previous ectopic pregnancy.² Rates of ectopic pregnancy following IVF-ET have been reduced by restricting the number of embryos transferred, avoiding deep fundal transfer and TET, injecting a smaller volume of fluid during ET, and transferring frozen-thawed embryos.^{1,2,9,10} In general, there has been a belief that higher progesterone concentrations in the luteal phase may reduce uterine contractility during fresh ET, which may prevent the embryo from migrating into the fallopian tubes.¹¹ However, a growing number of studies are now available to shed some light on lower ectopic pregnancy rate following frozen-thawed ET.

There is some evidence that transferring blastocysts that are ready to implant instead of earlier embryos may also reduce the incidence. Sometimes, however, despite the best-laid plans, ectopic pregnancies do occur.¹² In a selected patient population, most of the unruptured, live ectopic pregnancies can be successfully managed without surgical intervention using ultrasound guided aspiration and systemic injection with methotrexate or intrasac instillation of KCl or methotrexate.

Andres MP et al. have demonstrated the successful management of ectopic pregnancies with the use of ultrasound guided injection of fetotoxic substances like methotrexate into the intraamniotic and/or intrachorionic sac.¹² Dadhwal et al. reported successful management of live tubal ectopic pregnancy with local KCl and systemic methotrexate administration.¹³ Verma and Jacques reported three cases that were treated using ultrasound-guided intrasac KCl injection and systemic methotrexate. In all three cases, the resolution of ectopic pregnancy was achieved, and surgery was avoided.¹⁴

CONCLUSION

It is important for clinicians and patients to recognize the possibility of developing an ectopic pregnancy after embryo transfer in an IVF programme. Our case demonstrates that close follow-up of abnormally rising β -HCG levels, clinical suspicion, and ultrasonographic appearance of an adnexal mass can lead to the early diagnosis and its successful conservative management.

Funding: No funding sources

Conflict of interest: None declared

Ethical approval: Not required

REFERENCES

1. Clayton HB, Schieve LA, Peterson HB, Jamieson DJ, Reynolds MA, Wright VC. Ectopic pregnancy

- risk with assisted reproductive technology procedures. *Obstet Gynecol.* 2006;107:595-604.
2. Chang HJ, Suh CS. Ectopic pregnancy after assisted reproductive technology: what are the risk factors? *Curr Opin Obstet Gynecol.* 2010;22:202-7.
3. Nazari A, Askari HA, Check JH, O'Shaughnessy A. Embryo transfer technique as a cause of ectopic pregnancy in in vitro fertilization. *Fertil Steril.* 1993;60:919-21.
4. Mains L, Van Voorhis BJ. Optimizing the technique of embryo transfer. *Fertil Steril.* 2010;94:785-90.
5. Fanchin R, Ayoubi JM, Righini C, Olivennes F, Schonauer LM, Frydman R. Uterine contractility decreases at the time of blastocyst transfers. *Hum Reprod.* 2001;16:1115-9.
6. Schoolcraft WB, Surrey ES, Gardner DK. Embryo transfer: techniques and variables affecting success. *Fertil Steril.* 2001;76:863-70.
7. Milki AA, Jun SH. Ectopic pregnancy rates with day 3 versus day 5 embryo transfer: a retrospective analysis. *BMC Pregnancy Childbirth.* 2003;3:7.
8. Steptoe PC, Edwards RG. Reimplantation of a human embryo with subsequent tubal pregnancy. *Lancet.* 1976;1:880-2.
9. Pope CS, Cook EK, Army M, Novak A, Grow DR. Influence of embryo transfer depth on in vitro fertilization and embryo transfer outcomes. *Fertil Steril.* 2004;81:51-8.
10. Ishihara O, Kuwahara A, Saitoh H. Frozen-thawed blastocyst transfer reduces ectopic pregnancy risk: an analysis of single embryo transfer cycles in Japan. *Fertil Steril.* 2011;95:1966-9.
11. Shapiro BS, Daneshmand ST, De Leon L, Garner FC, Aguirre M, Hudson C. Frozen-thawed embryo transfer is associated with a significantly reduced incidence of ectopic pregnancy. *Fertil Steril.* 2012;98:1490-4.
12. Andres MP, Campillos, Lapresta, Lahoz, Crespo R, Tobajas J. Management of ectopic pregnancies with poor prognosis through USG guided intrasacular injection of methotrexate, series of 14 cases. *Arch Gynecol Obstet.* 2012;285:529-33.
13. Dadhwal V, Deka D, Ghosh B. Successful management of live ectopic pregnancy with high beta-hCG titres by ultrasound-guided potassium chloride injection and systemic methotrexate. *Arch Gynecol Obstet.* 2009;280:799-801.
14. Verma U, Jacques E. Conservative management of live tubal pregnancies by ultrasound guided potassium chloride injection and systemic methotrexate treatment. *J Clin Ultrasound.* 2005;33:460-3.

Cite this article as: Mishra V, Roy P, Choudhary S, Aggarwal R, Gandhi K, Saini SR. A novel treatment option in management of tubal ectopic pregnancy after in vitro fertilization with embryo transfer by trans-vaginal aspiration of gestational sac: a case report. *Int J Reprod Contracept Obstet Gynecol* 2016;5:3648-50.