



Crohn's disease with acute ileitis and its complications: a clinical case report

Adriel Contessotto Meneghelo¹, Beatriz Monteiro de Carvalho¹, Cássio Alfred Brattig Cantão¹, Cibele Alexandra Ferro¹, Fernanda Magni Cadamuro¹, Guilherme Gomes Romano², Luiz Fernando Criscuolo Filho¹, Mariah Menoci Mortean¹, Matheus Shirane Wajima¹, Rafael Moura Garcia¹, Stephaní Martins de Oliveira¹, Bruno Ziade Gil^{1*}

¹ FAMECA - Faculty of Medicine of Catanduva/Centro Universitário Padre Albino (UNIFIPA), Catanduva, São Paulo, Brazil.

² UNOESTE - Faculty of Medicine of Jaú, Jaú, São Paulo, Brazil.

*Corresponding author: Dr. Bruno Ziade Gil, FAMECA - Faculty of Medicine of Catanduva/Centro Universitário Padre Albino (UNIFIPA), Catanduva, São Paulo, Brazil. Email: bzgil@hotmail.com

DOI: <https://doi.org/10.54448/mdnt22410>

Received: 08-14-2022; Revised: 11-03-2022; Accepted: 11-15-2022; Published: 11-22-2022; MedNEXT-id: e22410

Abstract

Crohn's disease is a chronic, granulomatous inflammatory disease that can affect the entire gastrointestinal tract. Complications such as intestinal obstructions, fistula, or abscesses may determine the need for surgical treatment, with initial clinical stabilization. Therefore, the present work aimed to present a clinical case report, showing a patient who presented complications resulting from Crohn's disease to determine surgery as the definitive treatment and, emphasizes the importance of optimized treatment for this disease to avoid complications.

Keywords: Crohn's disease. Chronic inflammatory disease. Complications.

Introduction

Crohn's disease (CD) is a chronic inflammatory bowel disease, granulomatous, characterized by discontinuous lesions in heels that can affect the entire gastrointestinal tract, from the mouth to the perianal region, and extraintestinal organs [1]. Its incidence and prevalence are very variable, usually between the second and fourth decade of life and without predominance by sex, depending on factors such as geographic location, environmental factors, population immigration, and ethnic groups [1,2]. About 15% of patients with CD report a family history [3,4].

Risk factors related to its development include alterations in the intestinal microbiome, genetic factors, smoking, a low-fiber diet, physiological stress, and the use of medications (aspirin, antibiotics, NSAIDs, and oral contraceptives) [3]. It is important to highlight that

smoking increases the risk and early involvement by 2x more.

Abdominal pain, diarrhea, weight loss, rectal bleeding, low-grade fever, and fatigue are some of the symptoms presented. Clinical signs of malnutrition, cutaneous-mucosal pallor, pain, abdominal mass, distension, or fistulization of the abdominal wall can be found [5]. The gold standard in diagnosis is the combination of radiological, endoscopic, and pathological anatomy findings, demonstrating transmural, focal, and asymmetrical inflammation [4].

The goal of drug treatment is clinical and endoscopic remission, helping to prevent complications. Surgical treatment is mainly indicated for complications: intestinal obstruction, fistula or abscess formation, or a combination of these indications. Most of the time, surgery is elective, except in situations of intestinal perforation, peritonitis, excessive bleeding, or toxic megacolon, the need for surgery is urgent [6].

Therefore, the present work aimed to present a clinical case report, showing a patient who presented complications resulting from Crohn's disease to determine surgery as the definitive treatment and, emphasizes the importance of optimized treatment for this disease to avoid complications.

Methods

Study Design

The present study was elaborated according to the rules of the CARE case report (<https://www.care-statement.org/>). The patient's medical record was analyzed, who authorized access and signed the Free

and Informed Consent Form, and a thorough evaluation of the aspects inherent to the physical examination, complementary exams, and outcome of the surgical treatment, was to correlate with the literature cited in the bibliography. Data collection and analysis of the medical records of the patient in question were carried out at Hospital Escola Emílio Carlos - Catanduva, Sao Paulo, Brazil.

Ethical Approval

This case report was analyzed and approved with the number 5.791.392 by the Research Ethics Committee from the FAMECA / UNIFIPA, Catanduva, Sao Paulo, Brazil, and obtaining the Informed Consent Form according to CNS/CONEP Resolution 466/12.

Case Report

Patient Information and Clinical Findings, Timeline, Diagnostic Assessment, Therapeutic Intervention, and Follow-up

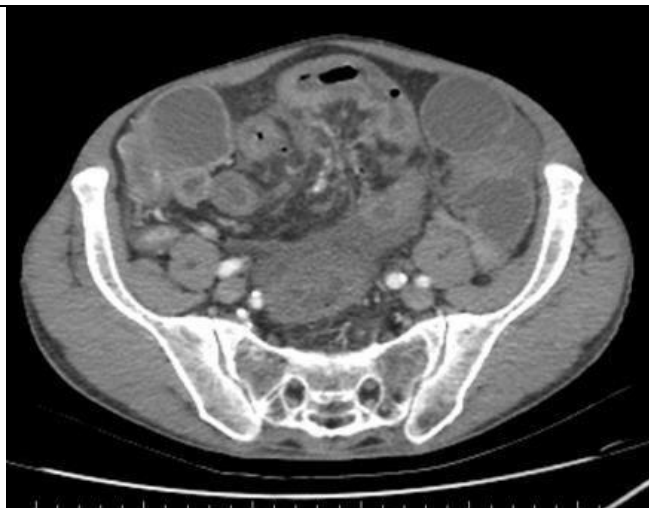
A 68-year-old man with Crohn's disease (CD), abdominal aortic aneurysm, and hypertension, comes to the emergency unit of Hospital Padre Albino, complaining of diffuse abdominal pain in colic for 3 days, associated with 3 episodes of diarrhea and vomiting. He denies the presence of blood and mucus in the stool. Denies fever. He refers to using infliximab 5mg/kg (patient weight 50kg). He reports not having had any episodes of exacerbation of CD since the diagnosis in 2017. On physical examination, he had a flaccid abdomen, painless on diffuse palpation, without signs of peritonitis and visceromegaly, with the presence of a mass in the infraumbilical region.

A CT scan of the abdomen with contrast was performed, which showed:

Figure 1. Computed tomography (CT) of the abdomen with contrast in the axial section showing pneumatosis in the portomesenteric venous system with a liver airportogram.

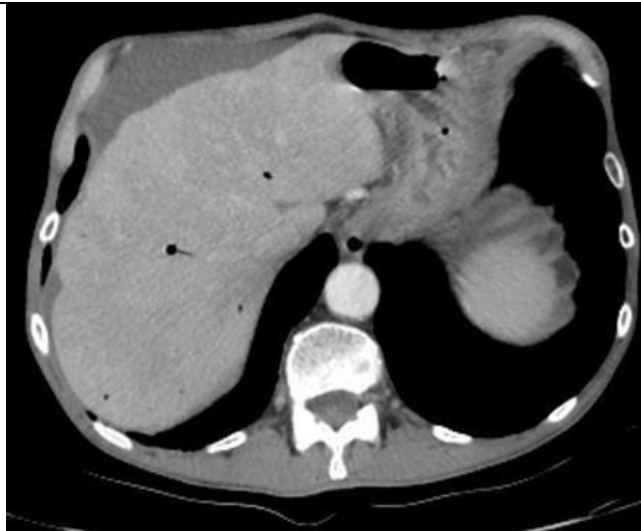

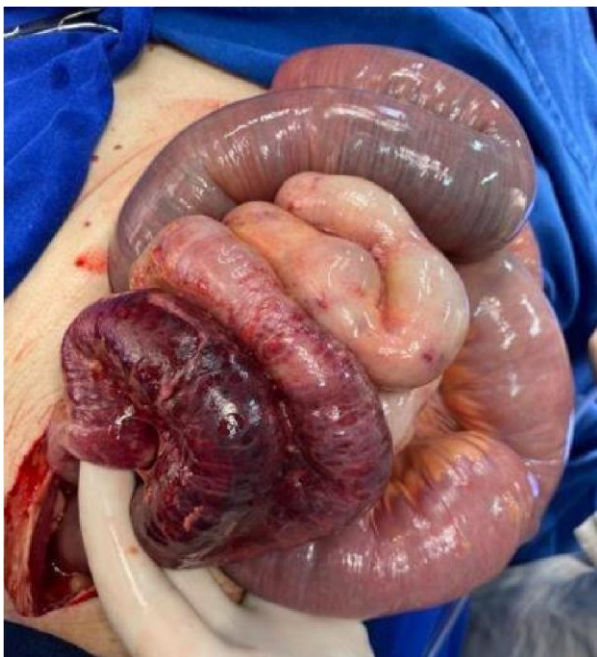Figure 2. Computed tomography of the abdomen with contrast in the axial section shows parietal thickening of the ileal loops in the hypogastric region, free fluid in the abdominal cavity, and hydro-air distension of the small bowel loops.



Due to contrast-enhanced abdominal tomography showing pneumoperitoneum with suspected small bowel perforation associated with pneumo portocholangiography, it was decided to transfer the patient to an emergency bed for monitoring and hemodynamic stabilization. Clinical treatment was initially carried out to improve the clinical conditions of the patient, using ceftriaxone, metronidazole, and hydrocortisone.

Subsequently, a surgical approach was performed, showing multiple adhesions forming a block near the terminal ileum loop with signs of ischemia, as well as an area of thickening in the mesentery and a large amount of bloody liquid in the abdominal cavity.

Figure 3. Cavity inventory – the presence of multiple adhesions forming a block near the terminal ileum loop with signs of ischemia, as well as a thickened area in the mesentery.



It was decided to perform a partial colectomy on the right with resection of the ischemic segment, undoing the adhesions found and making a Mikulicz ileostomy, which the patient remains in use until now at his own choice and that of the surgical team, due to its adaptation.

The anatomopathological examination showed acute, ulcerative ileitis, with parietal perforation, granulation tissue, non-caseating granulomatous reaction, acute fibrin-leukocyte peritonitis, and absence of malignancy. In the postoperative period, immunobiological and corticosteroids were not used, maintaining only ceftriaxone and metronidazole for 12 days until discharge. The patient was kept in bed in the intensive care unit with good evolution, without

complaints, and was discharged on the 6th postoperative day.

Discussion

The literature addresses surgical interventions in cases of complications and failure in clinical treatment, as in our case. In addition, some studies compare the surgical technique used in the past for patients with Crohn's disease, whose objective was a radical operation, with inflammation-free resection margins, with the surgery currently applied, a minimal procedure, intended only to remove the inflamed tissue, such as our case in question, in which a partial colectomy was performed on the right, foreseeing future possibilities in the future of recurrence of complications and the need to expand the area approached [6].

Genetic studies that associate Crohn's disease with ileal involvement to the NOD2 and CARD15 genes, and may also highlight the IL23R and ATG16L1 genes related to the disease [7]. The literature also shows that the use of immunobiological constitutes a new way to reduce local inflammation and relieve mucosal inflammation, allowing surgery to be performed in sites of complicated disease – as in our case in question, whose patient used infliximab to control the disease [1,6,8].

The preoperative management of septic conditions, as in the case of acute fibrin-leukocyte peritonitis present in this work, may be associated with a lower incidence of complications after surgery. Thus, clinical and hemodynamic stabilization of the patient before surgery is extremely important for a safe and uncomplicated postoperative period.

Conclusion

In our case, the patient had complications resulting from Crohn's disease that were important to determine surgery as the definitive treatment, as shown in the literature. The importance of an optimized treatment for Crohn's disease can be highlighted, avoiding the occurrence of complications, such as the one reported in the present case. After this complication is present in our case, the treatment is surgical. In our case, the initial clinical treatment was carried out, aiming to improve the patient's surgical conditions so that he could undergo surgery later. The surgery was a success, the patient had a good postoperative response, with a complete improvement of symptoms and a return to daily activities.

Acknowledgement

Not applicable.

Funding

Not applicable.

Ethics approval

This case report was analyzed and approved with the number 5.791.392 by the Research Ethics Committee from the FAMECA / UNIFIPA, Catanduva, Brazil, and obtaining the Informed Consent Form according to CNS/CONEP Resolution 466/12.

Informed consent

Was applied.

Data sharing statement

No additional data are available.

Conflict of interest

The authors declare no conflict of interest.

Similarity check

It was applied by Ithenticate@.

About the License

© The authors (s) 2022. The text of this article is open access and licensed under a Creative Commons Attribution 4.0 International License.

References

1. Gajendran M, Loganathan P, Catinella AP, Hashash JG. A comprehensive review and update on Crohn's disease. *Disease-A-Month*, [S.L.], v. 64, n. 2, p. 20-57, fev. 2018. Elsevier BV. <http://dx.doi.org/10.1016/j.disamonth.2017.07.001>.
2. Laass MW, Roggenbuck D, Conrad K. Diagnosis and classification of Crohn's disease. *Autoimmunity Reviews*, [S.L.], v. 13, n. 4-5, p. 467-471, abr. 2014. Elsevier BV. <http://dx.doi.org/10.1016/j.autrev.2014.01.029>.
3. Peng QH, Wang Yu-Fang, HE Man-Qing, Zhang Cui, Tang Qin. Clinical literature review of 1858 Crohn's disease cases requiring surgery in China. *World Journal Of Gastroenterology*, [S.L.], v. 21, n. 15, p. 4735-4743, 21 abr. 2015. Baishideng Publishing Group Inc. <http://dx.doi.org/10.3748/wjg.v21.i15.4735>.
4. Toh, JWt, Stewart P, Rickard MJfx, Leong R, Wang N, Young CJ. Indications and surgical options for small bowel, large bowel and perianal Crohn's disease. *World Journal Of Gastroenterology*, [S.L.], v. 22, n. 40, p. 8892, 2016. Baishideng Publishing Group Inc. <http://dx.doi.org/10.3748/wjg.v22.i40.8892>.
5. Doença de Crohn intestinal: manejo. *Revista da Associação Médica Brasileira* [online]. 2011, v. 57, n. 1, pp. 10-13. <https://doi.org/10.1590/S0104-42302011000100006>.
6. Yamamoto T. Surgery for luminal Crohn's disease. *World Journal Of Gastroenterology*, [S.L.], v. 20, n. 1, p. 78, 2014. Baishideng Publishing Group Inc. <http://dx.doi.org/10.3748/wjg.v20.i1.78>.
7. Kessler H. Recent results of laparoscopic surgery in inflammatory bowel disease. *World Journal Of Gastroenterology*, [S.L.], v. 17, n. 9, p. 1116, 2011. Baishideng Publishing Group Inc. <http://dx.doi.org/10.3748/wjg.v17.i9.1116>.
8. Protásio BKPF et al. Specificities of presentation of Crohn's disease in childhood. *Einstein (São Paulo)* [online]. 2018, v. 16, n. 1 <https://doi.org/10.1590/S1679-45082017RC4070>.

