

CZU: 616.212-007.2:617.317-007.254-031.4-089.844

DOI: <https://doi.org/10.52692/1857-0011.2022.2-73.07>

PRIMARY CORRECTION OF THE NASAL DEFORMITY ON PATIENTS WITH UNILATERAL CLEFT LIP

¹RAILEAN Silvia, dr. of med., MD.

²POȘTARU Cristina, dr. of med., MD.

¹LUPAN Roman, assistant

³NABILA Odi, student of stomatology department

¹State Medical and Pharmacy University "Nicolae Testemitanu".

Oro maxillofacial surgery for children and pedodontics department „Ion Lupan”

²State Medical and Pharmacy University "Nicolae Testemitanu".

Catedra de propedeutică stomatologică „Pavel Godoroja”

³State Medical and Pharmacy University Nicolae Testemitanu, Republic Moldova

silvia.railean@usmf.md

Summary.

Introduction. Orofacial clefts, is a group of conditions that includes cleft lip, cleft palate, and both together. Symmetry of the face can be obtained with primary nose reconstruction.

The goal: Analysis of patients with unilateral complete cleft lip patients treated with or without a primary nasal correction at the time of cleft lip repair were compared to evaluate the relevance of early surgical correction of the nose

Material and method. The 5 unilateral cleft subjects were operated on in 2022 by a technique of primary cleft nose correction (PCR), and 5 were operated without primary nose reconstruction (NNC). The anteroposterior and inferior facial appearances of each of the cases have been evaluated. A computer-based method of measuring nasal asymmetry was used to objectively analyze the results and compare them between children with and without primary nasal reconstruction. Measuring was done before and after the surgery and include qualitative and quantitative measurements.

Results: The results support the observation that nasal shape become symmetric in children that support primary nasal reconstruction and asymmetric in children without primary nasal reconstruction.

Conclusion: Primary nose reconstruction result in better cosmetic outcomes.

Key words: cleft lip/palate, primary nose reconstruction, Fisher technique, Millard technique, primary lip closure, qualitative and quantitative measurements.

Rezumat. Plastia primară a buzei superioare cu reconstrucția primară a nasului la copiii cu despicături labio/palatine.

Introducere. Despicăturile oro faciale include întreruperea continuității buzei superioare, palatului cât și ambele structure. Simetria facială obținută prin reconstrucția primară a nasului la copiii cu despicături totale unilateral definește și funcția precoce.

Materiale și metode. Au fost examinați 5 copii cu despicături labio/palatine la care plastia primară s-a efectuat cu reconstrucția nasului (PNC) și 5 pacienți cu despicături labio/palatine fără reconstrucția primară a nasului (NNC). Preoperatoriu și postoperatoriu au fost estimate măsurările calitative și cantitative în poziție anterioposterioară și inferioară.

Rezultate. Copiii cu plastia primară a buzei superioare și reconstrucția primară a nasului au arătat că măsurările au devenit identice la parte sănătoasă. Pe când copiii fără reconstrucții primare ale nasului în timpul plastiei primare a buzei măsurările au arătat că modificările nu au fost esențiale și asimetriile aproape că au rămas la cele preoperatorii.

Concluzie. Plastia primară a buzei superioare cu elementele de reconstrucție primară a nasului demonstrează rezultate cosmetice satisfăcătoare.

Cuvinte cheie. Despicături labiale/palatine, reconstrucția primară a nasului, metoda de plastie a buzei Millard, metoda de plastie a buzei Fisher, plastia primară a buzei superioare, măsurări calitative și cantitative.

Резюме. Первичная коррекция деформации носа у пациентов с односторонней расщелины губы.

Введение. Расщелины — это группа состояний, включающая расщелину губы, расщелину неба. Симметрию лица можно получить при первичной реконструкции носа.

Анализ пациентов с односторонней полной заячьей губой пациентов, получавших первичную коррекцию носа или без нее во время пластики губы сравнивали.

Цель. 5 пациентов с односторонней расщелиной были прооперированы с первичной коррекцией носа (ПКН), а 5 — без первичной реконструкции носа (БПКН). Были оценены передний и нижний вид лица в каждом из случаев. Для объективного анализа результаты были сравнены между детьми с первичной реконструкцией носа и без нее. Измерения проводились до и после операции и включали качественные и количественные измерения.

Результаты. Подтверждается наблюдение, что форма носа становится симметричной у детей, которые поддерживают первичную реконструкцию носа, и асимметричной у детей без первичной реконструкции носа.

Вывод: первичная реконструкция носа дает лучшие косметические результаты.

Ключевые слова: расщелина губы/нёба, первичная реконструкция носа, методика Фишера, методика Милларда, первичное закрытие губы, качественные и количественные измерения.

Introduction.

Orofacial clefts, is a conditions that includes cleft lip, cleft palate, and both together. A cleft lip contains an opening in the upper lip that may/may not extend into the nose. The opening may be on one side (unilateral) or both sides (bilateral). Cleft lip and palate are the result of tissues of the face not joining properly during development. As such, they are a type of birth defect. Cleft lip and palate occurs in about 1 to 2 per 1000 births, and it's about twice as common in males as females. Patient with oro-facial cleft deformity needs to be treated at right time and at right age to achieve functional and esthetic well being. Successful management of the child born with a cleft lip and palate requires coordinated care provided by a number of different specialties including oral/maxillofacial surgery, otolaryngology, genetics, speech/language pathology, orthodontics, prosthodontics, and other. Etiology could be complex of both genetic and environmental factors. Risk factors such as vitamin deficiency, especially folic acid deficiency, and maternal smoking, alcohol consumption, drug use, and chemical exposure have been associated with cleft lip development. Cleft lip and cleft palate can often be diagnosed during pregnancy with an ultrasound exam. A cleft lip or palate can be successfully treated with surgery. This is often done in the first few months of life for cleft lip and before eighteen months for cleft palate.

Cleft lip and cleft palate (CL/P) are one of the most common birth anomalies that may occur due to environmental factors and socioeconomic conditions as well as variability across geographic origin, race, and ethnic groups. CL/P prevalence is highest in the Asian and American populations and lowest in African populations. The gender distribution of cleft lip and palate is not equal in general. The incidence of CL/P is 2 times higher in men than in women.

CL±P incidences were reported in a study conducted by the International Perinatal Database of Typical Orofacial Clefts established in 2003 through the Human Genetics Program of World Health Organization (WHO). On the basis of the records evaluated according to geographical regions, CL ± P incidences were determined in Japan, Mexico, Western Europe, Canada, the United States, Australia, British Isles, Eastern Europe, United Arab Emirates, South Mediterranean Europe, and South Africa; the incidence was the highest in Japan and the lowest in South Africa.

Unilateral cleft lip nasal deformity is characterized by prominent asymmetry resulting from distorted and displaced structures. A variety of strategies have been proposed to treat this type of condition, including preoperative nasoalveolar molding, overcorrection of the nostril and alar cartilage, Postoperative relapse is a frequent finding due to the elasticity of the deformed alar cartilage.

Primary correction of the nasal deformity at the same time of lip repair has gained popularity, aiming at early restoration of the symmetry by lifting the alar cartilage and lengthening the columella on the cleft side.

The aim of the study: Analysis of the nasal deformity in children with complete cleft lip with and without surgical primary correction of the nasal deformity at the same time of lip repair. The objectives

1. Analyze the incidence of cleft lip according to the clinical department of oro-maxillofacial, of State Medicine and Pharmacy University.

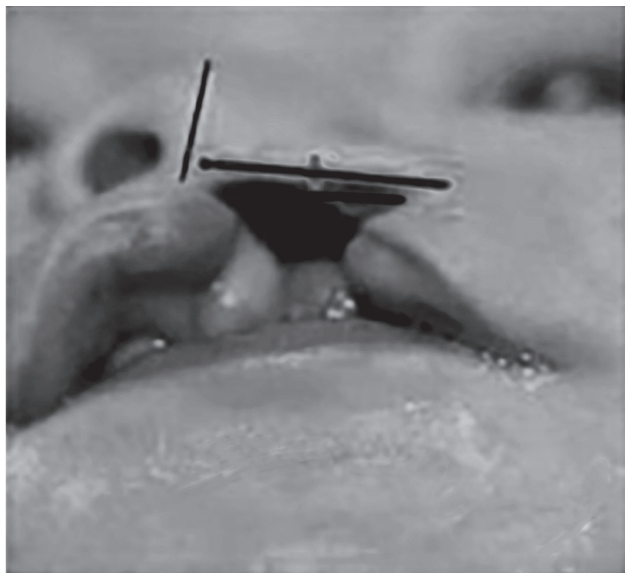2. Analyze and compare the qualitative and quantitative disorders of the nose in children with complete cleft lip with and without primary correction of the nasal deformity

Materials and methods The study was performed at Mother and Children Hospital of Republic of Moldova, Em. Cotaga Clinic, Chisinau city, at oro maxillofacial department for children. Our study was conducted during periods from January 2022 to Much 2022 and includes two steps. At the first step medical records of patients with cleft lip/palate were estimated. From medical records were taken an information about ages, type of cleft, geographical location.

The no nasal correction group (NNC, n = 5) was operated by the Millard technique. The primary nasal correction group (PNC, n = 5) was operated combining the modified Millard technique with a columellar lift and alar-septum mobilization and correction. The average age of the patients at the time of lip repair was 3 -6 months.

Qualitative and quantitative estimation were performed in both groups, before and after the primary closure of the lip. No significant differences in symmetry were found between the NNC and PNC groups before surgery. Regarding the measurements after the surgery NNC cleft groups produced a significant asymmetry after surgery when compared to the NC group.

For qualitative estimation three nasals linear measurements were taken. Nostril length, nostril width, columnella length, nasal base width (Fig?). The technique of taking the measurements has been describe by Farcas L 1981



	Nostril length
—	Nostril width
/	Columnella length
—	Nasal base width

Figure 1 Qualitative estimation of the nose

Quantitative estimation consist of evaluating the shape, dimensions, position, and symmetry of the alar base from frontal and basal views Alar base width is best evaluated from the frontal view. Basal view is essential in the evaluation of the anatomy of the nasal base, alar flaring, nostril circumference, and asymmetries.

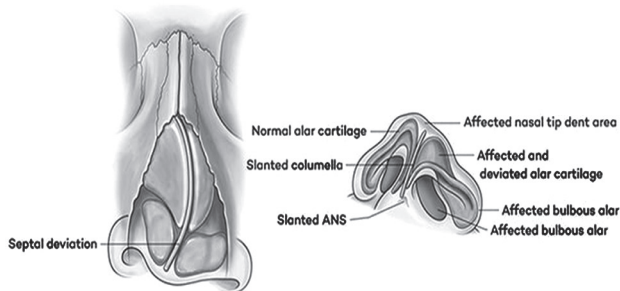


Figure 2. Quantitative appreciation of the nose in cleft lip/palate cases.

Nose qualitative and quantitative measaments were taken before surgery and 7 days after the surgery. Findings were compared between two groups of children with cleft lip developed with and without nose reconstruction.

Result and descution. Statistics about patients information that came to the hospital from 01/01/2022-22/03/2022 (12 patients in total).

În rezultatul studiului pe parcurs de trei luni s-a constatat o incidență mai mare a fetițelor în com-

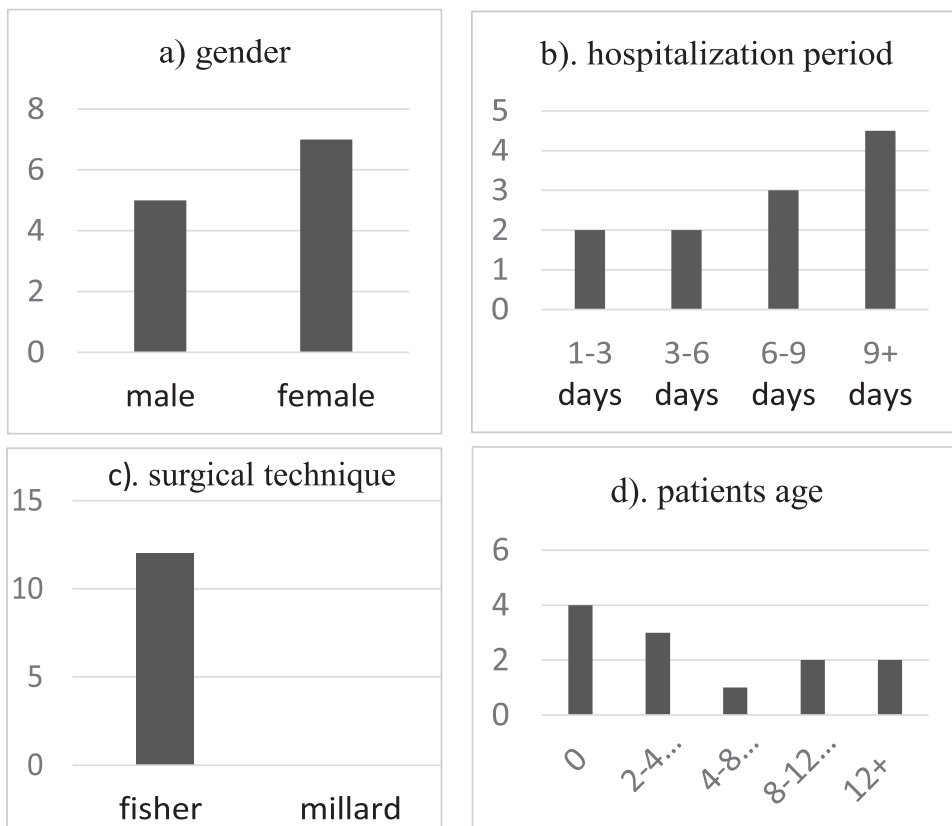


Figure 3. Distribution of patients by a) gender, b) hospitalization period, c) surgical technique, d) by age.

parație cu a băieților. Cele mai frecventa tratamente chirurgicale s-au constatat la 3 luni, deoarece s-a constatat o că o parte din copii au prezentat despicături de buză separate. La acești copii s-a efectuat reabilitarea primară chirurgicală prin plastia primară a buzei superioare și reconstrucția nasului. Restul copii au urmat tratamentul pe tape în funcție de vârsta copilului.

Pe perioada examinată copiii cu despicături ale feței, plastia primară a buzei superioare a fost efectuată după procedeul Fișer. Rezultatele postoperatorii au fost comparate cu rezultatele Millard fără reconstrucției primare ale nasului. În mediu copii s-au aflat în staționar aproximativ. 7 zile.

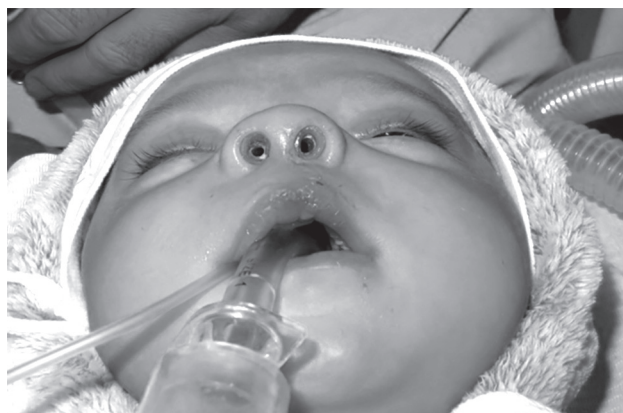
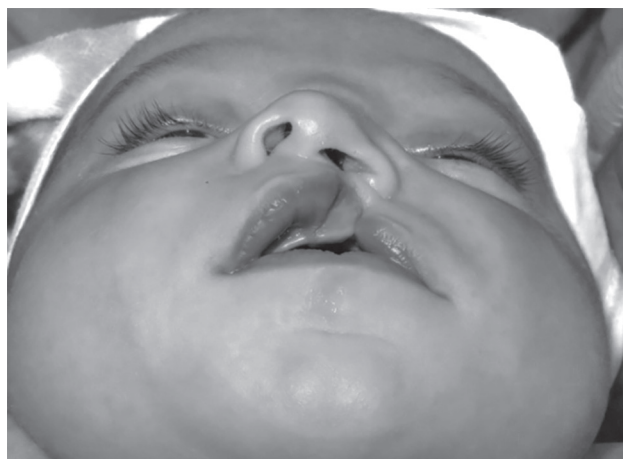
Figure 4. Cleft lip ad palat. Before and after the primary closure with primary nose reconstruction.

MEASUREMENTS

➤ *Quantitative examination preoperative* of the nose in the affected side: S-shape of the nose, flattened and horizontal widening, columella is deviated and shorter on cleft side, obtuse dome, nasal tip is displaced, base of the columella is deviated to non cleft side.

➤ *Qualitative examination preoperative:* Nostril length on the affected side 2 cm and non-affected side 1,5 cm. Nostril width 1 cm non-affected side and 2 cm on affected side. Columnella length 1mm non-affected side and 0,5 mm affected side. Nasal base width 3 cm

➤ *Quantitative examination postoperative:* The nasal wing is symmetrical with the healthy part, the S shape of the nasal wing has disappeared, the relief of the nose is symmetrical with the healthy part. The height of the columella is symmetrical with the healthy side.

➤ *Qualitative examination postoperative:* Nostril length 1,5 cm ,Nostril width 1,2 cm. Columnella length 1 cm. Nasal base width 2,3mm.

Table 1

Preoperative and postoperative nasal qualitative examination children with primary closure with nasal reconstruction.

nostril values	side of the nose	before surgery	after surgery
nostril length	healthy	1.5cm	1.5cm
	affected side	2cm	1.5cm
nostril width	healthy	1cm	1cm
	affected side	2cm	1,2cm
columnella length	healthy	1cm	1cm
	affected side	0.5cm	1cm
nasal base width		3cm	2.3cm

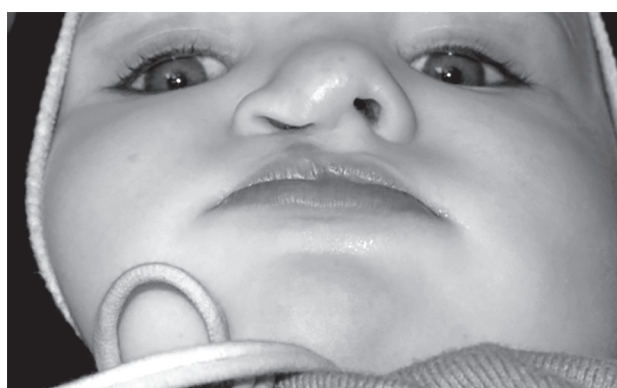
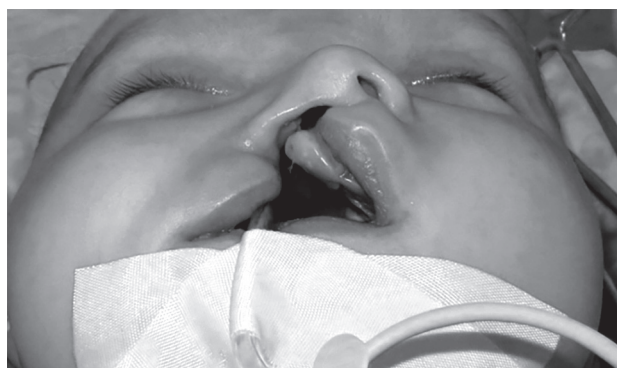
Figure 5. Primary closure of the lip without nasal reconstruction

MEASUREMENTS

➤ *Quantitative examination preoperative:* of the nose in the affected side: S-shape of the nose, flattened and horizontal widening, columella is deviated and shorter on cleft side, obtuse dome, nasal tip is displaced, base of the columella is deviated to non cleft side.

➤ *Qualitative examination preoperative:* Nostril length on the effected side 2 cm and non-affected side 1,5 cm. ,Nostril width 1 cm non-affected side and 2 cm on affected side. Columnella length 1mm non-affected side and 0,5 mm affected side.. Nasal base width 3 cm.

➤ As a result of the surgical treatment without elements of primary reconstruction of the nasal cartilage, a quantitative and qualitative measurements before and after the primary closure were the same.

Tabel 1

Preoperative and postoperative nasal qualitative examination children without primary nasal reconstruction.

nostril values	side of the nose	before surgery	after surgery
nostril length	healthy	1.5cm	1.5cm
	affected side	2cm	2cm
nostril width	healthy	1cm	1cm
	affected side	2cm	1,8cm
columnella length	healthy	1cm	1cm
	affected side	0.5cm	0.5cm
nasal base width		3cm	2.8cm

Results and discussions.

The incidence of cleft lip/palate in Moldova was estimated by A.M Guţan (1980), than by I. Gh. Lupan (2000). As a result the incidence of cleft lip/palate was estimated in 1, 01: 1000 live new-born in the period 1987-2000. The highest incidence was noted in the southern and central regions of the Republic Moldova (1, 06). By Lupan I. (2000) was estimated the increase of incidence up to 0, 32:1000 lives new-born in compare with the period 1960- 1974. The incidence of separate cleft lip (CL) increased only 0,03 and incidence of cleft lip and palate (CLP) increased 0,12 and the incidence of cleft palate (CP) increased 0,16 per 1000 live new-born, that resulted in the change of the ratio between the certain form of lip and palate clefts (CL:CLP:CP) from 1,4:1,4:1 to 1:1,3:1,2. The conclusion that was done by Lupan I. means the increase of the severe type of cleft lip/palate in Republic Moldova (4).

The cleft nose has long been a problem when closing the lip in a cleft palate patient. More today than in the past, close attention is paid to the outcome of the nasal form, nasal base, and the position of distorted structures like the nose cartilage and the septum. The different techniques of lip closure can be used simultaneously with the nasal correction. But different methods of lip repair without primary nasal correction also influence the nasal form. It seems that the reconstruction of the naso-labial muscles (including the orbicularis muscle) is an important factor to gain a symmetrical nose after the primary operation.

Although the results are very promising, it cannot be stated that no further operations will be needed later. But since growth disturbance has not been reported until now, most of the authors dealing with primary nasal correction recommend it simultaneously with the lip repair (1, 2, 3).

In the present study we found the quantitative and qualitative measurements before surgery in both PNC and NNC were approximately equal. (Table 1, 2). S-shape of the nose, flattened and horizontal widening, deviated columella and shorter on cleft side, obtuse dome, displaced nasal tip, deviated to non cleft side base of the columella was found in both groups. The qualitative values of the nose (nostril length nostril width columella length and nasal base width) in the healthy side (1.5, 1cm, 1cm, 3cm) and affected side (2cm, 2cm, 0.5cm, 3 cm) in both NNC and PNC was same.

In the group of PNC after surgery, the cosmetic condition of the face including nose obviously improved. Nostril length (from 2cm to 1,5cm), nostril width (from 2cm to 1,2cm), columella length from (0.5cm to 1cm) and nasal base width (from 3cm to 2,3cm) become after surgery same like in healthy side (Table 1, Figure 4).

In the NNC nostril length (from 2cm to 2cm), nostril width from (2cm to 1,8cm), columella length (from 0.5cm to 0,5cm), nasal base (width from 3cm to 2.8cm) was found asymmetrical in the healthy side and affected side.

According to the bibliographic data found in the specialized literature, we can say that the growth of the anatomical units, especially of the nose, is not affected by the elevation of the cartilage, nostril and septum. So, we considered that primary correction of the nose in the unilateral cleft lip nasal deformity achieves the excellence cosmetic and functional issues. (5, 6, 7).

Conclusion.

Correction of the cleft-lip nasal deformity is a difficult task. These deformities tend to accentuate as nasal growth continues. PNC in the unilateral cleft lip improves nasal symmetry and decrease the need for intermediate surgery. The open definitive rhinoplasty utilizing the primary open-structure rhinoplasty approach allows maximum exposure for placement of structural grafts to improve tip projection, definition, support, and function.

Bibliography.

1. H. K. McComb, B. A. Coghlan: Primary repair of the unilateral cleft lip nose: completion of a longitudinal study Cleft Palate Craniofac J 1996 Jan;33(1):23-30
2. C. A. Brussé, J. F. Van der Werff, H. P. Stevens, C. Vermeij-Keers, B. PrahI-Andersen, J. C van der Meulen,

J. M. Vaandrager. Symmetry and morbidity assessment of unilateral complete cleft lip nose corrected with or without primary nasal correction Cleft Palate Craniofac J. 1999 Jul;36(4):361-6.

3. Mostafa Farmand. Lip repair techniques and their influence on the nose. Facial Plast Surg 2002 Aug;18(3):155-64.

4. Lupan Ion. Recuperarea medicală a copiilor cu malformații congenitale ale feței. Teza de doctor habilitat în științe medicale. 2004.

5. Cristen E. Olds, Jonathan M. Sykes. Cleft Rhinoplasty. Clin Plast Surg., 2022 Jan;49(1):123-136.

6. Charles W. Shih, Jonathan M. Sykes. Correction of the cleft-lip nasal deformity Facial Plast Surg 2002 Nov;18(4):253-62.

7. Fatemeh Mirashrafi, Sara Rahavi-Ezabadi, Fatemeh Tavakolnejad, Amin Amali. Primary rhinoplasty in unilateral incomplete cleft lip nose: A 4-year follow up Int J Pediatr Otorhinolaryngol 2021 Jun;145:110717.