


Title	Metastasis to the finger of oral floor squamous cell carcinoma: A case report
Author(s)	Isomura, Tanaka Emiko; Hamaguchi, Munehiro; Nishimura, Nao et al.
Citation	Clinical Case Reports. 9(1) p.8-p.11
Issue Date	2021-01
oaire:version	VoR
URL	https://hdl.handle.net/11094/89683
rights	This article is licensed under a Creative Commons Attribution-NonCommercial 4.0 International License.
Note	

Osaka University Knowledge Archive : OUKA

<https://ir.library.osaka-u.ac.jp/>

Osaka University

Metastasis to the finger of oral floor squamous cell carcinoma: A case report

Emiko Tanaka Isomura¹  | Munehiro Hamaguchi² | Nao Nishimura² | Ayako Ushimura² | Mari Namikawa¹

¹First Department of Oral and Maxillofacial Surgery, Graduate School of Dentistry, Osaka University, Suita, Japan

²Yao Municipal Hospital Department of Oral and Maxillofacial Surgery, Yao, Japan

Correspondence

Emiko Tanaka Isomura, First Department of Oral and Maxillofacial Surgery, Graduate School of Dentistry, Osaka University, 1-8 Yamadaoka, Suita City, Osaka 565-0871, Japan.

Email: tanaemi@dent.osaka-u.ac.jp

Abstract

When cetuximab is used, diagnosing finger metastasis can be difficult due to the side effects of paronychia and color changes of nails. Finger metastasis may be a marker of multiple metastasis; therefore, it can lead to a poor prognosis.

KEYWORDS

metastasis to the finger, oral cancer, prognosis

1 | INTRODUCTION

A patient with oral floor squamous cell carcinoma received surgery and chemoradiotherapy. After prophylactic chemotherapy for lung metastasis, the patient developed pain and edema in the right middle finger and was diagnosed with finger metastasis. Metastasis to the finger may play a significant role in the prognosis of oral carcinoma.

Carcinoma metastasis to the finger is rare, with a reported frequency of 0.1%–0.2% of all cancers.¹ In addition, more than half of finger metastases are from lung carcinoma.² We present a rare case of metastasis to the finger after chemotherapy for lung metastasis of oral floor squamous cell carcinoma (SCC).

2 | CASE HISTORY/ EXAMINATION

The patient was a 65-year-old male with no systemic illness and no history of tobacco use. In December 2014, the patient

was seen by a dentist due to a mass on his oral floor and difficulty moving his tongue for 2 weeks. He was referred to our department for diagnostics and treatment.

The patient presented with a 15 × 10 mm rough mass with an ulcer, erythema, and induration on the left oral floor, and no abnormal findings on extraoral examination (Figure 1). There was no extension to other lesions. Positron emission tomography-computed tomography scan (PET-CT) showed a metastatic lesion in a left submandibular lymph node that was significantly edematous (20 × 18 mm) with no ring enhancement.

The clinical diagnosis was a left oral floor SCC with clinical staging of T1N1M0.

3 | DIFFERENTIAL DIAGNOSIS, INVESTIGATIONS, AND TREATMENT

Tracheotomy, tumor resection (including mandibular marginal resection), left modified radical neck dissection (type

This is an open access article under the terms of the Creative Commons Attribution-NonCommercial License, which permits use, distribution and reproduction in any medium, provided the original work is properly cited and is not used for commercial purposes.

© 2020 The Authors. *Clinical Case Reports* published by John Wiley & Sons Ltd

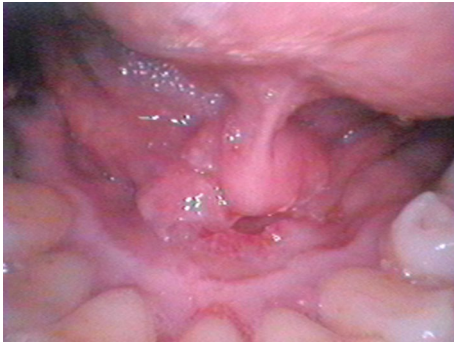

FIGURE 1 The image of the oral floor tumor. The patient presented with a 15 × 10 mm rough mass with an ulcer, erythema, and induration on the left oral floor

II), and a free forearm flap transplantation were carried out in December 2014. The margins of the excised tumor were tumor-free. The final clinical staging was pT1N2bM0, and there was more lymph metastasis than the previous CT revealed. Therefore, prophylactic postoperative chemoradiotherapy was chosen as a course of treatment (radiotherapy: 59.5 Gy/30 Fr and chemotherapy: Cisplatin [80 mg/m²] + 5-FU [800 mg/m²] × 2 times).

After postoperative chemoradiotherapy, the patient returned routinely for monthly follow-up visits. Eleven months after the operation, multiple lung metastases were discovered in a chest CT image. The patient was not a candidate for surgery due to the multifocality of the lesions; therefore, only chemotherapy was performed. Cetuximab and paclitaxel were administered

FIGURE 2 Images of the right middle finger metastasis. There is discoloration and stripping of the nail, edema, and erythema of the middle finger

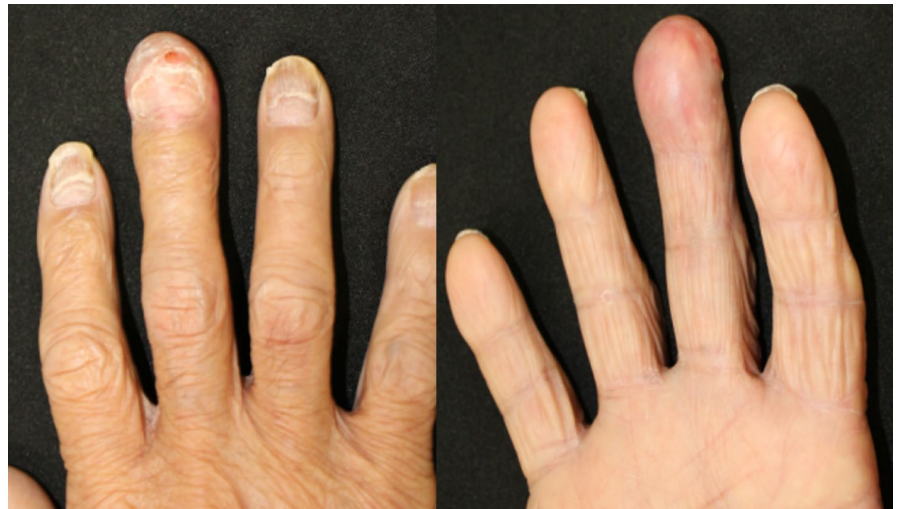

FIGURE 3 X-ray images of the right middle finger metastasis. The entire terminal phalanx has resorbed

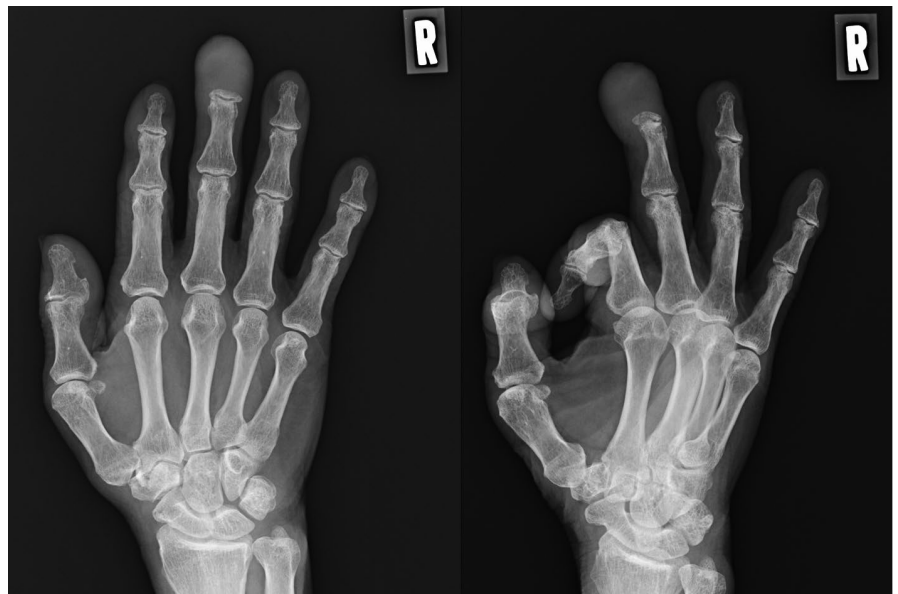


TABLE 1 Finger bone metastasis cases from oral cancer

Report	Age/sex	Histological diagnosis	Primary cancer	Finger metastasis	Multiple/single	Treatment	Prognosis (M)
Castigliano ⁹	65/M	SCC	Tongue-oral floor	Thumb	Multiple	RT	3
Castelló et al ¹⁰	68/M	SCC	Hard palate	Thumb	Multiple	Excision	10
Mandadi et al ¹¹	66/M	SCC	Base of the tongue	Fifth finger	Multiple	Amputation	Unknown
Viswathanan et al ¹²	70/M	SCC	Mandible	Middle finger and index finger	Multiple	Chemo-therapy	Unknown
Shrivastava et al ¹³	66/M	SCC	Mandible	Middle finger	Single	CRT	3
Mohanty et al ¹⁴	40/M	SCC	Mandible	Middle finger	Multiple	Chemo-therapy	2
Our case	65/M	SCC	Oral floor	Middle finger	Multiple	Palliative care	3

Abbreviations: M, male; SCC, squamous cell carcinoma.

for 8 months and stopped in April 2016 due to paronychia of all fingers, seemingly a side effect of cetuximab. Subsequently, titanium silicate (TS)-1 and docetaxel were administered continuously for 3 months. In October 2016 (22 months after presentation/diagnosis of oral cancer), the fingernails changed color, and in November 2016, the right middle finger nail peeled off (Figure 2). In December 2016 (2 years after excision of the primary tumor), the patient complained of severe pain and edema in the right middle finger. A dermatologist diagnosed phlegmon and prescribed antibiotics. However, the edema worsened. In March 2017, in association with increasing blood calcium concentration, multiple bone metastases were discovered by bone scintigraphy. Moreover, X-ray revealed a well-circumscribed bone resorption in the right middle finger and cytology showed SCC (Figure 3). Therefore, we diagnosed metastasis to the finger secondary to lung metastasis.

4 | OUTCOME AND FOLLOW-UP

There was no recurrence at the primary lesion site, and no metastasis at the neck lesions. However, the lung metastasis advanced, leading to death in May 2017.

5 | DISCUSSION

Metastatic tumors to the hand are rare, representing approximately 0.1% of all metastatic lesions to the skeleton; most lesions are from lung cancer.^{1,3-7} Kerin reported that the mechanism of metastatic dissemination to the hand was unclear.¹ Metastases are highest in bones that are rich in red marrow, however, the bone of the hand is not rich in red marrow. This may explain the rarity of metastatic tumors to the hand.

Finger metastasis from oral cancer is rarer than metastasis from other cancers. To our knowledge, there have only been

8 cases reported, including our case. One case had metastasis to the dorsum of the hand from oral malignant melanoma. Seven cases were of SCC and in males over 60 years of age (Table 1). Six cases were of multiple metastases and only one case of single metastasis. Three cases were of metastasis to the middle finger, two cases to the thumb, one case to the fifth finger, and one case to the middle finger and the index finger.⁸⁻¹⁴

Flynn et al reported that 60% of cases of finger bone metastases were to distal phalanges, with the middle finger or thumb of the dominant arm as the most frequent site.¹⁵ In our case, the finger metastasis was on the middle finger of the dominant arm, and clear bone absorption did not extend to the finger joint.

Paronychia and color change in the nails are side effects of cetuximab. Thus, when these medications are used, diagnosing finger metastasis can be difficult. In our case, the patient had an acne-like rash and paronychia soon after the administration of cetuximab. Furthermore, all nails changed color and the right middle finger nail peeled off after administering cetuximab. These phenomena appeared to be side effects. However, the pain and swelling of the middle finger after December 2016 led to the suspicion of finger metastasis.

To date, all reported cases with known lung cancer metastasis to the finger died within 1 year after diagnosis.¹ Therefore, metastasis to the finger plays a significant role in the prognosis of oral carcinoma with lung metastasis. As the life expectancy for those with cancer increases with new anticancer drugs, the risk of metastasis has increase. To improve prognosis, it is important to detect metastases in the early stages.

ACKNOWLEDGMENTS

We thank to medical staffs of Yao Municipal Hospital who did the patient's care. Published with written consent of the patient.

CONFLICT OF INTEREST

None declared.

AUTHORS CONTRIBUTIONS

Emiko Tanaka Isomura: wrote this paper. Munehiro Hamaguchi: treated the patient and collected the data of the patient. Nao Nishimura: treated the patient and collected the data of the patient. Ayako Ushimura and Mari Namikawa: treated the patient.

ORCID

Emiko Tanaka Isomura  <https://orcid.org/0000-0002-7855-9600>

REFERENCES

1. Kerin R. The hand in metastatic disease. *J Hand Surg.* 1987;12:77-83.
2. Afshar A, Farhadnia P, Khalkhali H. Metastases to the hand and wrist: an analysis of 221 cases. *J Hand Surg.* 2014;39:923.e17-932.e17.
3. Healey JH, Turnbull AD, Miedema B, Lana JM. Acrometastases. A study of twenty-nine patients with osseous involvement of hands and feet. *J Bone Joint Surg Am.* 1986;68(5):743-746.
4. Libson E, Bloom RA, Husband JE, Stoker DJ. Metastatic tumours of bones of the hand and foot. A comparative review and report of 43 additional cases. *Skeletal Radiol.* 1987;16:387-392.
5. Kerin R. Metastatic tumors of the hand. A review of the literature. *J Bone Joint Surg.* 1983;65(9):1331-1335.
6. Morris G, Evans S, Stevenson J, et al. Bone metastases of the hand. *Ann R Coll Surg Engl.* 2017;99:563-567.
7. van Veenendaal LM, de Klerk G, van der Velde D. A painful finger as first sign of a malignancy. *Geriatr Orthop Surg Rehabil.* 2014;5:18-20.
8. Tochigi H, Nakao Y, Horiuchi Y, Toyama Y. Metastatic malignant melanoma in the hand muscle—a case report. *Hand Surg.* 2000;5:69-72.
9. Castigliano SG. Metastasis to the distal phalanx from a primary malignancy of the oral cavity: report of case. *J Oral Surg (American Dental Association).* 1966;24:467-469.
10. Castello JR, Garro L, Romero F, Campo M, Najera A. Metastatic tumours of the hand: report of six additional cases. *J Hand Surg.* 1996;21:547-550.
11. Mandadi SR, Kudva A. Acrocuteaneous metastasis — A rare presentation. *Int J Sur Case Rep.* 2018;51:178-180.
12. Viswanathan PN, Rangad F, Roul RK. Metastases to the hand from carcinoma of the lower alveolus. *J Hand Surg.* 1996;21:544-546.
13. Shrivastava R, Singh KK, Umbarker BR, Karle R, Shrivastava M. Phalange metastasis from carcinoma of alveolus. *Indian J Dent Res.* 2009;20:496-498.
14. Mohanty SN, Samanta DR, Avinash A, Senapati SN. Acral metastasis in carcinoma of buccal mucosa: an unusual presentation. *Oncol J India.* 2018;2:35-37.
15. Flynn CJ, Danjoux C, Wong J, et al. Two cases of acrometastasis to the hands and review of the literature. *Curr Oncol.* 2008;15:51-58.

How to cite this article: Isomura ET, Hamaguchi M, Nishimura N, Ushimura A, Namikawa M. Metastasis to the finger of oral floor squamous cell carcinoma: A case report. *Clin Case Rep.* 2021;9:8–11. <https://doi.org/10.1002/ccr3.3344>