



Prolonged ischemia of the ileum and colon after surgical mucosectomy explains contraction and failure of “mucus free” bladder augmentation

^aInstitute of Surgical Research, University of Szeged, Pulz u.1., Szeged, H-6724, Hungary

^bDepartment of General Surgery, Hetényi Géza County Hospital, Tószegi U. 21., Szolnok, H-5000, Hungary

^cDepartment of Paediatric Urology, Royal Manchester Children's Hospital, Oxford Rd, Manchester, M13 9WL, United Kingdom

^dDepartment of Paediatric Surgery, Faculty of Medicine, Cairo University, Al Manial, Cairo Governorate, Egypt

* Correspondence to: Tamás Cserni, Department of Paediatric Urology, Royal Manchester Children's Hospital, Oxford Road, Manchester, Greater Manchester, M13 9WL, UK
urbandaniel03@gmail.com (D. Urbán)
varga.gabriella.1@med.u-szeged.hu (G. Varga)
erces.daniel@med.u-szeged.hu (D. Érces)
m.marei@cu.edu.eg (M.M. Marei)
Raimondo.Cervellione@mft.nhs.uk (R. Cervellione)
tamas.cserni@mft.nhs.uk (T. Cserni)

Keywords

In-vivo microscopy; Microcirculation; Mucosectomy; Bladder augmentation; Colon; Small intestine

Received 27 January 2022
Revised 8 March 2022
Accepted 15 April 2022
Available online 27 April 2022

Dániel Urbán ^{a,b}, Gabriella Varga ^a, Dániel Érces ^a, Mahmoud Marei Marei ^{c,d}, Raimondo Cervellione ^c, David Keene ^c, Anju Goyal ^c, Tamás Cserni ^{a,c,*}

Summary

Introduction

Mucus production by the intestinal segment used in bladder augmentation results in long term concerns especially stones and UTI. Bladder augmentation with demucosalized intestinal flap is a potential promising approach for mucus-free bladder augmentation, however the contraction of the flap remains a major concern. Mucosectomy has been shown to result in abrupt and immediate cessation of microcirculation in the ileum. However, assessment of microcirculation shortly after mucosectomy may miss a gradual recovery of micro-circulation over a longer period of time. Previous studies have not assessed the colon response to mucosectomy.

Objective

Our aim was to assess the effect of mucosectomy on the microcirculation of the colon and ileum beyond the known warm ischemia time.

Study design

Ileum and colon segments were detubularised and mucosectomy was performed in (n = 8) anaesthetised minipigs. **Group A:** sero-musculo-submucosal flaps were created with removal of the mucosa and preserving the submucosal layer **Group B:** sero-muscular flaps were created with the removal of submucosal-mucosal layer. The Microvascular Flow Index (MFI), the velocity of the circulating red blood cells (RBCV) was measured using Intravital Dark Field (IDF) side stream

videomicroscopy (Cytoscan Braedius, The Netherlands) after mucosectomy, for up to 180 min.

Results

Both the MFI and RBCV showed an abrupt reduction of microcirculation, on both surfaces of the remaining intestinal flap, in the ileum as well as in the colon. Slightly better values were seen in Group A of the colon, but even these values remain far below the preoperative (control) results. Some, tendency of recovery of the microcirculation was noted after 60–90 min, but this remained significantly lower than the preoperative control values at 180 min.

Conclusion

Both the ileal and the colonic flap remains in severe ischemia after mucosectomy beyond the warm ischemia time.

Discussion

This study shows that surgical mucosectomy compromises vascular integrity of the intestinal flaps used for bladder augmentation. Partial recovery which occurs within the warm ischemia time is not significant enough to avoid fibrosis therefore flap shrinkage may be inevitable with this technique.

Limitation

The gastrointestinal structure of the porcine model is not the same exactly as the human gastrointestinal system. However, although not an exact match it is the closest, readily available animal model to the human gastrointestinal system.

Introduction

Intestinal segments (ileum, colon) are the commonest donor tissues used for bladder augmentation. However, the presence of intestinal mucosa within the augmented bladder is associated with risk of significant complications, such as increased UTI rate and stone formation due to mucus production; absorption of electrolytes from urine; and adenocarcinoma development [1].

Extensive research has been carried out to eliminate intestinal mucosa from the augmented bladder. 'Sero-musculo-submucosal' flaps and 'sero-muscular' intestinal flaps have been used in experimental and clinical settings; however, flap contraction remains a concern.

It has been hypothesized that the contact of the urine with the raw surface of the intestinal segment after mucosectomy may be responsible for contraction. Composite flaps with cultured urothelium coverage of the denuded surface seemed to be a viable and promising approach, based on experiments with small sized patches; however, there are no further publications reproducing this with larger flaps, as would be required to translate this into clinical practice [2–4] and contraction of the intestinal flaps remains a major concern.

In an experimental study, using real-time in-vivo video-microscopy of the capillaries of the ileum, we demonstrated abrupt cessation of microcirculation in the ileum after mucosectomy, however the microcirculation was not monitored further in time to assess potential recovery. The effect of mucosectomy has not been studied in the colon, which is the second most used donor organ for bladder augmentation [5].

Our aim was to assess the effect of mucosectomy on the microcirculation of the colon and the ileum in the same experimental setting and monitor intramural microcirculation for possible recovery beyond the known warm ischemia time.

Material and methods

The experiments were performed according to the EU Directive 2010/63/EU on the protection of animals used for experimental and other scientific purposes and carried out in strict adherence to the NIH guidelines for the use of experimental animals. The study was approved by the National Scientific Ethical Committee on Animal Experimentation, with the license number V./1637/2013.

The study was performed on anaesthetised female Vietnamese mini pigs ($n = 8$, weight: 25–30 kg). The animals were kept under conventional circumstances, in standard cages. They were fed with commercially available mixed food, fasted 24 h before surgery and always had free access to water. Anaesthesia was induced with an intramuscular injection of a mixture of ketamine (20 mg/kg) and xylazine (2 mg/kg) and maintained with a continuous infusion of propofol (2%; 50 $\mu\text{l}/\text{kg}/\text{min}$ *i.v.*), via a cannulated ear vein. Endotracheal tube was inserted, and the animals were ventilated mechanically, with a volume-controlled ventilator. The tidal volume was set at

8–9 ml/kg, and the respiratory rate was adjusted to maintain the end-tidal carbon dioxide pressure (EtCO_2) to 35–45 mmHg. Norocarp S (carprofen; 4 mg/kg) and normal saline infusion were administered via the ear vein catheter. Heart rate, O_2 saturation (pulse oximetry), EtCO_2 (capnometry) and body temperature were continuously monitored perioperatively.

First, the ileal and colonic segments were isolated and detubularized along the anti-mesenteric line. The bowel was kept warm with 0.9% saline solution. The detubularised bowel strips were placed on wet gauze. The mesenteric pedicle was not clamped. The width and the microcirculation were recorded on the serosal and mucosal surfaces. Mucosectomy was then performed. In the 'sero-musculo-submucosal' group (Group A, it is subdivided into Group A-I (ileum) and Group A-C (colon)), only the mucosa was scraped off with the back of a forceps from the bowel at the level of the mucosal lamina propria. Surgical loops with 2.5 \times magnification were used to make sure that no mucosal islands are left behind. In the seromuscular group (Group B, it is subdivided into Group B-I (ileum) and Group B-C (colon)), the mucosa and the submucosa were peeled off the seromuscular layer, as one layer and in one piece. It was easy to separate the submucosa from the muscular layers at one corner of the flaps with a fine pair of forceps. Injection of saline into the submucosa was not necessary. The microcirculation was recorded with Intravital Dark Field (IDF) side stream videomicroscopy (Cytoscan Braedius, Netherlands) in each group on the serosal and the raw surface at 0, 5, 15, 30, 60, 90, 120, 180 min after the mucosectomy procedure.

Quantifying microcirculation

Microcirculatory videos were performed with IDF-imaging device (Cytocam, Braedius medical, Huizen, Netherlands), in accordance with international standard recommendations [6]. The camera is fully digital and contains a high-resolution sensor, with a pixel size of 1.4 micron. Video files were saved directly to the Braedius CytoCam HDD in AVI format. Optical magnification of 4 \times was used, to provide a 1.55 \times 1.16 mm field of view.

The MFI is a semi-quantitative and summarized score, which is the mean value of four quadrant measurements. Categorical values are given based on predominant flow (no flow = 0, intermittent = 1, sluggish = 2, continuous = 3). Red blood cell velocity (RBCV) being a quantitative marker, which was measured using the CapScan software, for this purpose, programmed by our team. RBCV is presented in meter/second ($\mu\text{m}/\text{s}$).

Statistical analysis

Data analysis was performed with a statistical software package (Sigmaplot 13.0.0/2017 for Windows by Systat Software Inc., Jandel Scientific, Erkrath, Germany, 2017). Normality of data distribution was analyzed with the Shapiro–Wilk test. The Friedman ANOVA on ranks was applied within groups. Time-dependent differences from

the baseline for each group were assessed with Dunn's method. Differences of extra- and intraluminal side within the groups (Group A-I, Group B-I, Group A-C and Group B-C) were analysed with the Mann–Whitney test. Median values and 75th and 25th percentiles are provided in the figures; $p < 0.05$ were considered significant.

Results

Both the MFI and RBCV showed an abrupt reduction of microcirculation on both surfaces of the remaining intestinal flap in both, the ileum and the colon. Slightly better values were seen on the colon (Group A-C), but even these values remain far below the preoperative (control) results. The values on the raw surface of the bowel flaps was slightly higher than that measured on the serosal surface. Some recovery of the microcirculation was noted after 60–90 min, but this remained significantly lower than the

preoperative control values. The results are summarized in Figs. 1 and 2.

Discussion

In a previous study we had demonstrated that mucosectomy results in an abrupt gross reduction of the capillary blood flow in the ileum [5]. The colon was not studied, and the length of the ischemic period was not recorded. However, every organ tolerates warm ischemia for a certain time period.

The warm ischemia time of ileum was found to be up to 45 min in rats [6], 2 h in dogs [7]. Strand-Amundsen (2018) investigated viability of the porcine intestine after mesenteric obstruction [8]. Light microscopy showed loss of crypt epythel, congestion and bleeding in lamina propria, neutrophil infiltration, wavy myocytes and focal necrosis in both muscular layers after 3 h of ischemia and 8 h of

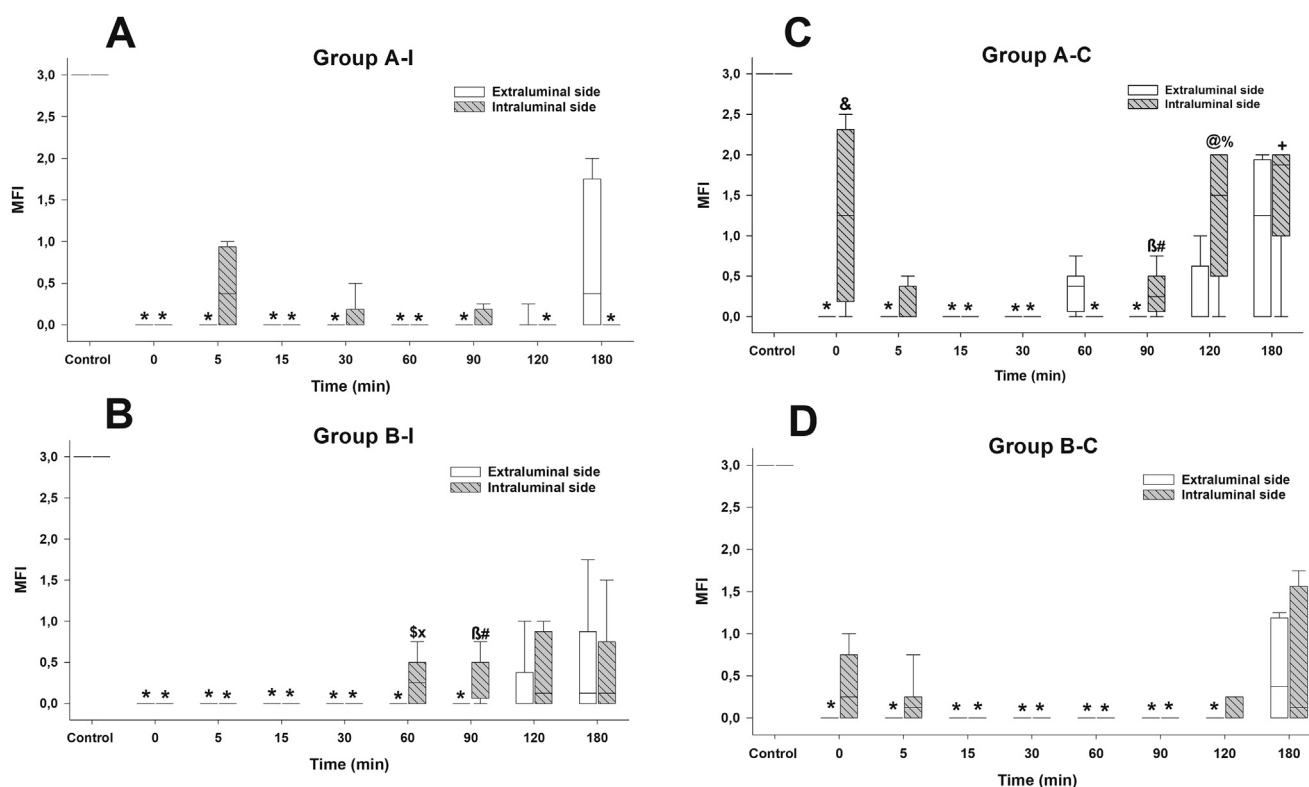


Fig. 1 Microvascular Flow Index. **A:** *Group A-I* (ileal sero-musculo-submucosal group) box plot diagram demonstrates results of the extraluminal side with white and the intraluminal side with white and line pattern; **B:** *Group B-I* (ileal seromuscular group) box plot diagram demonstrates results of the extraluminal side with white and the intraluminal side with white and line pattern; **C:** *Group A-C* box plot diagram demonstrates results of the extraluminal side with grey and the intraluminal side with grey and line pattern; **D:** *Group B-C* box plot diagram demonstrates results of the extraluminal side with grey and the intraluminal side with grey and line pattern. All of the plots demonstrate the median values (horizontal line in box plots) and the 25th (lower whisker) and 75th (upper whisker) percentiles, ($p < 0.05$). * $p < 0.05$ vs. baseline values. & $p < 0.05$ Group A-C extra-vs. intraluminal side 0 min; \$ $p < 0.05$ Group A-C extra-vs. intraluminal side 60 min; # $p < 0.05$ Group A-C extra-vs. intraluminal side 90 min; @ $p < 0.05$ Group A-C extra-vs. intraluminal side 120 min; x $p < 0.05$ Group A-C vs. Group B-C extraluminal side 60 min; β $p < 0.05$ Group A-C vs. Group B-C intraluminal side 90 min; % $p < 0.05$ Group A-C vs. Group B-C intraluminal side 120 min; + $p < 0.05$ Group A-C vs. Group B-C intraluminal side 180 min; \$ $p < 0.05$ Group B-I extra-vs. intraluminal side 60 min; # $p < 0.05$ Group B-I extra-vs. intraluminal side 90 min; x $p < 0.05$ Group A-I vs. Group B-I intraluminal side 60 min; β $p < 0.05$ Group A-I vs. Group B-I intraluminal side 90 min.

reperfusion. Electron microscopy demonstrated Inflammation, cell death, more comprehensive fine-vacuolization of the sarcoplasm, slightly swollen mitochondria, focal single cell necrosis, swollen cell nuclei after 3 h of ischemia and 3 h of reperfusion. Three hours of total ischemia of the small bowel followed by reperfusion was considered to be the upper limit for viability in porcine mesenteric ischemia model [7].

In humans the warm ischemia cut off time of the ileum for microvascular transplantation is considered between 1 and 2 h [9].

In the present study we demonstrated that the micro-circulation does not recover within the warm ischemia time of the ileum and colon after mucosectomy. Only minimal residual circulation was detected after mucosectomy. There was a degree of recovery in the RBCV, however both remained far below the control (preoperative) values. The partial re-establishment of circulation was seen after 60–90 min, sufficient to prevent acute necrosis. This is in accordance with our earlier observation where the flaps used for augmentation remained viable, even though they contracted [5].

When the muscularis propria and the muscularis mucosae are damaged, peristalsis and the movement of the villi will be lost. Regenerated scar tissue might not uphold sufficient peristalsis, and may lead to later stricture [10].

There is a plenty of clinical evidence for close relationship between ischemia, fibrosis and contraction [11–14].

Best example for systemic hypoxia induced intestinal stricture is the Necrotising enterocolitis (NEC) in premature neonates, where the link between NEC and intestinal stricture is well-known [15]. Almost 30% of NEC patients develop intestinal stricture long term [16]. Posttraumatic ischemic stenosis of the small bowel is rare condition, but a good example for local ischemia. After blunt trauma mesenteric defect causes ischemia of the corresponding bowel and result in stenotic, fibrotised/strictured bowel segment [17–19]. Similar example for local ischemia is when the superior rectal artery is divided below Sudeck’s point during sigmoidectomy, this been reported to cause ischemic stricture [20].

With the advancement of the Endoscopic Submucosal Dissection (ESD), which became a well-established minimal

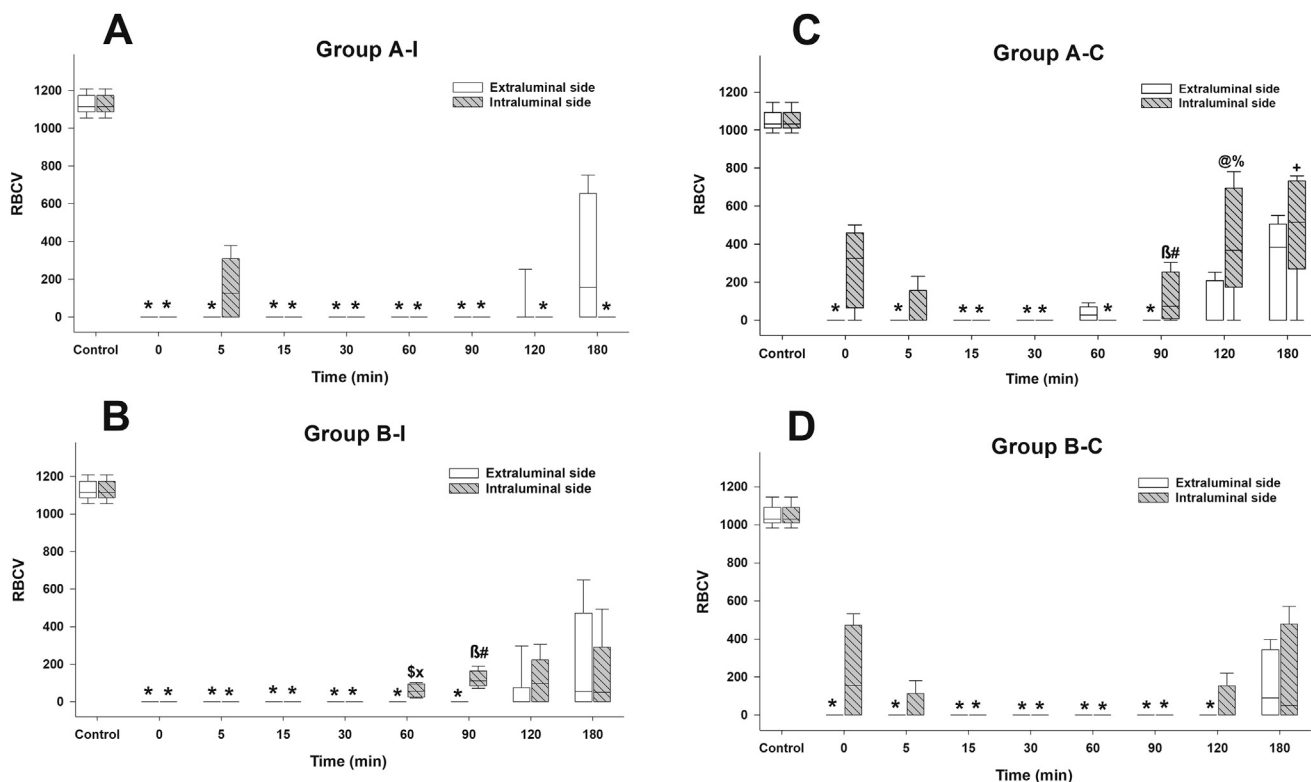


Fig. 2 Red Blood Cell Velocity. RBCV **A: Group A-I** (ileal sero-musculo-submucosal group) box plot diagram demonstrates results of the extraluminal side with white and the intraluminal side with white and line pattern; **B: Group B-I** (ileal seromuscular group) box plot diagram demonstrates results of the extraluminal side with white and the intraluminal side with white and line pattern; **C: Group A-C** box plot diagram demonstrates results of the extraluminal side with grey and the intraluminal side with grey and line pattern; **D: Group B-C** box plot diagram demonstrates results of the extraluminal side with grey and the intraluminal side with grey and line pattern. All of the plots demonstrate the median values (horizontal line in box plots) and the 25th (lower whisker) and 75th (upper whisker) percentiles, ($p < 0.05$). * $p < 0.05$ vs. baseline values; # $p < 0.05$ Group A-C extra-vs. intraluminal side 90 min; @ $p < 0.05$ Group A-C extra-vs. intraluminal side 120 min; β $p < 0.05$ Group A-C vs. Group B-C intraluminal side 90 min; % $p < 0.05$ Group A-C vs. Group B-C intraluminal side 120 min; + $p < 0.05$ Group A-C vs. Group B-C intraluminal side 180 min * $p < 0.05$ vs. baseline values \$ $p < 0.05$ Group B-I extra-vs. intraluminal side 60 min; # $p < 0.05$ Group B-I extra-vs. intraluminal side 90 min; x $p < 0.05$ Group A-I vs. Group B-I intraluminal side 60 min; β $p < 0.05$ Group A-I vs. Group B-I intraluminal side 90 min.

invasive management option of early gastrointestinal malignancies, it became clear that extensive removal of mucosa-submucosa with the malignant/premalignant lesion (above 75% of the circumference) results in stricture in esophagus, stomach or colorectum) [21–26]. In our experiment the removal of mucosa/submucosa corresponds to ESD. The stricture seen after excessive ESD is in accordance with our finding. Our study first provides link between mucosectomy and ischemia and explains stricture after excessive ESD i.e. mucosectomy.

Our results provide the first clear evidence that surgical mucosectomy in both ileum and colon induces ischemia beyond the warm ischemia time. This will inevitably result in flap fibrosis and contraction. Vascularisation is key to the long-term success of all bladder augmentations and must be the focus if we are to achieve mucus free composite flaps.

We did not observe any significant difference between the 2 mucosectomy processes (Group A and B). One would expect better results in Group A, with sero-musculo-submucosal flaps, where the submucous vascular plexus is not destroyed. This is however not the case according to our findings. The microcirculation of the sero-musculo-submucosal flaps also dropped significantly and only partially recovered showing no significantly better values than the seromuscular flaps. This is in accordance with our experience in the earlier study where we found seromusculo-submucosal flaps contracted after augmentation [5,27]. Furthermore, it is known that due to mucosal regrowth sero-musculo-submucosal flaps may not be ideal to eliminate mucus from augmented bladder.

In our previous study we tried to re-vascularise the flaps after mucosectomy with omentum, but it failed to prevent contraction of ileum [5]. It is likely that by the time the blood vessels from the omentum had established neovascularisation, the bowel flaps have already suffered irreversible ischemic damage. Pre-vascularisation of the donor organ perhaps with omentum before mucosectomy in the future might remain an option. But again it will be difficult to establish neovascularisation if previous vascular structure is intact. In addition, mucosectomy causes damage to the enteric nervous system which may compromise results [27].

Mucus free bladder augmentation using intestinal segment is an ideal goal but remains difficult to achieve. Surgical removal of the mucosa result in severe prolonged ischemia as well as damage to the enteric nervous system both in the ileum and the colon with resultant fibrosis and contraction of these flaps.

Funding

The study was supported by Hungarian National Research, Development and Innovation Office grant NKFIH-K116861.

Acknowledgement

The authors are grateful to Mihály Boros, József Kaszaki, Szabolcs Tallós, Attila Rutai and the colleagues of the SZTE Institute of Surgical Research for their helpful assistance and great advices.

References

- [1] Urbán D, Cserni T, Boros M, Juhász Á, Érces D, Varga G. Bladder augmentation from an insider's perspective: a review of the literature on microcirculatory studies. *Int Urol Nephrol* 2021;53: 2221–30. <https://doi.org/10.1007/s11255-021-02971-y>.
- [2] Turner A, Subramanian R, Thomas DFM, Hinley J, Abbas SK, Stahlschmidt J, et al. Transplantation of autologous differentiated urothelium in an experimental model of composite cystoplasty. *Eur Urol* 2011;59:447–54. <https://doi.org/10.1016/j.eururo.2010.12.004>.
- [3] Zhang Y, Liu G, Kropp BP. Re-epithelialization of demucosalized stomach patch with tissue-engineered urothelial mucosa combined with Botox A in bladder augmentation. *BJU Int* 2012;110: E106–12. <https://doi.org/10.1111/j.1464-410X.2011.10845.x>.
- [4] Hidas G, Lee HJ, Bahoric A, Kelly MS, Watts B, Liu Z, et al. Aerosol transfer of bladder urothelial and smooth muscle cells onto demucosalized colonic segments for bladder augmentation: in vivo, long term, and functional pilot study. *J Pediatr Urol* 2015;11: 260.e1-6. <https://doi.org/10.1016/j.jpuro.2015.02.020>.
- [5] Cervellione RM, Hajnal D, Varga G, Rakoczy G, Kaszaki J, Keene D, et al. Mucosectomy impairs ileal microcirculation and results in flap contraction after experimental ileocystoplasty. *J Pediatr Urol* 2017;13:81.e1–5. <https://doi.org/10.1016/j.jpuro.2016.11.007>.
- [6] Illyés G, Hamar J. Sequence of morphological alterations in a small intestinal ischaemia/reperfusion model of the anesthetized rat. A light microscopy study. *Int J Exp Pathol* 1992; 73:161–72.
- [7] Robinson JW, Haroud M, Winistörfer B, Mirkovitch V. Recovery of function and structure of dog ileum and colon following two hours' acute ischaemia. *Eur J Clin Invest* 1974;4:443–52. <https://doi.org/10.1111/j.1365-2362.1974.tb00418.x>.
- [8] Strand-Amundsen RJ, Reims HM, Reinholt FP, Ruud TE, Yang R, Høgetveit JO, et al. Ischemia/reperfusion injury in porcine intestine - viability assessment. *World J Gastroenterol* 2018; 24: 2009–23. <https://doi.org/10.3748/wjg.v24.i18.2009>.
- [9] Chen S-H, Tang Y-B, Chen H-C. Survival of transferred ileum after ischemia time longer than 1 hour: a clinical result different from animal studies. *J Am Coll Surg* 2013;217:300–5. <https://doi.org/10.1016/j.jamcollsurg.2013.03.018>.
- [10] Horgan PG, Gorey TF. Operative assessment of intestinal viability. *Surg Clin North Am* 1992;72:143–55. [https://doi.org/10.1016/s0039-6109\(16\)45632-x](https://doi.org/10.1016/s0039-6109(16)45632-x).
- [11] Cheng W, Heitmiller RF, Jones B. Subacute ischemia of the colon esophageal interposition. *Ann Thorac Surg* 1994;57: 899–903. [https://doi.org/10.1016/0003-4975\(94\)90199-6](https://doi.org/10.1016/0003-4975(94)90199-6).
- [12] Shavell VI, Saed GM, Diamond MP. Review: cellular metabolism: contribution to postoperative adhesion development. *Reprod Sci* 2009;16:627–34. <https://doi.org/10.1177/1933719109332826>.
- [13] Strowitzki MJ, Ritter AS, Kimmer G, Schneider M. Hypoxia-adaptive pathways: a pharmacological target in fibrotic disease? *Pharmacol Res* 2019;147:104364. <https://doi.org/10.1016/j.phrs.2019.104364>.
- [14] Lim DR, Hur H, Min BS, Baik SH, Kim NK. Colon stricture after ischemia following a robot-assisted ultra-low anterior resection with coloanal anastomosis. *Ann Coloproctol* 2015;31: 157–62. <https://doi.org/10.3393/ac.2015.31.4.157>.
- [15] Phad N, Trivedi A, Todd D, Lakkundi A. Intestinal strictures post-necrotizing enterocolitis: clinical profile and risk factors. *J Neonatal Surg* 2014;3:44.
- [16] Necrotizing Enterocolitis - Pediatrics. MSD Manual Professional Edition n.d. <https://www.msmanuals.com/en-gb/professional/pediatrics/gastrointestinal-disorders-in-neonates-and-infants/necrotizing-enterocolitis> (accessed March 2, 2022).

- [17] Lee-Elliott C, Landells W, Keane A. Using CT to reveal traumatic ischemic stricture of the terminal ileum. *AJR Am J Roentgenol* 2002;178:403–4. <https://doi.org/10.2214/ajr.178.2.1780403>.
- [18] Lien GS, Mori M, Enjoji M. Delayed posttraumatic ischemic stricture of the small intestine. A clinicopathologic study of four cases. *Acta Pathol Jpn* 1987;37:1367–74. <https://doi.org/10.1111/j.1440-1827.1987.tb00469.x>.
- [19] Bryner UM, Longerbeam JK, Reeves CD. Posttraumatic ischemic stenosis of the small bowel. *Arch Surg* 1980;115:1039–41. <https://doi.org/10.1001/archsurg.1980.01380090019005>.
- [20] Yamazaki T, Shirai Y, Sakai Y, Hatakeyama K. Ischemic stricture of the rectosigmoid colon caused by division of the superior rectal artery below Sudeck's point during sigmoidectomy: report of a case. *Surg Today* 1997;27:254–6. <https://doi.org/10.1007/BF00941656>.
- [21] Park CH, Yang D-H, Kim JW, Kim J-H, Kim JH, Min YW, et al. Clinical practice guideline for endoscopic resection of early gastrointestinal cancer. *Clin Endosc* 2020;53:142–66. <https://doi.org/10.5946/ce.2020.032>.
- [22] Spadaccini M, Belletrutti PJ, Attardo S, Maselli R, Chandrasekar VT, Galtieri PA, et al. Safety and efficacy of multiband mucosectomy for Barrett's esophagus: a systematic review with pooled analysis. *Ann Gastroenterol* 2021;34:487–92. <https://doi.org/10.20524/aog.2021.0620>.
- [23] Alzoubaidi D, Graham D, Bassett P, Magee C, Everson M, Banks M, et al. Comparison of two multiband mucosectomy devices for endoscopic resection of Barrett's esophagus-related neoplasia. *Surg Endosc* 2019;33:3665–72. <https://doi.org/10.1007/s00464-018-06655-0>.
- [24] Ohara Y, Toyonaga T, Tanaka S, Ishida T, Hoshi N, Yoshizaki T, et al. Risk of stricture after endoscopic submucosal dissection for large rectal neoplasms. *Endoscopy* 2016;48:62–70. <https://doi.org/10.1055/s-0034-1392514>.
- [25] Iizuka H, Kakizaki S, Sohara N, Onozato Y, Ishihara H, Okamura S, et al. Stricture after endoscopic submucosal dissection for early gastric cancers and adenomas. *Dig Endosc* 2010;22:282–8. <https://doi.org/10.1111/j.1443-1661.2010.01008.x>.
- [26] Kantsevov SV. Stenosis after colorectal endoscopic submucosal dissection: when to expect, how to manage? *Gastrointest Endosc* 2017;86:370–1. <https://doi.org/10.1016/j.gie.2017.04.031>.
- [27] Urbán D, Marei MM, Hajnal D, Varga G, Érces D, Poles M, et al. Mucosectomy disrupting the enteric nervous system causes contraction and shrinkage of gastrointestinal flaps: potential implications for augmentation cystoplasty. *J Pediatr Urol* 2020;16:20–6. <https://doi.org/10.1016/j.jpuro.2019.08.019>.